Finishing the cast restoration

Ashur University College

Dr. Mohammed Moudhaffer

Lect 17&18

Sequence for finishing a cast restoration

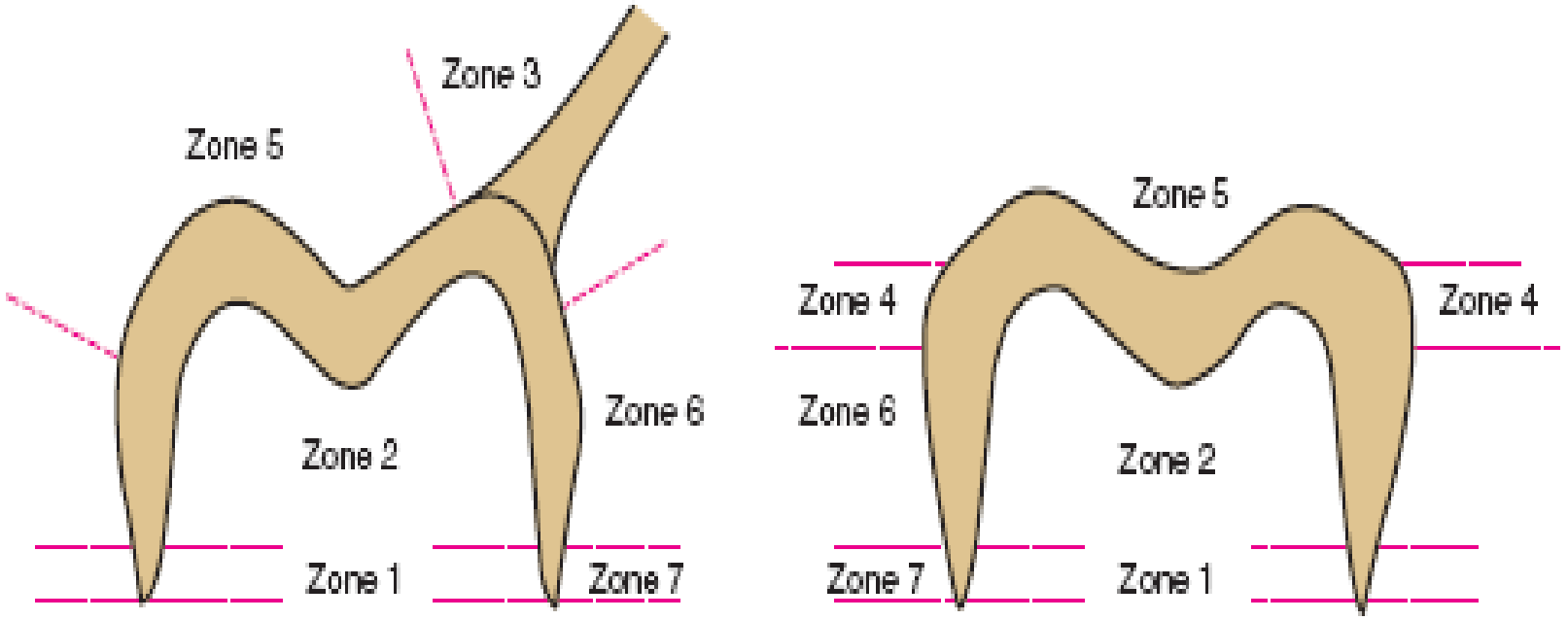

Fig. 29-1

Recommended sequence for finishing of a cast restoration. All procedures for a zone should be completed before the next zone is started. *Zone 1* is the internal margin; *Zone 2*, the internal surface; *Zone 3*, the sprue; *Zone 4*, the proximal contacts; *Zone 5*, the occlusal surface; *Zone 6*, the axial walls; and *Zone 7*, the external margins.

Zone 1: Internal Margin

Objective

To minimize any dissolution of the luting agent, a 1-mm-wide band of metal must be obtained that is closely adapted to the tooth surface. A defect within this zone can significantly reduce a restoration's longevity. Good adaptation is obtained by carefully reflowing the wax pattern.

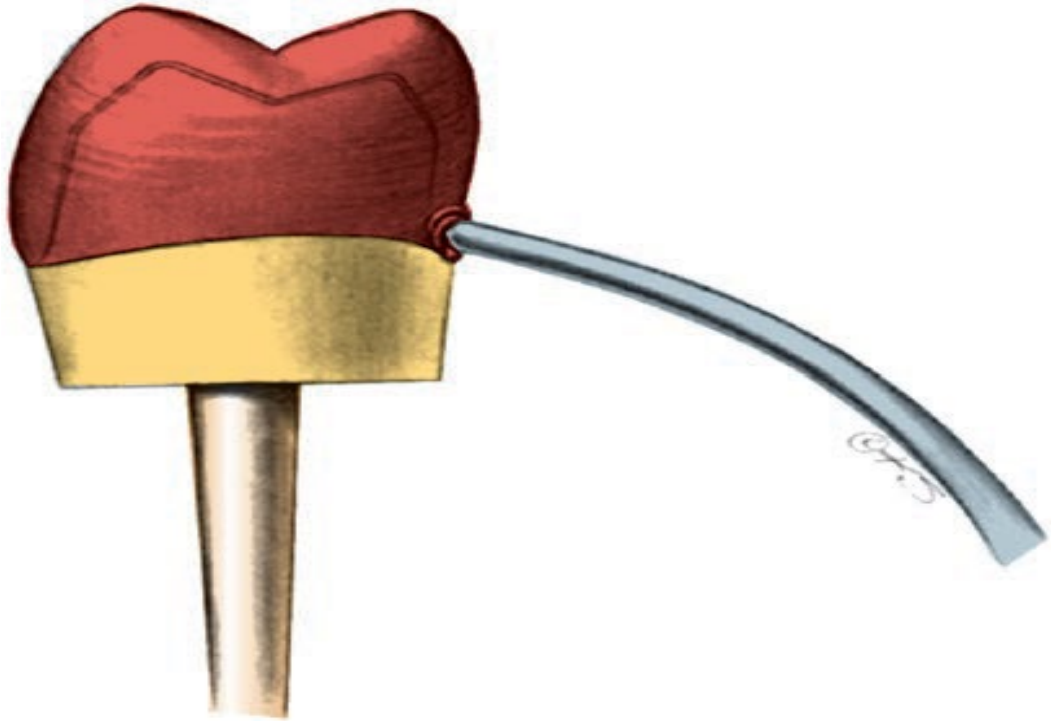

Procedure

If a defect occurs in the marginal area, the restoration must be remade. This may require an additional patient visit to make the new impression. Defects can be prevented or minimized by paying particular attention to reflowing the margins of the wax pattern and through careful investing.

Even small nodules can prevent a casting from seating completely. Careful examination under ample magnification helps identify interferences. Small nodules, if far enough away from the margin itself, can be removed with exceptionally cautious use of very small rotary instruments (e.g., a No. 1/4 round bur).

NEVER force the casting onto the die; use great caution when fitting the casting.

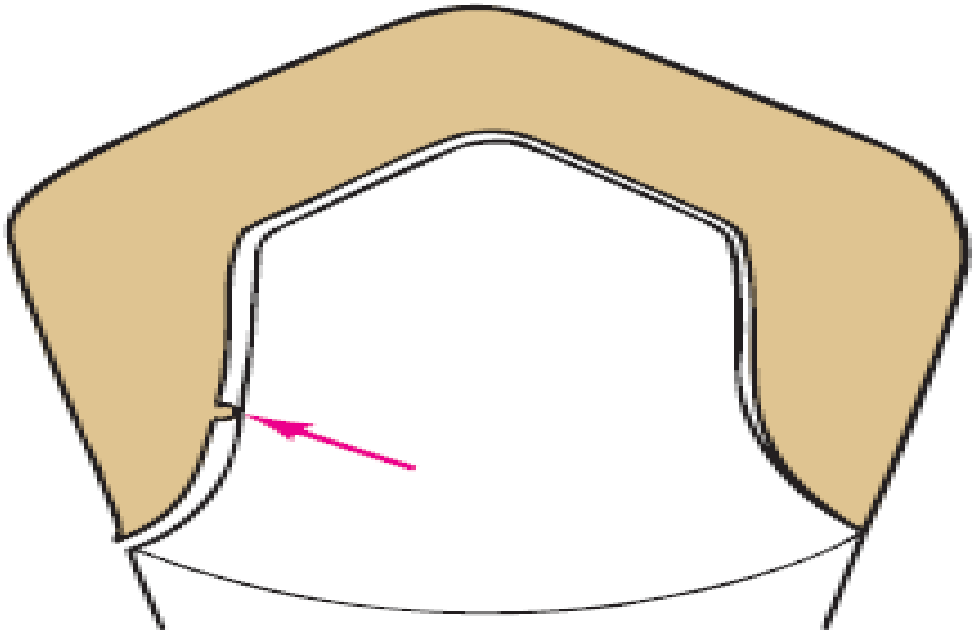

FIGURE 28-4 A relatively small nodule *(arrow)* results in stantial marginal gap width.

Zone 2: Internal Surface

Objective

No contact should exist between the die and the internal surface of the casting. A uniform space of 25 to 35 µm is necessary for the luting agent to spread evenly. Any contacts must be identified and relieved by careful selective grinding of the internal surface.

Procedure

Under normal circumstances, a casting's internal surface does not require finishing. It should, however, be examined for nodules before the restoration is seated on the die. Nodules can be removed with a small round carbide bur, which can be time consuming because it may need to be repeated several times.





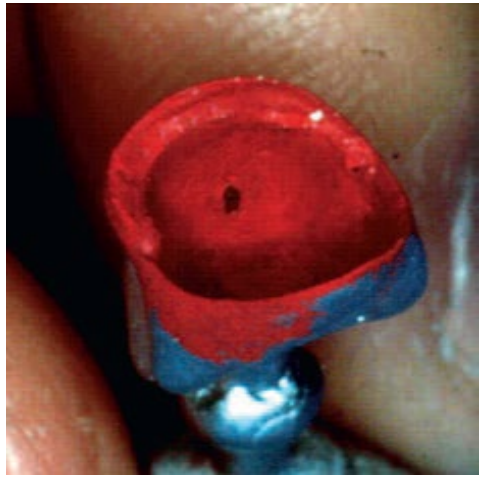

Nodules on this casting have resulted from improper investing. To enable complete seating of the casting, even small ones such as these must be removed entirely.

Zone 3: The Sprue:

Objective

To reestablish proper coronal structure and function, the sprue must be sectioned, and the casting must be recontoured in the area of its attachment.

Procedure

Once the fit of the casting has been verified on the die and it has been found to be acceptable, the sprue is sectioned, and the area of its attachment to the casting is reshaped.

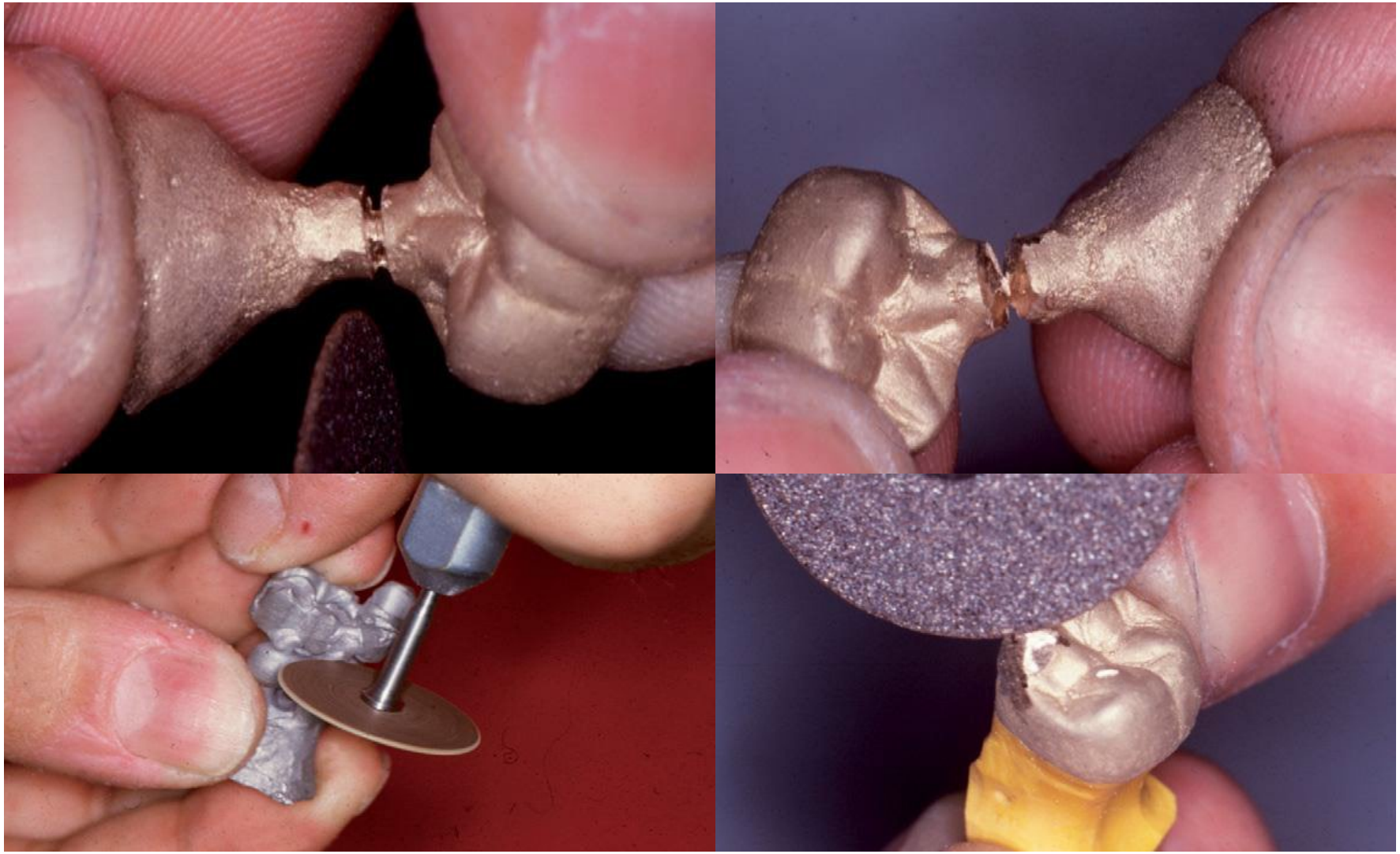

A carborundum separating disk is used to cut through the sprue. Cutting should be performed circumferentially, with a small area maintained in the center of the sprue. This last connection is broken by twisting and separating it from the casting.

Zone 4: Proximal Contacts:

Objective

The proximal contact areas are adjusted in the laboratory so that they will be correct (or slightly too tight) when the casting is evaluated in the mouth.

Procedure

Special care is needed to prevent the finishing procedures from producing an over reduced and, consequently, inadequate proximal contact. Although this can be corrected with solder , it is a time consuming and unnecessary procedure.

Rather than risk a deficient proximal contact at evaluation, the technician may reduce the cast slightly by scraping the adjacent teeth with a blade.



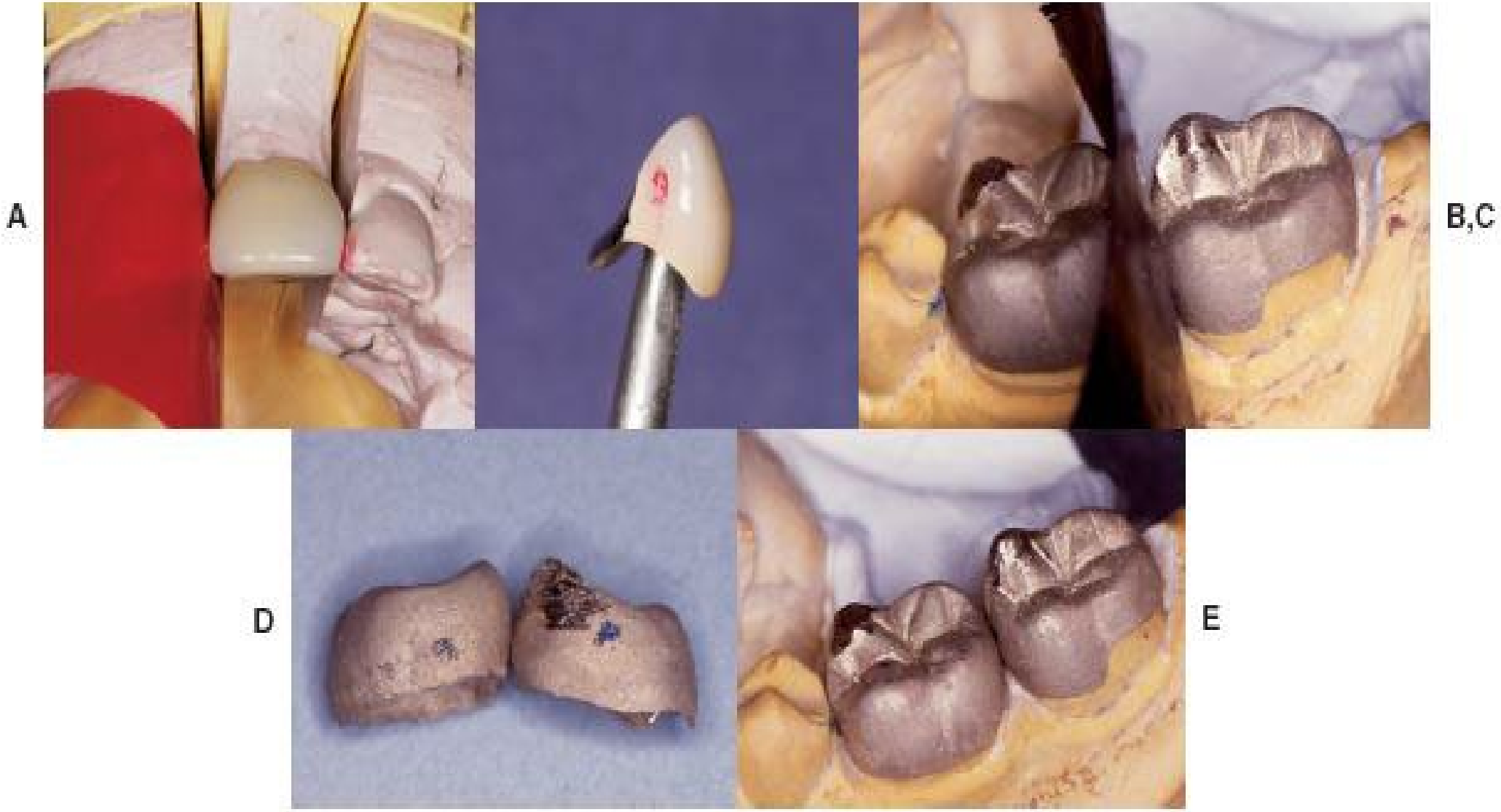

Fig. 29-10

A, Thin articulating film interposed between a metal-ceramic restoration and the adjacent tooth. **B**, The area of contact that prevents complete seating is readily apparent. **C** to **E**, Articulating film is used to detect the location of an excessive proximal contact on cast metal.

Zone 5: Occlusal Surface

Objective

Occlusal contacts are reestablished in static and dynamic relationships to the opposing arch.

Procedure

The occlusal contacts are checked with thin Mylar articulating film to ensure that they match the design in the waxing stage. If they do not, the occlusion must be adjusted.

Occlusal prematurities are generally the result of excessively heavy contact on the wax pattern.

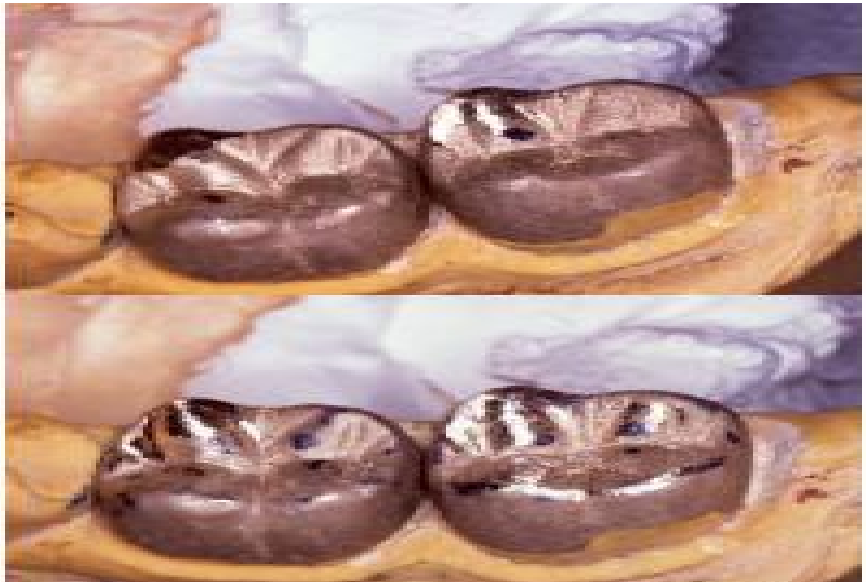

Occlusal adjustment

A

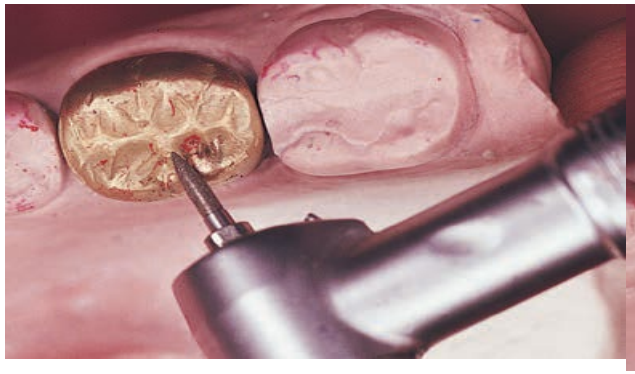

B

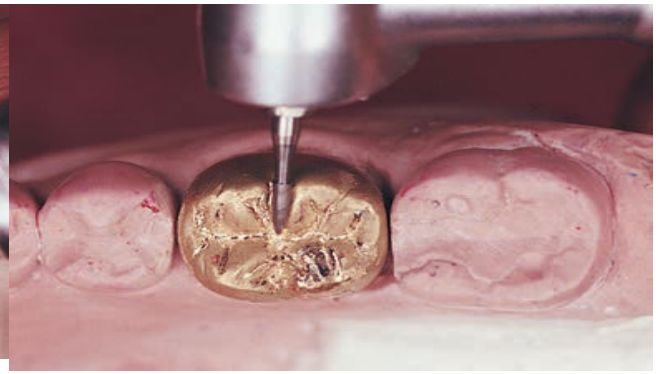

A, Occlusal adjustment is readily accomplished with a pointed diamond or carbide bur. B, The grooves and fissures are concurrently refined.

For structural durability, metal thickness of less than 1.0 mm is inadequate and is the result of insufficient occlusal reduction.



Zone 6: Axial Walls

Objective

When axial wall finishing is completed, the walls should be smoothly contoured and highly polished, enabling the patient to carry out optimum plaque control.

Procedure

Surface defects are removed by grinding with abrasive particles bound into a grinding stone or rubber wheel, on a paper disk, or applied as an abrasive paste.




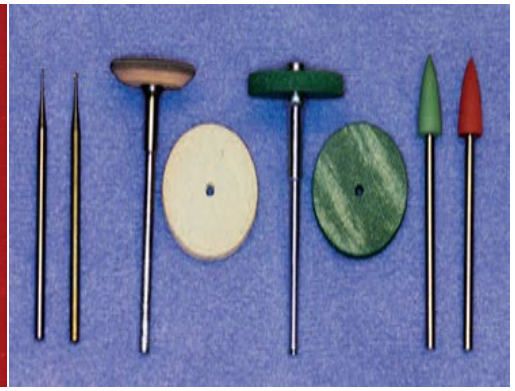

Zone 7: External Margins

The objective of all cast restoration finishing is a highly polished metal surface without ledges or steps as the transition is made from restoration to unprepared tooth. Failure to accomplish this leads to compromised plaque control.

Procedure

Care must be taken not to remove more metal than is strictly necessary. Excessive finishing creates problems similar to those caused by incomplete polishing. The edge of the margin must not be distorted during finishing, although carefully rubbing a smooth instrument along the length of the margin (burnishing) may improve the margin, but only when softer alloys are used.



Gently brushing a fine-grit stone over the surface to remove casting roughness



When the casting is smooth on all critical surfaces, any remaining polishing compound can be removed with a soft toothbrush, by ultrasonic cleaning in an appropriate solution, or by steam cleaning.



FIGURE 28-21 ■ Technique review. **A,** The internal margin is inspected to confirm that the casting accurately reproduces the prepared tooth and is intimately adapted to the prepared surfaces adjacent to the margin. **B,** The internal surface is inspected under magnification and adjusted as necessary with small stones and carbide burs. **C,** The casting should seat completely without force and without noticeable rocking or instability. **D,** The sprue is removed. **E,** The area of its attachment is reshaped. **F,** The proximal contact areas are identified. **G,** On the cast, proximal contacts can be left slightly tight before the clinical evaluation appointment. **H,** The occlusal surfaces are evaluated and adjusted. **I,** The axial surfaces are finished and polished. **J,** The polished restoration is cleaned.

Thank you