Ashur University College
Crown and Bridge
2nd year Prosthodontics
Technology dept.
Lect 12&13

Dr. Mohammed Moudhaffer M Ali

Wax Pattern for Posterior Teeth

The following sequence is recommended for waxing posterior teeth:

1. **Internal surface.**
2. **Wax pattern removal and evaluation.**
3. **Proximal surfaces.**
4. **Axial surfaces.**
5. **Occlusal surfaces.**
6. **Margin finishing.**

1. Internal Surface

Forming a closely adapted internal surface is the first step in waxing. The wax must reproduce all retention features of the restoration.

a. Apply die lubricant generously with a clean brush. Allow the lubricant to dry, and paint on a second coat.

b. Flow wax onto the die from a well-heated, large waxing instrument, making sure that any previous application is partially remelted. A large instrument holds sufficient heat to partially remelt previous wax increments and to prevent folds or lines from developing in the fitting surface.

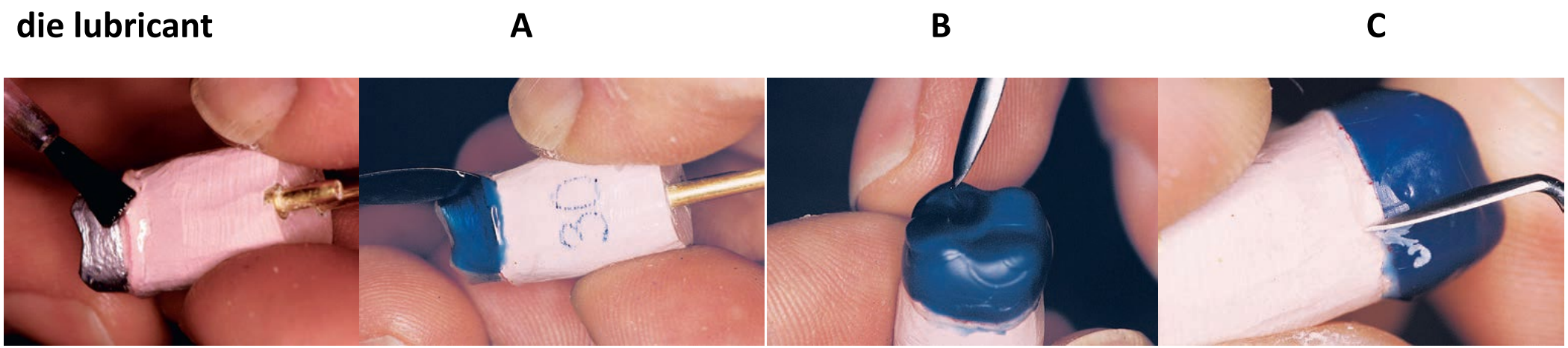

Forming the initial copings. A, A large instrument is used to keep the wax sufficiently hot. Previous applications should be remelted as additional wax is added. B, Wax is added to build up adequate bulk for rigidity. C, The wax is trimmed very carefully to the margin.

2. Wax Pattern Removal

The wax should be allowed to cool thoroughly before the coping is removed from the die. To remove the coping, the thumb and forefinger of one hand maintain a constant light grip on the pattern.

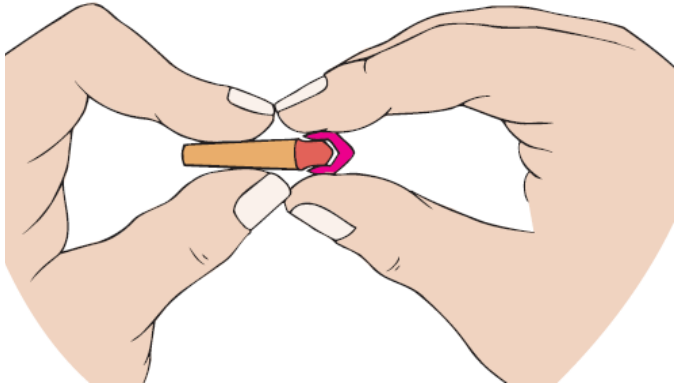

A

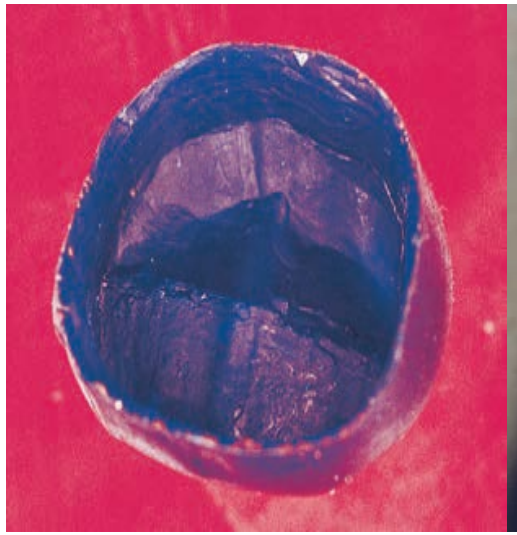

B



Evaluation. A, Well-adapted pattern. B, Poor adaptation. Folds and creases indicate that the wax was not hot enough when applied.

3. Proximal surfaces.

a- The proximal contact area of posterior teeth is located in the occlusal third of the crowns except for the contacts between the maxillary 1st and 2nd molars which are located at the middle 3rd.

b. The proximal contacts are located slightly to the buccal aspect of the middle of the posterior teeth, except for the contacts between maxillary 1st and 2nd molars which are located at the centered buccolingually.

A **B**

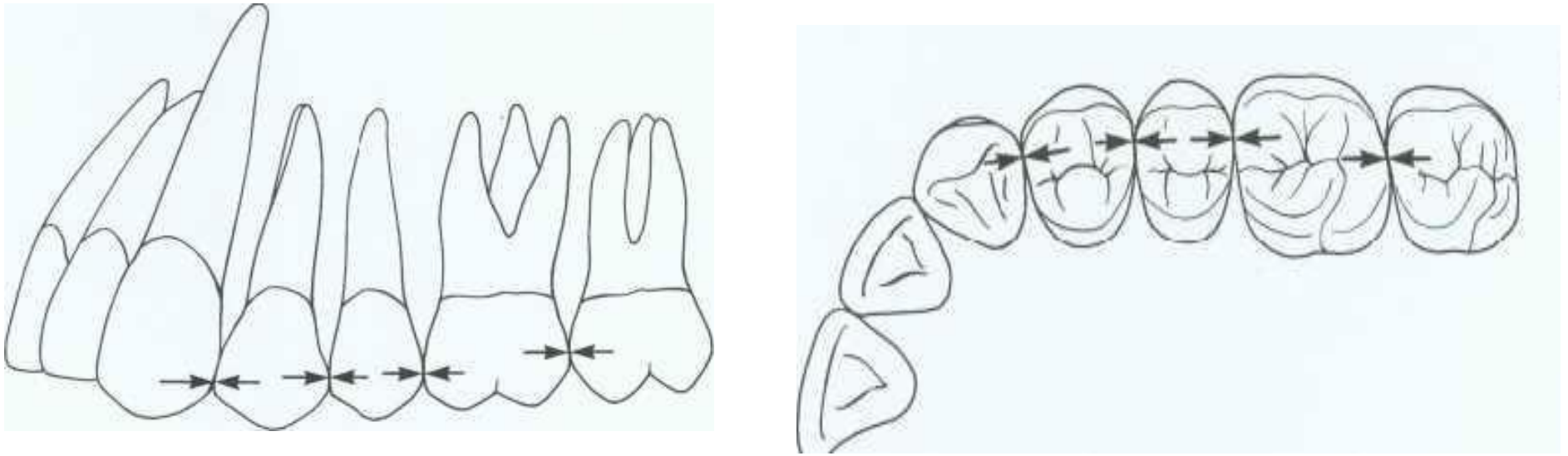

Location of the proximal contact areas. **A,** On maxillary teeth: progressively more occlusal and buccal the more anterior the tooth. **B**

Note how the position of the interproximal contact changes as you progress from anterior to posterior in both the maxillary and mandibular arches.

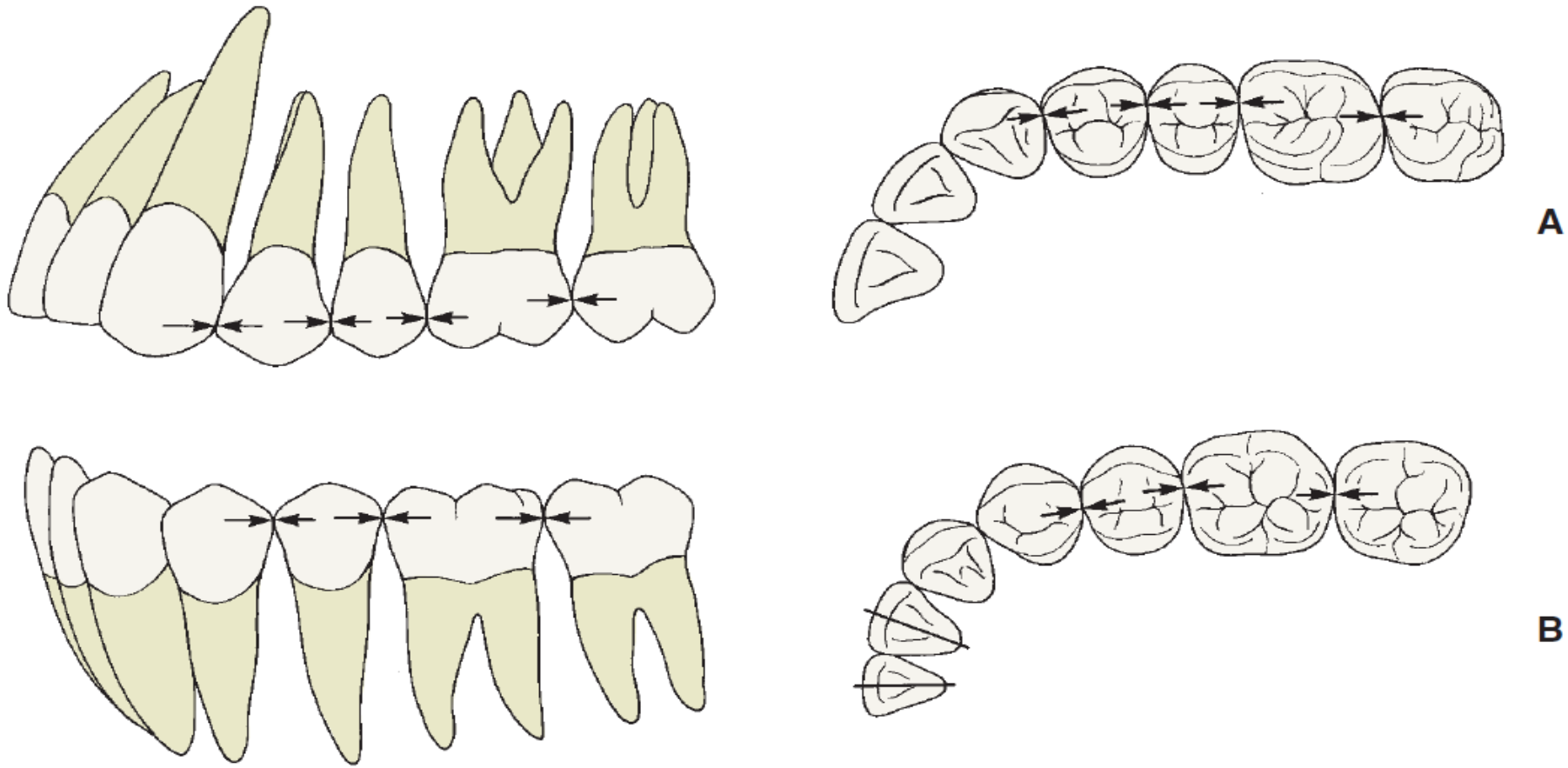

FIGURE 18-23 ■ Location of the proximal contact areas. **A,** On maxillary teeth: progressively more occlusal and buccal the more anterior the tooth. **B,** On mandibular posterior teeth: central.

c. The proximal surfaces of natural teeth are not convex . They tend to be flat or slightly concave from the contact area to the cementoenamel junction, and any restoration must reproduce this feature.



FIGURE 18-22 ■ Proximal surfaces gingival to the contact area are normally flat or concave. Note the triangular shape of the posterior embrasures.

4. Axial surface

a. The height of contour on the facial surface of posterior teeth usually occurs in the cervical third. It occurs in the middle third on the lingual surface of premolars and molars, but on the mandibular teeth, it occurs in the middle 3rd.

b. The amount of lingual prominence (height of contour) for mandibular molars is 1mm.

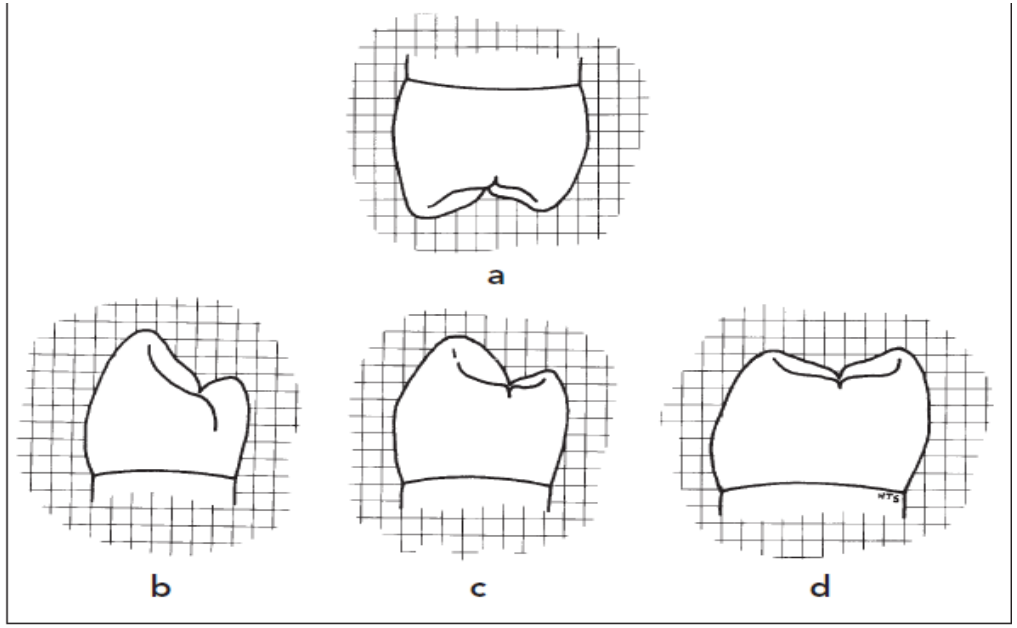

Fig 19-8 Height of contour on the facial surface of all posterior teeth extends horizontally 0.5 mm beyond the plane of the root. On the lingual surface of maxillary teeth *(a)* and mandibular first premolars *(b)*, the height of contour also extends 0.5 mm, but it increases to 0.75 mm on mandibular second premolars *(c)* and 1.0 mm on mandibular molars *(d)*.

c. The tooth surface gingival to its height of contour immediately adjacent to the gingival soft tissues, sometimes called the emergence profile, is usually flat or concave. Creation of a convexity in this area or a shelf or ledge makes bacterial plaque removal more difficult and has been shown to cause inflammatory and hyperplastic changes in the marginal gingiva.

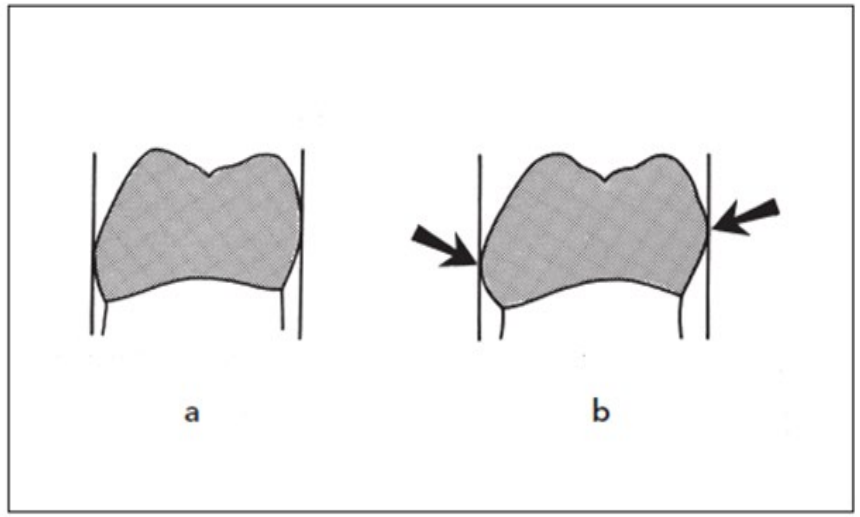

Fig 19-11 Axial contours of a full veneer crown on a mandibular molar: *(a)* correct; *(b)* overcontoured.

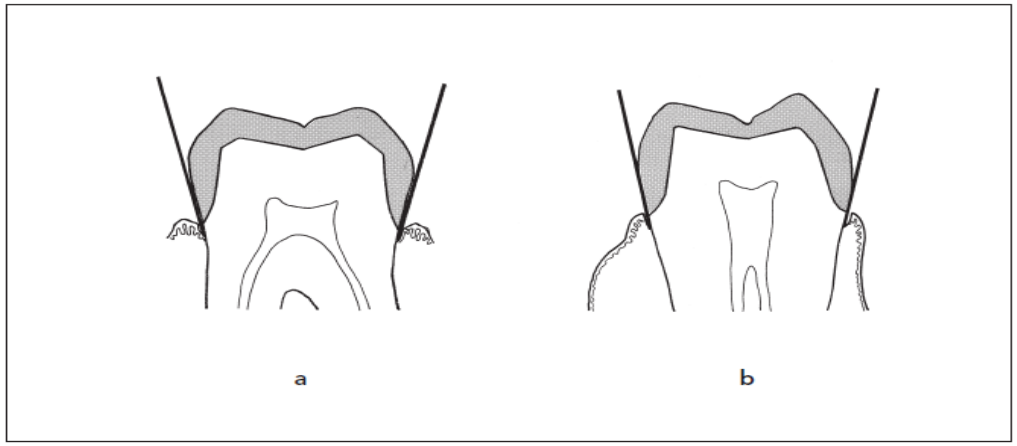

Fig 19-9 Emergence profile of the proximal surfaces *(a)* and of the facial and lingual contours *(b)*.

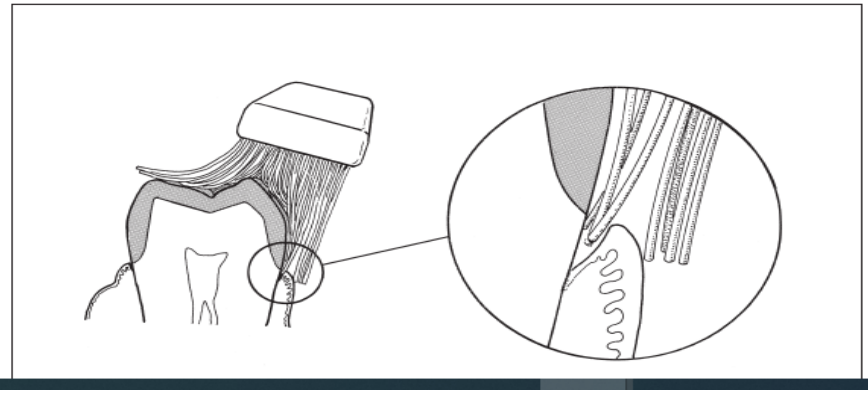

5. Occlusal surface

a. **The cusps and ridges of the occlusal surfaces should be shaped to allow even contact with the opposing teeth and directing forces along their long axis. Non functional or non centric cusps (buccal teeth of the upper and lingual teeth of the lower) should overlap vertically and horizontally, preventing accidental biting of the cheek or tongue and keeping food on the occlusal table.**

b. Point contacts between opposing teeth are preferable to broad, flat occlusal contacts because wear of the restorations is minimized and mastication of tough or fibrous foods is improved.

Occlusal Scheme:

2 occlusal schemes are present:

1- Cusp-marginal ridge scheme.

2- Cusp-fossa scheme.

In cusp-marginal ridge scheme, the buccal cusps of the lower premolars and mesiobuccal cusps of the lower molars contact the embrasures between upper teeth (contact two teeth).

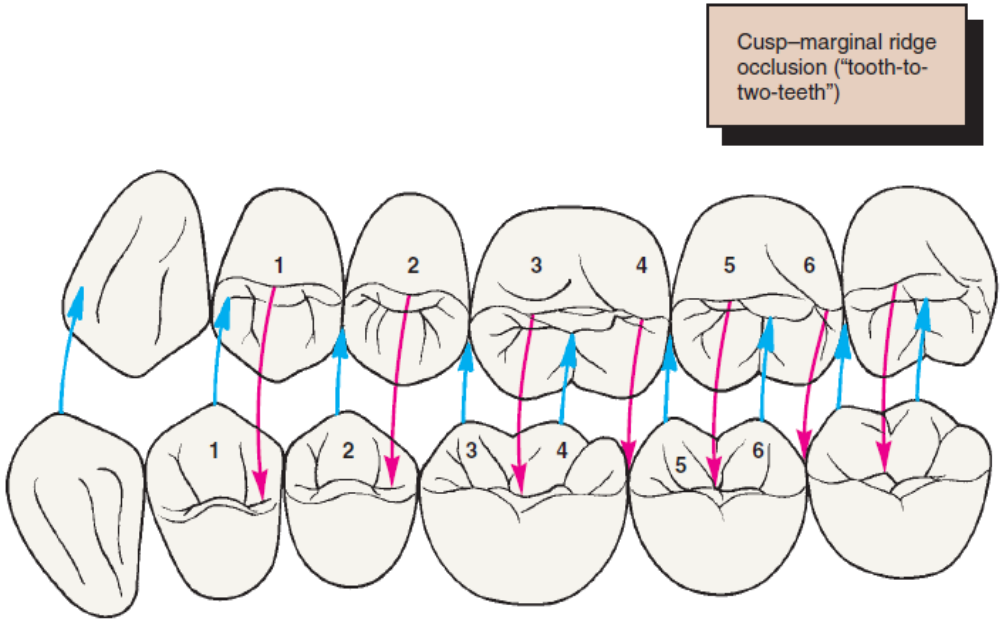

In cusp- fossa scheme, these lower centric cusps contact farther distally into the mesial fossa of the upper tooth (contact one tooth), the lingual (centric) cusps of the maxillary teeth contact the fossa of the lower teeth in both scheme.

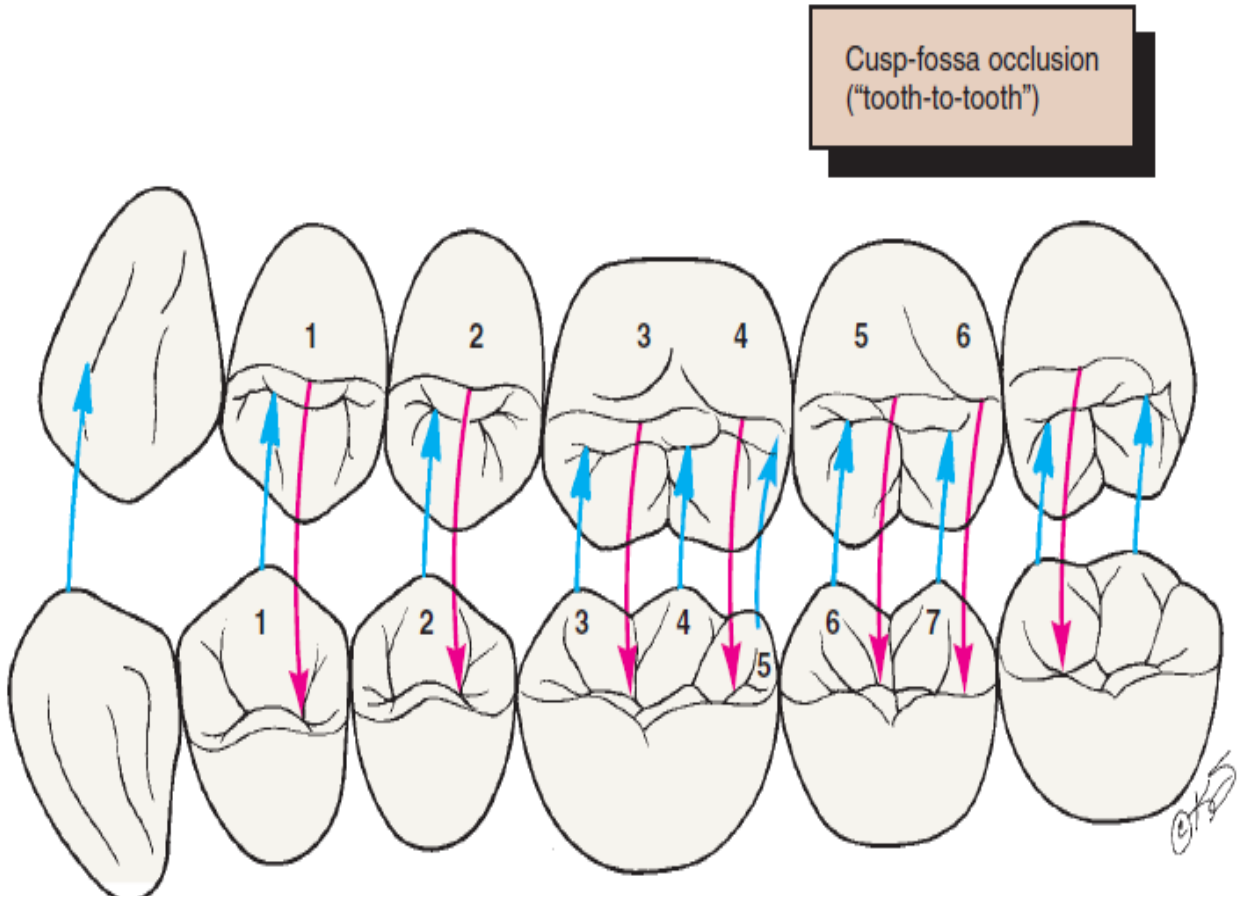

Waxing the Occlusal surface:

1- Position the cones for upper or lower buccal and lingual cusp, the length of cones can be determined by contacting with the opposing teeth.

Evaluation

The cones should be positioned so they follow the anteroposterior curve (sometimes referred to as the curve of Spee). The mandibular cusps should become taller farther distally, and the maxillary cusps should become shorter. They should also follow a mediolateral curve (the curve of Wilson) which is the in the mandibular arch.

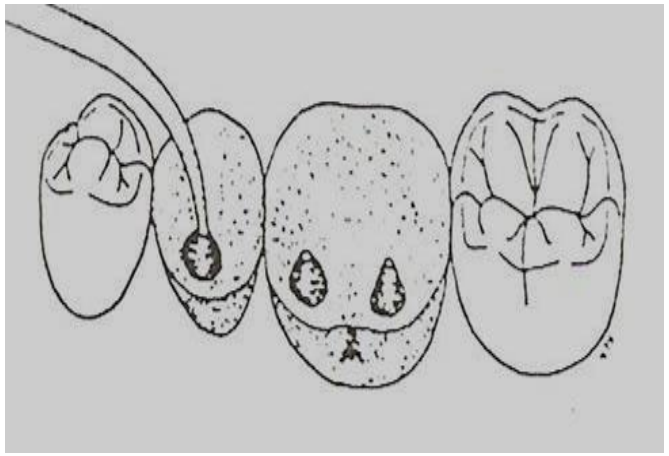

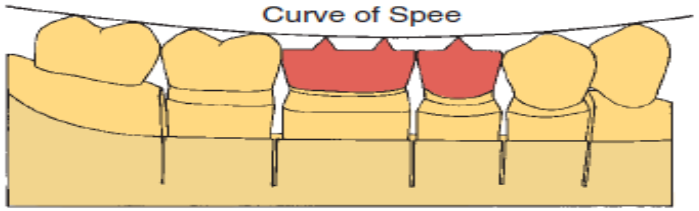



2- Place mesial and distal cusp ridges, by applying the wax from the tip of the cones to its base.

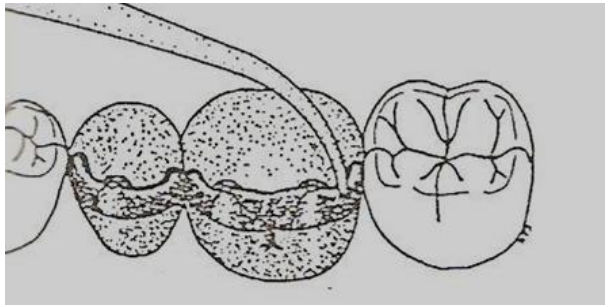

3- Place mesial and distal marginal ridges.

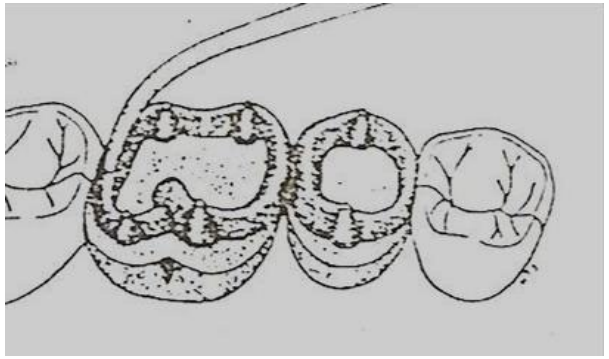

4- Place an axial ridge (buccal and lingual cusps ridges).

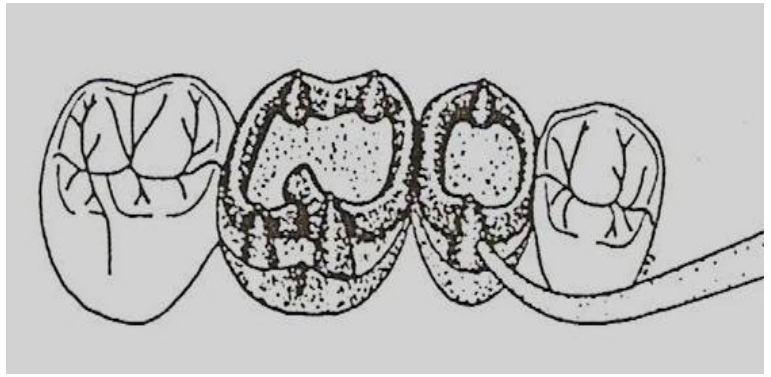

5- Place a triangular ridges, and secondary ridges.

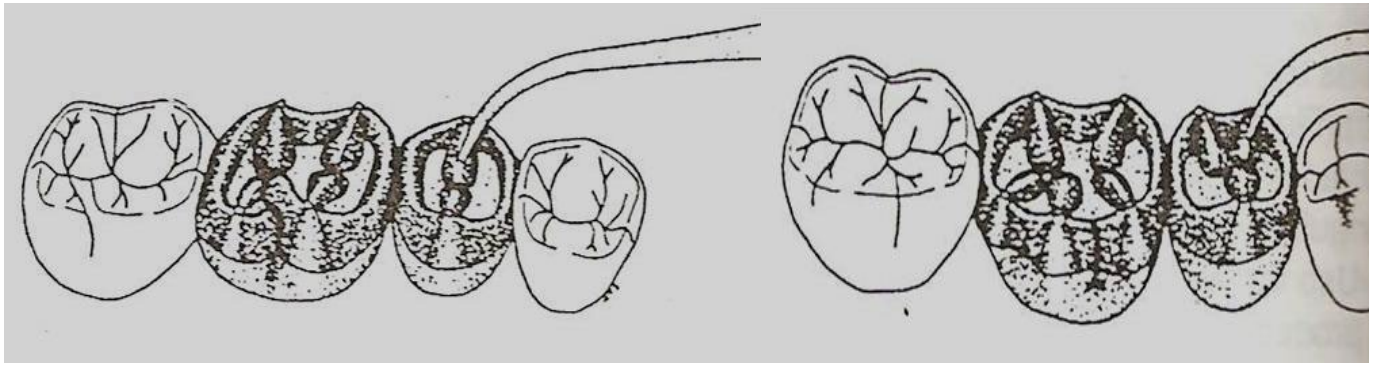

6- Smooth all grooves and fossae, the occlusal morphology complete.

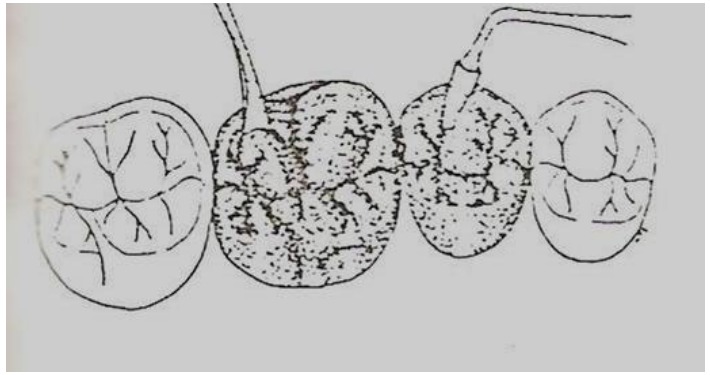

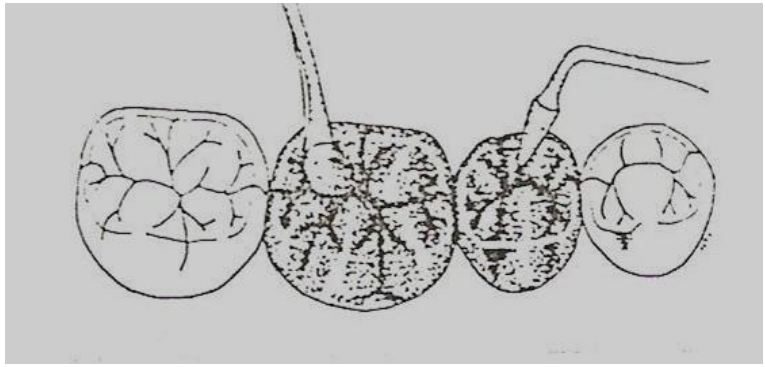

7- Remelt the margin, and add the wax on it and remove the excess.

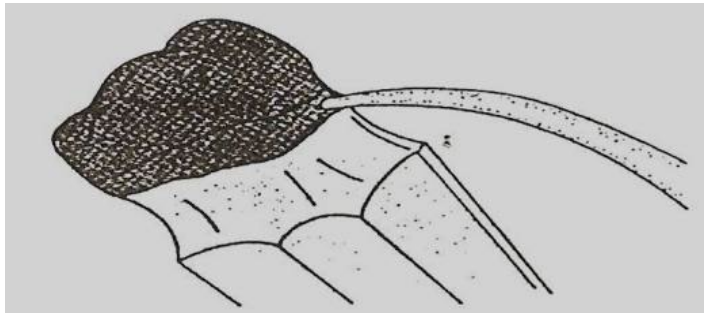

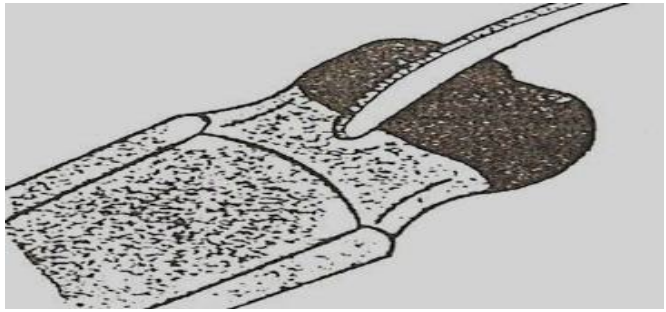

8- Check the wax pattern for any thin spots to correct them.

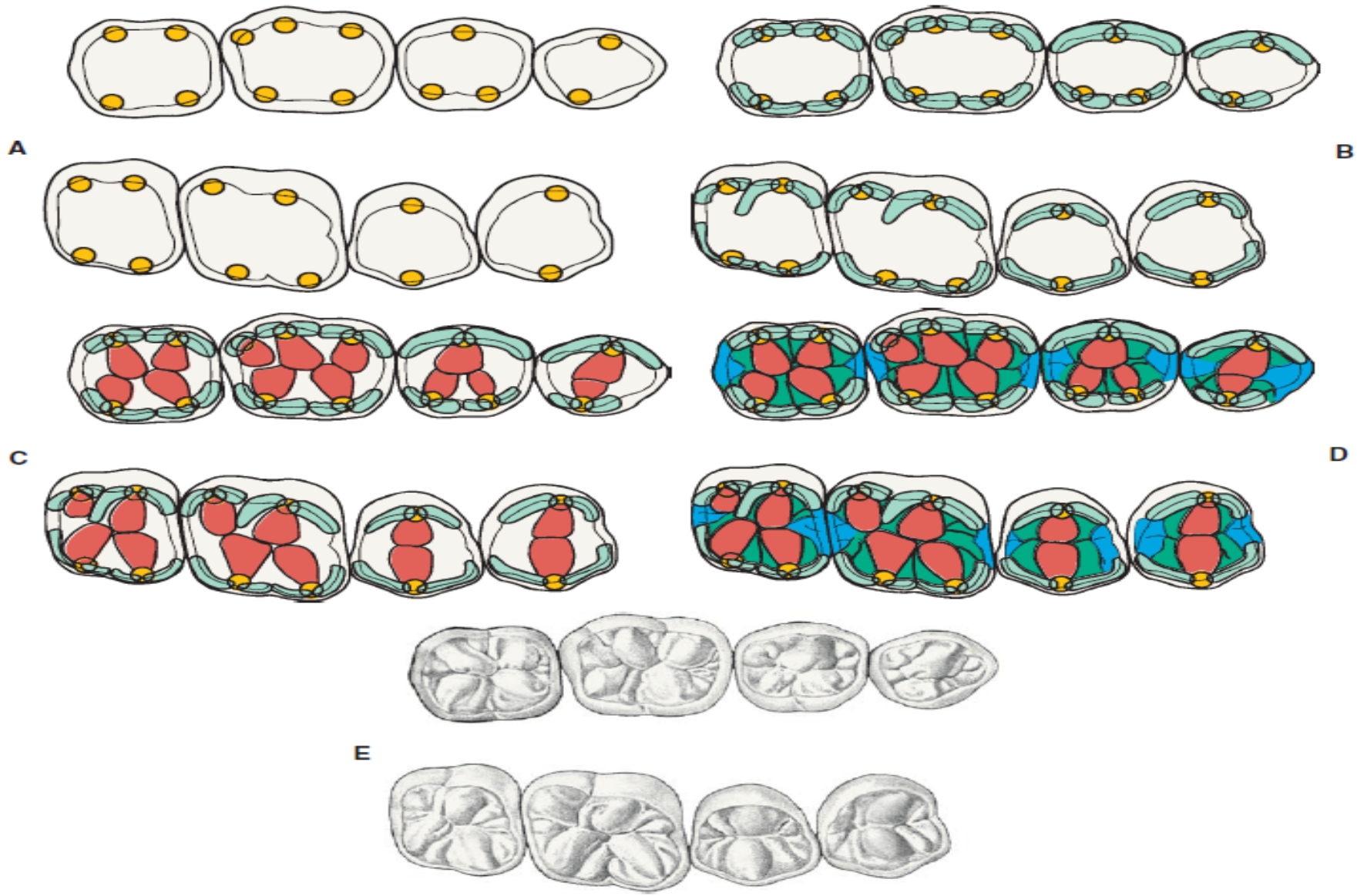

FIGURE 18-31 ■ Sequence of occlusal wax addition. **A,** Step 1: placement of cones. **B,** Step 2: superimposition of cuspal ridges. **C,** Step 3: placement of cones, cuspal ridges, and triangular ridges. **D,** Step 4: placement of cones, cuspal ridges, triangular ridges, and secondary and marginal ridges. **E,** Step 5: finished occlusal waxing.

Check if there is interference with the opposing.



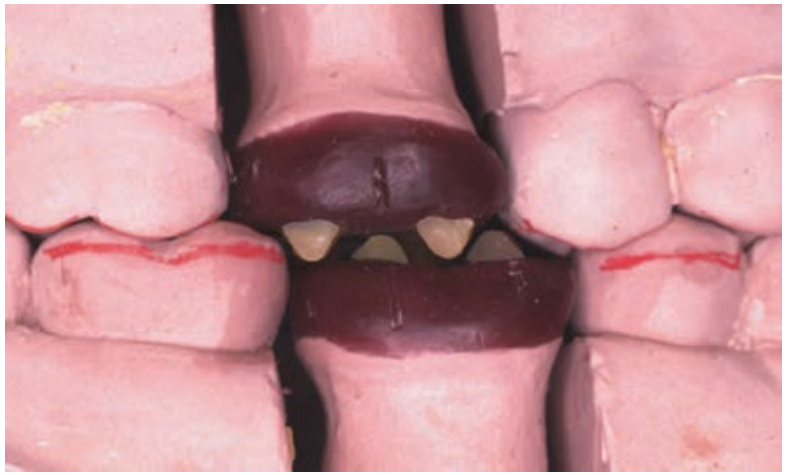

Evaluating the completed wax patterns.



Margin finishing:

Lift of the pattern, replace it and check for defects:

1-Overwaxed margin:

This may lead to breaking off when a pattern is withdrawn from the die.

2-Short margin:

The waxing does not extend to the red finish line will not provide an adequate seal for the final restoration.

3-Ripples:

Any roughness in the wax near from the margin will be duplicated in the casting. These roughness's in the final restoration lead to plaque collections that lead to irritation and inflammation of the adjacent gingival tissue.

4-Thick margin: Thick, round margin will result in poor sealing of the restoration and poor axial contours lead to periodontal problems. The margin should be fabricated with the fine edge.

5.Open margin:

It may be occurred during any stages of fabrication the wax pattern. The margin must be remelted to insure close adaptation on the finish line. After complete all these procedures the wax pattern smoothing with a cotton roll dipped in die lubricant.