Ashur University College
Crown and Bridge
2nd year Prosthodontics
Technology dept.
Lect 8 &9

Dr. Mohammed Moudhaffer M Ali

Mounting

It is the procedure of attaching the maxillary and mandibular casts to the articulator in their recorded jaw relation. It is also called ***articulation***.

The maxillary cast is first articulated, and then the mandibular cast is articulated after recording the vertical and centric jaw relations.

Preparation of articulator:

In mean value articulator (Class II articulator)

1. The articulator should be clean from any remnant of previous plaster.
2. The movable surfaces of the articulator should move freely without any hindrance.
3. The incisal pin should be flushed with the top of upper member of articulator to give zero reading.
4. The mounting table should be properly fixed to the articulator .

Mean value articulator.

for the **class II articulator** we use the mounting table to support the maxillary cast in its accurate position during mounting.

Preparing the cast for mounting: In preparing casts for mounting on articulator it is necessary to perform several initial checks:

1. Inspect the occlusal surface of the teeth in both the working and opposing the casts. Carefully remove all nodules or bubbles of stone so that there is no interference **with the tooth –to- tooth contact**.







nodule on cast



clean cast

2. If there are broken or chipped **working cusps** on the Buccal surface of the mandibular cast or lingual surface of the maxillary cast considers obtaining new cast.

3. Inspect thoroughly the surface of the teeth or the land areas of the cast for any interference with occlusion.



Poorly trimmed casts cannot be properly related as

the heels at the back of the casts get in the way.

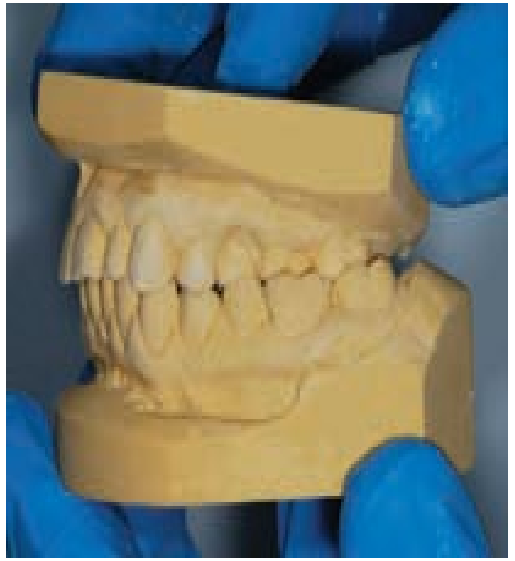

proper trimming and contacts.

4. Trim the casts to the desired thickness in relation to the articulator.

5 .Position the cast between the upper and lower member of the articulator.

6 . If a face- bow is available make certain that the model will fit in the face bow without touching mounting plate.

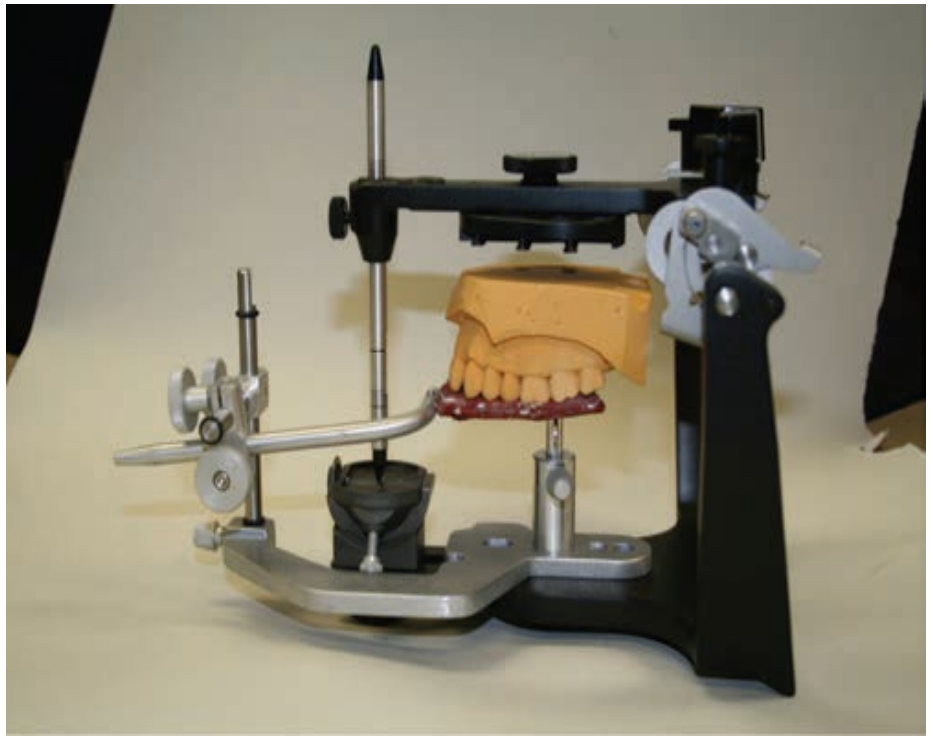

Mounting the maxillary cast

The maxillary cast is first attached to the upper member of the articulator after orientation jaw relation by using the face-bow with adjustable type of articulators, while for the mean value articulator use the mounting table to support the maxillary cast in its position during mounting. The mandibular cast is articulated after recording the vertical and centric jaw relations.

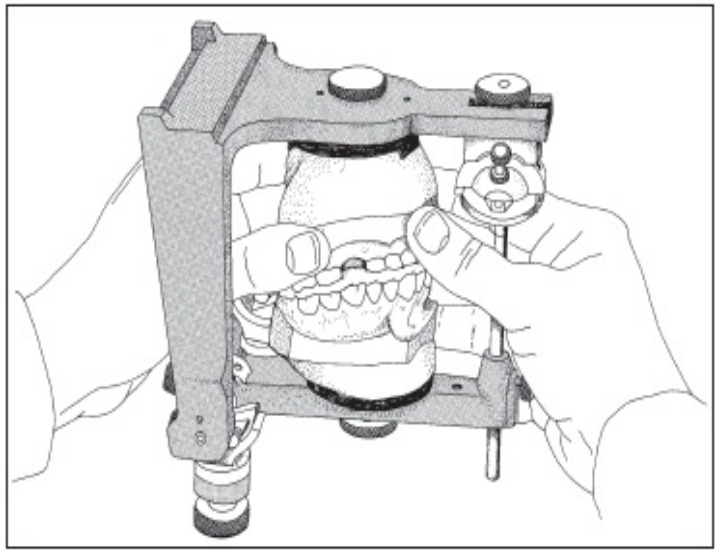

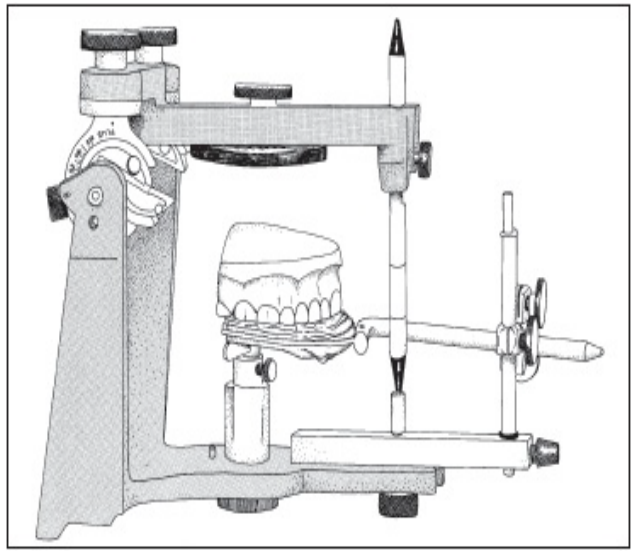



Mounting the mandibular casts:

1. The mandibular cast is mounted after recording vertical and centric jaw relations.
2. sealing should be done between the maxillary and mandibular casts after making centric jaw relation.
3. Care should be taken that there is no posterior interference between the maxillary and mandibular casts ***(Heel area)***.
4. The articulator with the mounted maxillary cast is inverted to aid in the mounting the mandibular cast.
5. The plaster is mixed and poured over the base of the mandibular cast and the articulator is closed until the incisal table touch the incisal pin, then the plaster should be smoothed and polished.

Steps of mounting cast on articulator

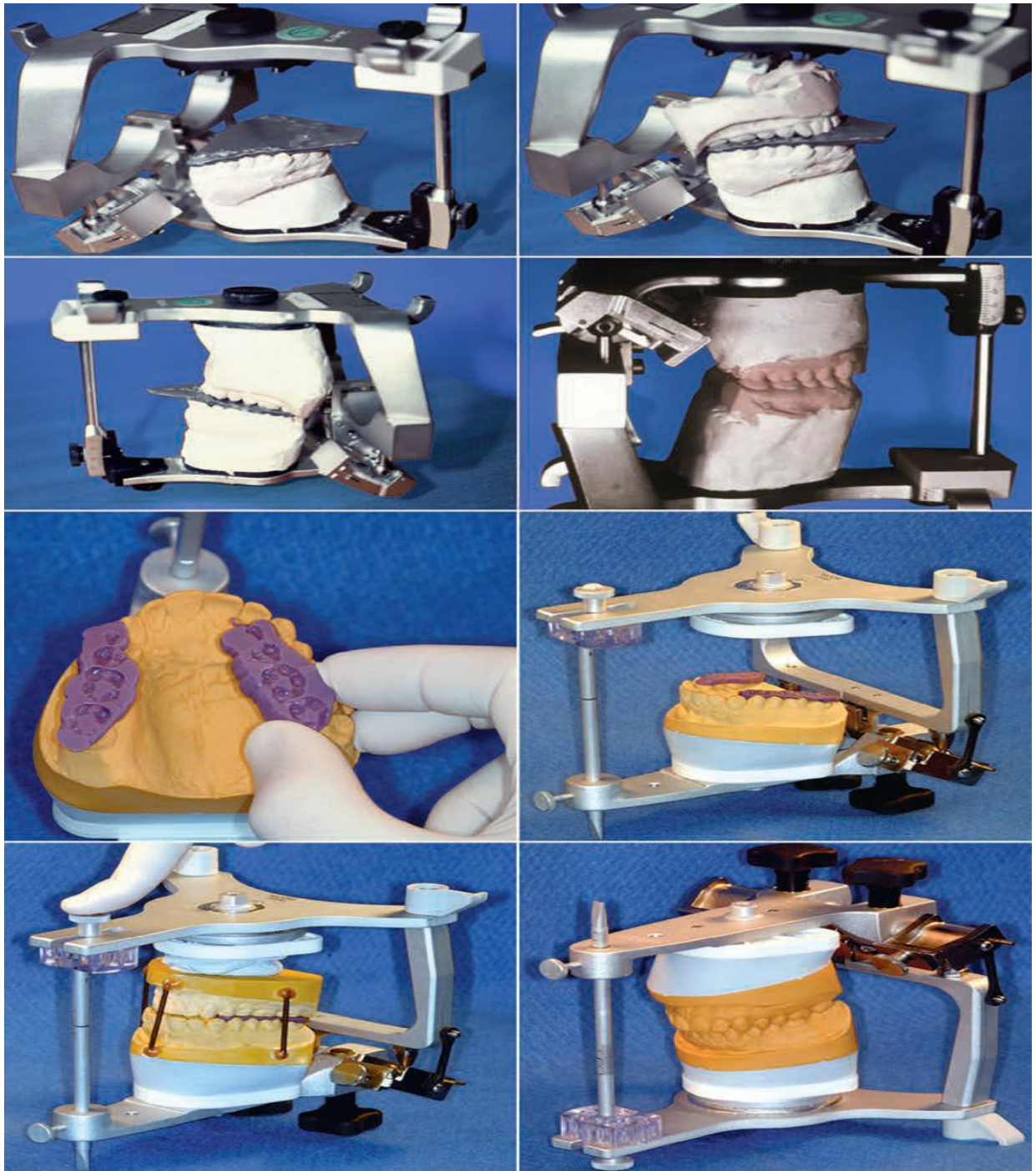

The articulated casts are inspected for the following criteria:

1. The condyle is in the retruded position in its condylar track mechanism.
2. Both casts are seated completely in the interocclusal wax record.
3. Mounting stone is securely attached to both casts and mounting plates.

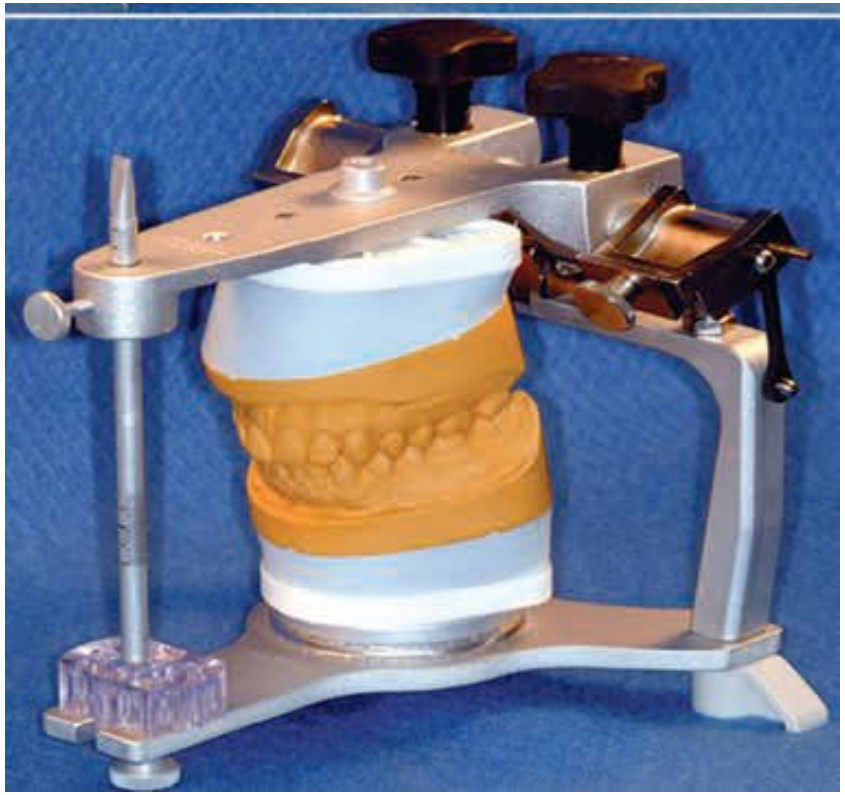

Errors occurred during mounting:

1. The inter occlusal record is not properly secured to the cast.
2. Interference of the casts posteriorly.
3. The incisal pin is not properly screwed.
4. The incisal pin not touching the incisal table.
5. Wrong transference of the midline of the articulator with that of the casts (shifting of the midline).
6. Movement of the casts during mounting.
7. Upper and lower casts are not properly fixed for orientation.
8. Dimensional changes in the plaster.
9. Face-bow record defected.

Methods of finish line exposer and die trimming

The finishing line must be exposed completely (when it is sub gingivally in order to ensure the reproduction) of the line in the working cast.

Tissue displacement is commonly needed to obtain adequate access to the prepared tooth and to expose all necessary surfaces, both prepared and not prepared.

This can be achieved by mechanical, chemical (chemo-mechanical), or surgical means.

Objectives of gingival retraction:

1. To create an access for the impression material to the area of the preparation that is located subgingivally.

2. To provide enough thickness of the impression material at the area of the

finishing line to prevent tearing and distortion of the impression material.

3. To control the amount of fluid in the gingival sulcus (crevicular fluid) that will cause voids in the impression.

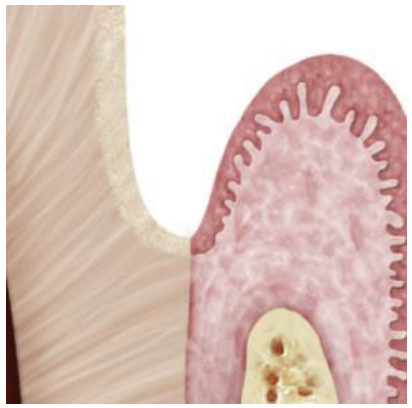

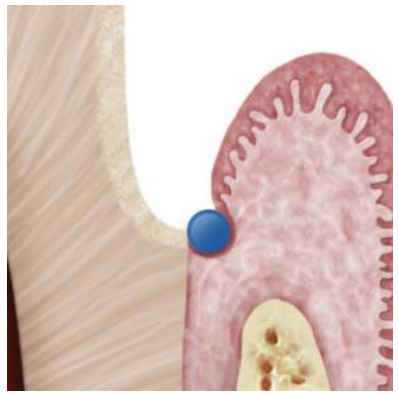



1. Mechanical method

a. Copper tube / using the copper tube to expose the finish line and make the impression in the same time.

b. Using of a temporary crown with a slightly long margin leaving it in place for 24 hours,

c. Rubber dam a sheet of thin latex rubber used by dentists to isolate a tooth or teeth from the fluids of the mouth during dental treatment, held in place by a clamp and frame.

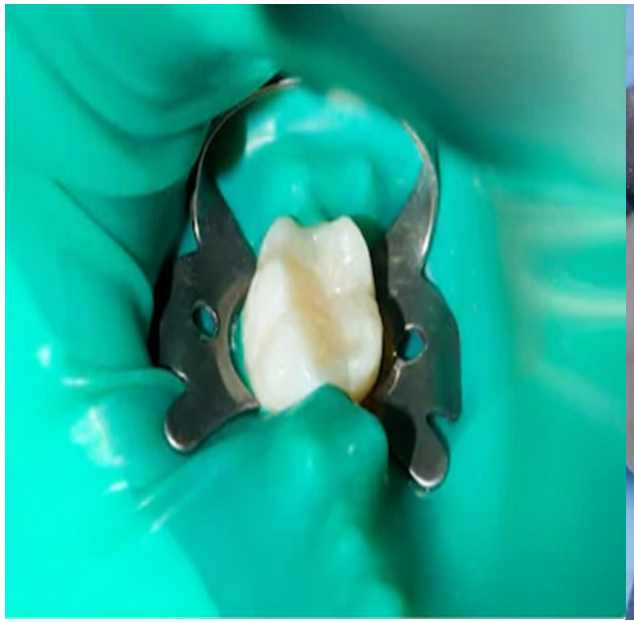



Temporary crown for gingival retraction.







2. Chemo-mechanical retraction cord and hemostatic agent.

a. Hemorrhage Control with an Infuser Syringe

Special instrument called dento infuser is used to apply 15% or 20% ferric sulfate $Fe_2(SO_4)_3$ solution in the sulcus area , done with burnishing action , the cord is soaked with the same solution and packed into the sulcus.







b. Displacement Pastes

Some dentists advocate displacement paste. It is an aluminum chloride–containing paste used for gingival displacement. The material is dispensed from a syringe directly into the sulcus.





c. The volumetric expansion pastes.

Expanding polymeric foam provides tissue displacement with minimal discomfort or gingival trauma. Hemorrhage control with ferric sulfate can be used if bleeding is noted .The expanding polymeric foam is injected around the preparation and condensed with a special hollow cotton roll .The patient closes on the cotton roll, maintaining pressure for 5 minutes before impression making.





Surgical method

a. Rotary curettage (gingitage) used with sub gingival finish line by removing limited amount of epithelial tissue while preparing the finishing line on the tooth.



b. Electrosurgery

An electro-surgery may be used for minor tissue removal before impression making. In one technique, the inner epithelial lining of the gingival sulcus is removed, which thus improves access for a subgingival crown margin and

helps effectively control postsurgical hemorrhage (provided that the tissues are not inflamed). Unfortunately, there is the potential for gingival tissue recession after treatment.






c. Soft Tissue Laser

Soft tissue lasers have been introduced into dentistry and can provide an excellent adjunct for tissue management before impression making and they are also useful for tissue contouring procedures.







Advantages of laser:

1. Sterilizes sulcus.
2. Reduced tissue shrinkage.
3. Excellent hemostasis and faster wound healing.
4. Relatively painless.

Disadvantages:

1. Slow technique.
2. Expensive.

d. Radiosurgery

Radiosurgery is a technique that provides cutting and/or coagulation from radio waves. An advantage over electrosurgery is that minimal lateral heat is generated. Different Wave forms are used for tissue removal or coagulation.

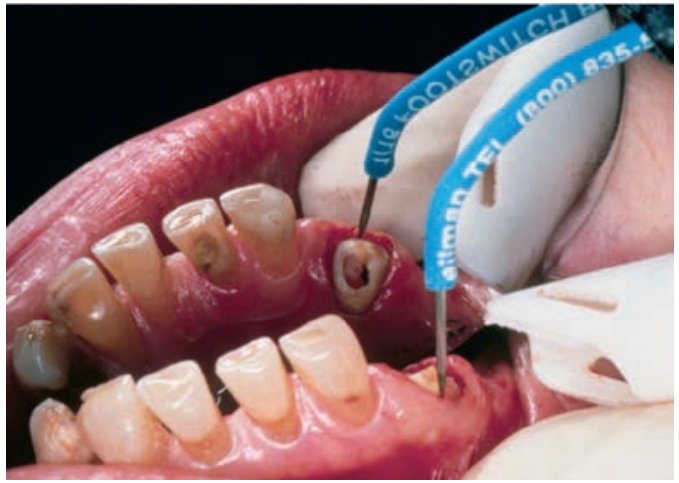



Die trimming

Remove most of excess stone with Arbor band.

- Use a pear-shaped acrylic bur to trim the die apical to the finish line of the preparation.
- Then fine trimming and smoothening with scalpel.

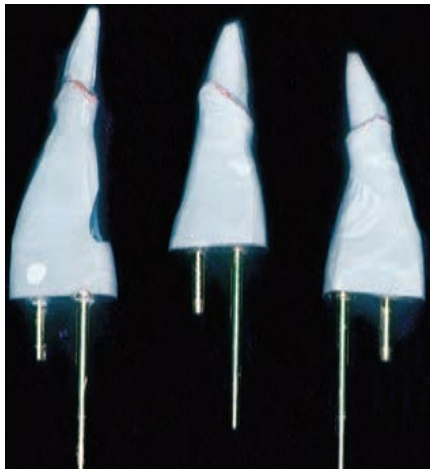




Die trimming helps to provide clear margin preparation, and is essential in providing accuracy of fit for crowns or other types of restorations. It also ensure properly sealed margin.

Ditching: before waxing, we should do ditching, which is the trimming of the stone that represents the gingiva around the prepared tooth in order to expose our finishing line which is located sub gingivally or with the level of the gum. It is done by using a sharp hand instrument(sharp knife).





Advantages of die trimming:

- Accentuate the finish line
- Resembling the normal contour of the natural root for proper cervical contouring of the wax pattern.
- Produce smooth area gingival to the finish line.

The original contour of the tooth structure below the margin must be preserved. Over trimming (dotted line) will result in over contoured restoration.

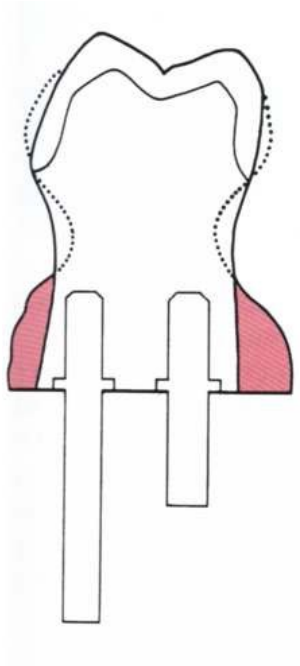

Marking the Margins

The technician’s awareness of the precise location of the preparation margin is crucial. By marking it with the side of a colored pencil tip, the technician can pinpoint this location .The color should contrast with that of the wax that will be used (e.g., a red pencil can be used for green wax). An ordinary lead pencil is not recommended because it can abrade the die, its darker color can interfere with efforts to verify that the wax has been properly adapted at the margin, and traces of the graphite (an antiflux) can prevent complete casting of the margins.





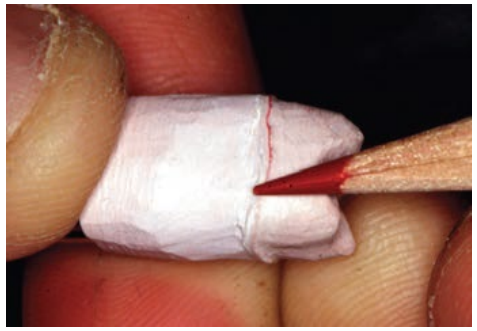

Die spacer application , die spacer is an agent used to provide space for the cement used to fix the crown it is applied in more than one layer it should be applied 0.5- 1mm away from the margin. The material is available in contrasting colors to facilitate applying the required number of coats.





