TEMPOROMANDIBULAR DISORDERS (TMDs)

TMD is often a combination of etiologies rather than a single anatomical or functional disharmony. Combination of etiologies often complicates successful treatment and can frustrate the clinician and patient. There is no strong evidence to suggest that TMDs are either associated with malocclusions or cured by orthodontic therapy. Most TMDs fall into one of two broad categories: muscle pain (Myogenic), which is the most common, or intra-capsular (Arthrogenic) disorders. Despite the involvement of various factors, certain etiologic factors such as the **occlusal condition, trauma, emotional stress, and parafunctional activity** (e.g. bruxism and clenching) have gained significant research support.

Occlusal Condition

There appears to be two ways the occlusal relationship of the teeth may be associated with TMD symptoms. The first is related to an acute change in the occlusal condition, for example: a situation when a crown or filling is placed and it is left a little high; afterward, the patient reports back to the clinic complaining of discomfort. Frequently this discomfort is not only around the sore tooth, but there also is muscle tightness and pain because the muscles protectively co-contract to minimize any damage. Muscle co-contraction refers to the simultaneous activation of muscles on opposite sides of a joint to maintain joint stability. The second is related to loading of the masticatory structures in the *absence of TMJ stability* **(**Orthopedic Instability). Every mobile joint is designed to be loaded, and this loading comes from the muscles that pull across the joint. Therefore, every joint has a musculo-skeletally stable position, and in the TMJ this is defined as the condyles resting on the articular eminences with the disks correctly positioned between those articulating surfaces. Orthopedic stability in the masticatory system is present when the teeth are in their stable biting position at the same time the joints are in their stable position. When this is present, joints and teeth can be loaded without injury or consequence. However, when the stable joint position is not in harmony with the stable occlusal position, the condition is considered orthopedically unstable. Hence, continued loading of the teeth by

activities such as heavy biting, chewing or bruxism can result in changes in the joint structures, e.g. fibrous connective tissue breakdown, bony degeneration, clicking, locking, and pain.

Trauma

A sudden blow to the face can immediately change the structures of the joint; this represents macrotrauma. However, microtrauma can also be an issue whereby small but repeated traumas can occur to the joints. The orthopedic instability coupled with loading (previously mentioned) is an example of microtrauma.

Emotional Stress

There is ample evidence that increased levels of emotional stress can be an etiologic factor associated with TMDs. If the stress is prolonged the muscles of mastication may show signs of fatigue, tightness, and pain. Prolonged stressors can result in an increase or upregulation of the autonomic nervous system. When this occurs, the central nervous system can play an active role in maintaining the pain condition, making management more difficult.

Parafunctional Activity

Bruxing and clenching of the teeth can produce pain. Patients who report that they wake up in the morning with painful muscle are certainly likely to be experiencing sleep related bruxism. However, there are other patients who report no pain upon awakening but instead their pain is in the late afternoons or evening. These individuals may be experiencing daytime clenching, or they may have a completely different etiologic basis for their myogenous pain.

It is very important to remember the fact that more than one of the abovementioned factors may be involved at any given time, which is often the case. Furthermore, we need to recognize the fact that all individuals are different in their capacity to adapt to less than ideal circumstances. Many people may have less than perfect occlusion, have received

some trauma, have some emotional stress, and have some parafunction, and yet they do not develop TMD symptoms. This is likely due to their capacity for adaptability, which is an important clinical consideration since it helps us understand the great variability of patient responses.

TMD from an Orthodontic Perspective

There is consensus that orthodontic treatment cannot be reliably shown to either "cause" or "cure" TMDs. The question that really needs to be asked is how can orthodontic therapy be used to minimize any risk factors that may relate to TMD? In reviewing the known etiologies of TMD, orthodontic therapy routinely affects only one of those factors: the occlusion. Since occlusal factors may be a potential source of TMD in some patients, it would seem logical that the orthodontist should develop an occlusion condition that will minimize any risk factors that might be associated with TMD. However, developing a sound occlusal relationship does not mean the patient will not develop TMD, because there are other etiologies that are outside the control of the orthodontist. It seems logical that since orthodontic therapy will change the patient's occlusal relationships, emphasis should be placed on creating an occlusion condition that will provide the best opportunity for successful masticatory function for the lifetime of the patient; hence, minimizing a dental risk factor.

Patient Evaluation for TMD

Because TMD symptoms are common, it is recommended that every orthodontic patient be screened for these problems, regardless of the apparent need or lack of need for treatment. Because orthodontic therapy will likely influence the patient's occlusal condition, it is important to identify any dysfunction in the masticatory system before therapy is ever begun. Knowing the functional condition of the masticatory system in advance helps prepare the patient and the orthodontist to what can be expected after the therapy has been completed. This information also helps develop the most appropriate treatment plan that will minimize dysfunction in future years. Nothing is more disheartening to the orthodontist than to be in the middle of orthodontic therapy and have

the patient report that a pre-existing TMD symptom was a result of the orthodontic therapy.

TMD Screen History

The screening history consists of several questions that will help alert the orthodontist to any TMD symptoms. These can be asked personally by the clinician or may be included in the general health and dental questionnaire that the patient completes before developing the treatment plan. The following questions are recommended to identify functional disturbances:

- In the last 30 days, how long did any pain last in your jaw or temple area on either side?

a. No pain

b. Pain comes and goes

c. Pain is always present

- In the last 30 days, have you had pain or stiffness in your jaw on awakening?

a. No

b. Yes

- In the last 30 days, did the following activities change any pain (that is, make it better or make it worse) in your jaw or temple area or either side?

A- Chewing hard or tough food

B- Opening your mouth or moving your jaw forward or to the side

C- Jaw habits such as holding teeth together, clenching, grinding, or chewing gum

D- Other jaw activities such as talking or yawning

If a patient report positively to 3 or more of these questions, the clinician should request additional information to clarify the condition.

TMD Screen Examination

It begins with an inspection of the face for any facial symmetry. The screening examination should include the palpation of facial muscle and the TMJs as well as observations of jaw movement. Several important muscles of the masticatory system can be palpated for pain or tenderness during the screening examination. The temporalis (Fig. 1) and masseter muscles (Fig. 2) are palpated bilaterally. Palpation of the muscle is

accomplished mainly by the palmar surface of the middle finger, with the index and ring fingers testing the adjacent areas; the degree of discomfort is ascertained and recorded.

Pain or tenderness of the TMJs is determined by digital palpation of the joints when the mandible is both stationary and during dynamic movement. The fingertips are placed over the lateral aspects of both joint areas simultaneously (Fig. 3), and the patient is asked to report any symptoms. Once the symptoms are recorded in a static position, the patient opens and closes, and any symptoms associated with this movement are recorded. Joint sounds are recorded as either clicks or crepitation. A click is a single sound of short duration. Crepitation is a multiple, gravel-like sound described as "grating" and "complicated." Crepitation is most commonly associated with osteoarthritic changes of the articular surfaces of the joint.

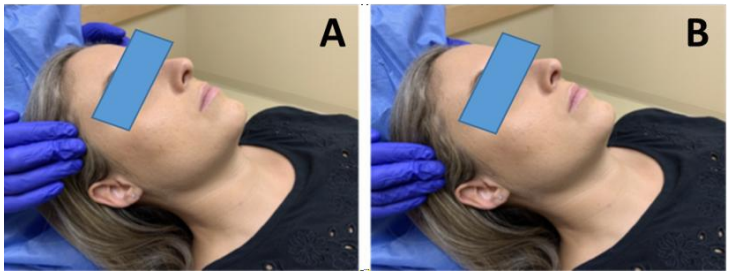

Fig. 1: A, Palpation of the anterior portion of the temporalis muscle. B, Palpation of the posterior portion of the temporalis muscle.

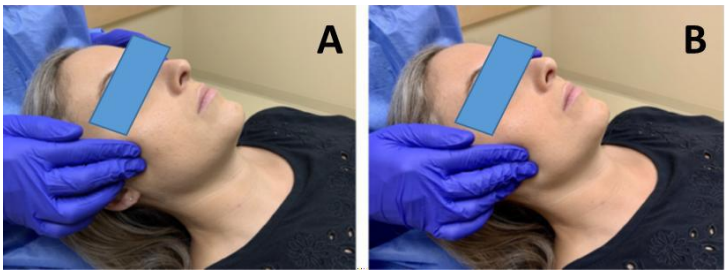

Fig. 2: A, Palpation of the masseter muscle at the superior attachment to the zygomatic arch. B, Palpation of the masseter muscle at its attachment of the lower border of the mandible.

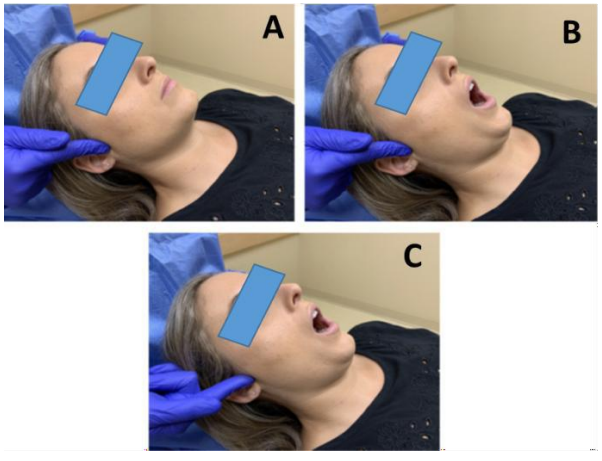

Fig. 3: A, Palpation of the TMJ in the closed-mouth position. B, Palpation of the TMJ in the opened-mouth position. C, Palpation of the TMJ with the mouth fully open. The finger is moved behind the condyle to palpate the posterior aspect of the joint.

Patients with TMD signs and symptoms may be seen and managed at three stages:

1- TMD signs and symptoms may be present before the onset of orthodontic treatment.

2- TMD signs and symptoms may arise during orthodontic treatment.

3- A completed patient may develop TMD after orthodontic treatment.

The orthodontist must be prepared to deal with each type of those patients. Table 1 shows a protocol summary for the management of TMD signs and symptoms within an orthodontic practice.

Table 1: Management of TMD signs and symptoms within an orthodontic practice.

At time of presentation	1. If patient has signs and symptoms of TMD, then the patient should be informed that orthodontic treatment will not resolve those problems
	2. Current TMD signs and symptoms should be noted, and a full TMD history and clinical examination should be undertaken and recorded
	3. If the existing TMD is acute and severe, the commencement of orthodontic treatment should be *postponed* until the condition is either resolved or stabilized
During treatment	1. Acknowledge and recognize the signs and symptoms of TMD
	2. Reassure and educate the patient that TMD is not necessarily a progressive problem and in most cases symptoms will improve over time with conservative treatment
	3. Active orthodontic treatment should be *discontinued,* and TMD signs and symptoms should be managed by either the orthodontist or an expert TMD colleague
	4. Once signs and symptoms have been alleviated or controlled, active orthodontic treatment may be resumed with consideration to modification of treatment (reduction of forces on headgear, remove or lighten elastics, use of oral TMD treatment appliance)
After treatment	The patient should be *monitored* for signs and symptoms throughout the retention period. If symptoms arise, appropriate management should be provided

Good Luck