Occlusion

Occlusion Concepts and Definitions

The scope of the subject of occlusion relative to dentistry includes the relationship between all the components of the masticatory system in normal function, dysfunction, and parafunction. This includes the morphological and functional features of contacting surfaces of opposing teeth and restorations, occlusal trauma and dysfunction, neuromuscular physiology, the temporomandibular joints and muscle function, swallowing and mastication, psychophysiological status, the diagnosis, prevention and treatment of functional disorders of the masticatory system. The following terms and concepts are universally accepted and considered "gold standards" when discussing, diagnosing, and managing the human dentition and occlusion, and also when discussing the static and functional anatomy and biomechanics of the masticatory system.

Centric Occlusion (Maximum Intercuspation, Habitual Occlusion, Intercuspal Position): The position of the mandible when the relationship of opposing occlusal surfaces provides maximum planned contact and/or intercuspation. This is a *tooth-determined position.*

Centric Relation (CR): The relationship of the mandible to the maxillae when the mandibular condyles are in their most superior position, with the central bearing area of the articular discs in contact with the articular surface of the condyles and with the articular eminentia. Importantly, the condyles may or may not be in their most retruded position, depending on the degree of restraint provided by the TM ligament. This position is independent of tooth contact and is determined by the structural features of the TMJ and not the dentition.

Centric Relation Occlusion (Retruded Contact Position): Is defined as the occlusion of the teeth when the mandible is in centric relation. This is a *tooth-joint determined position.*

Ideal Occlusion: A preconceived theoretical concept of occlusal structural and functional relationships that includes idealized principles and characteristics that an occlusion should have. It does not represent the "norm" and is used as a series of idealized parameters against which variations may be compared.

Physiologic (Normal) Occlusion: Usually in adults, it is an occlusion that deviates in one or more ways from the theoretically ideal, yet is well adapted to that particular environment, is esthetically pleasing to the patient, and has no pathological manifestations or dysfunctional problems. It does not require intervention.

Non-physiologic Occlusion: An occlusion which presents with signs or symptoms of pathology, dysfunction, or inadequate adaptation of one or more components of the masticatory system that can be attributed to faulty structural relationships or mandibular functional activity. Therapy to improve the malocclusion may be indicated.

Therapeutic Occlusion: An occlusion that has been modified by appropriate therapeutic modalities in order to change a non-physiologic occlusion to one that falls within the parameters of a physiologic occlusion, if not a theoretically ideal occlusion. This occlusion optimizes the health and adaptive potential of the masticatory system.

Malocclusion: Any occlusion in which the structural characteristics are beyond those established for a theoretically ideal occlusion. The term does not necessarily imply that such an occlusion is non-physiologic or that therapy is indicated. The presence of a malocclusion, particularly in adults, does not mean that therapy is necessary, and the malocclusion may be physiologic.

The Occlusion from an Orthodontic Perspective

The term occlusion has both static and dynamic aspects. Static refers to the form, alignment and articulation of teeth within and between dental arches and the relationship of teeth to their supporting structures. Dynamic refers to the function of the stomatognathic system as a whole comprising teeth, supporting structures, TMJ, neuromuscular and nutritive systems. Orthodontics is the specialty of dentistry concerned

with the management and treatment of malocclusion. In the majority of cases, a malocclusion does not in itself represent a disease state, but rather a variation from what is considered ideal. It is therefore important for the orthodontist to have a clear definition of what is meant by an ideal occlusion, as this will form a basis for diagnosis and treatment planning.

Angle's classification of malocclusion in the 1890s was an important step in the development of orthodontics because it not only subdivided major types of malocclusion but also included the first clear and simple definition of normal occlusion in the natural dentition. Angle's postulate was that the upper first molars were the key to occlusion and that the upper and lower molars should be related so that four classes can be identified:

Angle's "Normal Occlusion": An occlusion in which the mesiobuccal cusp of the maxillary molar occludes in the buccal groove of the mandibular molar and the teeth are arranged along a smoothly curving line of occlusion.

Angle's Class I Malocclusion: An occlusion in which there is a normal relationship of the molars but the line of occlusion is "incorrect" because of malposed teeth, tooth rotations, spacing or other causes.

Angle's Class II Malocclusion: An occlusion in which the mandibular molar is distally positioned relative to the maxillary molar, and the line of occlusion may or may not be correct (unspecified).

Angle's Class III Malocclusion: An occlusion in which the mandibular molar is mesially positioned relative to the maxillary molar, and the line of occlusion may or may not be correct (unspecified).

Almost one hundred years after Angle, Lawrence Andrews redefined the concept of an ideal static occlusion by describing it in terms of six individual keys, including an updated ideal relationship for the first molars. He analyzed 120 'normal' occlusions to evaluate those features which were key to a good occlusion (Box 1).

Box 1: Andrews' six keys of occlusion.

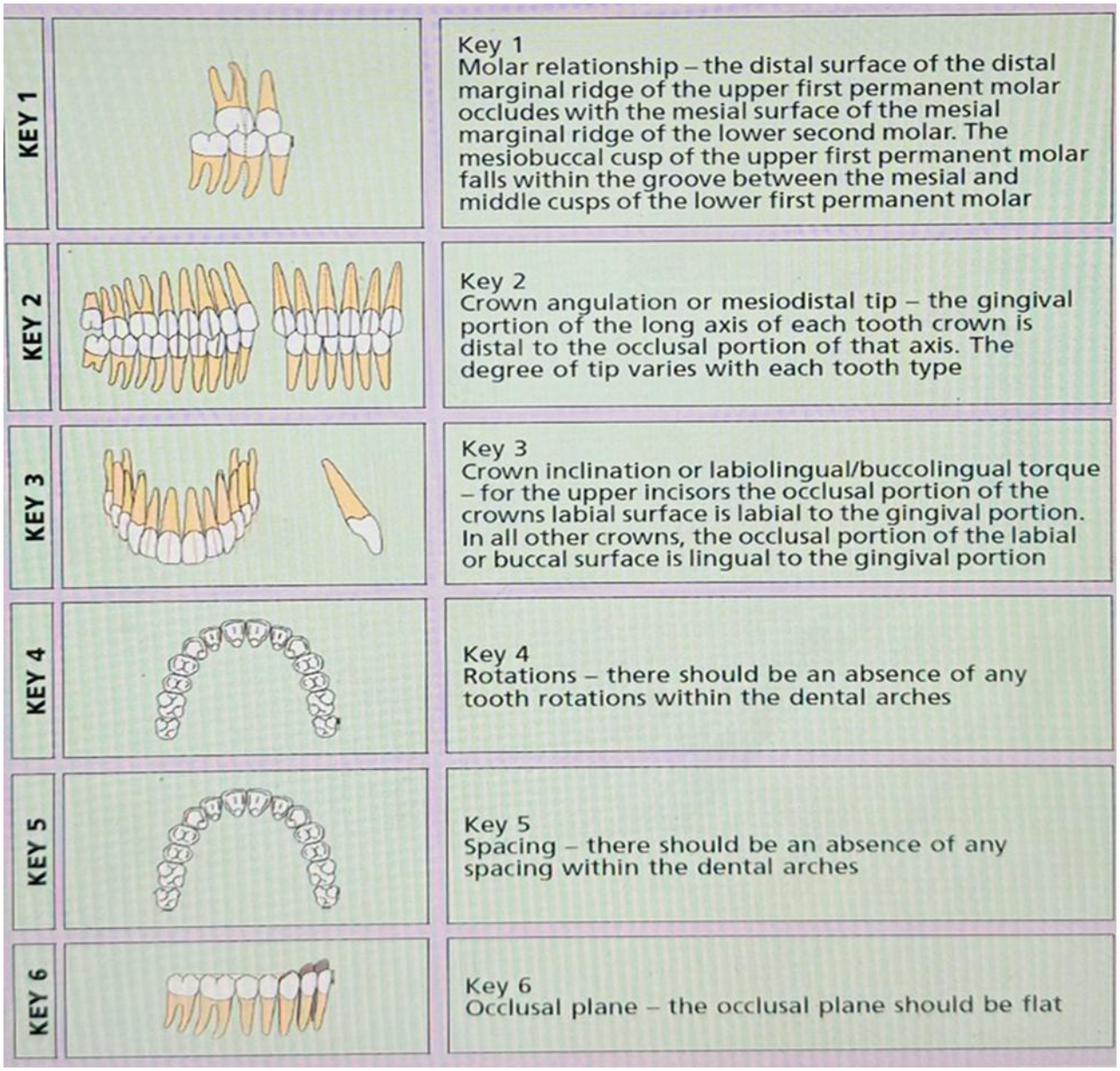

Role of Dentition in Occlusion

Orthodontists have traditionally based their treatment upon the abovementioned static occlusion goals, with little consideration for the dynamics of occlusion or the temporomandibular joints and associated musculature that forms the masticatory system. However, over the past few decades there has been a greater interest in the principles of gnathology and aspects of an occlusion in function. Much has been written about what constitutes an ideal functional occlusion, and an important concept is that of "mutually

protected occlusion", whereby teeth of the anterior and posterior dentitions protect each other in function. Mutual protection is thought to be achieved in the presence of:

• An immediate and permanent posterior disclusion in lateral and protrusive contact with no associated non-working side interferences (tooth contacts); this is achieved by the presence of canine guidance or group function in lateral excursion (Fig. 1), and incisal guidance in protrusion (i.e. the anterior teeth protect the posteriors, Fig. 2). The non-working side interferences are those occlusal contacts present on the non-working side during lateral excursion of the mandible (occur in abnormal, non-mutually protected occlusion).

• Multiple, simultaneous and bilateral contacts of the posterior teeth in the intercuspal position (or centric occlusion) with the incisor teeth slightly out of contact (i.e. the posterior teeth protect the anterior teeth).



Fig. 1: Canine guidance occurs when contact is maintained on the working side canine tooth during lateral excursion of the mandible. Group function occurs when contacts are maintained between several teeth on the working side during lateral excursion of the mandible.



Fig. 2: Incisal guidance in protrusion (the anterior teeth protect the posteriors).

In addition to the importance of molar teeth relationship, the canine relationship also provides a useful anteroposterior occlusal classification:

• Class I – the maxillary permanent canine should occlude directly in the embrasure between mandibular canine and first premolar;

• Class II – the maxillary permanent canine occludes in front of the embrasure between mandibular canine and first premolar; and

• Class III – the maxillary permanent canine occludes behind the embrasure between mandibular canine and first premolar.

Another clinically relevant method of classifying malocclusion is based upon the relationship of the maxillary and mandibular incisors, which is defined upon the relationship of the mandibular incisor tip to the cingulum plateau of the maxillary central incisors (Fig. 3):

Class I – the lower incisor tips occlude or lie below the cingulum plateau of the upper incisors;

• Class II – the lower incisor tips occlude or lie posterior to the cingulum plateau of the upper incisors. This classification is further subdivided into:

• Class II division 1 – the overjet is increased with upright or proclined upper incisors;

• Class II division 2 – the upper incisors are retroclined, with a normal or occasionally increased overjet;

• Class III – the lower incisor tips occlude or lie anterior to the cingulum plateau of the upper incisors.

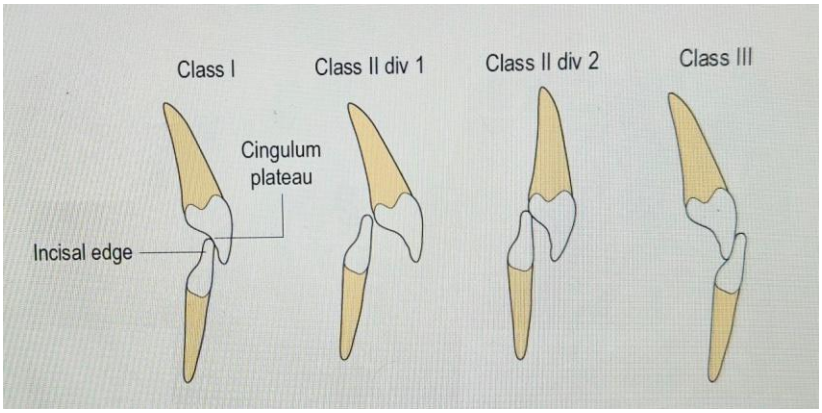

Fig. 3: British Standards Institute incisor classification.

Good Luck