# Orthodontics

## History and Clinical Examination

**Why do we need an orthodontic assessment?**

- ✓ Gather comprehensive patient information to establish an accurate orthodontic diagnosis.
- ✓ Identify and prioritize the patient's orthodontic problems before developing treatment options.
- ✓ Determine which findings require correction, which may be accepted, and which factors may influence treatment outcomes.
- ✓ Assess potential risks and limitations associated with orthodontic treatment.
- ✓ Discuss treatment needs, alternatives, risks, and expected benefits to facilitate informed patient decision-making.

**The elements of the database are:**

1) Taking a full history

2) Undertaking a clinical examination

3) Collecting appropriate records.

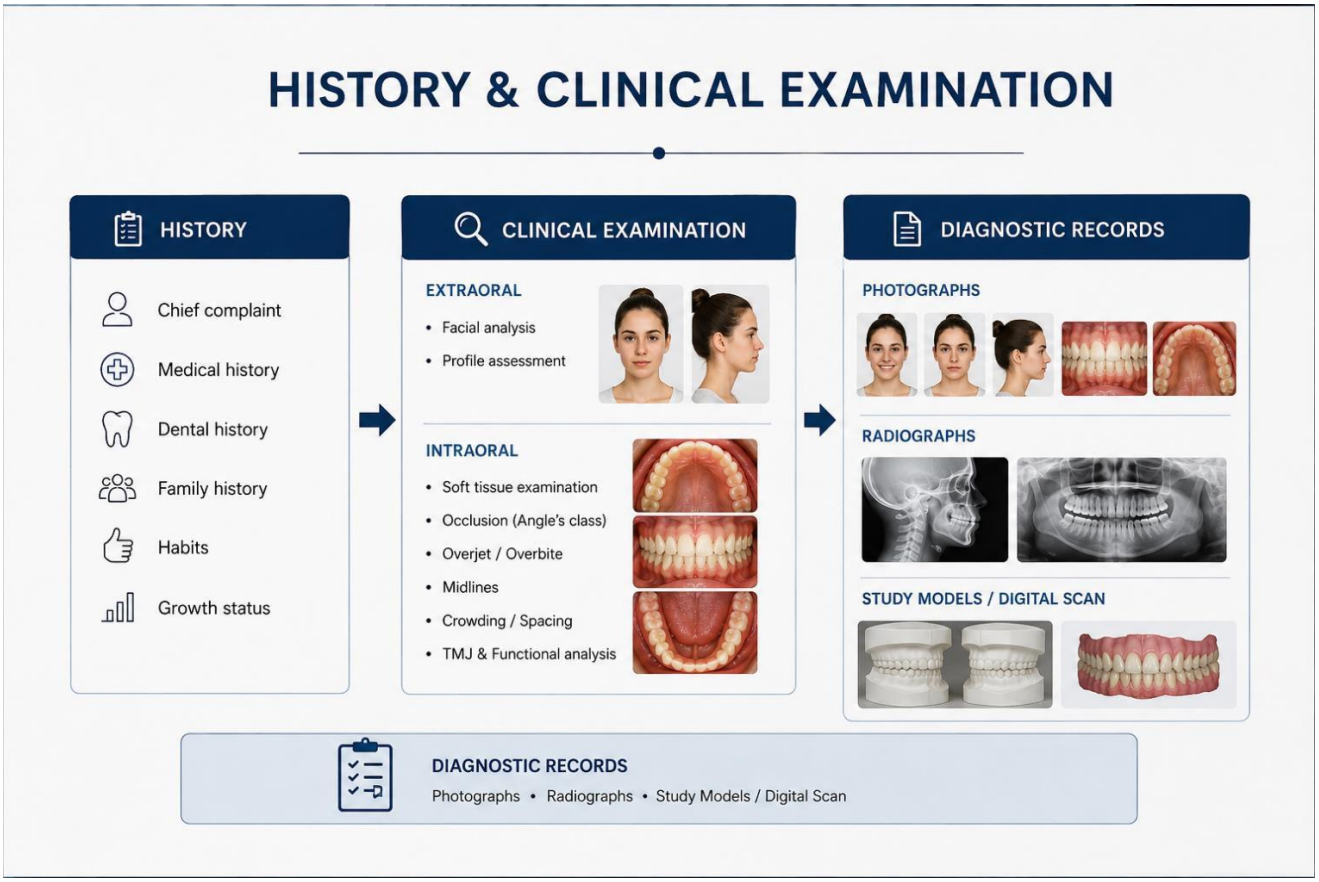

## 1) Taking a full history.

- ✓ Allow the patient to describe their problem in their own words.
- ✓ Clinician guides the patient with specific questions to cover relevant areas.
- ✓ Case history is collected from the patient, parent, or guardian to support diagnosis.
- ✓ Case history includes:

- Personal details
- Chief complaint
- Past history
- Present history

As summarized below:

## 1) Personal details of the patient

## A) Name:

The patients name should be recorded not only for the purpose of communication and identification but because it gives a personal touch to the following conversation. It makes the patients more comfortable when he is addressed by his first name and arouses a feeling of familiarity, which has a positive psychological effect on the patient.

## B) Age and Date of Birth

The age and date of birth of an orthodontic patient are essential pieces of information for several reasons:

1) Treatment Planning: The age of the patient plays a crucial role in determining the appropriate orthodontic treatment plan. Different orthodontic issues may be better addressed at specific stages of dental development. For example, interceptive orthodontics is often more effective for children with developing dental problems, while comprehensive orthodontic treatment may be suitable for older teenagers or adults.

2) Growth and Development: Orthodontic treatment aims to correct malocclusions and alignment issues while taking advantage of the patient's growth and development. The age of the patient can

influence the potential for growth and can impact treatment decisions, particularly in cases where growth modification is required.

3) Treatment Timing: The timing of orthodontic treatment is crucial. Early intervention in some cases can prevent the progression of certain orthodontic problems and avoid more complex treatments in the future. On the other hand, postponing treatment until the jaws have stopped growing may be necessary for some conditions to achieve optimal results.

4) Treatment Duration: The age of the patient can influence the estimated treatment duration. Younger patients, whose jaws and teeth are still developing, may require longer treatment times compared to older patients with fully developed jaws.

5) Eligibility for Certain Treatments: Some orthodontic treatments have age restrictions, and knowing the patient's age helps determine if they are eligible for specific treatment options.

Overall, the age and date of birth of an orthodontic patient are critical pieces of information that help orthodontists provide the most appropriate and effective treatment, taking into account the patient's individual needs, growth stage, and overall oral health.

## C) Gender

Sex of the patient also helps in treatment planning Girls mature earlier than boys, i.e. the timing of growth related events including growth spurts, eruption of teeth and onset of puberty are different in males and females. Facial Aesthetics: Gender differences can play a role in facial aesthetics. Orthodontic treatment aims not only to correct dental alignment but also to enhance the overall facial appearance. Understanding gender-related facial features can help in planning treatment that complements the patient's natural aesthetics. Social and Psychological Considerations: Gender can impact how individuals perceive themselves and how they are perceived by others. For some patients, addressing specific dental or facial features may have a greater impact on their self-esteem or social interactions based on their gender identity.

## D) Address and Occupation

These are important for communication, assessing the socioeconomic status as well as for records. The socioeconomic status might dictate the kind of appliance required. Knowing the patient's occupation and lifestyle can aid in personalizing the treatment plan to suit their specific needs and

demands. For example, a patient with a physically demanding job may require special considerations in their orthodontic treatment to ensure comfort and effectiveness. Also, patients coming from far may require a different appliance therapy as they might not be able to visit the clinician more frequently.

## 2) Patient's perception of the problem (Chief complaint)

The patient should be given the opportunity to express, in their own words, what their problem is and what they would like corrected. They may perceive their problem as:

- Aesthetics
- Functional (speech or mastication difficulties)
- Related to dental health (like a traumatic overbite).

It is important to recognize that the patient's perception of their problem may not always seem appropriate to the trained clinician. However, the patient is unlikely to be satisfied unless their problem is addressed as part of the treatment plan. Allowing the patient to describe their concerns will help to determine whether the patient's expectations are realistic and achievable.

## 3) Medical history

Knowledge of a patient's general health is essential and should be obtained prior to examination. It is best obtained by a questionnaire. In most cases orthodontic treatment can be undertaken but precautions may be required prior to extractions. Antibiotic coverage may be required in patients with cardiac anomalies even for molar band placement/removal, if the adjacent gums are inflamed or bleeding is anticipated. Mentally or physically challenged patients may require special management. For example diabetic patient may be more prone to intra-oral infections and periodontal problems and Treatment should be avoided in poorly controlled diabetics.

## 4) Dental history

The patient should be asked about their previous dental experience. This will provide an idea of their attitude towards dental health, what treatment they have had experienced previously, and how this may affect their compliance with orthodontic treatment. In particular, it is important to determine any ongoing dental problems, history of jaw joint problems, and any history of trauma to the teeth. There may also be a history of relevant inherited disorders affecting the dentition (e.g. hypodontia or enamel defects) and previous orthodontic treatment.

## 5) Habits

The patient should be asked about any previous or ongoing habits that involve the dentition. The most important are digit-sucking habits and the clinician needs to know the duration and nature of the habit. Other habits such as nail biting may predispose to an increased risk of root resorption.

## 6) Physical growth status

For some orthodontic treatment, the patient's growth status is important. In some cases, orthodontic treatment is more successful if they are still growing—for example, when a patient has an underlying skeletal problem that could be improved using a process known as growth modification. In others, treatment planning is best undertaken when growth is complete (e.g. an adolescent with a severe Class III malocclusion). The patient, or their parents, can be asked questions to determine if they are still growing.

## 7) Socio-behavioural factors

Socio-behavioral factors play a crucial role in orthodontic treatment outcomes and patient satisfaction. Understanding these factors is essential for orthodontists to provide comprehensive and patient-centered care. Here are some reasons why socio-behavioral factors are important in orthodontic patients:

1) Treatment Compliance: Socio-behavioral factors, such as a patient's attitude, motivation, and understanding of treatment benefits, can significantly impact their compliance with treatment recommendations. Patients who are committed to the treatment plan and actively participate in their care are more likely to achieve successful outcomes.

2) Oral Hygiene and Habits: Socio-behavioral factors, including oral hygiene practices and habits like smoking or nail-biting, can influence the progress and results of orthodontic treatment. Patients with good oral hygiene habits are less prone to complications, such as tooth decay or gum problems, during treatment.

3) Psychological Well-being: Orthodontic treatment can have a significant impact on a patient's self-esteem and psychological well-being. Understanding a patient's socio-behavioral factors allows orthodontists to address emotional concerns and provide support throughout the treatment process.

## 2) Clinical examination in three dimensions

**GENERAL EXAMINATION**

General examination should begin as soon as the patient first comes to the clinic. A general appraisal of the patient is done. The clinician should observe the gait (how a person walk), posture and physique of the patient. Height and weight are recorded to assess for the physical growth and development of the patient. Abnormal gait may be present due to an underlying neuromuscular disorder. Abnormal posture also may lead to malocclusions.

**Body Build**

Sheldon classified body build into:

a. Ectomorphic: Tall and thin physique.

b. Mesomorphic: Average physique.

c. Endomorphic: Short and obese physique.

The purpose of the clinical examination is to identify pathological and developmental problems and determine which (if any) diagnostic records are required. It is important to remember that the face and dentition should be examined in all three planes (anteroposteriorly, vertically, and transversely).

## A) Extraoral examination

Assessment of the patient should begin with an examination of the facial features because orthodontic treatment can have impact on the soft tissues of the face. Although a number of absolute measurements can be taken, a comprehensive facial assessment involves looking at the balance and harmony between component parts of the face and noting any areas of disharmony. Extraoral examination should start as the patient enters the room and it is important to look at the face and soft tissues when they are in passive and animated states. Once in the dental chair, the patient should be asked to sit and the face examined from the front and in profile, in a position of natural head posture which is the position the patient carries their head naturally. The patient should sit upright in the chair and be asked to focus on something in the distance.

The key to the extra-oral assessment is an understanding of the normal proportions of the face and recognizing when patients deviate from these normal relationships. The patient is assessed extra-orally in the:

• Frontal view (assessing in the vertical and transverse planes)

• Profile view (assessing in the anteroposterior and vertical planes).

An assessment of the smile aesthetics, soft tissues (lips and tongue), and an examination of the temporomandibular joint (TMJ) should also be undertaken.

## 1) Anteroposterior assessment

This aims to assess the relationship between the tooth-bearing portions of the maxilla and mandible to each other, and also their relationships to the cranial base. The anteroposterior relationship can be assessed in the following three ways:

- ✓ Assessing the relationship of the lips to a vertical line, known as the zero meridian, dropped from soft tissue nasion. Zero meridian is the true vertical line dropped from the soft tissue nasion. In a Class I relationship, the upper lip lies on or slightly anterior to this line and the chin point lies slightly behind it (Figure 1).
- ✓ Palpating intra-orally the anterior portion of the maxilla at A point and the mandible at B point (Figure 2). A fair picture of the sagittal skeletal relationship can be obtained clinically by placing the index and middle fingers at the approximate A and B points after lip retraction. Ideally, the maxilla is 2 to 3 mm anterior to the mandible in centric occlusion. In skeletal Class II cases, the index finger is much ahead of the middle finger whereas in Class III the middle finger is ahead of the index finger.
- ✓ Assessing the convexity of the face by determining the angle between the middle and lower thirds of the face in profile (Figure 3). This is assessed by the angle between the upper face (glabella to subnasale) and the lower face (subnasale to pogonion). The mean value is 12° ± 4°. A patient with a convex profile with an increased angle of facial convexity indicating a Class II skeletal pattern. A patient with a straighter profile with a normal angle of facial convexity indicating a Class I skeletal pattern. A patient with a concave profile indicating a Class III skeletal pattern.

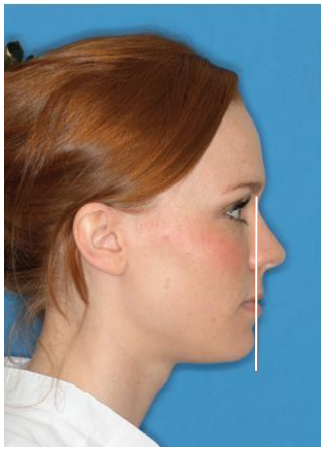

Fig.1: Using zero meridian to estimate anteroposterior relationship.

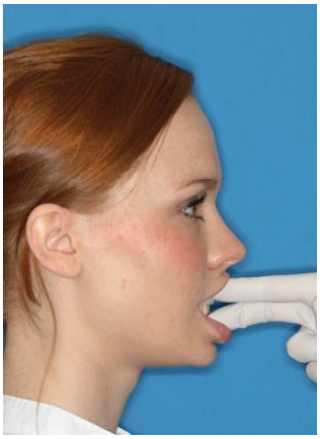

**Figure 2**: Palpating the anterior portion of the maxilla at A point and the mandible at B point to determine the underlying skeletal anteroposterior relationship. In a normal (Class I) skeletal relationship, as shown here, the upper jaw lies 2–4 mm in front of the lower. In a Class II, the `lower jaw would be greater than 4 mm behind the upper jaw. In a Class III, the lower jaw is less than 2 mm behind the upper (in more severe Class III cases, the lower jaw may be in front of the upper).



(a) (b) (c)

**Figure 3:** The anteroposterior relationship of the jaws can also be assessed using the convexity of the face.

## 2) Vertical assessment

The face can be assessed vertically in two ways:

- Using the rule of thirds.

The face can be split into thirds (Figure 4). In a face with normal proportions, each third is approximately equal in size. Any discrepancy in these thirds may suggest a facial disharmony in the vertical plane. In particular, orthodontists are interested in any increase or decrease in the proportion of the lower third of the face. The lower third of the face can also be split into thirds, with the upper lip lying in the upper third, and the lower lip lying in the lower two-thirds.



**Figure 4:** The face can be divided into equal thirds: hairline to glabella between the eyebrows (forehead), glabella to subnasale (middle third), and subnasale to lowest part of the chin (lower third). The lower third can be further divided into the thirds, with the upper lip lying in the upper third and the lower lip lying at the top of the lower two-thirds

- Measuring the angle of the lower border of the mandible to the maxilla.

Another clinical assessment that can be used to determine the vertical relationships is to assess the angle between the lower border of the mandible and the maxilla (Figure. 5). Placing a finger, or the handle of a dental instrument, along the lower border of the mandible gives an indication of the clinical mandibular plane angle.

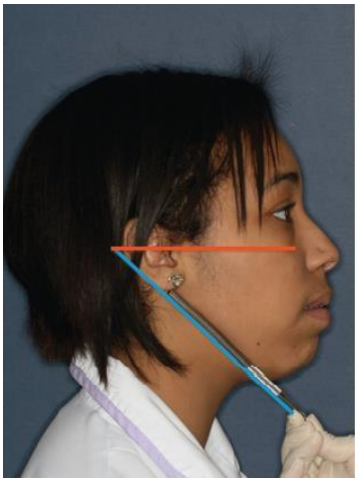

**Figure 5:** The mandibular plane angle can be estimated clinically by looking at the point of contact of intersecting lines made up by the lower border of the mandible (in blue) and the Frankfort horizontal plane (in red). The Frankfort plane is actually measured on a lateral cephalogram (between porion and orbital), but can be estimated clinically by palpation of the lower border of the orbit. The angle is considered normal if the two lines intersect at the occiput. In this case, the lines intersect anterior to the occiput, which is consistent with an increased angle, suggesting increased vertical proportions. If the lines intersect posterior to the occiput, then the angle would be decreased, indicating reduced vertical proportions.

## 3) Transverse assessment

The transverse proportions of the face can be examined from the frontal view, but also by looking down on the face, by standing behind and above the patient (Figure 6). No face is truly symmetrical, but any significant asymmetry should be noted. The soft tissue nasion, middle part of the upper lip at the vermillion border, and the chin point should all be aligned. The face can also be divided into fifths, with each section being approximately equal to the width of an eye (Figure 7). Gross facial asymmetries may be seen in patients with i. Hemifacial hypertrophy/atrophy ii. Congenital defects iii. Unilateral condylar hyperplasia. iv. Unilateral Ankylosis.




**Figure 6:** The transverse examination of the face should be done from the front, and from above the patient (by standing behind and above the patient while they are seated in the dental chair). (a) The patient has a symmetrical face, with the facial midline showing alignment of the soft tissue nasion, middle part of the upper lip at the vermillion border, and the chin point. (b) The same patient viewed from behind, confirming the symmetry. (c, d) A patient with marked mandibular asymmetry to the right.



**Figure 7**: In a face with normal transverse proportions, the face can divided into approximately five equal sections—each the width of an eye.

## 4) Smile aesthetics

Most patients seek orthodontic treatment to improve their smile, so it is important to recognize the various components of a smile that will improve the aesthetics.

A normal smile should show the following (Figure 8):

- The whole height of the upper incisors should be visible on full smiling, with only the interproximal gingivae visible. This smile line is usually 1–2 mm higher in females.
- The upper incisor edges should run parallel to the lower lip (smile arc).
- The upper incisors should be close to, but not touching, the lower lip.
- The gingival margins of the anterior teeth are important if they are visible in the smile. The margins of the central incisors and canines should be approximately level, with the lateral incisors lying 1 mm more incisally than the canines and central incisors.
- The width of the smile should be such that buccal corridors should be visible, but minimal. The buccal corridor is the space between the angle of the mouth and the buccal surfaces of the most distal visible tooth.
- There should be a symmetrical dental arrangement.
- The upper dental midline should be coincident to the middle of the face.



**Figure 8:** A normal smile.

## 5) Soft tissue examination

In addition to assessing the smile aesthetics, a soft tissue examination will also assess:

• lips • tongue.

Lips can be competent (i.e. meet together at rest), potentially competent (position of incisors prevents comfortable lip seal to be obtained at rest, but the patient can hold the lips together if required), or incompetent (require considerable muscular activity to obtain a lip seal). The relationship of the lips should also be evaluated from the frontal view (Figure 9):

• Competent lips are together at rest;

• Potentially competent lips are apart at rest, but this is due to a physical obstruction, such as the lower lip resting behind the upper incisors; and

• Incompetent lips are apart at rest and require excessive muscular activity to obtain a lip seal.

Lip incompetence is common in preadolescent children, but increases with age due to vertical growth of the soft tissues. The ability to achieve lip competence is particularly important when reducing an overjet in a Class II division 1 malocclusion, as the stability of the case is improved if the upper incisor position is under the control of competent lips at the end of treatment.

Lips should be everted at their base, with some vermillion border seen at rest. Protrusion of the lips does differ between different ethnic groups with patients of Afro-Caribbean origin being more protrusive than those of Caucasian origin. The use of Ricketts' esthetic line (E-line) provides a guide to the appropriate prominence of the lips within the face). The nasolabial angle is formed between the base of the nose and the upper lip and should be 90–110° (Figure 10). It can be affected by the shape of the nose, but also the drape of the upper lip. The drape of the upper lip can be affected by the support of the upper incisor. If the shape of the nose is normal, a high nasolabial angle could therefore indicate a retrusive lip, whereas a low nasolabial angle could indicate lip protrusion.

The reason why an assessment of the tongue is performed during the extra-oral examination is to determine the method by which patients achieve an anterior seal during swallowing, and the position of the tongue at rest. In some patients with incompetent lips, the tongue thrusts forward to contact with the lips to form an anterior seal. This is usually adaptive to the underlying malocclusion, so when the treatment is complete and normal lip competence can be achieved, the tongue thrust ceases. In some patients, there is a so-called endogenous tongue thrust, which will re-establish itself after

treatment, leading to relapse. Being able to identify cases that may have this strong relapse potential would be helpful. It is, however, very difficult to confidently distinguish between an adaptive tongue thrust and an endogenous tongue thrust. Patients with an endogenous tongue thrust tend to show proclination of both the upper and lower incisors, an anterior open bite, an associated lisp, and the tongue tends to sit between the incisors at rest. It is probably the resting position of the tongue, rather than the action of the tongue in function that is more important.



**Figure 9:** Competent (left), potentially competent (middle) and incompetent (right) lips.

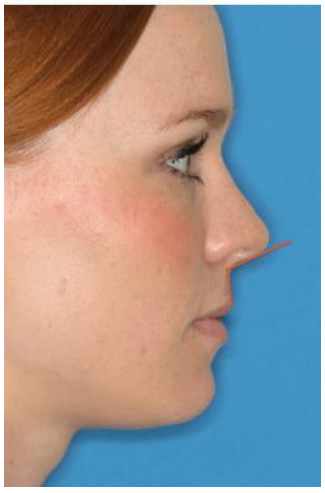

**Figure 10:** The normal nasolabial angle is 90–110°. This is important to note as the angle can be affected by orthodontic movement of the upper incisors.

## B) Intraoral examination

The intra-oral examination allows the clinician to assess the:

- Stage of dental development (by charting the teeth present)
- Soft tissues and periodontium for pathology
- Oral hygiene
- Overall dental health, including identifying any caries and restorations
- Tooth position within each arch and between arches.

## 1) Assessment of oral health

It is key that any pathology is identified in the mucosal surfaces, periodontally or in the teeth themselves. Generally, any pathology needs to be treated and stabilized before any orthodontic treatment can be undertaken. Periodontal disease is fortunately unusual in child patients, but is relatively common in adults. Any mucogingival or periodontal problems need to be carefully noted. The importance of identifying and stabilizing periodontal disease, allowing us to modify treatment planning and mechanics for these patients. Excellent oral hygiene is essential for orthodontic treatment otherwise there is a high risk of decalcification and increased attachment loss. Treatment should not begin until a patient can demonstrate they can consistently maintain high levels of oral hygiene. Dental pathology can have a significant influence on the treatment plan, and additional radiographs and special tests (such as vitality tests) may be required.

## 2) Assessment of each dental arch

Each arch is assessed individually for:

- Crowding or spacing.
- Alignment of teeth, including displacements or rotations of teeth.
- Inclination of the labial segments (proclined, upright, or retroclined).
- Angulation of the canines (mesial, upright, or distal) as this affects anchorage assessment later.
- Arch shape and symmetry • depth of curve of Spee.

## 3) Assessment of arches in occlusion

The arches are now assessed in occlusion. The incisor relationships are assessed first: incisor classification, overjet or anterior crossbites (anteroposterior), overbite or open bite (vertical), and

centrelines (transverse). Then the buccal relationships are assessed: canine and molar relationships (anteroposterior), any lateral open bites (vertical), and buccal crossbites (transverse).

- ✓ Incisor classification.
- ✓ Overjet

  This is measured from the labial surface of the most prominent incisor to the labial surface of the mandibular incisor. This would normally be 2–4 mm. If the lower incisor lies anterior to the upper incisors, then overjet is given a negative value.

- ✓ Overbite

  This measures how much the maxillary incisors overlap the mandibular incisors vertically. There are three features to note when assessing the overbite: • Amount of overlap. • Whether the lower teeth are in contact with the opposing teeth or soft tissues (complete overbite) or if they are not touching anything (incomplete overbite). • Whether any soft tissue damage is being caused (when it is described as traumatic). A normal value would be one-third coverage of the crown of the lower incisor. If the overlap is greater than this, the overbite is described as increased, and if it is less than this, it is decreased. If there is no overlap at all, it is an anterior open bite. Occasionally an overbite can be traumatic.

- ✓ Centrelines (midline)

  The centrelines should ideally be coincident with each other and to the facial midline.
- ✓ Canine and molar classification.
- ✓ Crossbite

## 3) Informed consent

Informed consent: means the patient is given information to help them to understand the:

- Malocclusion.
- Proposed treatment and alternatives.
- Commitment required.
- Duration of treatment.
- Cost implications.

Treatment alternatives, which must always include no treatment as an option, must be clearly explained, with the risks and benefits of each approach carefully discussed.

Patients who are 16 years or older are presumed to have competence to give consent for themselves. Many orthodontic patients are younger than this, but provided that they fully understand the process, they can give consent. If a competent child consents to treatment, a parent cannot override this decision – this is known as 'Gillick competence'.

However, it is preferable to have full parental support for the treatment if possible. If the converse occurs – the parent wants the treatment, but the child does not – then it is best not to proceed. Orthodontic treatment requires a great deal of compliance, and unless the patient is totally committed, it is best to delay until such time as they are.

It is advisable to obtain a written consent for the treatment. A copy should be given to the patient with clear details of the:

1- Aims of the treatment,
2- Risks and benefits,
3- Types of appliances to be used,
4- Details of any teeth to be extracted,
5- Commitment required,
6- Likely duration of treatment
7- Any financial implications,
8- As well as long-term retention requirements.

As well as providing a written record of the aims of the treatment and the treatment plan, it is useful to give the patient a summary of exactly what is expected from them, this involves information about:

1- Maintenance of good oral hygiene.
2- Appropriate diet and regular attendance.
3- Also any specific requirements relevant to their case, such as headgear wear, turning expansion screws and elastic wear. A fully prepared and committed patient is more likely to result in more successful orthodontic treatment.

## In conclusion

- ✓ **Purpose of Orthodontic Assessment** – To gather complete patient information through history, clinical examination, and records, enabling an accurate diagnosis, risk–benefit evaluation, and informed patient decision-making.
- ✓ **History Taking** – Includes personal, medical, dental, and social details, chief complaint, habits, growth status, and socio-behavioral factors, all of which influence treatment planning, timing, and appliance choice.
- ✓ **Comprehensive Clinical Examination** – Extra-oral and intra-oral assessments in all three planes (AP, vertical, transverse) plus evaluation of smile aesthetics, soft tissues, occlusion, and oral health to detect problems and guide targeted intervention.
- ✓ **Informed Consent & Patient Commitment** – Clear communication of diagnosis, treatment options, risks, benefits, costs, and retention needs ensures patient cooperation, compliance, and optimal treatment outcomes.

## References:

1) **Littlewood SJ, Mitchell L. (2019):** An introduction to orthodontics. 5th ed. Oxford University Press.
2) **Phulari BS. (2017):** Orthodontics: principles and practice: JP Medical Ltd.
3) **Proffit WR, Fields HW, Larson BE, Sarver DM. (2025):** Contemporary orthodontics 6th ed. Philadelphia: Mosby.

# Good Luck