

NEUTRAL ZONE TECHNIQUE IN COMPLETE DENTURE

م.د. غزوان الكناني

Neutral Zone Technique in complete denture

م.د. غزوان الكناني

The stability of complete dentures is influenced by the surrounding neuromuscular system in the oral cavity. Oral functions, such as speech, mastication, swallowing, smiling, and laughing, involve the synergistic actions of the tongue, lips, cheeks, and floor of the mouth that are very complex and highly individual. Neuromuscular control is the key for the stability of dentures. Size and position of denture teeth and the contours of polished surface play a crucial role in denture's stability as they are subjected to destabilizing forces from the tongue, lips, and cheeks if they interfere with the function of oral structures.

Definition of Neutral Zone. : Is the potential space between the lips and cheeks on one side and the tongue on the other; that area or position where the forces between the tongue and cheeks or lips are equal. (GPT.9, 2017)

The Neutral Zone Philosophy

It is based upon the **concept** that for each individual, there is a denture space which is a specific area where the function of the musculature will not unseat the denture and where the forces generated by the tongue are neutralized by the forces generated by lips and cheeks.

The Neutral Zone and the denture Space:

In complete edentulous patients a void in the oral cavity is called **potential denture space.**

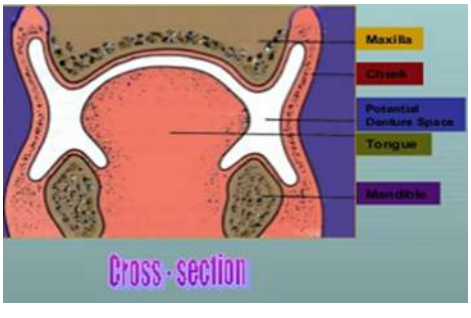

Boundaries of denture space

- Maxilla and soft palate _superiorly
- Mandible and floor of the mouth _inferiorly

- Tongue _medially
- Muscles and tissues of cheek and lips _laterally

Neutral Zone Concept

Neutral zone is that area in the mouth where, during function, the forces of tongue pressing outward are neutralized by the forces of the cheeks and lips pressing inwards. Since these forces are developed through muscular contraction during chewing, speaking, swallowing etc. they vary in magnitude and direction in different individuals and in different periods of life.

The way these forces are directed against the denture will either stabilize or dislodge them. Our objective is to utilize this information to so position the teeth and the external surface that the force the musculature exerts will have a seating effect. This can be only accomplished by a knowledge of neutral zone and by positioning the teeth and developing the external surface so that all the forces exerted are neutralized.

The central thesis of the neutral zone approach to complete dentures is 'to locate that area in the edentulous mouth where the teeth should be positioned so that the forces exerted by the muscles will tend to stabilize the denture rather than unseat it'.

Muscles involved in Neutral zone Techniques:

<u>Muscles of Cheek:</u>

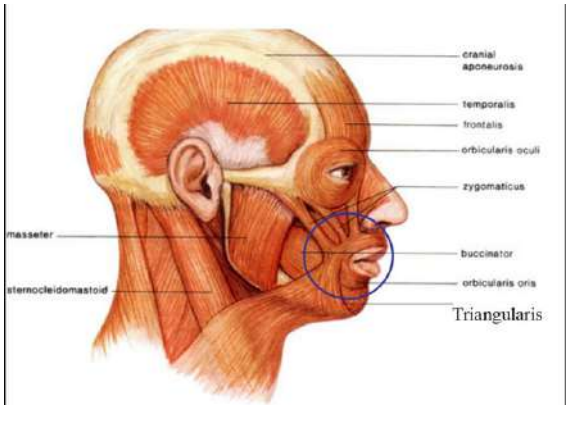

1. Masseter

Affects distobuccal border of mandibular denture.

2. Buccinator

Muscle fibers forms a continuous bands ,hence the size of the arch is limited by the strength of the contractile force and the length of the muscles when they are contracted.

Common practice of centralization or lingualization of occlusion creates a space between the cheek and teeth and external surface of the denture which prevents the buccinator from performing its proper function in two ways:

First: Food accumulation and becomes more difficult to the cheek to place the food back to the occlusal surface of the teeth.

Second: The space prevents the buccinator from neutralization the lateral forces of the tongue during function.

Muscles of the lips:

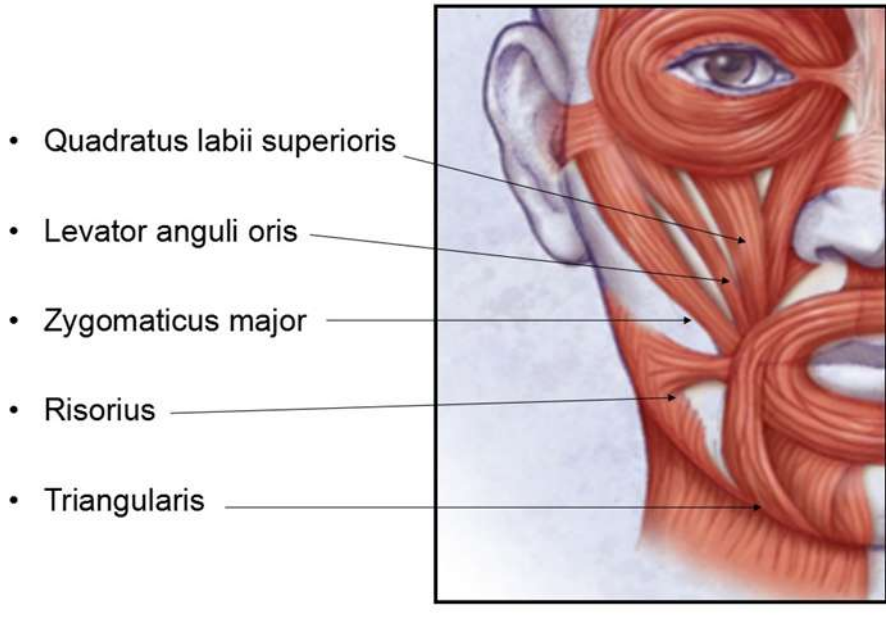

---

1. **Orbicularis oris:** During function as in chewing , smiling and swallowing , it exerts force against teeth and denture flanges which counteracted by the tongue .

2. **Caninus** This together with other muscles, pulls the upper lip upward and in sucking and swallowing pull the lip forward, thus exerting forces on teeth and labial flanges.
3. **Zygomatico major.** Pulls the angle of the mouth upward and backward.
4. **Risorius:** Retract the corner of the mouth.
5. **Mentalis:** Turns the lower lip outward and on contraction makes the lower labial vestibule shallow.
6. **Triangularis:** Contracts during sucking and exert pressure on teeth and denture flange.
7. **Modiolus:** It is contributed by followings facial muscles **:**
   1. Orbicilaris oris
   2. Buccinator
   3. Levator anguli oris
   4. Depressor anguli oris
   5. Zygomaticus major
   6. Risorius
   7. Platysma
   8. Levator labii superioris

   Because of strength and variability of movement of the area, **modiolus** is very important in stability of lower denture. Proper positioning of teeth and contouring and narrowing of external surface of premolar area should be done otherwise the modiolus will constantly unseat the lower denture.

Muscles of the Tongue:

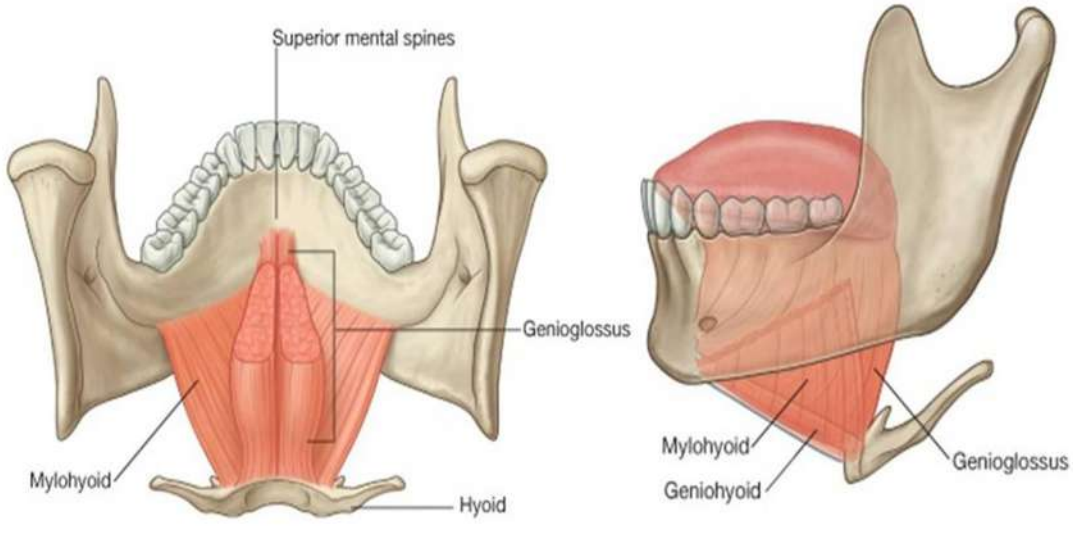

1. Intrinsic muscles

they are confined to the tongue and not attached to the bone. They produce change in shape of the tongue.

2. Extrinsic muscles

These muscles attached to the bones and soft palate.They are**:**

Genioglossus , styloglossus , hyoglossus and palatoglossus .

They are responsible for tongue movement and change in shape.

Tongue is capable of changing shape and position during function as in mastication, swallowing and speech. During function it will be in constant contact with lingual surface of lower teeth, lingual flange of lower denture and palatal surface of upper denture. The common practice of lingualization is one of the greatest influencing factors of lower denture instability because it violates the neutral zone and encroaches on the tongue space.

Influence of muscles on dental arches:

During childhood , the teeth erupt under the influence of muscular environment created by forces exerted by tongue , cheeks and lips ,in addition to genetic factor .

These forces have a definite influence upon the position of the erupted teeth ,arch form ,and occlusion .

Generally ,muscular activity and habits which develop during childhood continue throughout life and after teeth loss .

It is important to position artificial teeth in the arch form compatible with these muscular forces .

As the impression surface area decreases (due to alveolar ridge resorption), the retention and stability of the denture decrease .

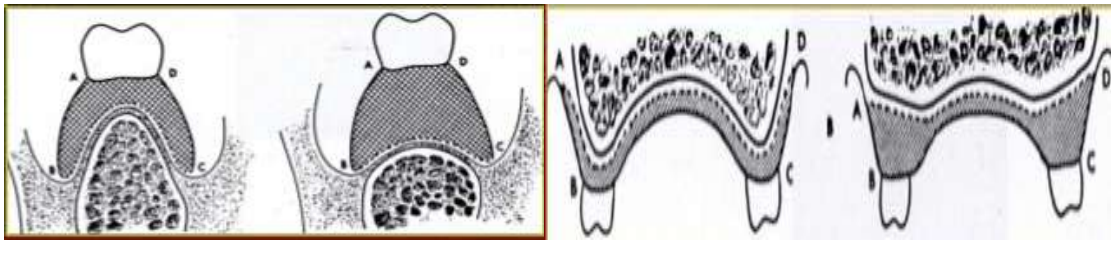

Consequently, retention and stability become more dependent on the correct positioning of the teeth and contours of the polished surfaces of the dentures.

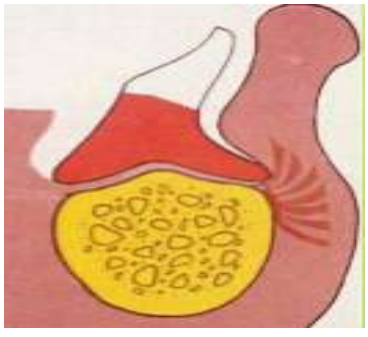

The polished surfaces should be so contoured that the horizontally directed forces applied by the peri_denture muscles should act to seat the denture.
The artificial teeth should not be placed on the crest of the ridge or buccally or lingually to it_rather these should be placed as dictated by musculature.



After the teeth have been lost, muscle function greatly influence any complete dentures that are placed in the mouth. It is therefore, extremely important that the teeth be placed in the mouth within the arch form that falls within the area that is compatible with muscular forces.

Influence of forces on denture surfaces

The more ridge loss, the less influence of impression surface of the denture on its stability and retention ,and the more external surface area which is needed to be contoured properly to overcome this situation.
The forces on external surfaces are changing in magnitude and direction during function and remain constant at rest.
In order to construct denture that function properly, we must develop fit and contour of external surface as fit and contour of impression and occlusal surfaces.

Objectives of Neutral zone Techniques:

1. Rehabilitation of complete denture patient.
2. Achieve maximum prosthesis stability, comfort, and function.
3. Arrange the denture teeth and contour the complete denture polished surfaces.
4. Minimize the ongoing diminution of the residual alveolar ridges.

Indications of Neutral zone Techniques:

1. Severely atrophic mandibular ridge.



2. High mentalis attachment

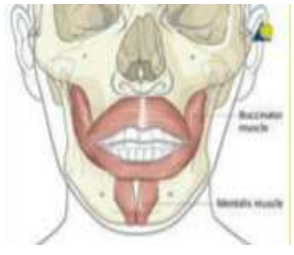

3. Neuromuscular disease.

4. Atypical shape of oral structures.

5. Trauma.

6. Systemic disease.

7. Locate optimal position for implants.



8. Partial glossectomy.

9. Motor nerve damage to the tongue.

Neutral zone technique could be performed in:

- Impression stage.
- Jaw relation record.
- Trial denture.
- Finished or previous prosthesis.

Recording neutral zone in final impression stage

Step by step :

- ✓ Primary impression of upper and lower arches.
- ✓ Construction of acrylic bases.

An acrylic denture base with retentive wires is fabricated to retain impression material during recording neutral zone area.

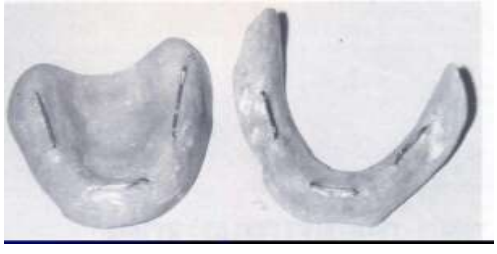

- ✓ Impression compound is adapted on external surface of the tray and inserted in the patient's mouth.



- ✓ Establishment of occlusal plane.



- ✓ Locating neutral zone for the upper arch.

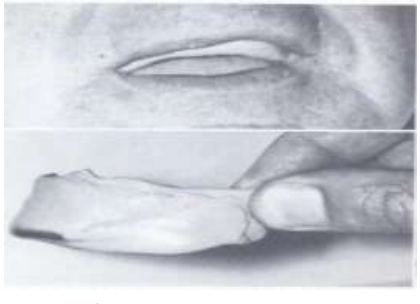

- ✓ Vertical dimension establishment.
- ✓ Lower final impression with Z.O.E.

The lower record base is inserted with lubricated upper denture base together to make impression with **closed mouth technique.**

- ✓ Second impression is made with krex material which is white ,soft ,thin , free flowing and contrasting color with the Z.O.E.
- ✓ Upper arch impression.



Several holes is made in the rugea area to allow excess Z.O.E. to escape during impression.

- ✓ Second impression with krex.
- ✓ Centric relation record.
- ✓ Mounting to the articulator and fabrication of matrices.



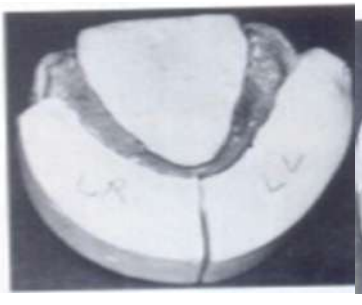



Lower matrix

Upper matrix

- ✓ Teeth arrangement.





- ✓ Trial denture and neutral zone impression for polished surfaces and the dentures is ready for investing.







Recording neutral zone in jaw relation visit

- Primary impression with impression compound.
- Final impression with Z.O.E.

- Jaw relation record.
- Lower acrylic special tray with metal spurs.

Occlusal pillars built in green stick to establish the occlusal height.





- Instruct the patient to perform certain oral movement including: ***<u>sucking , grinning , whistling , pursing of the lips and swallowing</u>*** .





- Tissue conditioner being molded with mouth movement.



- The tray is returned to the cast and plaster index is formed .



- Wax rim is formed and teeth set up.





- Insertion



Recording neutral zone in try in stage

- ❖ Apply vaseline on trial denture before making impression.
- ❖ Impression material is applied on buccal & lingual surfaces of waxed up denture.



- ❖ Patient performs oral function.
- ❖ Inspect the impression on polished area including palatal surface.



- ❖ Carefully carve the material over tooth surfaces with carver.



- ❖ Finished denture.



Recording neutral zone in finished denture

Determining the fit of complete denture to neutral zone.

- Coat the polished surface of the denture with low viscosity silicone impression material.
- Ask the patient to perform functional movement while the material sets.
- Inspect the denture and adjust any heavy muscle contact.



Determining the optimal space for a segment of the denture.

- Remove the teeth and base material from the segment of the denture that needs modification.
- Apply adhesive and take the impression with moldable material.
- Check for stability and undertake the laboratory procedure.



Comparison between conventional mandibular denture and mandibular denture made by neutral zone concept •

- **According to setting of the teeth in relation to the crest:**

Position	Conventional method	Neutral zone method
Anteriorly	Slightly labial	Slightly lingual
Premolar area	Exactly on the crest	Slightly lingual
Posteriorly	Lingually	buccally

- **According to denture surface area:**
  The neutral zone denture tissue surface area is **higher** than the conventional denture .
- **According to denture volume:**
  The neutral zone denture volume is **lower** than the volume of the conventional denture .

ADVANTAGE:

1.Improved stability and retention.
2.Correct positioning of posterior teeth allowing sufficient tongue space.
3.Reduced food trapping adjacent to the molar teeth.
4.Good esthetic due to facial support.

LIMITATION FOR THE SUCCESS OF NEUTRAL ZONE IMPRESSION TECHNIQUE:

1.Viscosity of the material used . More viscous, the more difficult for the muscle to mold .
2.Geriatric patients could suffer from the procedure due to loss of their muscular tone .
3.Proper stability & retention of the bases , so as the comfort.
4. The resultant neutral zone is often narrow and might be lingually placed, this will affect functional movement of the tongue and phonetics.
5. The technique does not offer any guidelines for the selection of teeth.

Neutral zone always moves according to the periods of edentulism, tonicity of the perioral musculatures and tongue. Arrangement of the teeth in neutral zone, increasing the impression surface area of the denture and reduction in the volume of the denture, provides good retention, stability and comfort to the patients.