Human Anatomy

Dr. Akad Al-Asadi

1st stage **Lab. -1-**

The skull

Frontal or anterior view of the skull

They are the frontal bone, ethmoid, lacrimal bone, maxilla, zygomatic bone, nasal bone, and mandible

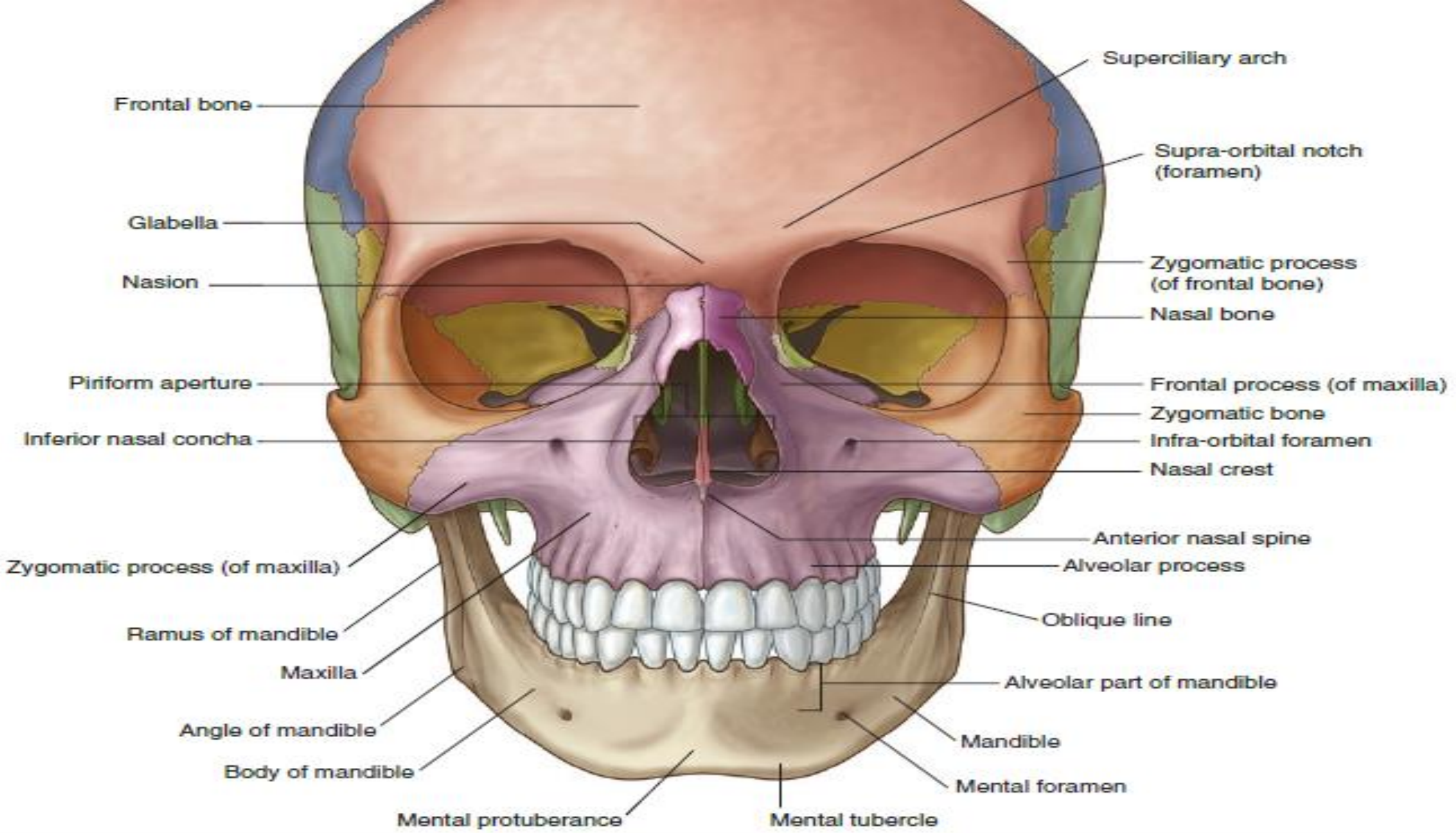
Superciliary arch
Frontal bone
Supra-orbital notch (foramen)
Glabella
Zygomatic process (of frontal bone)
Nasion
Nasal bone
Piriform aperture
Frontal process (of maxilla)
Zygomatic bone
Inferior nasal concha
Infra-orbital foramen
Nasal crest
Anterior nasal spine
Zygomatic process (of maxilla)
Alveolar process
Oblique line
Ramus of mandible
Maxilla
Alveolar part of mandible
Angle of mandible
Mandible
Body of mandible
Mental foramen
Mental protuberance
Mental tubercle

-The **frontal bone**, or forehead bone, curves downward to make the upper margins of the orbits .**supraorbital notch** (or **supraorbital foramen**) is at or near the orbital rim. Medially, the frontal bone articulates with the frontal processes of the maxillae and with the nasal bones. Laterally, the frontal bone articulates with the zygomatic bone.

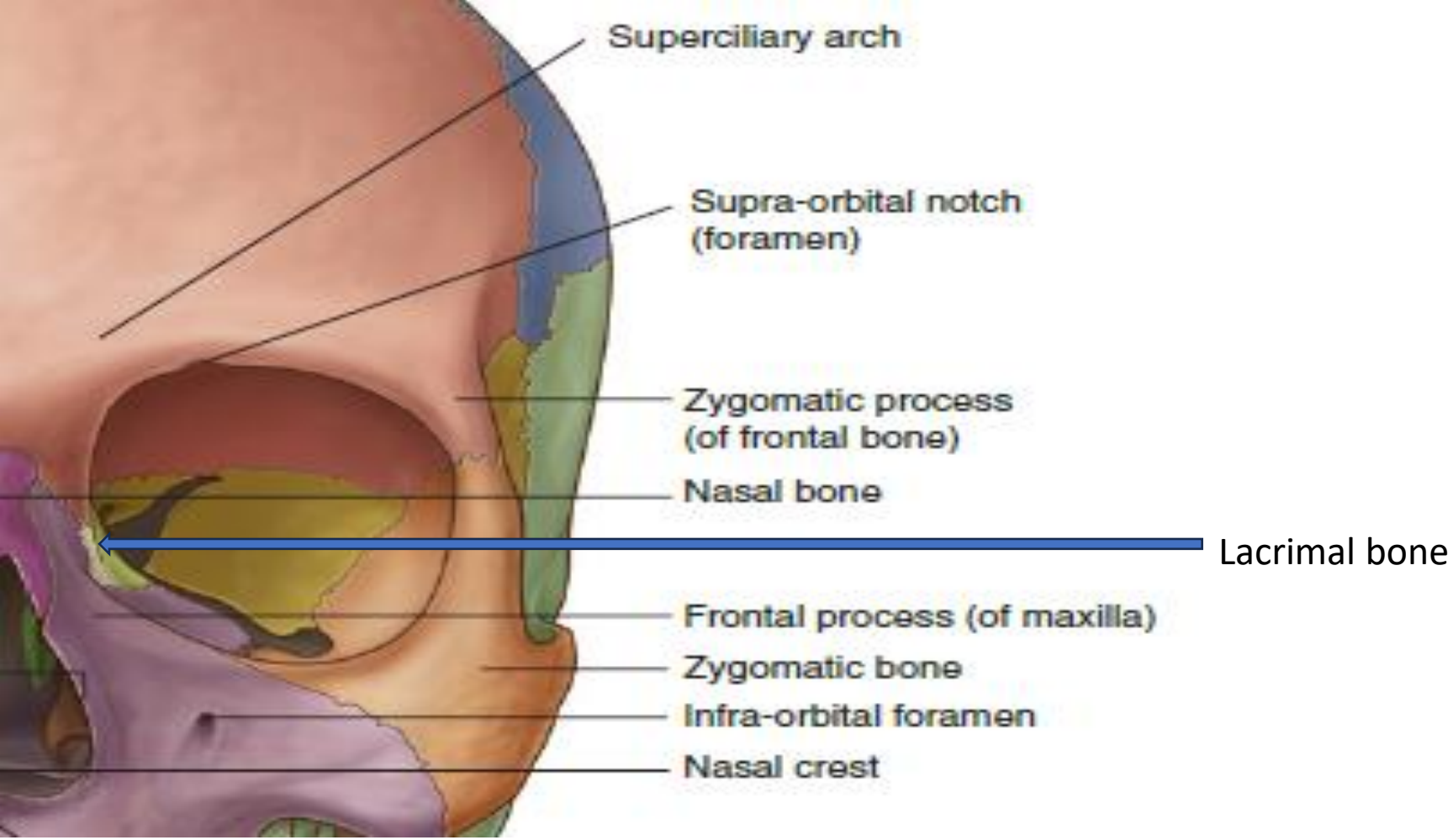

-The **orbital margins** are bounded by the frontal bone superiorly, the zygomatic bone laterally, the maxilla inferiorly, and processes of the maxilla and frontal bone medially.

The frontal bone contains two hollow spaces lined with mucous membrane, the **frontal air sinuses**, just above the orbital margins. These sinuses communicate with the nose and serve to lighten the facial skeleton and act as voice resonators.

cleared specimen from the front, illuminated from behind

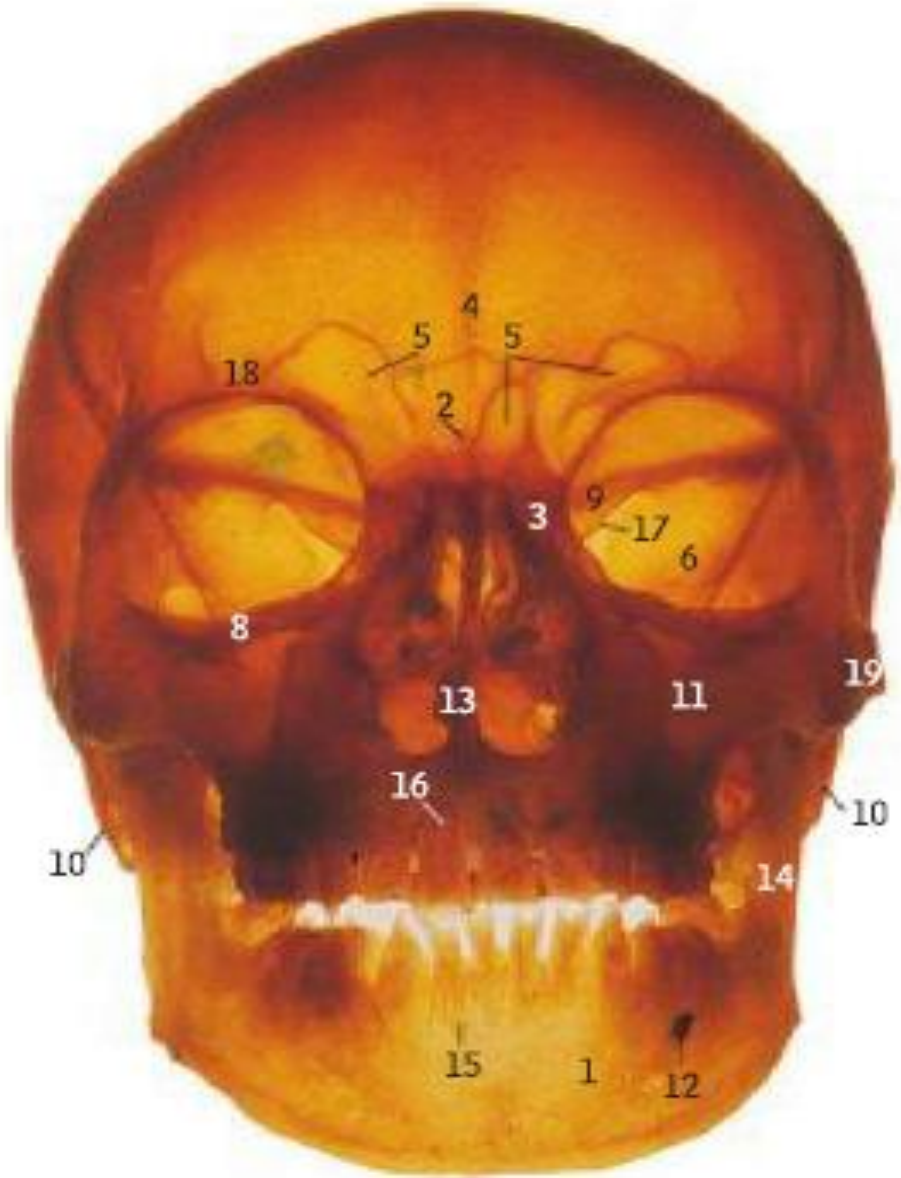

radiograph of facial bones, occipitofrontal view

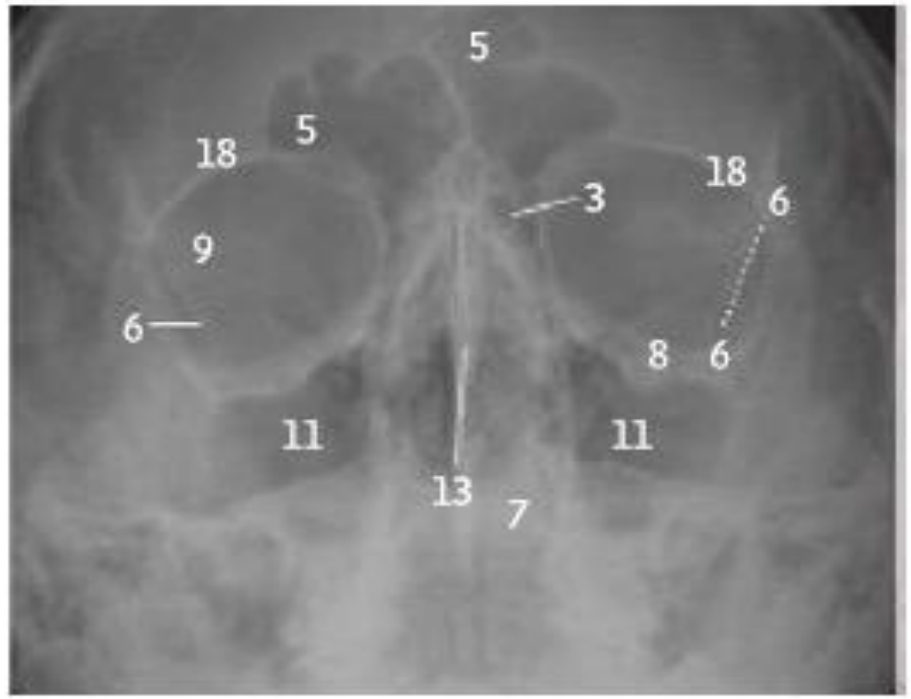

Compare with the skull on page 1.

1 Body of mandible
2 Crista galli
3 Ethmoidal air cells
4 Frontal crest
5 Frontal sinus
6 Greater wing of sphenoid bone
7 Inferior nasal concha
8 Infra-orbital margin
9 Lesser wing of sphenoid bone
10 Mastoid process
11 Maxillary sinus
12 Mental foramen
13 Nasal septum
14 Ramus of mandible
15 Root of lower lateral incisor
16 Root of upper central incisor
17 Superior orbital fissure
18 Supra-orbital margin
19 Zygomatic arch

The two **nasal bones** form the bridge of the nose. Their lower borders, with the maxillae, make the **anterior nasal aperture** and is pear-shaped. The nasal cavity is divided into two by the bony **nasal septum**, which is largely formed by the **vomer** and also by the **perpendicular plate of the ethmoid**. The **superior** and **middle conchae** are shelves of bone that project into the nasal cavity from the ethmoid on each side. The **inferior conchae** are separate bones.

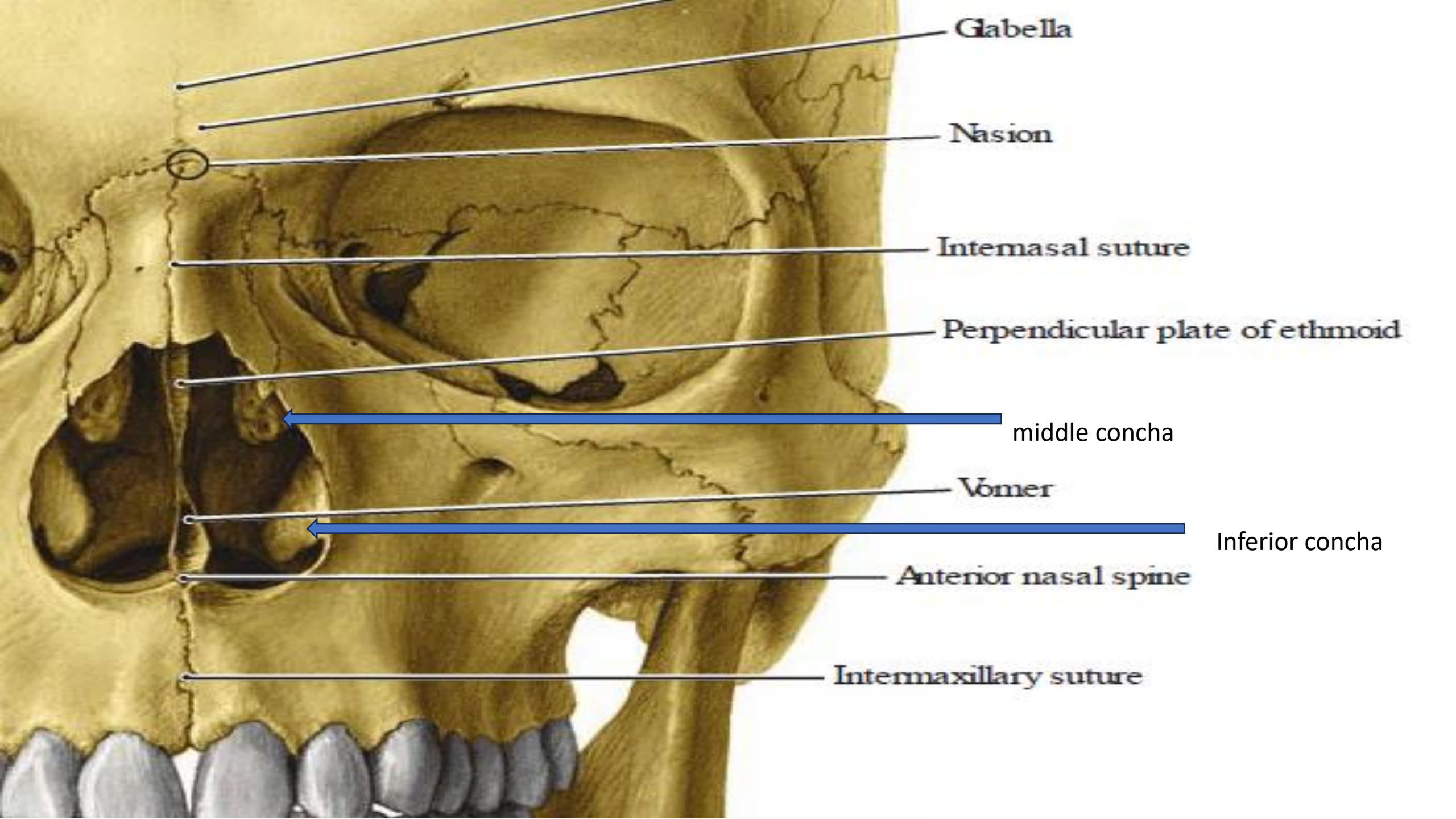
Glabella
Nasion
Internasal suture
Perpendicular plate of ethmoid
middle concha
Vomer
Inferior concha
Anterior nasal spine
Intermaxillary suture

The two **maxillae** form the upper jaw, the anterior part of the hard palate, part of the lateral walls of the nasal cavities, and part of the floors of the orbital cavities. The two bones meet in the midline at the **intermaxillary suture** and form the lower margin of the nasal aperture. The **infraorbital foramen** perforates the maxilla below the orbit. Medial to the orbit, the maxilla articulates directly with the frontal bone through the **frontal process of the maxilla**. This process forms the lower part of the medial margin of the orbit. It articulates anteriorly with the **nasal bone** and posteriorly with the **lacrimal bone**.

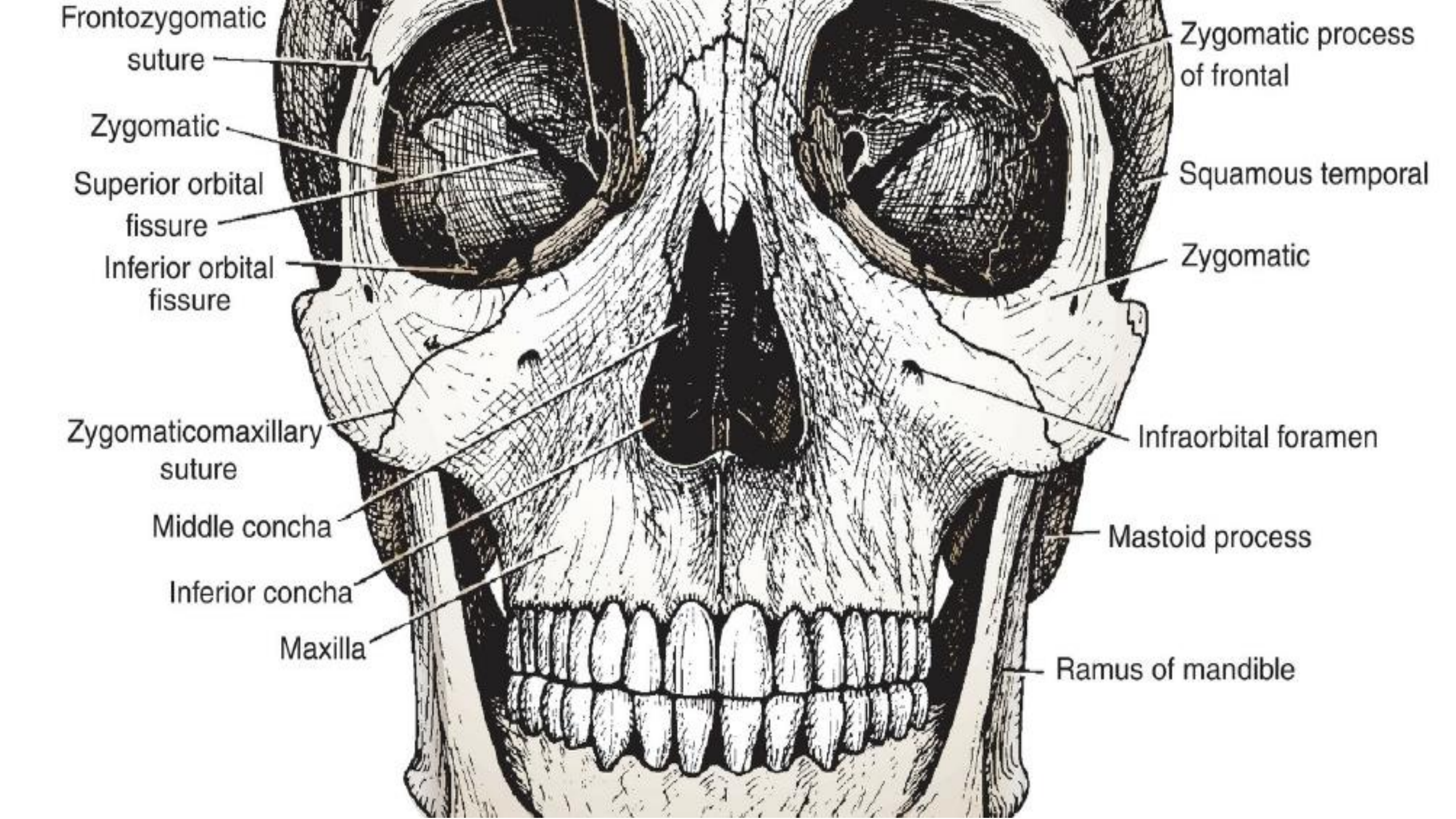
Frontozygomatic suture
Zygomatic
Superior orbital fissure
Inferior orbital fissure
Zygomaticomaxillary suture
Middle concha
Inferior concha
Maxilla
Zygomatic process of frontal
Squamous temporal
Zygomatic
Infraorbital foramen
Mastoid process
Ramus of mandible

The **alveolar process** projects downward and, together with the fellow of the opposite side, forms the **alveolar arch**, which carries the upper teeth. Each maxilla contains a large, pyramid-shaped cavity lined with mucous membrane, the **maxillary sinus**. This communicates with the nasal cavity and serves to lighten the facial skeleton and act as a voice resonator.



A. Postero-anterior Radiograph

RADIOGRAPHS OF THE CRANIUM

A. Postero-anterior (*Caldwell*) radiograph. This view places the orbits centrally in the head and is used to examine the orbits and paranasal sinuses.

Observe in **A**:

- The labeled features include the superior orbital fissure (*Sr*), lesser wing of the sphenoid (*S*), superior surface of the petrous part of the temporal bone (*T*), crista galli (*C*), frontal sinus (*F*), mandible (*MN*), maxillary sinus (*M*), and diploic veins (*DP*).
- The nasal septum is formed by the perpendicular plate of the ethmoid (*E*) and the vomer (*V*); note the inferior and middle conchae (I) of the lateral wall of the nose.
- Superimposed on the facial skeleton are the dens (*D*) and lateral masses of the atlas (*A*).

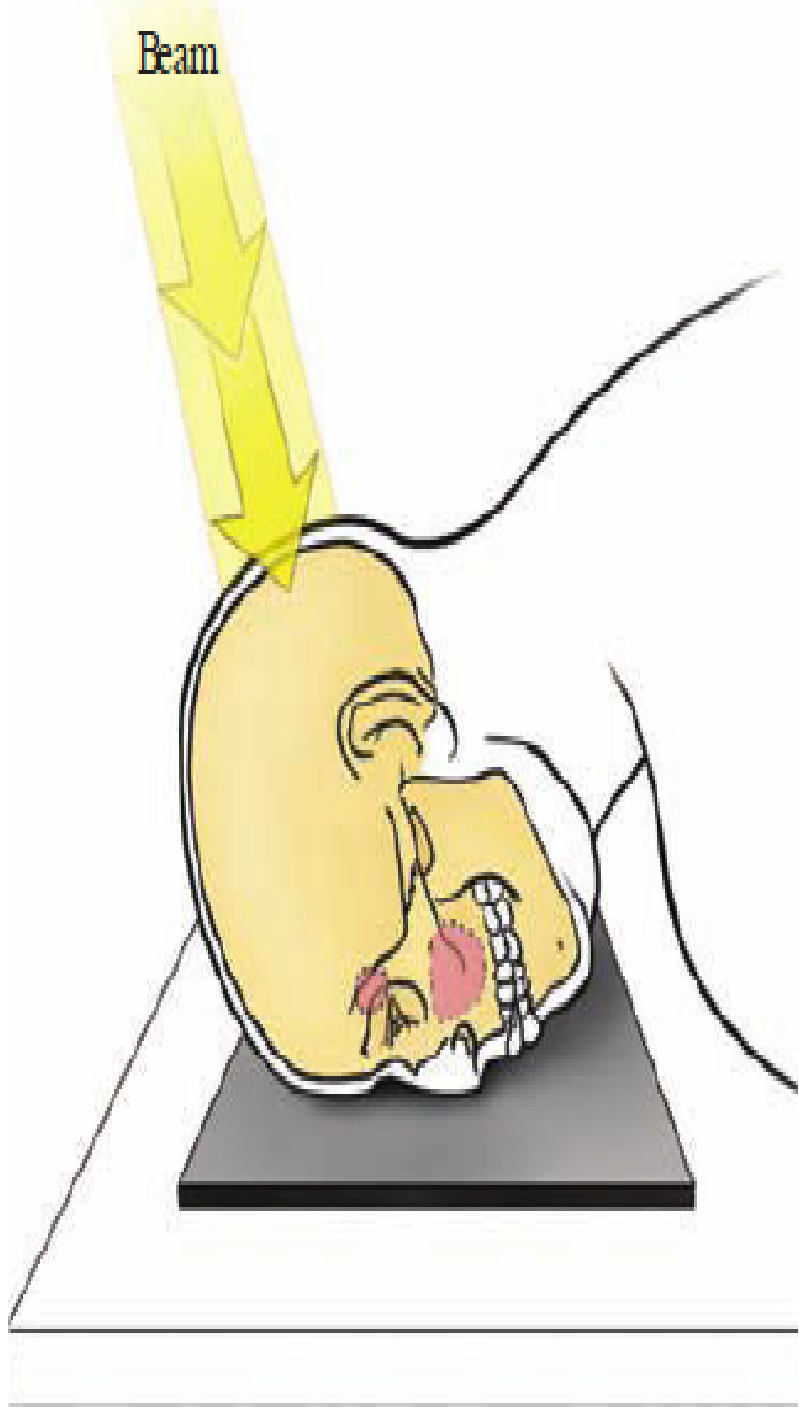

The **zygomatic bone(cheek bone)** forms the prominence of the cheek and part of the lateral wall and floor of the orbital cavity. Medially, it articulates with the maxilla, and laterally, it articulates with the zygomatic process of the temporal bone to form the **zygomatic arch**. The zygomatic bone is perforated by two foramina for the zygomaticofacial and zygomaticotemporal nerves. It forms the lateral wall of the orbit with the greater wing of the sphenoid bone. The zygomatic bone between the orbit and anterior surface of the maxilla forms the lateral half of the inferior orbital margin.

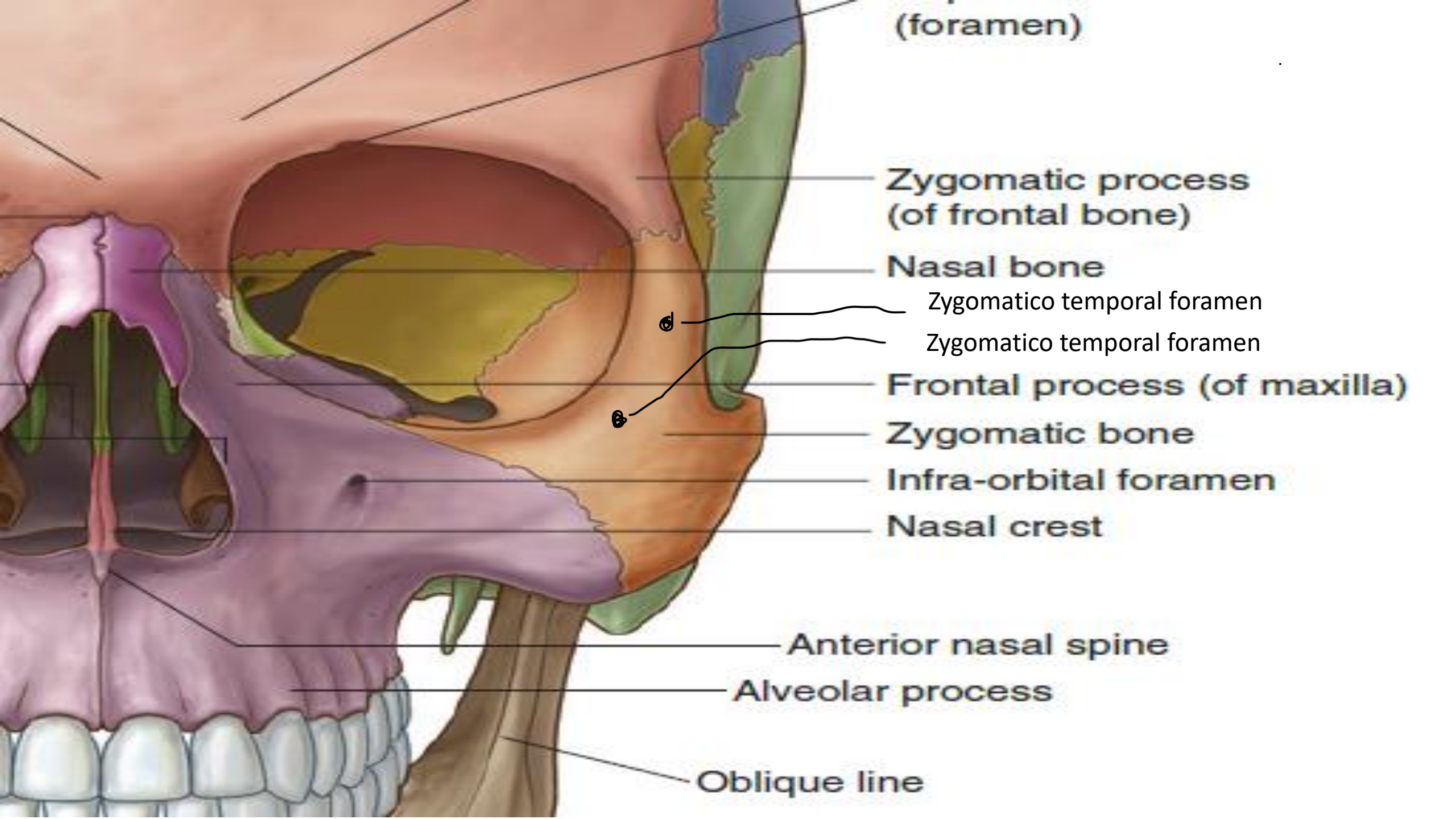
(foramen)
Zygomatic process
(of frontal bone)
Nasal bone
Zygomatico temporal foramen
Zygomatico temporal foramen
Frontal process (of maxilla)
Zygomatic bone
Infra-orbital foramen
Nasal crest
Anterior nasal spine
Alveolar process
Oblique line

The bone of the lower jaw is the **mandible**. Identify the horizontal **body** of the mandible. upper part of the body which bears the alveolar sockets for the lower teeth is called the alveolar process . The lower border of the body extends laterally to the **angle** of the mandible. The two halves of the mandible are fused together in the adult at the **symphysis menti**. The **mental foramen** lies about 4 cm lateral to the midline between the alveolar border and the lower border of the mandible. In the living, it is felt as a slight depression.

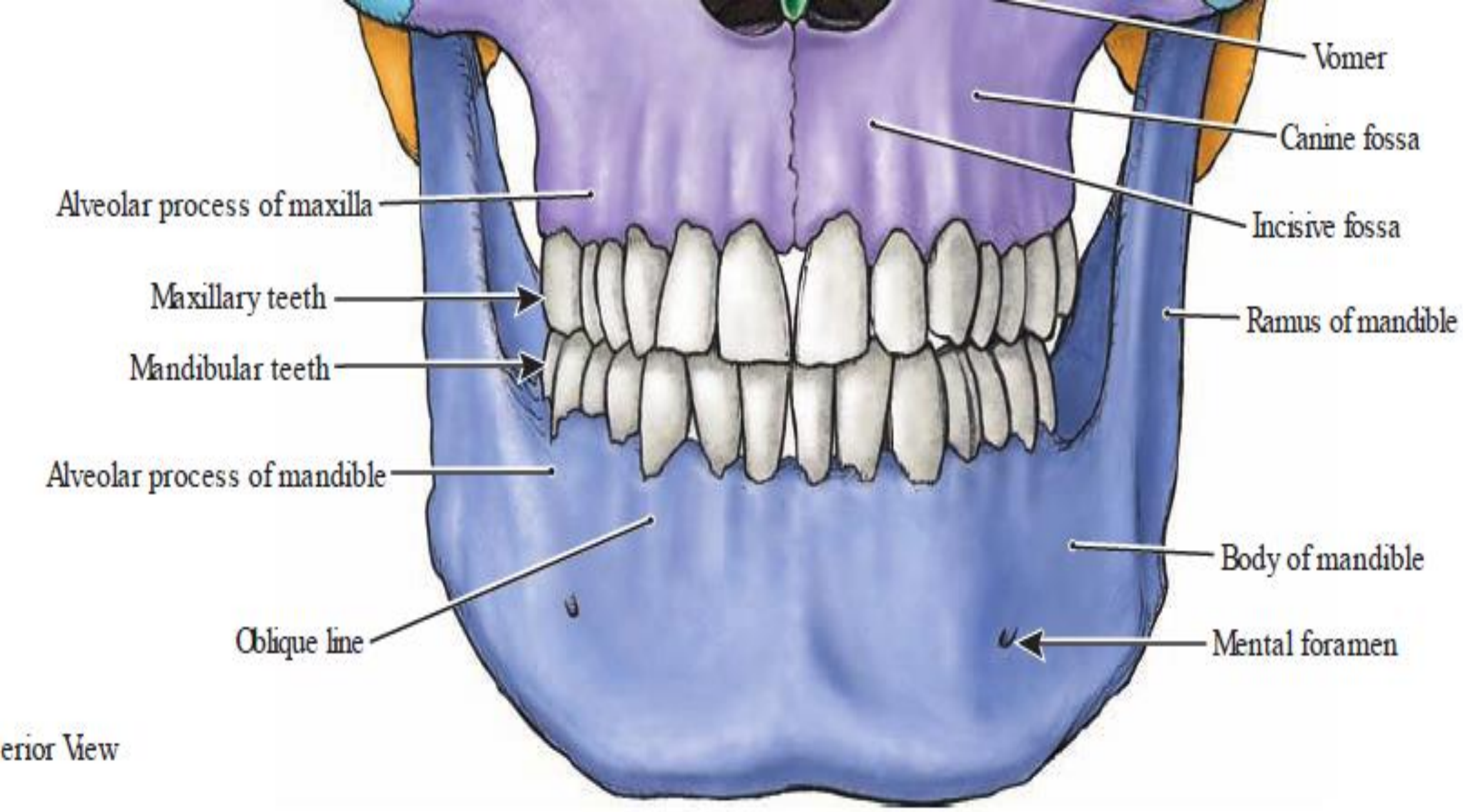
Vomer
Canine fossa
Incisive fossa
Alveolar process of maxilla
Maxillary teeth
Ramus of mandible
Mandibular teeth
Alveolar process of mandible
Body of mandible
Oblique line
Mental foramen

erior View

