9.1.2023

PEDIATRIC DENTISTRY

4th Year



Professor
Zainab Juma Jafar

MORPHOLOGICAL CONSIDERATIONS IN CAVITY PREPARATION OF PRIMARY TEETH

- *The crowns of the primary teeth are smaller but more bulbous than those of the corresponding permanent teeth, and the molars are bell-shaped, with a definite constriction in the cervical region.*
- *The characteristic sharp lingual inclination occlusal to the facial surfaces results in the formation of a distinct faciogingival ridge that ends abruptly at the cemento-enamel junction.*
- *The sharp constriction at the neck of the primary molar necessitates special care in the formation of the gingival floor during class II cavity preparation.*
- *The buccal and lingual surfaces of the molars, sharply converging occlusally, form a narrow occlusal surface or food table; this is especially true of the first primary molar.*
- *The pulpal outline of the primary teeth follows the dentino-enamel junction more closely than that of the permanent teeth.*
- *The pulpal horns are longer and more pointed than the cusps would indicate. The dentin also has less bulk or thickness, so the pulp is proportionately larger than that of the permanent teeth.*
- *The enamel of the primary teeth is thin but of uniform thickness. The enamel surface tends to be parallel to the dentino-enamel junction.*

BASIC PRINCIPLES IN CAVITY PREPARATION IN PRIMARY TEETH



Traditional cavity preparations for class I and class II lesions include areas that have caries involvement and may be areas that retain food and plaque material and considered areas of potential caries involvement.

A flat pulpal floor is generally advocated. However, a sharp angle between the pulpal floor and the axial wall of a two-surface preparation should be avoided.

Rounded angles throughout the preparation will result in less concentration of stresses and will permit better adaptation of the restorative material into the extremities of the preparation.

In the traditional class II cavity preparation for amalgam, the buccal and lingual extensions should be carried to self-cleansing areas. The cavity design should have greater buccal and lingual extension at the cervical area of the preparation to clear contact with the adjacent tooth. This divergent pattern is necessary because of the broad, flat contact areas of the primary molars and because of the distinct buccal bulge in the gingival third.

Ideally the width of the preparation at the isthmus should be approximately one-third the inter-cuspal dimension.

The axio-pulpal line angle should be beveled or grooved to reduce the concentration of stresses and to provide greater bulk of material in this area, which is vulnerable to fracture.

Although the traditional class I cavity preparation and restoration may occasionally be the most practical treatment for a tooth in certain circumstances, such treatment is currently obsolete for most class I lesions. The traditional treatment has been replaced, for the most part, by conservative caries excavation and restoration with a combination of bonding restorative and sealant materials.

Likewise, the traditional class II cavity preparation and restoration, although not yet considered obsolete, are currently used less frequently as steadily improving restorative materials with therapeutic and bonding capability are developed.

CAVITY PREPARATION IN PRIMARY TEETH

The steps in cavity preparation in a primary tooth are not difficult, but they do require precise operator control. Many authorities advocate the use of small, round-ended carbide burs in the high-speed hand-piece which allow for conservative cavity preparations with rounded line angles and point angles.

Alternatively, cavity preparations may be made with aluminum oxide air abrasion systems or with laser systems approved for hard-tissue procedures, when indications allow.

CAVITY PREPARATION IN PRIMARY TEETH

For patients younger than 2 years with a small but definite carious lesion in the central fossa of first primary molars, A No. 329 or No. 330 bur is used to open the decayed area and extend the cavo-surface margin only to the extent of the caries lesion. If the patient is resistant (usually), completing the preparation with an air abrasion or laser system would be inconvenient. The preparation can be completed in just a few seconds. Restoring the tooth with amalgam or a resin-modified glass ionomer arrests the decay and at least temporarily prevents further tooth destruction without a lengthy or involved dental appointment for the child.

DEEP-SEATED CLASS CAVITY

*If an **amalgam** restoration is planned, the first step in the preparation of an extensive class I cavity is to the enamel. The caries-affected dentin should next be removed with large, round burs or spoon excavators. If a caries exposure is not encountered, the cavity walls should be finished first. With deep carious lesions and near pulp exposures, the depth of the cavity*

should be covered with a biocompatible base material to provide adequate thermal protection for the pulp.

If a ***resin-based composite*** *and/or* ***glass-ionomer restoration*** *is planned, any disease-free pits and grooves may be sealed as part of the bonded restoration. The restorative material also provides thermal insulation to the pulp.*



Proximal lesions in a preschool child indicate excessive caries activity; a preventive and restorative program should be undertaken immediately.

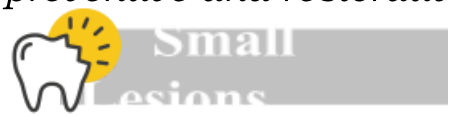

Very small incipient proximal lesions may be chemically restored with topical fluoride therapy provided by the dentist, along with the judicious use of fluoride products designed for topical application at home, improved diet and improved oral hygiene, and periodic examinations; some incipient proximal lesions may remineralize or remain in an arrested state indefinitely.

As bonded restorations have improved, especially those restorations capable of fluoride release, more conservative cavity preparation designs have also been advocated. In otherwise sound teeth free of susceptible pits and fissures, accessing small class II caries lesions via small openings in the marginal ridges or in the facial surfaces of the teeth are becoming popular techniques. Gaining access to the lesion with openings only large enough to allow caries excavation is the goal. Using resin-modified glass-

ionomer materials result in excellent restorations for this conservative procedure.



Lesions with Greater Dentin Involvement

The first step in the traditional preparation of a class II cavity in a primary tooth involves opening the marginal ridge area. Extreme care must be taken to prevent damage to the adjacent proximal surface.

Amalgam

- *The gingival seat and proximal walls should break contact with the adjacent tooth.*
- *The angle formed by the axial wall and the buccal and lingual walls of the proximal box should approach a right angle.*
- *The buccal and lingual walls necessarily diverge toward the cervical region, following the general contour of the tooth.*
- *The occlusal extension of the preparation should include any caries-susceptible pits and fissures. If the occlusal surface is sound and not caries-susceptible, then a minimal occlusal dovetail is still often needed to enhance the cavity retention form.*
- *If caries affected tooth structure remains after the preparation outline is established, it should be removed next.*
- *The appropriate liner or intermediate base, and a snug-fitting matrix should be placed before the amalgam is inserted.*

Aesthetic Materials

The preparation and restoration may be similar to those for amalgam when significant caries exists on both the occlusal and proximal surfaces. However, little or no occlusal preparation may be required when the occlusal pits and fissures are caries-susceptible but sound or incipient. The proximal restoration may then be combined with the application of an occlusal sealant (with or without enameloplasty). Whenever composite restorative materials are used, enamel beveling, etching, and application of bonding agents are recommended.

- *It has been demonstrated that the placement and finishing of posterior composite restorations are significantly more time consuming than those for comparable amalgam restorations. In addition to increasing the cost of care, the extra time required for treatment may complicate patient management for some young patients.*

CLASS III CAVITY

Carious lesions on the proximal surfaces of anterior primary teeth sometimes occur in children whose teeth are in contact and in children who have evidence of arch inadequacy or crowding. Caries involvement of the anterior primary teeth, however, may be interpreted as evidence of excessive caries activity requiring a comprehensive preventive program.

If the carious lesion has not advanced appreciably into the dentin and if removal of the caries will not involve or weaken the incisal angle, a small

conventional class III cavity may be prepared and the tooth may be restored with the dentist's choice of bonding materials.

Primary incisors with small proximal carious lesions may not require conventional restorations at all. Enameloplasty of the affected proximal surface (usually described as "disking") to open the proximal contact and remove most, if not all, of the cavitation, followed by topical fluoride varnish, will often suffice until the teeth exfoliate naturally. Extraction is usually indicated when primary incisors have extensive caries.

MODIFIED CLASS III CAVITY PREPARATION

The modified class III preparation uses a dovetail on the lingual or occasionally on the labial surfaces of the tooth. A lingual lock is normally considered for the maxillary canine, whereas a labial lock may be more conveniently prepared on the mandibular teeth, for which the aesthetic requirement is not as important. The preparation allows for the additional retention and access necessary for proper insertion of the restorative material. It is indicated for the distal surface of the primary canine in which the position of the tooth in the arch, the characteristically broad contact between the distal surface of the canine and the mesial surface of the primary molar, and the height of the gingival tissue sometimes make it difficult to prepare a typical class III cavity and restore it adequately.

CLASS IV CAVITY PREPARATION

One type of preparation used for the aesthetic restoration of primary incisors in which dental caries approximates or involves the incisal edge of the teeth. As with other operative procedures for the pediatric patient, the use of the rubber dam is helpful.

The preparation includes a proximal reduction through the incisal angle and the caries lesion, and ends at the established cervical seat. Labial and lingual locks are then prepared in the cervical third of the tooth. The remaining caries is removed, the tooth is etched, and a bonding agent is applied.

A properly placed matrix tightly wedged at the cervical seat aids the operator in placing, shaping, and holding the resin-based composite during the curing process. A good matrix also simplifies the finishing procedures. Beveling the enamel margins slightly before etching, to further improve the marginal bonding of the restoration had been recommended. Final polishing may be accomplished with the rubber cup and a fine, moist abrasive material or one of the composite polishing systems.