L .Noor Ahmed

MORPHOLOGY OF INDIVIDUAL PRIMARY TEETH

INTRODUCTION

Studying tooth morphology includes understanding the shape, configuration and parts of a tooth. It is very important for clinical application during performing various procedures. Cavity preparations must conform to the thickness of enamel and dentin, keeping in mind the location and size of the pulp. Restoration of natural contours and morphology of deciduous teeth is needed for function, which can be achieved only with a good knowledge of tooth morphology.

An accurate chronology of primary tooth calcification is of clinical significance to the dentist. It is often necessary to explain to parents the time sequence of calcification in utero and during infancy. The common observations of tetracycline pigmentation, developmental enamel defects, and generalized hereditary anomalies can be explained if the calcification schedule is known. A brief discussion of the morphology of the primary teeth is also appropriate before restorative procedures are considered for children.

MAXILLARY CENTRAL INCISOR

Labial aspect:

1. The mesiodistal diameter of the crown is greater compared to the cervicoincisal height.
2. The incisal edge is straight with sharp mesioincisal and rounded distoincisal angle.
3. The labial surface is smooth without developmental grooves or depressions
4. The mesial outline is straight whereas the distal outline is convex.

5. The mesial contact area is near the mesioincisal angle and the distal contact area is in the incisal third.
6. The root is conical with evenly tapered sides.

Lingual aspect:

1. The cingulum and marginal ridges are well developed.
2. The lingual fossa is in the incisal third of the lingual surface.

Mesial and Distal aspects:

1. The crown is wide labiolingually in the cervical third because of prominent cingulum.
2. The labial outline shows prominent cervical ridge.

Incisal aspect:

1. The labial surface is smooth
2. Lingual surface tapers towards cingulum.
3. The crown is wider mesiodistally than faciolingually.

MAXILLARY LATERAL INCISOR

1. The maxillary lateral incisor is similar to maxillary central incisor except:
2. Crown is smaller than central incisor.
3. The distoincisal angle is more rounded.
4. The crown height is greater than mesiodistal width
5. The root is longer in proportion to crown height.

MAXILLARY CANINE

Labial aspect:

1. The crown shows marked cervical constriction.
2. The mesial and distal outlines are convex.

3. Maxillary canine has a long sharp cusp with two cusp ridges meeting at an acute angle.
4. The mesial cusp slope is longer and straighter than distal cusp slope.
5. The mesial and distal contact areas are near the center of the crown cervico-occlusally.
6. The root is long, slender and tapering.
7. The root length is approximately more than twice the crown height.

Lingual aspect:

1. The lingual surface of canine shows a well-developed, prominent cingulum
2. Well-developed mesial and distal marginal ridges.
3. The lingual ridge is somewhat distal to the midline of tooth.

Mesial and Distal aspects:

1. The crown appears triangular from mesial and distal aspects.
2. The cervical third of the crown is much thicker than that of the incisors.
3. The cusp tip is labial to long axis of the tooth.
4. The cervical ridge on the labial surface is prominent.
5. The root is bulky in its middle and cervical third and tapered in the apical third.

Incisal aspect:

1. The crown outline is somewhat angular and tapers considerably towards the cingulum.
2. The mesial outline is flat, tapered, angular and thicker faciolingually than in the distal half of the crown.
3. The cingulum is centered mesiodistally.
4. The crown is faciolingually broader than incisors

MANDIBULAR CENTRAL AND LATERAL INCISOR:

1. The crowns resemble the permanent mandibular incisor but are much smaller in size.
2. The crowns have prominent labial cervical bulge
3. The roots are thin and nearly twice as long as the crowns.
4. Incisal edges are straight.
5. The distoincisal angle is rounded.
6. The mesial and distal sides taper evenly from contact areas.
7. The lingual surface shows cingulum, marginal ridges and lingual fossa.
8. The mesial aspect shows typical outline of an incisor.

MANDIBULAR CANINE:

1. There is very little difference in functional form between this tooth and maxillary canine.
2. The mesiodistal dimension of mandibular canine at root trunk is greater than mesiodistal width at contact area.
3. Mandibular canine is smaller mesiodistally than maxillary canine.
4. Mesial cusp slope is shorter than distal cusp slope.
5. Cervical ridge is less prominent than maxillary canine.

L .Noor Ahmed

MORPHOLOGY OF INDIVIDUAL PRIMARY TEETH

MAXILLARY FIRST MOLAR

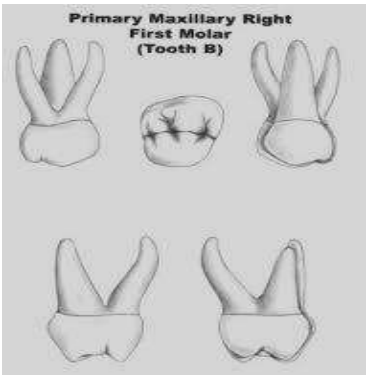

Buccal aspect

1. The occlusal outline is scalloped with no definite cusp form.
2. The crown height is more mesially than distally.
3. The crown shows marked cervical constriction.
4. The mesial outline is straight and the distal outline is convex
5. The contact area is in middle 1/3.
6. The buccal surface is smooth with little evidence of developmental grooves
7. The cervical third of crown has prominent cervical ridge
8. The three roots are thin and widely spread
9. The root trunk is short
10. The trifurcation of roots begins just below the cervical line

The lingual aspect:

1. The crown is narrower on lingual aspect
2. The general outline of the crown is similar to the buccal aspect.
3. The mesiolingual cusp is the most prominent, largest and sharpest.

4. The distolingual cusp is poorly developed.
5. All three roots are seen from this aspect.
6. The palatal root is longer and larger than others.

Mesial aspect:

1. In the cervical third the crown is much wider buccolingually than the occlusal third.
2. The crown tapers occlusally.
3. The buccal outline shows prominent cervical ridge.
4. The buccal outline is straight from the ridge to the occlusal margin.
5. The lingual outline is convex in cervical and middle thirds and straight in the occlusal third.
6. The mesial marginal ridge may show a developmental groove.
7. The root trunk is short.
8. Only palatal and mesiobuccal roots are visible from this aspect.

Distal aspect:

1. The crown is narrower buccolingually and shorter cervico-occlusally than on the mesial side.
2. The cervical ridge is less prominent than from the mesial aspect.

Occlusal aspect:

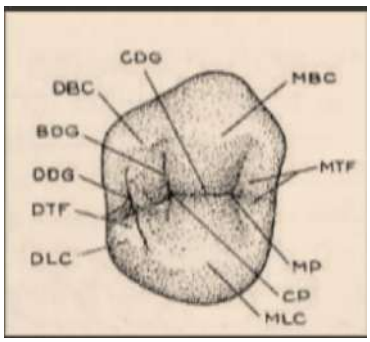

1. The occlusal surface bears four cusps: mesiobuccal, distolingual, distobuccal and mesiolingual.
2. The crown is broader buccally more than lingually and mesially more than distally.
3. The crown shows lingual and distal convergence.
4. The occlusal surface is rectangular with the short sides represented bythe marginal ridges.
5. The occlusal surface shows:

a. Central fossa

b. ▪ Central groove that connects the mesial and distal fossae, which are present just inside the mesial and distal marginal ridges respectively.

c. Buccal developmental groove separates mesiobuccal and e distobuccal cusps.

d. A well-defined triangular ridge connects mesiolingual and distobuccal cusps called as oblique ridge.

e. Supplemental grooves radiating from the central groove are present.

MAXILLARY SECOND MOLAR

Buccal aspect:

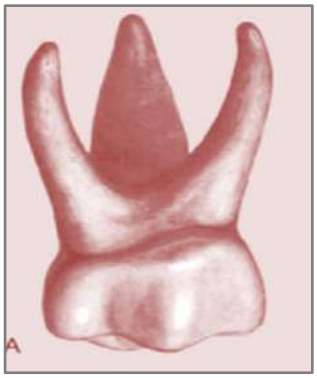

1. The primary maxillary_second molar resemble the permenant maxillary first molar, but it is smaller in size
2. The buccal view show two well define buccal cusps with buccal developmental groove in between
3. The mesial and distal outlines converge cervically from contact areas
4. All three roots are longer, and thicker as compared to the maxiallary first molar
5. The root trunk is very short

Lingual aspect:

1. The crowns shows three cusp: mesiolingual cusp,distolingual cusp and a supplemental cusp.
2. Cusp present on the lingual surface of mesiolingual cusp is called the 'tubercle of Carabelli' or fifth cusp.

Mesial and Distal aspects:

1. The buccolingual width is more as compared to crown height.
2. The mesiobuccal and lingual roots are seen from this aspect.

3. The mesiobuccal root extends far beyond the outline of the crown.
4. Buccal outline shows cervical ridge.
5. Both the buccal and lingual outlines show occlusal convergence.

Occlusal aspect:

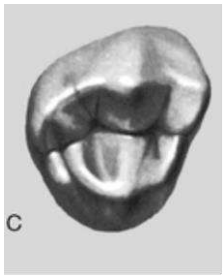

1. The tooth resembles permanent first molar.
2. The occlusal surface is rhomboidal with 4 well developed cusps i.e.mesiobuccal, distobuccal, mesiolingual and distolingual.
3. The buccal outline is flat with a developmental groove in between the cusps.
4. The occlusal surface shows:

a. Central fossa with central pit
b. Mesial triangular fossa, distal triangular fossa
c. Central groove is seen connecting mesial and distal pits.
d. The oblique ridge is prominent connecting the mesiolingual cusp with distobuccal cusp.
e. Distal to oblique ridge, distal fossa with distal groove is present.
f. The distal groove separates two lingual cusps and continues on the lingual surface as lingual developmental groove.

MANDIBULAR FIRST MOLAR

The anatomy of mandibular first molar does not resemble any tooth in permenant dentition

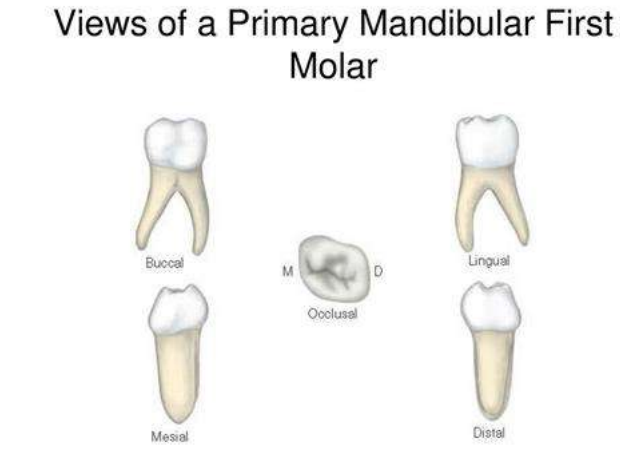

Buccal aspect:

1. The crown is wider mesiodistally
2. The mesiobuccal cusp is the largest and longest cusp.
3. The mesial outline is nearly straight whereas the distal outline is convex.
4. The mesial and distal roots are widely separated.
5. Roots are slender and the furcation is close to the cervical line.
6. Buccal surface shows a prominent cervical ridge.

Lingual aspect:

1. The crown and root converge lingually on the mesial side Part of mesial surface is visible from the lingual aspect.
2. The mesiolingual cusp is larger and longer than the distolingual cusp.
3. The lingual groove extends between two lingual cusps and ends in a depression in cervical third

Mesial aspect:

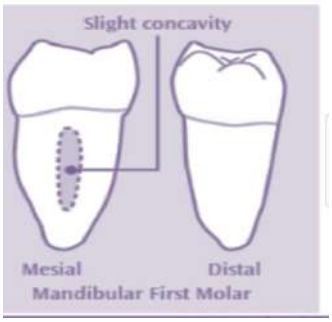

1. Buccal outline shows prominent cervical ridge.
2. ▪ the crown appears to lean towards lingual surface.
3. From cervical ridge the buccal outline is straight.
4. The mesial marginal ridge is concave is located more occlusally than distal marginal ridge.
5. The occlusal table is small buccolingually.
6. The cervical portion of the crown is quite wide in comparison (cervical convergence),
7. The mesial root is flat and squarish with a broad apex.
8. The mesial root has a depression along most of its length.

Distal aspect:

1. Buccal cervical ridge is less prominent from the distal side than from the mesial.
2. The distobuccal and distolingual cusps are nearly of the same height.
3. The distal marginal ridge is located more cervically than mesial marginal ridge.
4. The distal root is more rounded, less broad, thinner and shorter than the mesial root.

Occlusal aspect:

1. The general outline of this tooth from the occlusal aspect is rhomboidal.
2. Four cusps are present, they are mesiobuccal, mesiolingual, distobuccal and distolingual.
3. The mesiobuccal angle is acute and prominent.
4. The distobuccal angle is obtuse.
5. The crown shows lingual and distal convergence.
6. The mesiolingual cusp is the largest cusp.
7. The occlusal surface shows:
8. Transverse ridge is seen between the mesiobuccal and
9. mesiolingual cusps.
10. Buccal developmental groove divides two buccal cusps and extends from between the buccal cusps to the central pit.
11. Central developmental groove separates the mesiobuccal and mesiolingual cusps.
12. Mesial and distal fossae contain mesial and distal pits respectively.

MANDIBULAR SECOND MOLAR

• The primary mandibular second molar resembles the permanent mandibular first molar.

It is the largest tooth in the deciduous dentition.



Buccal aspect:

1. The crown is wide mesiodistally.
2. The crown appears to be tilted distally on its root base.
3. There are 3 cusps of nearly equal size, namely mesiobuccal, distobuccal and distal.
4. These cusps are separated by mesiobuccal and distobuccal grooves.
5. The roots are widely separated.
6. Root trunk is short.

Lingual aspect:

1. Mesiolingual and distolingual cusps are about the same size and height.
2. Both the cusps are separated by lingual groove.
3. Root trunk is slightly longer.

Mesial aspect:

1. Buccal outline shows a prominent mesial cervical ridge giving the crown an appearance of lingual tilt.
2. The buccal and lingual outlines converge towards the occlusal surface.

3. The mesial marginal ridge is traversed by the mesial marginal groove.

4. The mesial surface is convex and flattens cervically.

5. The mesial root is broad and flat with a shallow depression.

6. Mesial root has two root canals.

Distal aspect:

1. Crown is narrower on the distal side than on mesial.
2. Distal root is broad and has less blunt apex.
3. Distal root may have I or 2 root canals.

Occlusal aspect:

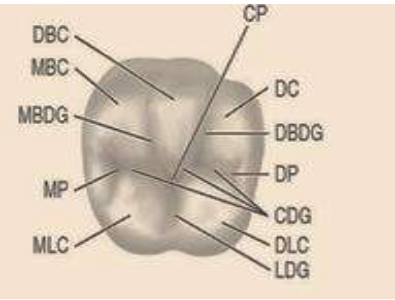

This tooth has 5 cusps with mesiobuccal cusp being the largest cusp.

Occlusal surface shows:

- Central fossa
- Mesial and distal triangular fossa
- Central groove, mesiobuccal groove, distobuccal groove and lingual groove.