College of Dentistry/University of Baghdad
Pedodontics and Preventive Dentistry Department

جامعة بغداد
كلية طب الاسنان
COLLEGE OF DENTISTRY
University of Baghdad
١٣٧٣هـ ١٩٥٣م

Pediatric Dentistry

4th Year



Lec. 4

Eruption of teeth

Assistant Professor: Aseel Haidar

Assistant Professor Aseel Haidar

Local Factors influence time of eruption

1) **Infection around the tooth:** if it is: 1. near the eruption time it will cause tearing of tissues and sometimes resorption in the area resulting in early eruption.

   2. If the infection occur before long period of time it will result in late eruption because infection for long period will healed with fibrosis in the area which aid in late eruption.

2) **Supernumerary tooth:** may be of importance in retarded the eruption.

3) **Trauma:** any trauma may cause early shedding of primary teeth, which lead to late eruption of permanent successor teeth.

4) **Gingival fibromatosis:** Hereditary gingival fibromatosis (HGF) is characterized by a slow, progressive, benign enlargement of the gingivae, which is the most common genetic form of gingival enlargement, usually has an autosomal dominant mode of inheritance. It is also referred to as elephantiasis gingiva or hereditary hyperplasia of the gum. The dense fibrous tissue often causes displacement of the teeth and malocclusion, also it may prevent eruption of teeth and treatment usually is gingivectomy.

   Note: gingival hyperplasia is an overgrowth of gum tissue around the teeth. There are a number of causes for this condition, but it's often a symptom of poor oral hygiene or a side effect of using certain medications (like what???).

5) **Ankylosed teeth:** It is aberration of tooth eruption in which the continuity of the periodontal ligament has been compromised (absence of the periodontal membrane in a small area or the whole of the root surface) and the tooth is fused to the underlying bone.

Application of the term submerged molar to this condition is inaccurate, even though the tooth may appear to be submerging into the mandible or maxilla. This misconception results from the fact that the ankylosed tooth is in a state of static retention, whereas in the adjacent areas eruption and alveolar growth continue. Ankylosis should be considered an interruption in the rhythm of eruption and that a patient who has one or two ankylosed teeth is more likely to have other teeth become ankylosed. The mandibular primary molars are the teeth most often observed to be ankylosed. In unusual cases, all the primary molars may become firmly attached to the alveolar bone before their normal exfoliation time. Ankylosis of the anterior primary teeth does not occur unless there has been a trauma. The cause of ankylosis in the primary molar areas is unknown. It may follow a familial pattern. There is a relationship between the congenital absence of permanent teeth and ankylosed

Baghdad College of Dentistry

primary teeth. Normal resorption of the primary molar begins on the inner or lingual surfaces of the roots. The resorption process is not continuous but is interrupted by periods of inactivity or rest. A reparative process follows periods of resorption. In the course of this reparative phase, a solid union often develops between the bone and the primary tooth. This intermittent resorption and repair may explain the various degrees of firmness of the primary teeth before their exfoliation. Extensive bony ankylosis of the primary tooth may prevent normal exfoliation and the eruption of the permanent successor. If ankylosis occurs early, eruption of the adjacent teeth may progress enough that the ankylosed tooth is far below the normal plane of occlusion and may even be partially covered with soft tissue. An epithelium- lined track, however, will extend from the oral cavity to the tooth. Ankylosis may occasionally occur even before the eruption and complete root formation of the primary tooth. Ankylosis can also occur late in the resorption of the primary roots and even then can interfere with the eruption of the underlying permanent tooth.

The diagnosis of an ankylosed tooth

It is not difficult to make. Because:

1. No contact with opposing molar.
2. The ankylosed tooth is not mobile, even in cases of advanced root resorption.
3. Ankylosis can be partially confirmed by tapping the suspected tooth and an adjacent normal tooth with a blunt instrument and comparing the sounds. The ankylosed tooth will have a solid sound, whereas the normal tooth will have a cushioned sound *(Why ????).*
4. The radiograph is often a valuable diagnostic aid. A break in the continuity of the periodontal membrane, indicating an area of ankylosis, is often evident radiographically.

The management of an ankylosed tooth

Early recognition and diagnosis are extremely important.

1) The eventual treatment may involve surgical removal. However, unless a caries problem is unusual or loss of arch length is evident, the dentist may choose to keep the tooth under observation.

2) A tooth that is definitely ankylosed may at some future time undergo root resorption and be normally exfoliated. When patient cooperation is good and recall periods are regular, a watchful waiting approach is best.

Baghdad College of Dentistry

3) For primary teeth: In situations in which permanent successors of ankylosed primary molars are missing, attempts have been made to establish functional occlusion using stainless steel crowns, overlays, or bonded composite resins on the affected primary molars. This treatment is successful only if the eruption of permanent teeth are still in state of active eruption they will be seen by pass the ankylosed tooth.

4) For permanent teeth: The incomplete eruption of a permanent molar may be related to a small area of root ankylosis. The removal of soft tissue and bone covering the occlusal aspect of the crown should be attempted first, and the area should be packed with surgical cement to provide a pathway for the developing permanent tooth. Unerupted permanent teeth may become ankylosed by inostosis of enamel. This process follows the irritation of the follicular or periodontal tissue resulting from chronic infection. The close association of an infected apex with an unerupted tooth may give rise to the process. In the unerupted tooth, enamel is protected by enamel epithelium. The enamel epithelium may disintegrate because of infection (or trauma), the enamel may subsequently be resorbed, and bone or coronal cementum may be deposited in its place. The result is solid fixation of the tooth in its unerupted position.

Baghdad College of Dentistry

Systemic (disease) Factors which cause late eruption

1) TRISOMY 21 SYNDROME (DOWN SYNDROME DS):

Trisomy 21 syndrome (Down syndrome [DS]): it is the presence of three number 21 chromosomes rather than the normal two (diploid). It is one of the congenital anomalies and it is characterized by:

- Delayed eruption of the teeth frequently occurs.
- The first primary teeth may not appear until 2 years of age, and the dentition may not be complete until 5 years of age.
- The eruption often follows an abnormal sequence, and some of the primary teeth may be retained until 15 years of age.

DS occurs very early in embryonic development, possibly during the first cell divisions. Anomalies of the eye and external ear are seen, and congenital heart defects are often present. The occurrence of DS is frequently related to maternal age.

The diagnosis of DS

In a child is not usually difficult to make because of the characteristic facial pattern:

1. The orbits are small, 2. The eyes slope upward, 3. The bridge of the nose is more depressed than normal. 4. The formation of the external ear, characterized by outstanding "lap" ear with flat or absent helix. 5. Intellectual disability is another characteristic finding, with most children in the mild to moderate range of disability 6. Retardation in the growth of the maxillae and mandible was evident in those with DS. Both the maxillae and mandible were positioned anteriorly under the cranial base. 7. The upper facial height was found to be significantly smaller. 8. The midface was also found to be small in the vertical and horizontal dimensions. 9. The smaller jaws contribute to a tendency for protrusion of the tongue and dental crowding, both of which may compromise the development of good occlusion. 10. The tongue also tends to be larger than normal. 11. Abnormalities of the immune response in children with DS are responsible for their greater susceptibility to oral mucosal disease. 12. Individuals with DS have a higher prevalence of periodontal disease mainly in the anterior region. However, susceptibility to dental caries is low for both primary and permanent teeth.

Baghdad College of Dentistry

Many children with DS have chronic inflammation of the conjunctiva and a history of repeated respiratory tract infections. The use of antibiotics has reduced the incidence of chronic infection and has resulted in fewer deaths from infection.

2) CLEIDOCRANIAL DYSPLASIA

A rare congenital syndrome that has dental significance is cleidocranial dysplasia (CCD), which has also been referred to as cleidocranial dysostosis,

The diagnosis is based on the finding of an absence of clavicles, although there may be remnants of the clavicles, as evidenced by the presence of the sternal and acromial ends. 2. The fontanels are large, and radiographs of the head show open sutures, even late in the child's life. 3. The sinuses, particularly the frontal sinus, are usually small. 4. The development of the dentition is delayed. Complete primary dentition at 15 years of age, resulting from delayed resorption of the deciduous teeth and delayed eruption of the permanent teeth, is not uncommon. 5. One of the important distinguishing characteristics is the presence of supernumerary teeth. Some children may have only a few supernumerary teeth in the anterior region of the mouth; others may have a large number of extra teeth throughout the mouth. Even with removal of the primary and supernumerary teeth, eruption of the permanent dentition (without orthodontic intervention), is often delayed and irregular.

- Delayed eruption has also been reported in other forms of osteopetroses.

3) HYPOTHYROIDISM

Hypothyroidism is another possible cause of delayed eruption. Patients in whom the function of the thyroid gland is extremely deficient have characteristic dental findings.

Congenital Hypothyroidism (Cretinism)

Occurring at birth and during the period of most rapid growth, if undetected and untreated, causes mental deficiency and dwarfism. This condition was referred to as cretinism. Congenital hypothyroidism is the result of an absence or underdevelopment of the thyroid gland and insufficient levels of thyroid hormone.

- Child with congenital hypothyroidism is:
- A small and disproportionate person, with abnormally short arms and legs.
- His head is disproportionately large, although the trunk shows less deviation from the norm.
- Obesity is common.

If the child does not have adequate hormonal therapy:

- The dentition of the child will be delayed in all stages, including eruption of the primary teeth, exfoliation of the primary teeth, and eruption of the permanent teeth.
- The teeth are normal in size but are crowded in jaws that are smaller than normal.

Baghdad College of Dentistry

The tongue is large and may protrude from the mouth. The abnormal size of the tongue and its position often cause an anterior open bite and flaring of the anterior teeth. Tooth crowding, malocclusion, and mouth breathing cause a chronic hyperplastic type of gingivitis.

Juvenile Hypothyroidism (Acquired Hypothyroidism)

It results from a malfunction of the thyroid gland, usually between 6 and 12 years of age. Because the deficiency occurs after the period of rapid growth, the unusual facial and body patterns characteristic of a person with congenital hypothyroidism are not present. However, obesity is evident to a lesser degree. In untreated juvenile hypothyroidism, delayed exfoliation of the primary teeth and delayed eruption of the permanent teeth are characteristic. A child with a chronologic age of 14 years may have a dentition in a stage of development comparable with that of a child 9 or 10 years of age.



The clinical feature a fourteen years old girl with juvenile hypothyroidism.



X-ray for a fourteen years old girl with juvenile hypothyroidism.

Baghdad College of Dentistry

4) HYPOPITUITARISM

A pronounced deceleration of the growth of the bones and soft tissues of the body will result from a deficiency in secretion of the growth hormone. Pituitary dwarfism is the result of an early hypofunction of the pituitary gland. Again, early diagnosis is routine because of the mandatory blood screening of newborn infants for congenital hypothyroidism. An individual with pituitary dwarfism is well proportioned, but he resembles a child of considerably younger chronologic age.

Orally:

- The dentition is essentially normal in size.
- Delayed eruption of the dentition is characteristic.
- In severe cases, the primary teeth do not undergo resorption but instead may be retained throughout the life of the person. 6. The underlying permanent teeth continue to develop but do not erupt.
- Extraction of the deciduous teeth is not indicated because eruption of the permanent teeth cannot be ensured.
- Some degree of cognitive disability often occurs, so that this child may need special dental management.

5) ACHONDROPLASTIC DWARFISM

It is easily diagnosed at birth, demonstrates a few characteristic dental findings. Many children die during first year of life. Growth of the extremities is limited because of a lack of calcification in the cartilage of the long bones. Stature improvements have been reported with surgical lengthening of the limbs and also with growth hormone therapy. The head is disproportionately large, although the trunk is normal in size. The fingers may be of almost equal length, and the hands are plump. The fontanels are open at birth. The upper face is underdeveloped, and the bridge of the nose is depressed. The etiology of achondroplastic dwarfism is unknown, it is clearly an autosomal-dominant disorder. There is some evidence that the condition is more likely to occur when the ages of the parents differ significantly. In contrast to DS, the increased age of the father may be related to the occurrence of the condition.

Baghdad College of Dntistry

Oral conditions

- Deficient growth in the cranial base is evident in many individuals with achondroplastic dwarfism.
- The maxilla may be small, with resultant crowding of the teeth and a tendency for open bite.
- Chronic gingivitis is usually present. However, this condition may be related to the malocclusion and crowding of the teeth.
- The development of the dentition was slightly delayed.

6) OTHER CAUSES

Delayed eruption of the teeth has been linked to other disorders, including fibromatosis gingivae, chondroectodermal dysplasia (Ellis-van Creveld syndrome), Gardner syndrome, familial hypophosphatemia, and rickets.

The effect of bisphosphonate therapy on children with osteogenesis imperfecta:

- Bisphosphonates inhibit the ability of osteoclasts to resorb bone. Indeed, children with osteogenesis imperfecta treated with bisphosphonates had an associated delay in tooth eruption.

Deciduous Dentition Period

The initiation of primary teeth occur during first 6 week of IUL and the first primary tooth erupts at the age of 6 months. It takes around 2 ½ to 3 ½ years for all the primary teeth to establish their occlusion.

Ugly Duckling Stage

Also called Broadbent phenomenon, a self-correcting malocclusion is seen around 9-11 years of age or during eruptions of canine. As the permanent canines erupt, they displace the roots of lateral incisors mesially. This force is transmitted to the central incisors and their roots are also displaced mesially. Thus, the resultant force causes the distal divergence of the crown in an opposite direction, leading to midline spacing (diastema in the incisor region). The term ugly duckling stage indicates the anesthetic appearance of the child during this stage. This condition corrects itself after the canines have erupted when it apply pressure on the crowns of the incisors thereby causing them to shift back to original positions. No orthodontic treatment should be

Baghdad College of Dntistry

attempted at this stage, as there is danger of deflecting the canine from its normal path of eruption.

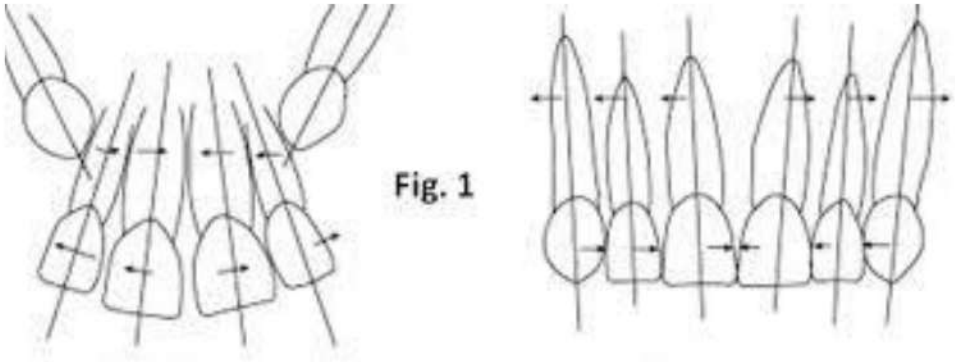

Fig. 1

a. The ugly duckling stage

b. Final anterior alignment

Baghdad College of Dntistry

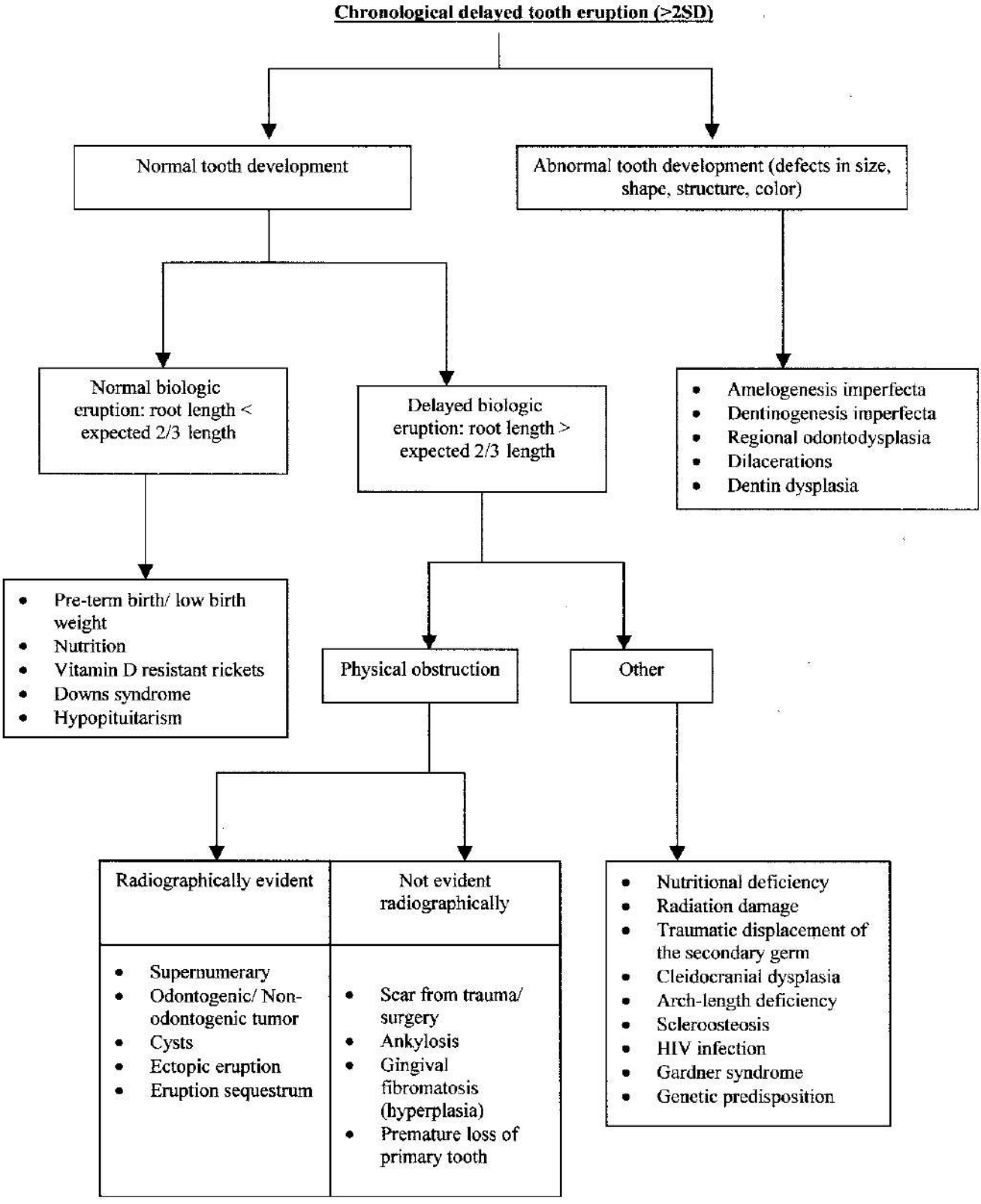

A diagnostic algorithm for Delay teeth eruption