College of Dentistry/University of Baghdad

Pedodontics and Preventive Dentistry Department

جامعة بغداد

كلية طب الاسنان

COLLEGE OF DENTISTRY

University of Baghdad

Pediatric Dentistry

4th Year

Lec. 3

Eruption of teeth

Assistant Professor

Aseel Haidar

Assistant Professor Aseel Haidar

ERUPTION HEMATOMA (ERUPTION CYST)



An eruption hematoma is a bluish-purple elevated area of tissue occasionally develops a few weeks before the eruption of a primary or permanent tooth. It may result from trauma to the area during function and then hemorrhage in the follicle of an erupted tooth and it will subside after eruption after breakage of the soft tissue by the tooth. The blood-filled cyst is most frequently seen in the primary second molar or the first permanent molar region (6 and E). Because the condition is almost always self-limiting, treatment of an eruption hematoma is rarely necessary. However, surgical uncovering of the crown may occasionally be justified. When the parents discover an eruption hematoma, they may fear that the child has a serious disease such as a malignant tumor. The dentist must be understanding and sensitive to their anxiety while reassuring them that the lesion is not serious.

ERUPTION SEQUESTRUM



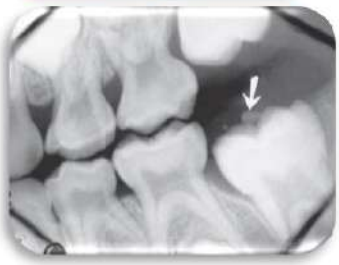

The eruption sequestrum is occasionally seen in children at the time of the eruption of the first permanent molar (6). Clinically it is appear as a tiny spicule of nonviable bone overlying the crown of an erupting permanent molar just before or immediately after the emergence of the tips of the cusps through the oral mucosa. It is composed of dentin and cementum as well as a cementum-like material formed within the follicle.

Eruption sequestra are usually of little or no clinical significance. It is probable that some of these sequestra spontaneously resolve without noticeable symptoms. However,

Baghdad College of Dentistry

after an eruption sequestrum has surfaced through the mucosa, it may easily be removed if it is causing local irritation. The base of the sequestrum is often still well embedded in gingival tissue when it is discovered, and application of a topical anesthetic or infiltration of a few drops of a local anesthetic may be necessary to avoid discomfort during removal.

ECTOPIC ERUPTION

A variety of local factors may influence a tooth to erupt or try to erupt in an abnormal position such as arch length inadequacy and tooth mass redundancy. Occasionally this condition may be so severe that actual transposition of teeth takes place. First permanent molars may be positioned too far mesially in their eruption path, with resultant ectopic resorption of the distal root of the second primary molar.



There are two types of ectopic eruption— reversible and irreversible. In the reversible type, the molar frees itself from the ectopic position and erupts into normal alignment, with the second primary molar remaining in position while in the irreversible type, the maxillary first molar remains unerupted and in contact with the cervical root area of the second primary molar. By the ages of 7 and 8 years, any ectopic eruption of a permanent first molar should be considered irreversibly locked.

The ectopic molar often occurred in more than one quadrant and was most often observed in the maxilla.



Irreversible ectopic molars that remain locked, if untreated, can lead to premature loss of the primary second molar with a resultant decrease in quadrant arch length, asymmetric shifting of the upper first molar toward Class II positioning, and supraeruption of the opposing molar with distortion of the lower curve of Spee and potential occlusal interference. Early assessment with intraoral or panoramic films approximating the timing of first permanent molar eruption is thus critical to identification of the problem and provides an opportunity to intercept potential sequelae. If the problem is detected at 5 to 6 years of age, an observation approach of "watchful waiting" with appropriate monitoring may be indicated, given the two-thirds potential for self-correction. With self-correction being unlikely as the child

Baghdad College of Dentistry

approaches 7 years of age, continued "locking" of the first molar with advanced resorption of the primary second molar usually warrants intervention. Another timing clue is that when the opposing molar reaches the level of the lower occlusal plane, intervention is indicated to establish proper vertical control and prevent supraeruption.

Early Eruption

(NATAL AND NEONATAL TEETH)

The prevalence of natal teeth, which are the teeth present at birth, and neonatal teeth, which are those teeth that erupt during the first 30 days, is low. About 85% of natal or neonatal teeth are mandibular primary incisors, and only small percentages are supernumerary teeth. It is common for natal and neonatal teeth to occur in pairs. Natal and neonatal molars are rare. They had also been described in the literature as "congenital teeth", "fetal teeth". Most studies suggested that the etiology for the premature eruption or the appearance of natal and neonatal teeth is multifactorial. A possible factor involving the early eruption of primary teeth seems to be familial, due to inheritance as an autosomal-dominant trait.

Most premature tooth eruption seems to occur in otherwise normal infants, with or without a family history of the condition. In some infants, however, the presence of such teeth may be a localized manifestation of various environmental causes or an underlying syndrome, with the most common being Ellis-van Creveld syndrome, Hallermann-Streiff syndrome, Pierre Robin syndrome, and Sotos syndrome. This underscores the importance of thorough diagnostic evaluations of infants with natal or neonatal teeth.

Baghdad College of Dentistry

A radiograph should be made to determine the amount of root development and the relationship of a prematurely erupted tooth to its adjacent teeth. One of the parents can hold the x-ray film in the infant's mouth during the exposure.

Most prematurely erupted teeth (immature type) are hypermobile because of limited root development. 1. If the tooth is extremely mobile to the extent that there is danger of displacement of the tooth and possible aspiration, so the treatment indicated in such a case is the removal of the tooth. 2. If the tooth has sharp incisal edge that may cause laceration of the lingual surface of the tongue, so treatment is the removal of the tooth.

The preferable approach, however, is to leave the tooth in place and to explain to the parents the desirability of maintaining this tooth in the mouth because of its importance in the growth and uncomplicated eruption of the adjacent teeth. Within a relatively short time, the prematurely erupted tooth will become stabilized, and the other teeth in the arch will erupt.

Eruption of teeth during the neonatal period presents less of a problem. These teeth can usually be maintained even though root development is limited.

A retained natal or neonatal tooth may cause difficulty for a mother who wishes to breast-feed her infant. If breast-feeding is too painful for the mother initially, the use of a breast pump and bottling of the milk are recommended. However, the infant may be conditioned not to "bite" during suckling in a relatively short time if the mother persists with breast-feeding. It seems that the infant senses the mother's discomfort and learns to avoid causing it.



Baghdad College of Dentistry

What is this lesion?



EPSTEIN PEARLS, BOHN NODULES, AND DENTAL LAMINA CYSTS

Small, white or grayish-white lesions on the alveolar mucosa of the newborn may be incorrectly diagnosed as natal teeth. The lesions are usually multiple but do not increase in size. No treatment is indicated because the lesions are spontaneously shed a few weeks after birth.

1. ***Epstein pearls*** *are formed along the midpalatine raphe. They are considered remnants of epithelial tissue trapped along the raphe as the fetus grew.*



Epstein pearls

Baghdad College of Dentistry

2. ***Bohn nodules*** *are formed along the buccal and lingual aspects of the dental ridges and on the palate away from the raphe. The nodules are considered remnants of salivary gland tissue and are histologically different from Epstein pearls.*

3. ***Dental lamina cysts*** *are found on the crests of the maxillary and mandibular dental ridges. The cysts apparently originated from remnants of the dental lamina.*

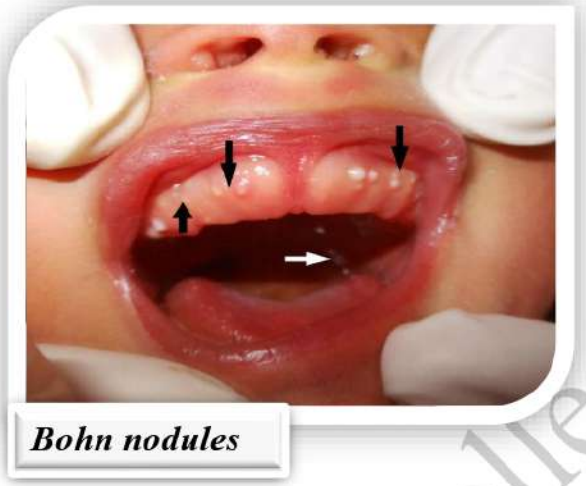

Bohn nodules



Dental lamina cyst

Baghdad College of dentistry

Shedding of the primary teeth

The human dentition like those of most mammals consists of two generations. The first generation is known as the deciduous or primary dentition and the second as the permanent dentition. The need and the necessity of two dentitions exists because: 1. Infant jaws are small and the size and number of teeth they can support is limited. 2. Since the teeth, once formed, cannot increase in size, a second dentition, consisting of larger and more teeth, is required for the larger jaws of the adult. **The physiological process resulting in the elimination of the deciduous dentition is called shedding or exfoliation**.

Pattern of Shedding

The result of progressive resorption of the roots of teeth and their supporting tissues is the shedding of deciduous teeth. In general, the pressure generated by the growing and erupting permanent tooth dictates the pattern of deciduous tooth resorption.

Resorption of Anterior teeth

The permanent anterior tooth germ position is lingual to the apical third of the roots of the primary tooth hence the resorption is in the occluso-labial direction, which corresponds to the movements of the permanent tooth germ. Later the resorption proceed horizontally because the crown of the permanent tooth lies directly apical to the root of primary tooth, and this horizontal resorption allows the permanent tooth to erupt into the position of the primary tooth.

Resorption of Posterior teeth

Initially, the growing crowns of the premolars are situated between the roots of the primary molars, so the root resorption of the posterior primary teeth will started at the inter-radicular bone area followed by resorption of the adjacent surfaces of the root. Meanwhile, the alveolar process is growing to compensate for the lengthening roots of the permanent tooth. As this occurs, the primary molars move occlusally, which allows the premolars crowns to be more apical. The premolars continue to erupt until the primary molars roots are entirely resorbed and the teeth exfoliate. The premolars then appear in place of the primary molars.

Remnants of Deciduous teeth

Sometimes parts of the deciduous teeth that are not in the path of eruption remain embedded in the jaw for a considerable time. They are most frequently associated with permanent premolars because the roots of the lower second deciduous molars are strongly

Baghdad College of Dentistry

curved or divergent. When they are close to the surface of the jaw, they may ultimately be exfoliated. Progressive resorption of the root remnants and replacement by bone may cause the disappearance of these remnants.

Retained Deciduous Teeth

They may retained for a long period of time beyond their usual shedding schedule. Such teeth are usually without permanent successor, or their successors are impacted. Retained deciduous teeth are most often the upper lateral incisor, less frequently the mandibular second primary molars and rarely the lower central incisors. If permanent tooth is ankylosed or impacted, its deciduous predecessors may also be retained.

Factors causes differences in time of eruption

1. Genetic factor: teeth eruption is a localized, genetically programmed event. Genes play a definite role in tooth eruption so that eruption failure is often attributed to genetic factors.

2. Sex: It is observed that the teeth of girls erupt slightly earlier than those of boys. Initially during the formation stage, there was no sex difference up to the stage of calcification, and the difference begins only from the crown completion stage.

3. Socioeconomic conditions: Retarded eruption of anterior teeth and accelerated emergences of the posterior dentition has been linked to low socioeconomic status in all racial groups. In another hand, children from good socioeconomic level erupt their teeth earlier because of their good nourishment and health.

4. Birth weight: Low birth weight has been associated with delayed emergence of permanent teeth and conversely early eruption has been associated with increased birth weight.

Baghdad College of Dentistry

5. Systemic disorders: Precocious (earlier) eruption is rare and is observed less commonly than retarded (delayed) eruption. Delay in permanent tooth eruption is associated with some syndromes like Down's syndrome, cleidocranial dysostosis, hypothyroidism, hypopituitarism and hemifacial atrophy. While precocious eruption is seen in precocious puberty, hyperthyroidism, hemifacial hypertrophy, Sturge-Weber syndrome and hyperpituitarism.

6. Hormones and vitamins: Disturbance of the endocrine glands usually has a profound effect on the entire body, including the dentition. Thyroid, pituitary [growth hormone], and parathyroid hormones are essential for normal eruption of teeth. Vitamins like vitamin B complex, A, C and D aid either directly or indirectly for tooth eruption.

7. Local causes: Ankylosis of primary teeth delays the eruption of permanent tooth. Dental caries and periapical infection of primary teeth resulted in early eruption of the corresponding permanent tooth. Very early extraction of a primary molar delays the eruption of the successor.

8. Race: Negro teeth erupted earlier than white people did.

9. Environment: industrialized countries children erupt their teeth later than rural area because industrialized countries children eat ready food than the developing countries who eat raw food.

10. Nutrition and growth: good nutrition lead to good growth, which lead to early eruption of teeth. A positive correlation between body height and weight and teeth emergence has been found. The taller and heavier children are slightly advanced dentally while it is apparent that stunting (retarded linear growth) is more strongly associated with delayed tooth eruption.

Baghdad College of Dentistry