Periodontal regeneration

New attachment and guided tissue regeneration GTR

Aspects of periodontal healing or periodontal treatment outcomes:

1. Regeneration.
2. Repair
3. New attachment.

I. **Regeneration:** is the growth and differentiation of new cells and intercellular substances to form new tissues. It occurs by growth from the same type of tissue that has been destroyed or from its precursor.

In the periodontium:

1. Gingival epithelium is replaced by epithelium.
2. Connective tissue, PDL., bone & cementum all are derived from connective tissue, undifferentiated connective tissue cells develop into fibroblasts, osteoblast and cementoblasts.

Regeneration under normal conditions:

Regeneration of the periodontium is a continuous physiologic process, new cells and tissues are continuously being formed to replace mature and dead cells, this is termed "wear and tear repair".

Regeneration during destructive periodontal disease:

Most gingival and periodontal diseases are chronic inflammatory conditions, i.e, they are healing processes and regeneration is part of healing. However, bacteria and bacterial products are injurious to the regenerating cells and tissues. They prevent the healing from proceeding to completion, but, when bacterial plaque is removed and prevented from new formation by periodontal treatment, the inherent regenerative capacity of tissues is established.

II. **Repair**: restoration of the continuity of the diseased marginal gingiva and re-establishment of a normal gingival sulcus at the same level as the base of a preexisting pocket, it is called (healing by scar), bone loss is arrested with mobilization of epithelial

and connective tissue cells into the damaged area with increase mitotic division to provide a sufficient number of cells.(long junctional epithelium)

III. **New attachment**: is the embedding of new PDL. Fibers into new cementum and attachment of epithelium to a tooth surface previously denuded by disease. The term reattachment was used in the past to represent the restoration of the marginal periodontium, but because it is not the existing fibers that reattach but new fibers that are formed and attach to new cementum, the term was changed to new attachment.

Reattachment: refer to repair in areas of the root not previously exposed to the pockets, but after surgical detachment of the tissues or after traumatic tears in cementum, tooth fractures, or treatment of periapical lesion.

Epithelial adaptation: close apposition of the gingival epithelium to the tooth surface without complete obliteration of the pocket, it may be as resistant to disease as true connective tissue attachments. 4-5mm. depth with absence of bleeding or secretion on probing post therapy may be acceptable. This may indicate that the "deep sulcus" persists in an inactive state.

Regeneration of PDL is the basis for new attachment because:

1) PDL provides continuity between the alveolar bone and cementum.
2) PDL contains cells that can synthesize and remodel the 3 connective tissues of the periodontium.

The possible outcomes of therapy:

During healing stages of a periodontal pocket, the area is invaded by cells from 4 different sources which modify the final outcome of pocket healing:

1. Oral epithelium: if epithelium proliferates along the tooth surface before the other tissues reach the area, the result will be a long junctional epithelium.
2. Gingival connective tissue: if the cells from the gingival connective tissue are the first to populate the area, the result will be fibers parallel to the tooth surface and remodeling of the alveolar bone, with no attachment to the cementum (recurrence of pocket).
3. Bone. If bone cells arrive first, root resorption and ankylosis may occur.

4. Periodontal ligament: when cells from PDL proliferate coronally, there is new formation of cementum and PDL (new attachment). Which is the ideal outcome of periodontal therapy as it will obliterate the pocket and reconstitute the marginal periodontium.

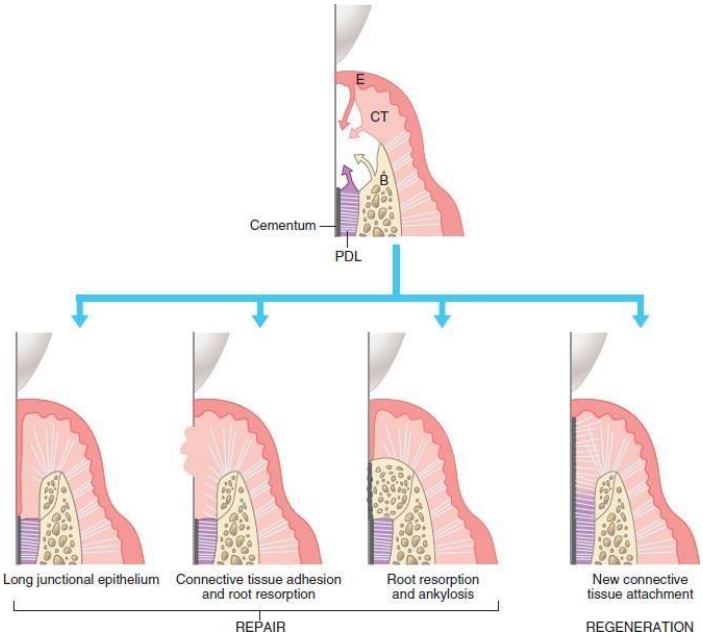

Evaluation of new attachment and bone regeneration:

1) **<u>Clinical methods:</u>** comparison of pre and post treatment records of:
    a. Pocket probing.
    b. Attachment level
    c. Gingival indices
    d. Bone level.

A-pocket probing

The periodontal pocket is a soft tissue change; therefore it is not detected by radiographic examination, but by careful exploration with a periodontal probe.

The probing depth is the depth of penetration of a probe in a pocket (the distance from gingival margin to the apical extent of periodontal probe) that depends on factors such as the size of the

probe, the force with which it is introduced, the direction of penetration, the resistance of the tissues and the convexity of the crown. The probe tip penetrates to the most coronal intact fibers of the connective tissue attachment apical to the junctional epithelium about 0.3mm, reduction of this penetration after treatment may be a result of reduced inflammatory response rather than gain in attachment.

BIOLOGIC WIDTH ANATOMY

In the human body, ectodermal tissue serves to protect against invasion from bacteria and other foreign materials. However, both teeth and dental implants must penetrate this defensive barrier. The natural seal that develops around both, protecting the alveolar bone from infection and disease, is known as the biologic width. The biological width is defined as the dimension of the soft tissue, which is attached to the portion of the tooth coronal to the crest of the alveolar bone. This term was based on the work of Gargiulo *et al*., who described the dimensions and relationship of the dentogingival junction in humans. They established that there is a definite proportional relationship between the alveolar crest, the connective tissue attachment, the epithelial attachment, and the sulcus depth. They reported the following mean dimensions: A sulcus depth of 0.69 mm, an epithelial attachment of 0.97 mm, and a connective tissue attachment of 1.07 mm. Based on this work, the biologic width is commonly stated to be 2.04 mm, which represents the sum of the epithelial and connective tissue measurements

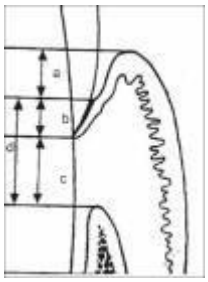

(a) Histological sulcus (0.69 mm), (b) Epithelial attachment (0.97 mm), (c) Connective tissue attachment (1.07 mm), (d) Biologic width (b+c)

B-Attachment level:

Is the distance between the base of the pocket and a fixed point on the crown, such as the cemento-enamel junction, it is measured by a periodontal probe. Clinical determinations of attachment level are more useful than pocket depths, because the latter may change due to displacement of the gingival margin and degree of inflammation, while changes in the level of attachment can be due only to gain or loss of attachment, this gives better indication for the degree of periodontal destruction. Shallow pockets attached at the level of the apical third

of the root represents more sever destruction than deep pockets attached at the coronal third of the roots.

- When the gingival margin is located at the level of CEJ the loss of attachment equals the pocket depth.
- When the gingival margin is located apical to the CEJ. The loss of attachment will be greater than the pocket depth, and therefore the distance between the CEJ and the gingival margin should be added to the pocket depth to measure loss of attachment.
- When the gingival margin is located on the anatomic crown, the pocket depth will be greater than loss of attachment and therefore the distance between gingival margin and CEJ is subtracted from the pocket depth to measure level of attachment.

Measurement should be reproducible, this can be performed by the use of (a grooved acrylic stent)

C- Gingival indices:

The gingival index of Loe and Silness(1963) and the Sulcus Bleeding Index of Muhlemann and Son(1971) are the most useful in clinical evaluation of gingival health before and after treatment.

D-Alveolar bone level:

Is evaluated clinically by (trans-gingival probing) after anaesthetizing the area. It determines the height and contour of the facial and lingual bones obscured on the radiograph by the dense roots. The architecture of the interdental bone also can be evaluated.

2-Radiographic methods:

standardized technique is needed for reproducible positioning of the film and the tube, even though, this technique is less reliable than clinical probing technique, because a sufficient loss should take place at the alveolar crest to be recognized radiographically (not sensitive).

3-Surgical re-entry:

Evaluation can be performed by taking repeated impression. This can give a good view of the state of the bone crest that can be compared with the view taken during the initial surgical intervention. This method has 2 disadvantages:

a. Requires unnecessary 2nd operation.
b. Does not show the type of attachment if it is new attachment or long junctional epithelium.

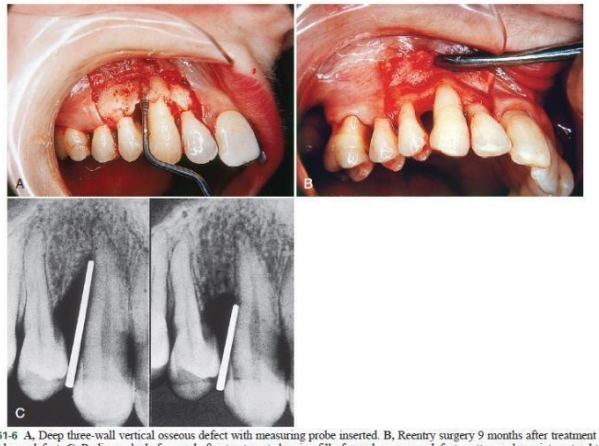

ıre 61-6 A, Deep three-wall vertical osseous defect with measuring probe inserted. B, Reentry surgery 9 months after treatment shows ared bone defect. C, Radiographs before and after treatment showing fill of angular osseous defect; gutta percha points extend to base

4-Histologic methods:

Type of attachment can be determined only by histologic analysis of tissue blocks obtained from the healed area. Animal studies can be used because this method needs extraction of the examined tooth with its periodontium after successful treatment, therefore it's not used in humans.

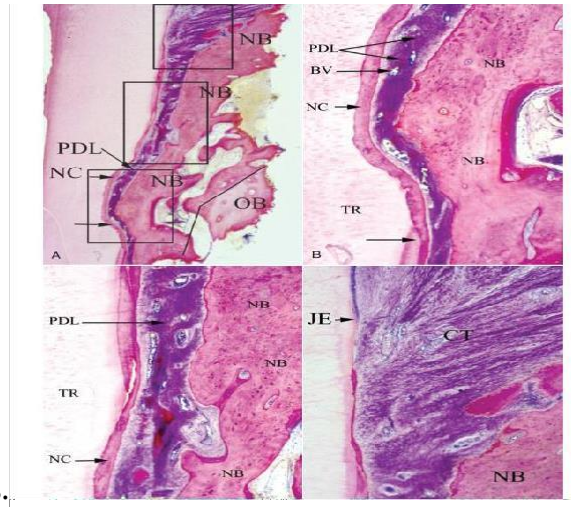

Reconstructive surgical techniques:

Can be divided into two major approaches:

I. Non- bone graft associated new attachment.
II. Bone Graft associated new attachment or combination of both approaches.

I. Non-bone graft associated new attachment:

New attachment is more likely to occur when the destructive process has occurred very rapidly e.g after treatment of pockets with acute periodontal abscess, acute necrotizing ulcerative gingivitis ANUG.

Non–Graft-Associated Procedures

Removal of Junctional and Pocket Epithelium.
Junctional and pocket epithelium has been perceived as a barrier to successful therapy because its presence interferes with the direct apposition of connective tissue and cementum, thus limiting the height to which periodontal fibers can insert to the cementum. Several methods have been recommended to remove the junctional and pocket epithelium. These include curettage, chemical agents, ultrasonics, lasers, and surgical techniques.

Preventing or Impeding the Epithelial Migration. As with coronally displaced flap

Clot Stabilization, Wound Protection, and Space Creation.
Preservation of the root surface fibrin clot interface prevents apical migration of the gingival epithelium and allows for connective tissue attachment during the early wound-healing period. The importance of space creation for bone repair has long been recognized in orthopedic and maxillofacial surgery.

Laser-Assisted New Attachment Procedure. The
Role of laser in periodontal therapy remains controversial . Nevertheless, the use of neodymium : yttriumaluminum-garnet (Nd : YAG) to perform surgical LANAPs has been reported for the management of chronic periodontitis and can potentially result in new attachment and periodontal regeneration

Many questions remain about LANAP that need to be clarified. The first is the exact mechanism and parameter by which healing by new attachment versus regeneration occur with LANAP therapy. Additionally, a blinded split mouth study to compare LANAP protocol to other existing periodontal therapies is in progress and needs to be completed. This along with other randomized controlled trials will be needed for meta-analysis to determine if LANAP is equivalent or superior to other conventional therapy. As with all periodontal therapy, the long-term stability of the regeneration need to be explored.

****Guided Tissue Regeneration.*** GTR is used for the prevention of epithelial migration along the cemental wall of the pocket and maintaining space for clot stabilization. this method is based on the assumption that periodontal ligament and perivascular cells have the potential for regeneration of the attachment apparatus of the tooth.* GTR consists of placing barriers of different types (membranes) to cover the bone and periodontal ligament, thus temporarily separating them from the gingival epithelium and connective tissue. Excluding the epithelium and the gingival connective tissue from the root surface during the postsurgical healing phase not only prevents epithelial migration into the wound but also favors repopulation of the area by cells from the periodontal ligament and the bone.

Guided periodontal regeneration

Generation 1= GTR (guided tissue regenerative membrane).

Generation 2= Biomaterials as EMD (enamel matrix derivative protein), BMP (bone morphogenic protein), PRP (plasma rich protein).

Generation 3= Growth factors, stem cells, tissue engineering.

Regenerative procedures

Periodontal regenerative procedures used to improve:

1. Local gingival architecture.
2. Function.
3. Prognosis of periodontitis involved teeth.

The intrabony defect (infrabony) could be classified according to the number of surrounding bone walls into:

1. One-wall defect.
2. Two-wall defect.
3. Three-wall defect.

The authors reported that new attachment had occurred in 2-wall and 3-wall defect but not in 1-

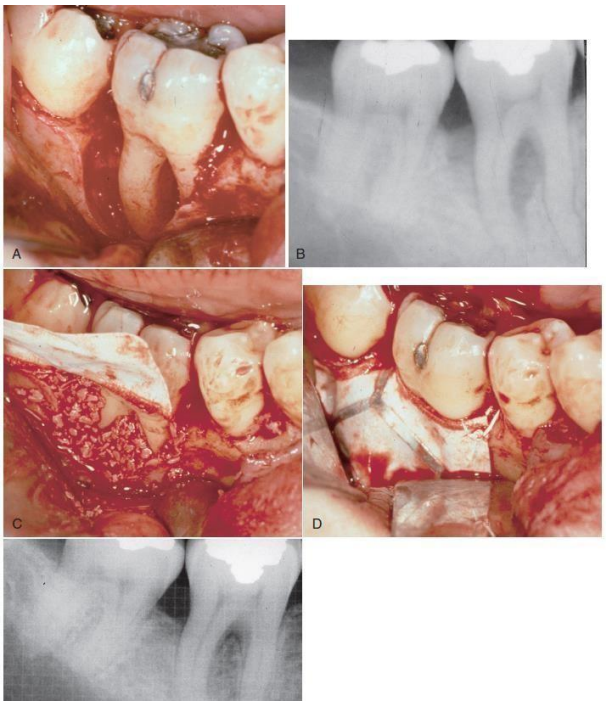

wall defect.

Principles of non-graft new attachment*: are based on*

1. Complete removal of all irritants with or without exposure of the area with a flap.
2. Occlusal adjustment may be indicated if there is trauma from occlusion.
3. Removal of the junctional and pocket epithelium: because it is a barrier to successful therapy due to interference with direct apposition of connective tissues and cementum limiting the height of insertion of periodontal fibers to cementum. Several methods have been recommended to remove junctional and pocket epithelia. These include curettage, chemical agents, ultrasonic methods,laser and surgical techniques. Because of lack of control over the first four methods, they are not currently use. Surgical techniques are recommended (the excisional new attachment procedure): consists of internal bevel incision with a surgical knife, which is performed either without flap but after carful scaling and root planning , an interproximal sutures are used to close the wound or it use with flap as now by the modified Widman flap operation.
4. Prevention of epithelial migration along the cemental wall of the pocket by guided tissue regeneration (GTR) which is the placement of barriers of different types to cover the bone and periodontal ligament excluding the epithelium and the gingival connective tissue from the root surface permit only PDL and bone cells to repopulate the area and aid in tissue expantion.

   Two types of membranes have been used:

A. Non-degradable (non resorbable): the one used clinically is the polytetra-fluoroethylene membrane (Gore-Tex) which can be obtained in different shapes and sizes to suit proximal spaces, facial and lingual surfaces of furcations, it must be removed after the initial healing stages (3-6 weeks).
B. Biodegradable (resorbable) membranes: are resorbed and therefore do not require a second intervention. These membranes include different resorbable materials: derived either from:

- Porcine collagen.
- Cecum of an ox.

- Polylactic acid.
- Synthetic skin (Biobrane).
- Freeze-dried dura mater.

The resorbable membranes resorbs at different periods as 4-18 weeks; 6-14 months.

Some studies use membranes with autogenic bone graft for better results especially in grade II furcation, or in interdental defect.

GTR disadvantages

- Non-resorbable
    A. 2nd surgery required after initial stage of healing 3-6 weeks
    B. Exposure to oral environment
    C. Bacterial contamination
    D. Failure of collapse.
- Resorbable
    A. Risk of exposure.
    B. Collapse into the defect area (bone filler is needed).
    C. Technical difficulties.
    D. Harmful degradation products of synthetic membranes.

5. Preparation of the root surface: changes in the root surface of periodontal pockets that interfere with new attachment are degeneration of remnants of sharpey's fibers, accumulation of bacteria and their product and disintegration of the cementum and dentin.

    These obstacles can be eliminated by thorough root planning but there are several substances can give better conditioning of the root surface for attachment of new connective tissue fibers, these include: 1.citric acid 2.fibronectin 3.tetracycline.

1. Citric acid: application of citric acid at PH=1 for 2-3 or 5 minutes on planed root surfaces produced a surface demineralization that induced cementogensis and attachment of collagen fibers with prevention of apical epithelial migration along denuded roots.

2. Fibronectin: is a glycoprotein needed by fibroblasts to attach to root surface, addition of fibronectin locally but at the same level as that present in plasma may promote new attachment.
3. Tetracycline:(in vitro) it increases binding of fibronectin which in turn stimulates fibroblast attachment and growth while suppressing epithelial cell attachment and migration.

Both citric acid and tetracycline remove the smear layer of microcrystalline debris that is formed on planed root surface. Thus exposing the dentinal tubules.

II. Graft new attachment:

Grafting procedure: to stimulate periodontal regeneration, the flap approach was combined with the placement of bone graft or implant materials into the curetted bony defect. These materials may actively induce bone formation or through its own viability may deposit new bone. The various graft and implant materials used can be placed into four categories depend on their sources:

1. **Autogenous graft:** grafts transferred from one position to another within the same individual and are harvested either from intra oral or extra oral (iliac) donor site. It comprises:
    a. Cortical bone
    b. Cancellous bone of marrow. From max. tuberosity , edentulous areas ,and healing socket
    c. Bone blend which is combination of the previous two. bone is removed from predetermined site, triturated in a capsule to be workable ,plastic like mass and packed into bony graft
2. **Allograft:** a graft transferred between genetically dissimilar members of the same species (cadaver)
    a. Viable cancellous bone and marrow.
    b. Sterilized cancellous bone and marrow
    c. Freeze-dried bone.(FDBA).(spongy bone)

Decalcified freeze dried bone allograft is preferred because it has a higher osteogenic potential than freeze-dried bone graft because the process of decalcification or demineralization followed by acid application exposed the

component of bone matrix which are closely associated with collagen fibrils as bone morphogenic protein (BMP)

3. **Hetro- or xenografts:** grafts taken from a donor of another species (Calf ox bone).Bio-Oss is the most widely used, it's an inorganic bovine derived bone. in periodontology bio-oss used as graft material covered with resorbable membrane

Both allograft and xenograft are considered foreign, thus provoke an immune response, this antigenicity should be suppressed through radiation, freezing and chemical therapy.

4. **Alloplastic materials (non-bone graft synthetic material):** inert implant calcium phosphate bio materials which have been used as substitutes for bone grafts ex:

   a. Hydroxyapatite: similar to that found in bone, it is non bioresorbable.
   b. Tricalcium phosphate: is partially bioresorbable.
      Other alloplastic materials other than calcium phosphate are; sclera, cartilage, plaster of Paris , and bio active glass

The grafting materials introduce in treating periodontal disease may either:

- Contain bone forming cells (osteogensis) ex : DDB allograft.
- Serve as scaffold for bone formation (osteo conduction) ex BIO-OSS: Alloplastic materials.
  They induce bone formation when placed next to viable bone but not when surrounded by non-bone forming tissue such as skin.
- Induce bone formation (osteoinduction) because the matrix of bone graft contains bone-inducing substances.

GENERATION 2 (Bio active materials)

Enamel matrix Derivatives: Emdogain, enamel matrix protein mainly derived (Amelogenin) are secreted by Hertwigs epithelial root sheath during tooth development and induce acellular cementum formation. These proteins are believed to favor periodontal regeneration. The available derivative obtained from porcine teeth name's (emdogain) which is available as gel consisted in 90% is amelogenin with the rest are primarily proline-rich non amelogenin, tuftelin, tuft protein, etc.

Acellular dermal matrix allograft (ADMA): acellular human cadaver skin is a relatively new type of bioresorbable grafting material that has been obtained from tissue skin (Alloderm).

One of the major advantages of ADMA is that it's basically an immunologically inert avascular connective tissue. This is due to the fact that most of the targets of rejection response have been eliminated during the initial deepithelization and decellularization processes.

In periodontal surgery, the use of ADMA has been recommended in the management of ridge deformities , also in increasing keratinized tissue around teeth and dental implants and for root coverage.

It could be used in combination with EMD in treating gingival recession.

GENERATION 3 (Growth regulatory factors for periodontal regeneration)

Growth factor is a general term to denote a class of polypeptide hormones that stimulate a wide variety of cellular events such as proliferation, chemotaxis, differentiation and production of extracellular matrix protein.

Proliferation and migration of periodontal ligament cells and synthesis of extracellular matrix as well as differentiation of cementoblasts and osteoblasts is a prerequisite for obtaining periodontal regeneration. Therefore, it is conceivable that growth factors may represent a potential aid in attempts to regenerate the periodontium.

The effect of various growth factors were studied in vitro, and a significant regeneration potential of growth factors was also demonstrated in animal models. These growth factors

primarily secreted by macrophage ,endothelial cells ,fibroblast and platelets. The important growth factors are:

- Platelet derived growth factors (PDGF).
- Insulin-like growth factor (IGF).
- Bone morphogenetic proteins (BMPs)
- Transforming growth factor(TGF)

Ideal requirements of Bio-Materials

- Biocompatibility.
- Enhancement of clinical attachment level.
- Reduction of probing depth.
- Hard tissue fill of the intrabony defects.

Factors influencing the success or failure of all regeneration techniques:

- Plaque control.
- Systemic status that affect the periodontium.
- Traumatic injury to teeth or tissues
- Root preparation
- Wound closure
- Soft tissue approximation
- Post-operative and long term maintenance.