Periodontics

Tooth mobility

Mobile teeth are worried not only for the patient, but also to the dentist, because it is the critical stage where the tooth lies between two "S" (to be saved or sacrificed).

Mobility is the loosening of a tooth in its socket& it is of two types : physiologic & pathologic mobility.

physiological mobility refers to a large force exerted on the crown of a tooth surrounded by a healthy & intact periodontium& the tooth will show tipping movement or it will tip within its alveolus until a closer contact has been established between root & marginal or apical bony tissue.(Fig.1).

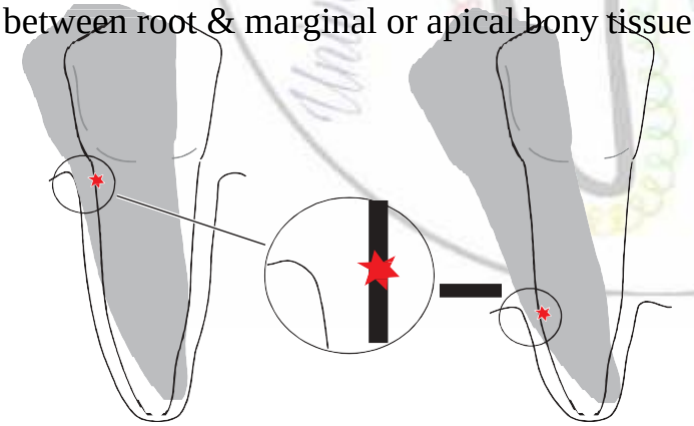

a b

Fig .1

All teeth have a slight degree of physiologic mobility, which varies for different teeth & at different times of the day. It is greatest on arising in the morning & progressively decreases. The increased mobility in the morning is attributed to slight extrusion of the tooth because of limited occlusal contact during sleep. During the waking hours, mobility is reduced by chewing & swallowing forces which intrude the teeth in the sockets. Also this mobility is less marked in persons with healthy periodontium than in those with occlusal habits as bruxism & clenching.

If a similar force is applied to a tooth which is surrounded by a periodontal ligament with an increased width, the excursion of the crown in horizontal direction will become increased; the clinical measurement consequentlydemonstrates that the tooth has an increased mobility.

An increased displacement of the crown of the tooth after force application, can also be found in situations where the height of the alveolar bone has been reduced but the remaining periodontal ligament has a normal width. At sites where this type of bone loss is extensive, the degree of tooth mobility (i.e., excursion of the crown) may be pronounced.

In (Fig 1 b) a tooth which is surrounded by alveolar bone of reduced height. The width of the remaining periodontal ligament, however, is within normal limits. A horizontally directed force applied to the crown of the tooth in this case will result in a larger excursion of the crown than if a similar force is applied to a tooth with normal height of the alveolar bone and normal width of the periodontal ligament (Fig. 1 a). The *increased mobility* measured in the case of Fig. 1-b is, ***physiologic*** if the displacement of the two teeth is assessed not from the crown but from a point on the root at the level of the bone crest. If a horizontal force is directed to the teeth as indicated in Fig. 1 the referencepoints (*) on the root surfaces will be displaced a similar distance in

both instances. *Obviously,* ***it is not the length of the excursive movement of the crown that is important from a biologic point of view, but the displacement of the root within its remaining periodontal ligament*****.**

Pathologic mobility is the *progressive increasing tooth mobility*, which may occur in conjunction with trauma from occlusion,is characterized by active bone resorption and which indicates the presence of inflammatory alterations within the periodontal ligament tissue**.**

Tooth mobility could be in horizontal or vertical direction

Horizontal tooth mobility is the ability to move the tooth in a facial-lingual direction in its socket. It is assessed by putting the handles of two dental instruments on either side of the tooth and applying alternating moderate pressure in the facial lingual direction against the tooth first with one, then with the other instrument handle (Fig .2)

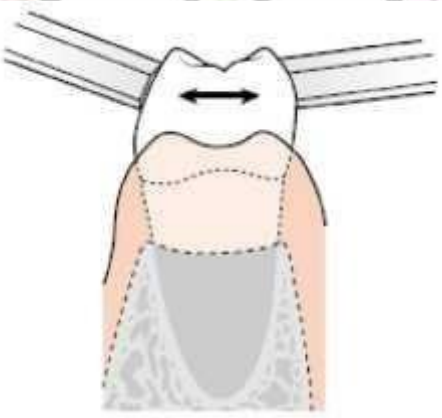

Fig .2 Assessing Horizontal Tooth Mobility.
Usingthe ends of two handles, apply alternating pressure, first from the facial and then from the lingual aspects of the tooth.

Vertical tooth mobility, is the ability to depress the tooth in its socket, is assessed using the end of an instrument handle to exert pressure against the occlusal or incisal

surface of the tooth (Fig 3).

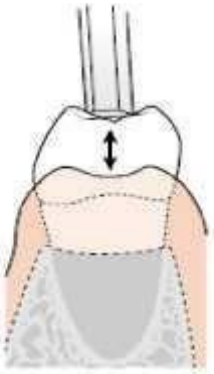

Fig.3 Assessing Vertical Tooth Mobility. Use the end of an instrument handle to exertpressure against the occlusal surface or incisal edge of the tooth.

Tooth mobility has several principal causes:

1. Advanced periodontal diseases & loss of supporting bone:
   Normally the crest of alveolar bone located about 1-2 mm shorter than C.E.J . The amount of mobility depends on the severity of bone destruction & there will be reduction in the height of bone.
2. Gingival & periodontal inflammation:
   Mobility will occur by increase the infiltration of connective tissues by fluid of inflammatory exudates.
3. Trauma from occlusion:
   It is injury to the tissue produced by excessive occlusal forces or occlusal habits as bruxism or clenching & it is a common cause for increased tooth mobility. The pathologic changes that occur because of trauma from occlusion are widening of periodontal ligament space &/or destruction of the bone surrounding the root.
4. Immediately following periodontal therapy:
   May cause transient mobility for a short period of time because of the surgical trauma (physical trauma rather than bacterial) due to the use of surgical

instruments. After 2-3 weeks, the mobility will disappear if the diagnosis, treatment plan & maintenance phase of therapy were done correctly.

5. Pulpal inflammation:

   Spread of inflammation from periapical area to the periodontal ligament may results in changes that increase tooth mobility.

Factors that govern tooth mobility in a horizontal direction (Fig.4)

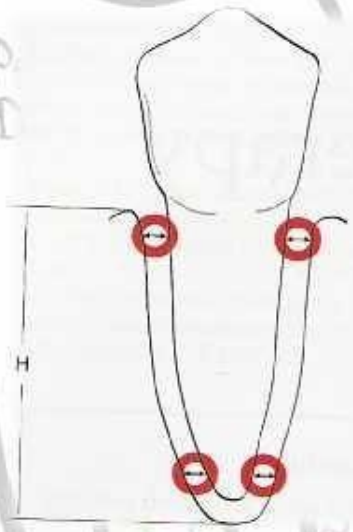

(Fig.4)

1. The width of the periodontal ligament space (it is about 0.25mm determined by x-ray).
2. The height of alveolar bone H (is 1mm apical to the C.E.J).
3. Number of roots (multirooted teeth are less subjected to mobility than single rooted teeth).
4. The shape of the roots (short tapered shape root is more susceptible to mobility than normal size & wide roots).

5. The degree & duration of the applied force whether in normal or abnormal function.

Classification of tooth mobility (T.M.):

T.M. is graded according to the following criteria:

Grade I: is the mobility of the crown 0.2-1 mm in horizontal direction.

Grade II: mobility of the crown of the tooth exceeding 1mm in horizontal direction.

Grade III: mobility of the crown of the tooth in vertical direction as well & the tooth becomes even depressed in its socket.

Initial & secondary tooth mobility:

A tooth which is surrounded by normal periodontium may be moved in horizontal & vertical directions & may be forced to perform rotational movements. Clinically, tooth mobility is assessed by exposing the crown of the tooth to a certain force & determine the distance the crown can be displaced buccal&/or lingual direction.

The mechanism of T.M. was studied in detail by Muhlemann (1954, 1960) who described a standardized method for measuring even minor tooth displacement. By means of **periodontometer** (fig. 5), a small force (100 pounds) is applied to the crown of a tooth, the crown start to tip in the direction of the force & the crown is moved only 0.05-0.1 mm. This movement of the tooth is called initial tooth mobility (I.T.M.) which is the result of intra alveolar displacement of the root. In this movement there is pressure & tension zone. In the pressure zone there is 10% reduction in the width of periodontal ligament & in the tension zone there is a corresponding increase. In the I.T.M., there is reorientation of the P.D. ligament fibers into a position of functional

readiness towards tensile strength & it is differing from individual to another & from tooth to tooth (Fig.6)

When large force (500 pounds) is applied to the crown, the fiber bundles on the tension side cannot offer sufficient resistance to further root displacement. The additional displacement of the crown is called secondary tooth mobility (S.T.M.) which is allowed by distortion & compression of the periodontium in the pressure side. The displacement of the crown when a force of 500 pounds is applied varies between teeth:

Incisors 0.1-0.12 mm
Canines 0.05-0.09 mm
Premolars 0.08-0.1 mm
Molars 0.04-0.08 mm
& it is larger in children than adults & is larger in females than males &

increase during pregnancy

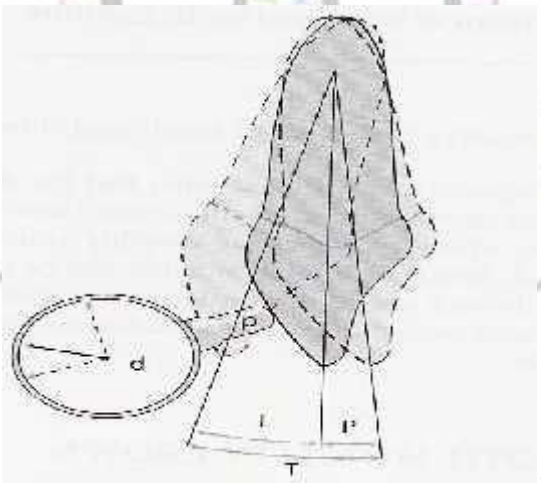

(Fig 5)Tooth mobility measurements by means of the Periodontometer. d = dial indicator; p = pointer; L = labial excursion of the crown; P = palatal excursion of the crown; T = L + P = total excursion of the crown

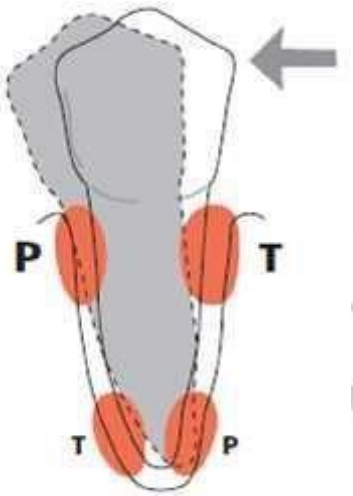

Fig (6) If the crown of a tooth is exposed to excessive, horizontally directed forces (arrow), pressure (P) and tension (T) zones will develop within the marginal and apical parts of the periodontium. The supra-alveolar connective tissue remains unaffected by force application. Within the pressure and tension zones tissue alterations take place which eventually allow the tooth to tilt in the direction of the force.

Sign & symptoms of T.M

1) Patient awareness of mobility:

Mobility is detected quite incidentally when patient's attention is brought to tooth by tenderness experienced on chewing**.**

2) Functional discomfort:

Pain may be expected following sudden tooth displacement when biting on hard foods or with inadvertent trauma.

3) **Aesthetic:**

Anterior labial or lateral tooth displacement results in fanning & elongation of clinical crown with poor appearance

Treatment of increased tooth mobility:

A number of situations will be described for the aim of reducing increased tooth mobility.

Situation I: (increased mobility of a tooth with increased width of the periodontal ligament but normal height of the alveolar bone).

This case is seen in teeth with improper filling or crown restoration (high spot) (fig 7) so occlusal interferences develop & the surrounding periodontal tissues become inflamed (trauma from occlusion). If a tooth is subjected to forces directed in buccal direction, bone resorption will develop in the buccal-marginal & lingual-apical pressure zones with a resulting increase in the width of periodontal ligament space in these zones. Such traumatizing forces in teeth with normal periodontium cannot result in pocket formation or loss of connective tissue attachment, the resulting mobility of the tooth is regarded as a physiological adaptation of the periodontal tissues to the altered functional demands. In such a case bone resorption is a reversible process can be treated by elimination of occlusal interferences or occlual adjustment.

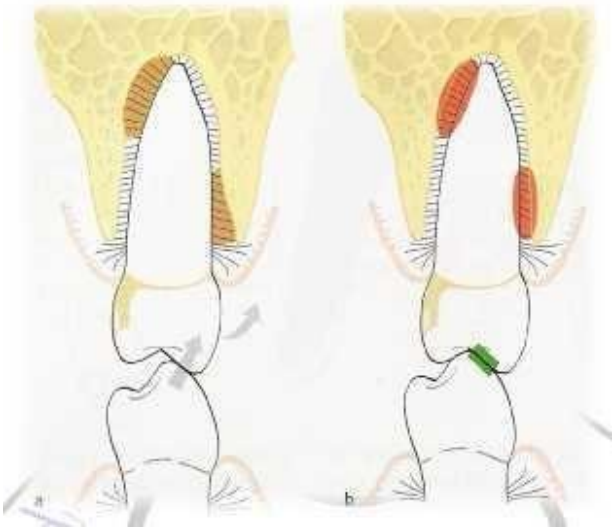

Fig.7

Situation II: (increased mobility of a tooth with increased width of P. D. ligament& reduced height of alveolar bone). When a dentition properly treated for plaque-associated periodontal disease, gingival health is established but the teeth will be surrounded by periodontal structures of reduced height. If a tooth with reduced periodontal tissue support is exposed to excessive horizontal forces (trauma from occlusion), inflammatory reaction develops in the pressure zone of the periodontal ligament with bone resorption& result in increase width of P.D.ligament & the tooth become hypermobile. Treatment of such a case is by occlusal adjustment & elimination of the excessive force or reduce it, so bone apposition will occur & the P.D.lig. will regain its normal width & the tooth stabilized (Fig.8).

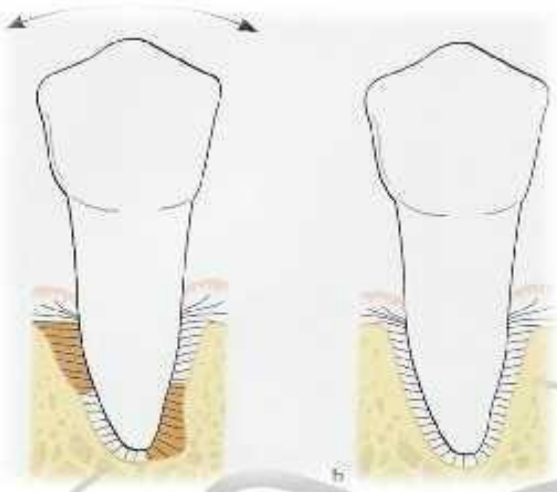

(Fig 8).

Situation III: (increased mobility of a tooth with reduced height of alveolar bone & normal width of P.D.ligament).

In teeth with normal width of P.D.lig, no further bone apposition on the walls of the alveoli can occur. If such an increased tooth mobility does not interfere with the patient chewing function or comfort, no treatment is required. If the mobility disturb the patient so it can be treated by splinting by joining the mobile tooth or teeth together with other teeth in the jaw either by using composite fillings, fixed bridges or removable partial prosthesis.

Situation IV: (progressive (increasing) mobility of a tooth (teeth) as a result of gradually increasing width of P.D.ligament in teeth with reduced height of alveolar bone). This case seen in advanced periodontal disease, the tissue destruction may have reached a level where extraction of one or several teeth can not be avoided. Teeth that remaining in such dentition are still available for periodontal treatment may after therapy exhibit a progressively increasing mobility when force applied during function which may mechanically disrupt the remaining P.D.lig. components& cause

extraction of the teeth.Treatment is only by fixed splint to stabilize the hyper mobile teeth & to replace missing teeth.

Situation V: (increased bridge mobility despite splinting)

In patient with advanced P.D. disease, the destruction of the periodontium has progressed to varying levels around different teeth & tooth surfaces in the dentition. Following proper treatment of the plaque-associated lesions, often including multiple extraction, the remaining teeth may display extreme reduction of the supporting tissues with increased tooth mobility & they may be distribued in the jaw in such away that it make it difficult or impossible to obtain proper splinting effect even by means of cross-arch bridge & the entire bridge/splint may exhibit mobility.

An increased mobility of a cross-arch bridge/splint can be accepted providing that the mobility does not disturb chewing ability or comfort & the mobility of the splint is not progressively increasing.**Treatment of increased T.M can be summarized in the following table:**

P.D ligament Width	**Alveolar bone height**	**Treatment**
1. Increased	Normal height	Occlusal adjustment
2. Increased	Reduced height	Occlusal adjustment
3. Normal width	Reduced height	Splint if mobility disturb the patient
4. Gradual increase in the width of P.D. lig.	Reduced height	Splint
5. Gradual increase in the width of P.D.lig. with increased mobility of a cross-arch bridge/splint	Reduced height of bone	Mobility of cross-arch splint accepted if not disturb the patient