# *Perio*

Gingival and periodontal pocket

---

Tooth gingival interface

The interface between a tooth and the surrounding gingival tissue is a dynamic structure. The gingival tissue forms a crevice surrounding the tooth, resemble fluid-filled moat, wherein food debris, endogenous and exogenous cells, and chemicals float. The depth of this crevice, known as a sulcus, is in a constant state of flux due to microbial invasion and subsequent immune response. Located at the depth of the sulcus is the epithelial attachment, consisting of approximately 1 mm of junctional epithelium and another 1 mm of gingival fiber attachment, comprising the 2 mm of biologic width naturally found in the oral cavity. The sulcus is literally the area of separation between the surrounding epithelium and the surface of the encompassed tooth.

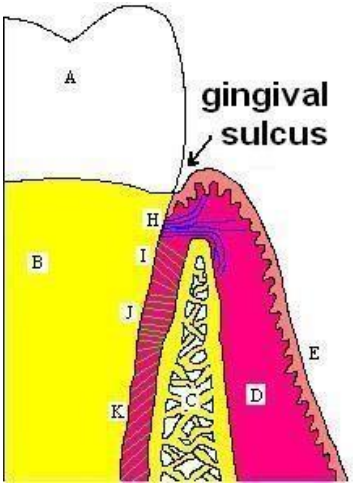


Gingival sulcus

---

A healthy sulcular depth is 3 millimeters or less. Through much investigation and research, it has been determined that sulcular depths of 3 millimeters or less are readily self-cleansable with a properly used toothbrush or the supplemental use of other oral hygiene aids. When the sulcular depth is chronically in excess of three millimeters, regular home care may be insufficient to properly cleanse the full depth of the sulcus, allowing food debris and microbes to accumulate, forming dental biofilm. This poses a danger to the periodontal ligament (PDL) fibers that attach the gingiva to the tooth. If accumulated microbes remain undisturbed in a sulcus for an extended period of time, they will penetrate and ultimately destroy the delicate soft tissue and periodontal attachment fibers. If left untreated, this process may lead to a deepening of the sulcus, recession, destruction of the periodontium, including the bony tooth socket, tooth mobility, and tooth loss

Both the **gingival and periodontal pocket** are extensions of the gingival sulcus, which exists in health. **Gingival and periodontal pockets** are dental terms indicating the presence of an

abnormal depth of the gingival sulcus near the point at which the gingival tissue contacts the tooth.

***pocket***

- ✓ It‟s an inflammatory changes and apical migration of junctional epithelium; it is also defined as a pathological deepening of gingival sulcus, which occurs by coronal movement of gingival margin, apical displacement of gingival attachment, or both.

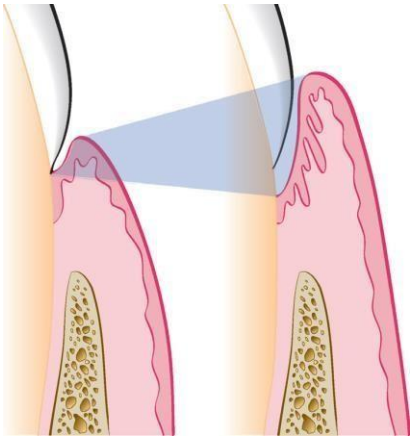

***Classification***:

**1. According to the involved tooth surface:**

a) Simple pocket: involve one surface
b) Compound pocket: involve more than one surface
c) Complex or spiral pocket: originating on one surface and twisting around the tooth to involve one or more additional surface (but it opens into the oral cavity on the surface of its origin). These types of pockets are most common in furcation areas.

**2. According to its location:**

a) Gingival pocket: which is formed by gingival enlargement without destruction of underlying periodontal tissue. The sulcus is deepened because of increased bulk of the gingiva.

---

A gingival pocket presents when the marginal gingiva experiences an edematous reaction, whether due to localized irritation and subsequent inflammation, systemic issues, or drug induced gingival hyperplasia. Regardless of the etiology, when gingival hyperplasia occurs, greater than normal (the measurement in a pre-pathological state) periodontal probing measurements can be read, creating the illusion that periodontal pockets have developed. This phenomenon is also referred to as a false pocket or pseudopocket. The epithelial attachment does not migrate, it simply remains at the same attachment level found in pre-pathological health. The only anatomical landmark experiencing migration is the gingival margin in a coronal direction.

In a gingival pocket, no destruction of the connective tissue fibers (gingival fibers) or alveolar bone occurs. This early sign of disease in the mouth is completely reversible when the etiology

of the edematous reaction is eliminated and frequently occurs without dental surgical therapy. However, in certain situations, gingivectomy is necessary to reduce the gingival pocket depths to a healthy 1–3 mm.

.

b) Periodontal pocket: associated with destruction of underlying supportive tissues. periodontal pocket, which is defined as a pathologically deepened gingival sulcus, is one of the most important clinical features of periodontal disease. All different types of periodontitis, share histopathologic features, such as tissue changes in the periodontal pocket, mechanisms of tissue destruction, and healing mechanisms. However, they differ with regard to their etiology, natural history, progression, and response to therapy.

---

**3. According to its relation to alveolar crest:**

a) Suprabony pocket: also called supra crestal or supra alveolar. The base of the pocket is coronal to the level of underlying bone. The bone loss is horizontal
b) Infrabony pocket: also known as sub crestal or intra alveolar pocket. The base of the pocket is apical to the level of adjacent bone. The bone loss is vertical.

***Diagnosis/ detection of pockets***

1. Careful exploration with periodontal probe. (this method is accurate).
2. Radiographic: pockets are not detected by the radiographic examination because pockets are soft tissue changes.

A calibrated silver points or gutta percha points can be used with radiographic to assist in determining the level of attachment of periodontal pocket.

***Pathogenesis***

The initial lesion in the development of periodontitis is the inflammation of the gingiva in response to a bacterial challenge. Changes involved in the transition from the normal gingival sulcus to the pathologic periodontal pocket are associated with different proportions of bacterial cells in dental plaque. Healthy gingiva is associated with few microorganisms, mostly coccoid cells and straight rods. Diseased gingiva is associated with increased numbers of Spirochetes and motile rods. However, the microbiota of diseased sites cannot be used as a predictor of future attachment or bone loss, because their presence alone is not sufficient for disease to start or progress.

# *Perio*

Sequences in pathogenesis of periodontal pocket

- Accumulation of microorganisms on the supra gingival tooth surface and its extension into gingival sulcus.
- Inflammatory changes in the connective tissue wall of the gingival sulcus.
- Cellular and fluid inflammatory exudate causes degeneration of the connective tissue including the gingival fibers.
- Collagen fibers gets destroyed apical to the junctional epithelium and the area becomes occupied by the inflammatory cells and edema.
- The coronal portion of the junctional epithelium detaches from the root as the apical portion migrates.
- Polymorphonuclear neutrophils invade the coronal end of the junctional epithelium in increasing number.
- With continued inflammation the gingiva increase in bulk and the crest of the gingival margin extends coronally.
- The junctional epithelium continues to migrate along the root and separate from the root.

***Mechanisms of collagen loss:***
Two mechanisms involved:

- First mechanism:

Collagenases and other enzymes secreted by fibroblast, PMNs and macrophages in healthy and inflamed tissues, become extracellular and destroy collagen These enzymes that degrade the collagen and other matrix macromolecules into small peptides are called matrix metalloproteinase.

- Second mechanism

Fibroblast phagocytize collagen fibers by extending cytoplasmic processes to the ligament-cementum interface and degrade the inserted collagen fibrils and the fibrils of cementum matrix.

***Histopathology:***

***Epithelial changes*** The epithelium of the lateral wall of the pocket presents striking proliferative and degenerative changes. Epithelial buds or interlacing cords of epithelial cells project from the lateral wall into the adjacent inflamed connective tissue, and they may extend farther apically than the junctional epithelium

***A.***

- Epithelium becomes degenerated and atrophied

**The severity of the degenerative changes is not necessarily related to pocket depth**

- Inner aspect of the lateral pocket walls becomes ulcerated due to progressive degeneration and necrosis of the epithelium.

- Pus occurs in the pocket with suppurative inflammation of the inner wall.
- **The epithelium at the gingival crest of a periodontal pocket is generally intact and thickened, with prominent rete pegs**

B-.connective tissue changes

- The connective tissue is edematous and densely infiltrated with plasma cells**(approximately 80%)** ,lymphocytes and **a scattering of** PMNs
- Blood vessels are increased in number , dilated and engorged **particularly** in sub epithelial connective tissue layer
- **The connective tissue exhibits varying degrees of degeneration. Single or multiple necrotic foci are occasionally present. In addition to exudative and degenerative changes,**
- Proliferation of endothelial cells .with newly formed capillaries,fibroblasts, and collagen fibers

***C- Root surface wall of the pocket***

Root surface forms the medial wall of the pocket. As the pocket deepens, collagen fibers embedded in the cementum are destroyed, and cementum becomes exposed to the oral environment The root surface that get expose to the oral environment as a result of periodontal attachment loss, undergoes following changes (structural, chemical, cytological).

- Structural changes:
  Exposure of cementum to the oral environment ⟶ minerals present in saliva tend to get deposited on cementum surface (Ca, F,~~P,Mg~~) area of hypermineralization▶ root surface is exposed to oral fluids and bacterial plaque ⟶ proteolysis of embedded remnants of Sharpey‟s fibers⟶ Area of demineralization▶ root caries (yellowish or brown patch)⟶ soft and lethargy on probing▶ patient feels hypersensitivity to the thermal changes and sweets ⟶ pulp exposure may occur in sever forms.(demineralization is related to dental carries)
- Chemical changes
  Cementum exposed to saliva may absorb calcium, phosphorus, magnesium and fluoride. This increase in mineral content of the root surface alters the chemical composition of the cementum, making it resistant to dental caries.

- Cytotoxic changes:

Histologic studies of periodontally involved cementum have shown the presence of bacteria in the cementum or endotoxins in the cementum. Collagenous remnants of Sharpey fibers in the cementum undergo degeneration, thereby creating an environment favorable to the penetration of

bacteria. Bacterial penetration into the cementum can be found as deep as the cemento dentinal junction, and it may also enter the dentinal tubules.

Penetration and the growth of bacteria leads to fragmentation and breakdown of the cementum surface and results in areas of necrotic cementum that are separated from the tooth by masses of bacteria.

In addition, bacterial products (e.g., endotoxins) have also been detected in the cementum wall of periodontal pockets , diseased root areas induce an inflammatory response, and prevent fibroblast attachment These changes manifest clinically as softening of the cementum surface; this is usually asymptomatic, but it can be painful when a probe or explorer penetrates the area. They also constitute a possible reservoir for reinfection of the area after treatment. During the course of treatment, these necrotic areas are removed by root planing until a hard, smooth surface is reached. Cementum is very thin in the cervical areas, and scaling and root planing often remove it entirely, exposing the underlying dentin. Sensitivity to cold may result until secondary dentin is formed by the pulp tissue.

***Content of the pocket:***

1) Microorganisms .
2) Bacterial products (enzymes and endotoxins).
3)GCF.
4)Remnants of food
5)Salivary mucin.
6)Desquamated epithelial cells.
7)Leukocytes
8) Plaque covered calculus usually projects from the tooth surface
9) Purulent exudates may be present and this is a secondary feature because deep pocket may have little or no pus and shallow pocket may have extensive pus formation so pus is not an indicator of the depth of pocket.

***Surface Morphology of Tooth Wall.*** The following zones can be found in the bottom of a periodontal pocket

1. *Cementum covered by calculus,* in which all of the changes can be found.
2. *Attached plaque,* which covers calculus and which extends apically from it to a variable degree (typically 100 to 500 μm).
3. The zone of *unattached plaque* that surrounds attached plaque and extends apically to it.
4.The zone of *attachment of the junctional epithelium to the tooth.* The extension of this zone, which in normal sulci is more than 500 μm, is usually reduced in periodontal pockets to less than 100 μm.
5. A zone of *semidestroyed connective tissue fibers* may be apical to the junctional epithelium.

Zones 3, 4, and 5 make up the “plaque-free zone” seen in extracted teeth.

**Microtopography of the Gingival Wall**

Scanning electron microscopy has permitted the description of several areas in the soft-tissue (gingival) wall of the periodontal pocket in which different types of activity take place. These areas are irregularly oval or elongated and adjacent to one another, and they measure about 50 to

200 μm. These findings suggest that the pocket wall is constantly changing as a result of the interaction between the host and the bacteria. The following areas have been noted:
1. *Areas of relative quiescence*, showing a relatively flat surface with minor depressions and mounds and occasional shedding of cells
2. *Areas of bacterial accumulation,* which appear as depressions on the epithelial surface, with abundant debris and bacterial clumps penetrating into the enlarged intercellular spaces. These bacteria are mainly cocci, rods, and filaments, with a few spirochetes.

3. *Areas of emergence of leukocytes,* in which leukocytes appear in the pocket wall through holes located in the intercellular spaces.
4. *Areas of leukocyte–bacteria interaction,* in which numerous leukocytes are present and covered with bacteria in an apparent process of phagocytosis. Bacterial plaque associated with the epithelium is seen either as an organized matrix covered by a fibrin like material in contact with the surface of cells or as bacteria penetrating into the intercellular spaces.
5. *Areas of intense epithelial desquamation,* which consist of semi attached and folded epithelial squames, which are sometimes partially covered with bacteria.
6. *Areas of ulceration,* with exposed connective tissue.
7. *Areas of hemorrhage,* with numerous erythrocytes. The transition from one area to another could result from bacteria accumulating in previously quiescent areas and triggering the emergence of leukocytes and the leukocyte–bacteria interaction.This would lead to intense epithelial desquamation and finally to ulceration and hemorrhage.

***Periodontal pocket as healing lesions:***

Periodontal pockets are inflammatory lesions and constantly undergoing repair. Complete healing does not occur because of persistence of bacterial attack which continues to stimulate an inflammatory response causing degeneration of new tissues elements formed during the continuous effort at repair.
The condition of the soft-tissue wall of the periodontal pocket results from the interplay of the destructive and constructive tissue changes. Their balance determines clinical features such as color, consistency, and surface texture of the pocket wall..
.
**Edematous pocket walls**: when the inflammatory component predominates(inflammatory fluid and cellular exudate predominate) the lateral wall appears soft, edematous friable, with smooth shiny surface and bluish red discoloration.

**Fibrotic pocket wall**: when reparative changes predominates,( If there is a relative predominance of newly formed connective tissue cells and fibers), the pocket wall is more firm and pink the gingiva appears fibrotic and pink.

In some cases both lesions present in the same pocket as outer surface of a pocket wall fibrotic, the inner surface of soft tissue wall is inflamed and ulcerated.

Edematous and fibrotic pockets represent opposite extremes of the same pathologic process rather than different disease entities. They are subject to constant modification, depending on the relative predominance of exudative and constructive changes

Clinical features/histopathological feature:

A.1- bluish red discoloration of the gingival wall of pocket, this caused due to circulatory stagnation.

2- flaccidity of tissue: due to destruction of gingival fibers.
3- smooth shiny surface: due to atrophy of the epithelium and edema.,
4- pitting on pressure: due to edema and degeneration.

B.Gingival wall may be pink or firm when ⟶ fibrotic changes predominates over exudation and regeneration.

**particularly in relation to the outer surface of the pocket wall. However, despite the external appearance of health, the inner wall of the pocket invariably presents some degeneration and is often ulcerated**

C. Bleeding on probing: due to

- Increased vascularity.
- Thinning and degeneration of epithelium.
- Proximity of engorged vessels to inner surface.

D. Probing is generally painful: due to ulceration of the inner aspect of the pocket wall.

E. Pus may be present: due to suppurative inflammation.

F. Other clinical features

- Thickened marginal gingiva.
- Loss of stippling.
- Tooth mobility and diastema formation

**Periodontal disease activity**

1--- Period of quiescence or inactivity this period characterized by reduced inflammatory response and little or no loss of bone and connective tissues.
A buildup of unattached plaque with its gram negative and anaerobic bacteria
2--- period of exacerbation or activity bone and connective tissue attachment are lost and the pocket deepens
This period may last for days, weeks, months and eventually followed by period of remission and quiescence in which G+ve bacteria proliferate and more stable condition is established
Clinical feature shows bleeding spontaneous or on probing and greater amount of gingival exudates
Histological features , pocket appear thin and ulcerated ,infiltrate composed of plasma cells and PMNs leukocytes

***Pocket probing:***

We have two different pocket depths:

1) **Biologic or histologic depth**: distance between gingival margin and base of the pocket.measured histologically(accurate measurement but not used routinely)
2) **Clinical or probing depth**: distance to which a probe penetrates into the pocket.

   The standardized force used for penetration of probe is 25 pounds or 23 grams (0.75 N).

**Probing Pocket depth PPD:** Distance between base of pocket and gingival margin.

**Extent**

The "extent" of disease refers to the proportion of the dentition affected by the disease in terms of percentage of sites. Sites are defined as the positions at which probing measurements are taken around each tooth and, generally, six probing sites around each tooth are recorded, as follows:

1. mesiobuccal

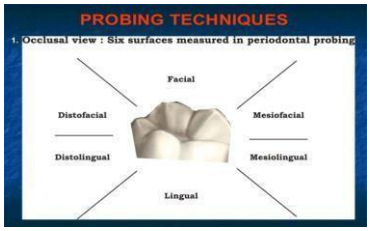


2. mid-buccal
3. distobuccal
4. mesiolingual
5. mid-lingual
6. distolingual

If up to 30% of sites in the mouth are affected, the manifestation is classified as "localized"; for more than 30%, the term "generalized" is used.

Probing techniques this can reveals the extent of the disease

i. Occlusal view: six surfaces measured in periodontal probing
ii. In multirooted teeth, the possibility of furcation involvement should be carefully explored with specially designed probe (eg. Nabers probe).

The probe should be inserted parallel to the vertical axis of the tooth and walked circumferentially around each tooth to detect the area of deepest penetration.

iii. To detect internal crater: the probe should be placed obliquely from both facial and lingual surfaces, so as to explore the deepest point of the pocket located beneath the contact point.

Periodontal probes are used to locate, measure, and mark pockets, as well as determine their course on individual configuration. The typical probe is a tapered, rod-like instrument calibrated in millimeters, with a blunt rounded tip

**Level of attachment loss CAL**: Distance between base of pocket and a fixed point on the tooth such as CEJ.

**Severity**

The "severity" of disease refers to the amount of periodontal ligament fibers that have been lost, termed "clinical attachment loss". According to the American Academy of Periodontology, the classification of severity is as follows:

- Mild: 1–2 mm of attachment loss
- Moderate: 3–4 mm of attachment loss
- Severe: ≥ 5 mm of attachment loss

**Classification of periodontal probes**

Periodontal probes may be divided into:

*First generation probes are conventional , and hand held probes , e.g. conventional periodontal probes.

*Second generation probes are pressure –sensitive probes . It has been shown that, with forces up to 30gms the probe tip remains within junctional epithelium and forces up to 50gms are necessary to diagnose osseous defects. This probe did solve many problems of the conventional probes, but lacked tactile sensitivity.

* Third generation probes are computerized probes . Gibbs et al designed Florida probe. E.g.-Foster Miller Probe, Toronto Automated Probes, which can detect the cemento-enamel junction **The Florida Probe provides a means of recording relative clinical attachment level changes over time**

* Fourth generation probes are the three dimensional probes in which sequential probe positions are measured .They are three dimensional probes

* Fifth generation probes are ultra-sonographic probes which provides painless probing to the patient. The guidance path is predetermined in these probes.

Periodontal Probes have blunt, rod shaped working ends that may be circular or rectangular in cross-sections

**Types of conventional Calibrated Periodontal Probe**

- Marquis color-coded probe Calibrations are in 3mm sections, markings are 3,6,9,12mm
- University of Michigan „O" probe, with Williams markings
- Michigan „O" probe Markings include 1,2,3,5,7,8 and 9mm with 4mm and 6mm missing
- The UNC-15 Probe 15mm long and markings are at each mm and coding at the 5 th ,10 th and 15 th mm. Millimeter markings at 1,2,3,4,5,6,7,8,9,10,11,12,13,14 and 15 millimeters

- World Health Organization (WHO) probe Prescribed in 1978. The probe was designed for two purposes: Measurement of pocket depth. Detection of sub gingival calculus. Used in the assessment of CPITN (Community Periodontal Index for Treatment Needs)
- Naber"s Furcation Probe It is used to determine the extent of furcation involvement on a multi rooted teeth. <It has a curved working end for accessing the furcation area. The end is blunt so that it will not harm soft tissues. Most of the nabers probe do not have markings. The depth of insertion of the probe into the furcation area determines the degree of furcation involvement
- Periimplant Probing Advantages: Can measure the level of mucosal margin relative to a fixed position on the implant. Measure the depth of tissue around the implant. Periimplant probing depth is often a measure of the thickness of surrounding connective tissue and correlates most consistently with the level of surrounding bone. The probing depth around implants presumed to be "healthy" has been about 3mm around all surfaces.

The results obtained with periimplant probing cannot be interpreted same as the natural teeth because: Differences in the surrounding tissues that support implanted teeth. , Probe inserts and penetrates differently. Around natural teeth, the periodontal probe is resisted by the insertion of supra-crestal connective tissue fibers into the cementum of root surface. There is no equivalent fiber attachment around implants.

**When to Probe.** The probing of pockets is performed at various times for diagnosis and to monitor the course of treatment and maintenance. The initial probing of moderate or advanced cases is usually hampered by the presence of heavy inflammation and abundant calculus, and it cannot be done very accurately. Probing at this stage is also difficult as a result of the discomfort and pain that occurs when the gingival tissues are inflamed. The purpose of this initial probing, together with the clinical and radiographic examination, is to determine whether the tooth should be saved or extracted. After the patient has performed adequate plaque control for some time and the calculus has been removed, the major inflammatory changes disappear, and an accurate probing of the pockets can be performed. The purpose of this second probing is to accurately establish the level of attachment and the degree of involvement of roots and furcations. Data obtained from this probing provides valuable information for treatment decisions.
Later during periodontal treatment, probing's are done to determine changes in pocket depth and to ascertain healing progress after different procedures.

***Treatment:***

*Non surgical treatment:*

1) Oral hygiene instruction.
2) Scaling and root planning
    - ✓ Use curettes for subgingival scaling, root planing and removal of the soft tissue lining the pocket.
    - ✓ Root planing strock should be moderate to light.
    - ✓ Pull strock for final smoothing and planing of root surface.
    - ✓ Continuous series of long, overlapping shaving strock is achieved.
    - ✓ To avoid over instrumentation, a delicate transition from short, powerful scaling strocks to longer, lighter root planning strokes must be made as soon as calculus and initial roughness have been eliminated.
    - ✓ Periodontal medication as application of tetracyclines

**Surgical treatment**------

Pocket depth reduction through different surgical procedures

1-gingival curettage

2- gingivectomy

3- periodontal flap procedures

4-osseous surgery

Periodontal regeneration procedures

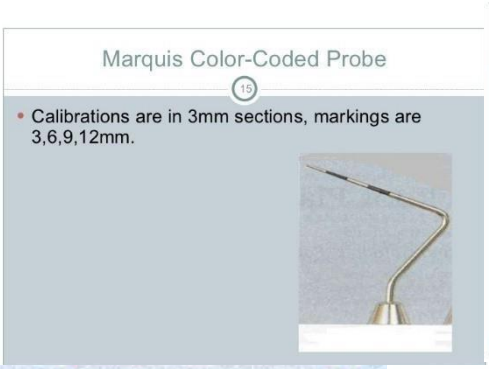







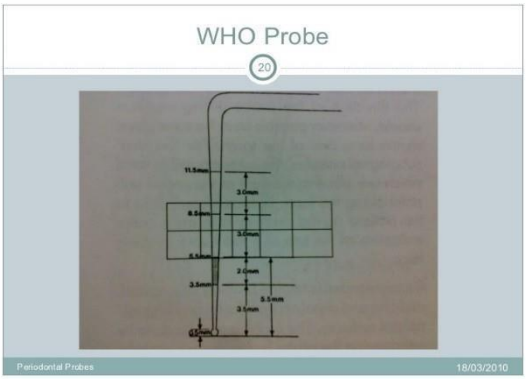


plastic periimplant probe

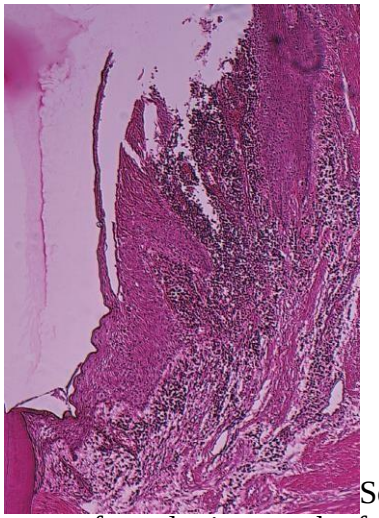




Scanning el
ectron frontal micrograph of the periodontal pocket wall. Different areas can be seen in the pocket wall surface. *A*, Area of quiescence; *B*, bacterial accumulation; *C*, bacterial–leukocyte interaction; *D*, intense cellular desquamation. Arrows point to emerging leukocytes and holes left by leukocytes in the pocket wall. (×800.)