Lecture 11

Periodontics

Furcation involvement:

The term furcation involvement" refers to invasion of the bifurcation and/or trifurcation of multirooted teeth by periodontal disease. The primary etiological factor for furcation involvement is bacterial plaque which plays an important role in the etiology of gingivitis and destructive periodontal disease & the long – standing inflammation of periodontal tissues.

Consequently, therapeutic measures aimed to eliminate gingival inflammation and arresting progression of periodontal tissue breakdown must include the careful removal of microbial deposits from the tooth surfaces and the establishment of home-care program which prevents recurrence of gross amount of plaque and calculus.

The progression of the bacterial plaque apically along the root surface not occur only vertically, but also horizontally leading to furcation involvement.

Terms frequently used in furcation involvement

Root complex is the portion of a tooth that is located apical to the cemento-enamel junction (CEJ), i.e. the portion that normally is covered with a root cementum.The root complex may be divided into two parts: **the *root trunk* and the *root cone(Fig.1).***

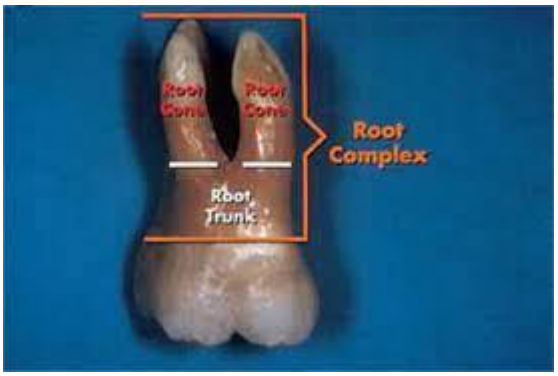

Fig.1

Root trunk represents the *undivided region* of the root. The height of the root trunk is defined as the distance between the CEJ and the separation line (furcation) between two root cones (roots). Depending on the position of the separation line the height of the root trunk may vary from one surface to the next in one given molar or premolar.

The *root cone* is included in the *divided region* of the root complex. The root cone (root) may vary in size and position and may at certain levels be connected to or separated from other root cones. Two or more root cones make up the *furcated region* of the root complex . The *furcation* is the area located between individual root cones.
The *furcation entrance* is the transitional area between the undivided and the divided part of the root (Fig.2)

The *furcation fornix* is the roof of the furcation (Fig.2)



Anatomical characteristics:

The anatomy of the roots and the topography of the alveolar bone in the furcation areas of multi-rooted teeth in a periodontal patient can be examined if a muco-periostal flap is elevated. General information regarding the anatomy of the furcation areas of multi-rooted tooth may be gained from "autopsy material".

If the buccal bone plates are removed from an autopsy preparation, the buccal furcas are exposed as well as the location of the furcas in relation to cemento-enamel junction.

The position and spread of the roots of the maxillary molars often give rise to a large areas of inter radicular supporting bone. A thin buccal bone plates is sometimes associated with the presence of fenestrations (window-like exposed area) and/or dehiscence in combination with gingival recession.

The use of radiographs to identify the structures in the furcations area is generally of limited value. Hances in maxillary molars, frequently only the buccal furca can be properly identified and in the mandibular molars the images of the buccal and tooth and bone structures often become super imposed over the furcation areas. Parallel and bitewing films can be used to discover these areas.

The fact that furcas may be present in teeth which normally have only one root should be also in consideration. Thus 2-rooted incisors or canines and mand. Premolars may exist. Occasionally, 3-rooted max. premolars and 4-rooted mand. molars can be found.

There are some morphological variations that must be considered in the diagnosis and treatment of furcation involved teeth. These are:

1- Fusions between divergent roots

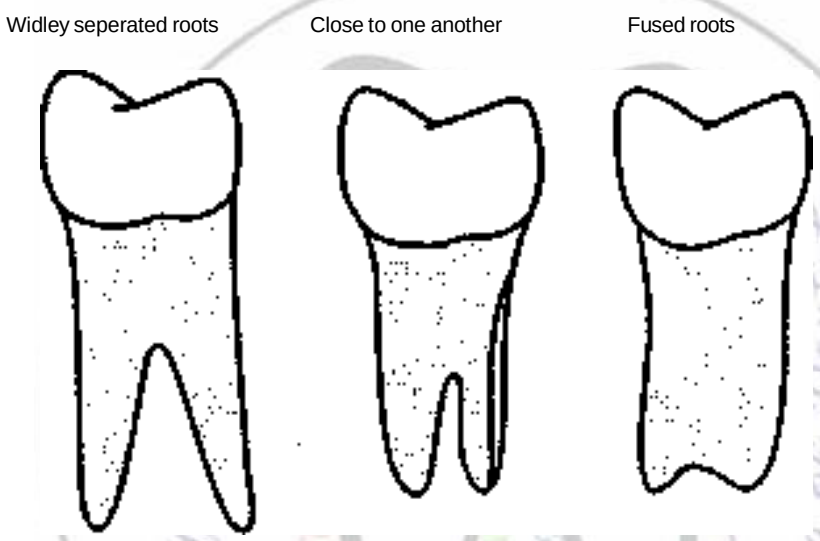

Fig.3

2- cervical enamel projection or enamel pearl in the furcation areas :They occur approximately in 15 percent of molars. They favor plaque accumulation and must be removed to facilitate scaling and root planing.

It was classified by Masters and Hoskins in 1964 as:

Grade I: The enamel projection extends from the cementoenamel junction of the tooth towards the furcation entrance.

Grade II: The enamel projection approaches the entrance to the furcation but does not enter the furcation and hence has no horizontal component.

Grade III: The enamel projection extends horizontally into the furcation.

3-the presence of accessory pulp canals which communicate with the furcation area:

It is believed that once the pulp is infected through the accessory canal, endo-perio communication may result, which in turn can cause either destruction of inter radicular periodontium or interfere with the healing response of either periodontal or endodontic procedures

4- The distance between CEJ & furcation area(Fig.4)

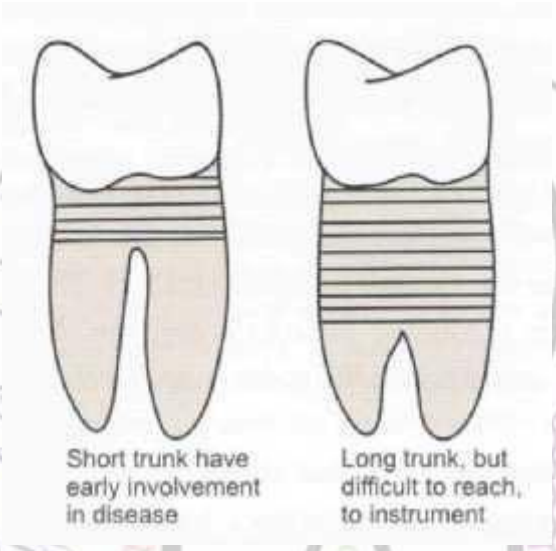

Fig. 4

5-The position of the tooth in the arch.(Fig.5a,b,c,d)



Maxillary first premolars can be bifurcated with ***buccal and palatal roots.*** When bifurcated, the roots of a maxillary first premolar separate many millimeters apical to the cemento-enamel junction.

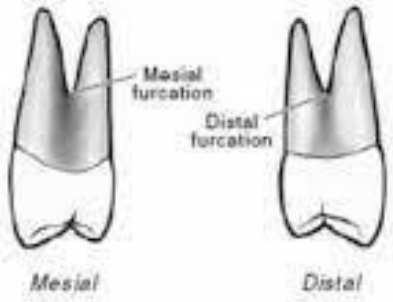

Maxillary molar teeth usually are trifurcated with ***mesiobuccal, distobuccal, and palatal*** (lingual) **roots.**

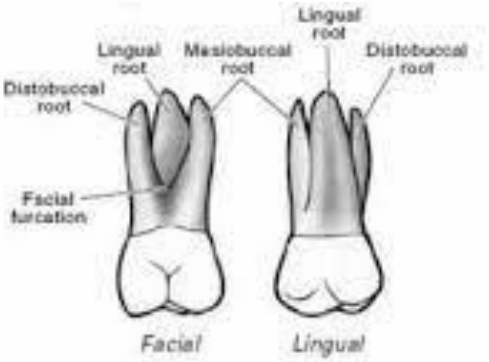

On the mesial surface of a maxillary molar, the furcation is located more toward the lingual surface.

On the distal surface of a maxillary molar, the furcation is located near the center of the tooth.

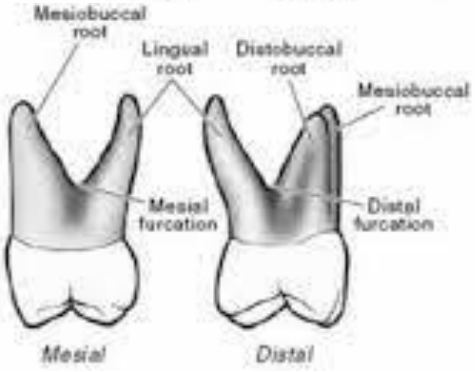

Classification of furcation involvement

Furcation involvement may be classified into 3 degrees depending on the extention of the destruction within inter-radicular area.This classification was suggested by Hamp *et al*. (1975) which include the following criteria of the involved furcation:

- Class I (initial): denotes horizontal loss of periodontal tissue (PD) support not exceeding 1/3 of the width of the tooth. (fig.6a)
- Class II (partial): denotes horizontal loss of PD tissue support exceeding 1/3 of the width of the tooth but not encompassing the total width of the furcation area.(fig.6b)
- Class III (total) denotes horizontal “through and through” destruction of the PD tissues in the furcation area.(fig.6 c)
- Sometimes we have Class IV when the gingiva recedes apically so that the furcation opening is seen clinically.(fig.6 d)

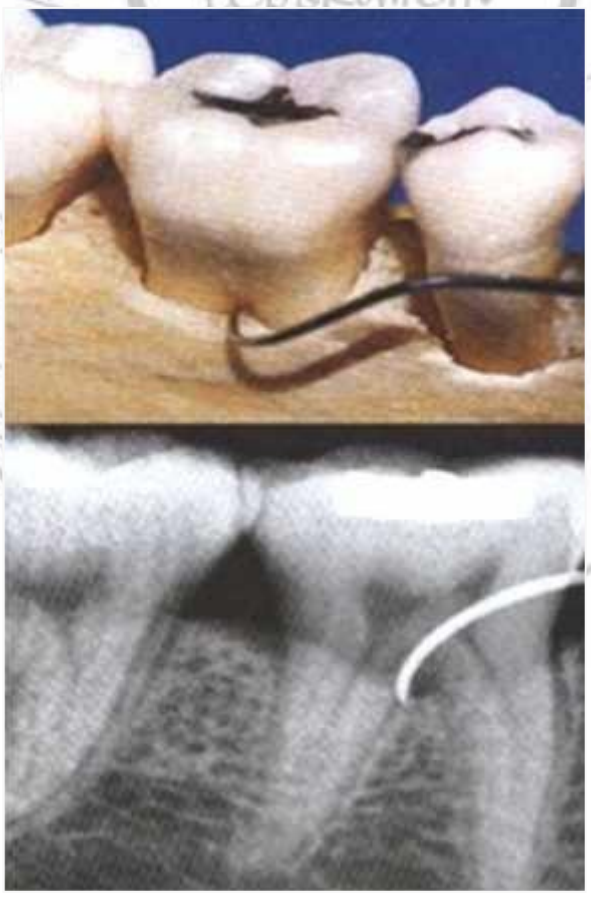

Fig6a



.(fig.6b)

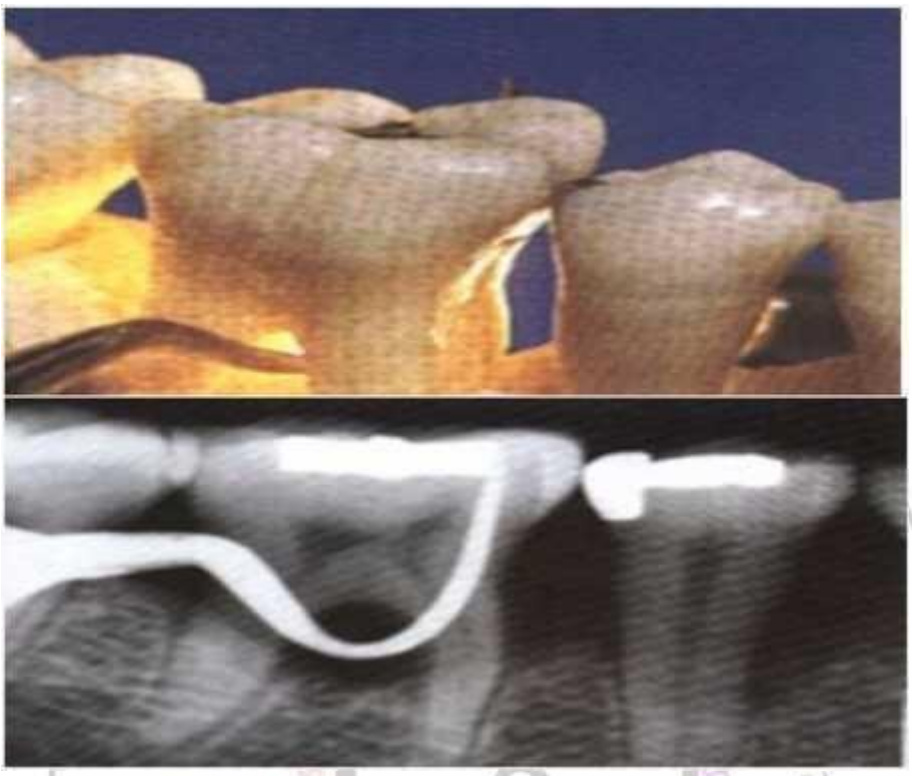

Fig.6c

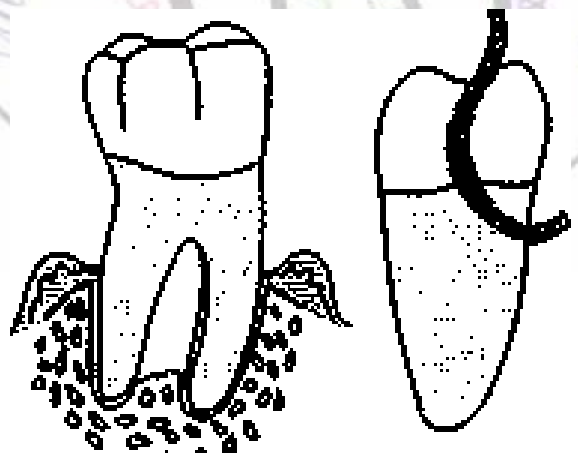

Fig.6d

Diagnosis: The examination should comprise both clinical probing and radiographic analysis.

Probing: The buccal furca of the max. molars and buccal and lingual furcas of the mand. molars are normally accessible for examination by clinical probing by using graduated curved periodontal Probe, explorers or small curettes(fig7). Special furcation probes are available which are rounded & have millimeter indications .These probes are called Naber probes.

Fig7



The clinical examination of furcas on the proximal tooth surfaces may be more difficult when neighboring teeth are present, especially if the contact area

between the teeth is wide, this is particularly in case of max. molars, in which the mesial furcation entrance is located much closer to the palatal than to the buccal tooth surface. Thus, the mesial furcation should be probed from the palatal aspect of the tooth(fig8),while the furca in the distal surface is probed from either the buccal or the palatal aspect.



Fig8

In maxillary premolars the root anatomy often varies considerably. The roots may also harbor irregularities such as longitudinal furrows, invaginations or true furcations, which may open at varying distances from the CEJ.The clinical examination of max. premolars is often difficult due to limited access for probing. It may not always be possible to identify the presence and the degree of furcation involvement in such teeth until a flap is raised in a surgical procedure in the area.

Radiographical analysis

Radiographs must always be obtained to confirm findings made during probing of a furcation-involved tooth. The radiographic examination should include both paralleling “periapical” and vertical “bite-wing” radiographs. In the radiographs the location of the interdental bone as well as the bone level within the root complex should be examined (fig9).



Fig9

Situations may occur when findings from clinical probing and from the radiographs are inconsistent. Thus, the localized but extensive attachment loss which may be detected within the root complex of a maxillary molar with the use of a probe, will not always appear in the radiograph. This may be due to the superimposition in the radiograph of the palatal root and of remaining bone structures.(fig10)



fig10

Differential diagnosis

A lesion in the inter-radicular space of a multi-rooted tooth may be associated with problems originating from the root canal or be the result of occlusal overload. The treatment of a furcation-involved tooth, therefore, should not be initiated until a proper differential diagnosis of the lesion has been made.

Pulpal pathosis may sometimes cause a lesion in the periodontal tissues of the furcation . The radiographic appearance of such a defect may have some features in common with a plaque associated furcation lesion. In order to differentiate between the two lesions the vitality of the affected tooth must *always* be tested. If the tooth is vital, a plaque-associated lesion should be suspected. If the tooth is non-vital, the furcation involvement may have an endodontic origin. In such a case, proper endodontic treatment must *always* precede periodontal therapy.

In fact, endodontic therapy may resolve the inflammatory lesion, soft and hard tissue healing may occur and the furcation defect will disappear(fig11).



Fig11

Trauma from occlusion

Forces elicited by occlusal interferences, e.g. bruxers and clenchers , may cause inflammation and tissue destruction or adaptation within the inter-radicular area of a multi-rooted tooth. In such a tooth a radiolucency may be seen in the radiograph of the root complex. The tooth may exhibit increased mobility. Probing, however, fails to detect an involvement of the furcation. In this

particular situation, occlusal adjustment must always precede periodontaltherapy.

Prognosis

Maxillary first premolars and maxillary as well as mandibular molars are the teeth with multiple roots. Furcation involvement will be likely to occur in these multirooted teeth. Maxillary first premolar often shows fusion of the roots and the furcation area may be located very much apically and also the roots of the maxillary first premolars are placed buccally and palatally with furcation opening in a mesiodistal direction. For these reasons, furcation involvement in maxillary first premolar has poor prognosis.

In the case of maxillary molars furcations may open bucally, mesially and distally because of the presence of the three roots. Since access from proximal areas is difficult for plaque control, prognosis of furcation involvement in maxillary molars is not good.

Mandibular molars have two roots, placed mesially and distally and the furcation opens buccolingually. The roots are usually divergent especially in mandibular first molars. As a result prognosis of furcation involvement in mandibular molar (especially the first molar) is considered good.

Treatment of furcation involvement:

- Degree I: scaling + root planning
  furcation plasty
- Degree II: furcation plasty
  Tunnel preparation
  Root resection & tooth hemisection
  Tooth extraction
  Guided tissue regeneration
- Degree III: Tunnel preparation
  Root resection & tooth hemisection
  Tooth extraction
  Guided tissue regeneration

Treatment of advanced forms of periodontal disease frequently includes surgical procedures. **The general objectives of these procedures are:**

1. To obtain visibility and access to the root surfaces for proper professional debridement.
2. To eliminate the pathologically deepened pockets
3. To establish a morphology in the dento-gingival region which facilitates proper, self-performed tooth cleaning

Objectives of Treatment of furcation involvement

1- The elimination of the microbial plaque from the exposed surfaces of the root complex.

2- The establishment of an anatomy of the affected surfaces that facilitates proper self-performed plaque control.

Degree I

1- Scaling and root planing:

Is the removal of hard and soft bacterial deposits from the tooth and root surfaces in order to simplify the self performed plaque control measures.

2- Furcation plasty: It is the therapeutic measure that is preferably used in the treatment of advance degree I & initial degree II involvement. It include the following procedures:

1. Reflection of a mucoperiosteal flap to obtain proper access to the interradicular area.

2. Removal of hard and soft bacterial deposits and inflammatory soft tissue from the furcation area.
3. Odontoplasty: removal of tooth substance in the furcation area in order to widen a narrow entrance of the furca and to reduce the horizontal depth of the involvement.
4. Osteoplasty: recontouring of bony defects in the furcation area.
5. Repositioning and suturing of the flap (Fig 1).

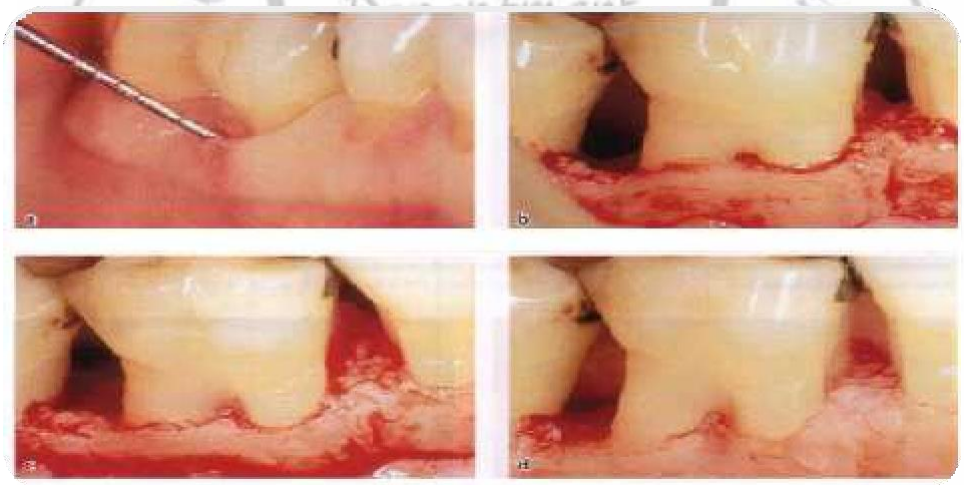

- Aims of furcation plasty:

  Is the removal of all the soft and hard materials and then establish a good area for the patient for self performed plaque control measures.

We have some side effects in recontoring the tooth by this procedure:

1. Hyper sensitivity of the area

2. Root surface caries
3. More destruction of the periodontal tissue.

Degree II

1- furcation plasty

2- Tunnel preparation (Degree II& III)

3- Root resection& tooth hemisection (Degree II& III)

4-Tooth extraction (Degree II& III)

5-Guided tissue regeneration (Degree II& III)

Notes: scaling and root planing is made in the treatment of any degree of furcation involvement and not only for degree I.

Tunnel preparation: used in cases of degree II& mostly degree III furcation involvement. It is a surgical exposure of the entire furcation area. Buccal &lingual mucoperiostial flap is elevated , root surface is scaled & planed ,bone is recontoured . We remove all the infected materials, in the bone, in the bottom of the pocket and on the sides of the roots so we need odontoplasty and osteoplasty then either left exposed or covered by tissue depending on the patient whether maintaining high level of plaque control because of high risk of root caries .This procedure is applied mostly to lower molar bifurcation (has mesial &distal roots) so it provide space for spiral brush to pass freely through the furcation from the buccal to lingual side (Fig2).

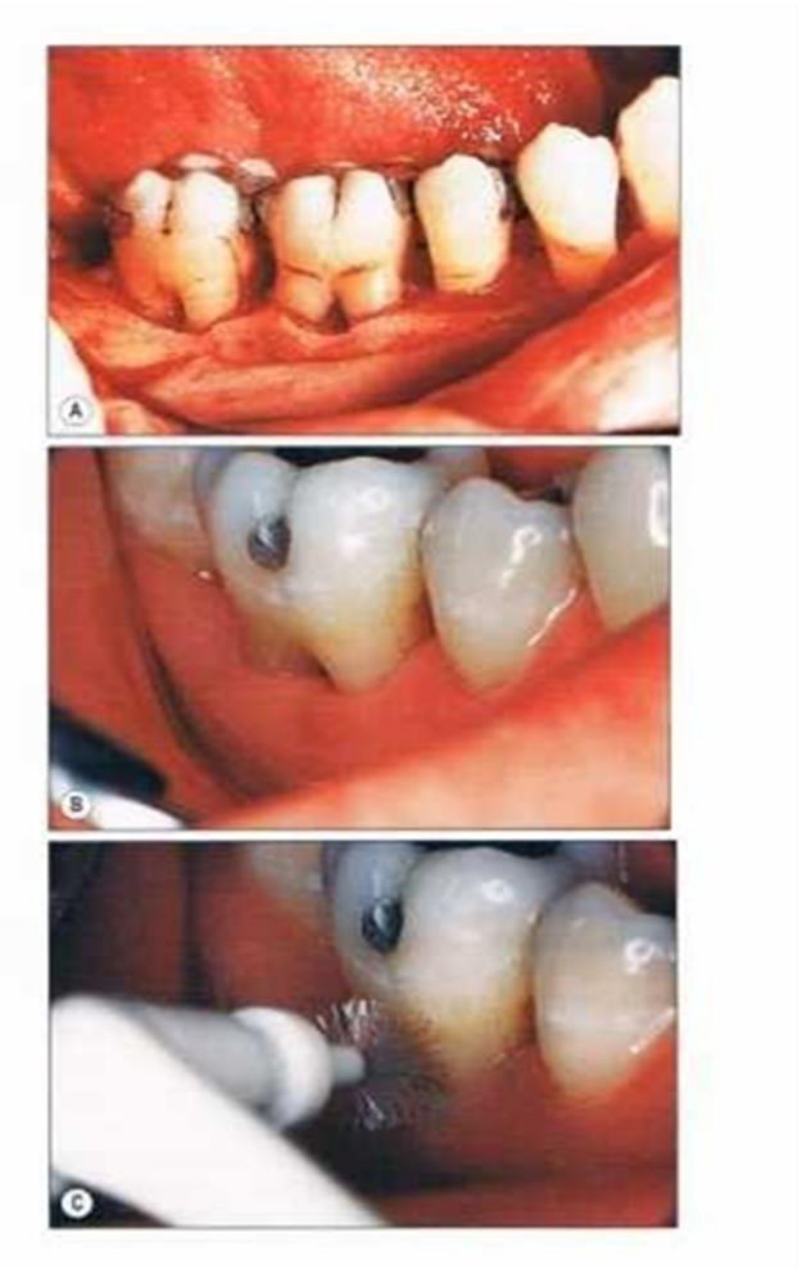

Fig2

This procedure is more valuable in treatment of lower molars because

1. Short root trunk
2. Wide separation angle
3. Long divergence between mesial &distal root .

Root resection/Separation , tooth division& hemisection:

Root Separation :It involves the sectioning of the root complex and the maintenance of all roots.(see the figure below)

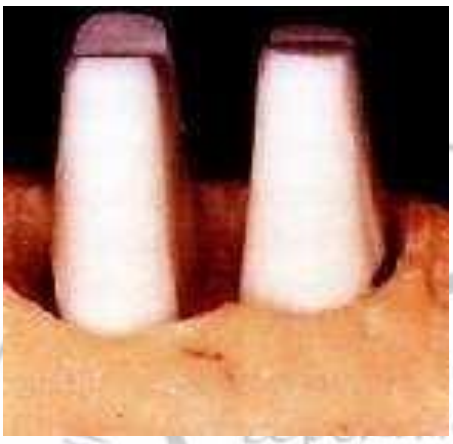

Root resection is the procedure of choice in cases of deep degree II and III involvement and includes the removal of one or more roots from a multi rooted tooth to allow access to the furcation area for cleaning (Fig3.A). After raising buccal & palatal flaps, sectioning should start in the affected furcation and its path may be planned by passing a blunt probe through the space from buccal to palatal. The cut is made with a tapered diamond bur cooled by sterile water. A wide enough space should be made to elevate the root, taking care not to remove too much substance from the part of the tooth

To be retained.

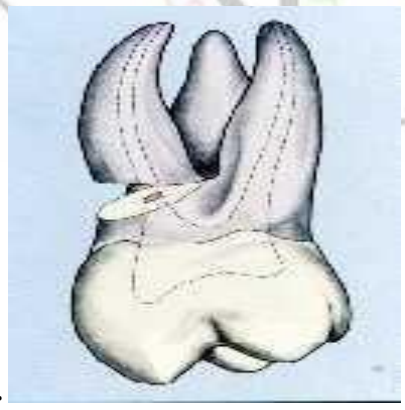

Tooth division *is* indicated for extensive furcation involvement of lower molars where bone loss around both roots is similar. In this procedure ,the tooth is completely divided by extending a cut from the roof of the furcation through the crown after raising a buccal & lingual flaps . Each half of the tooth is reshaped into a single-rooted tooth& will be subsequently prepared to receive a crown. In this way a two-rooted molar is converted into two single-rooted teeth (Fig3 B).

Hemisection (Fig. 3C)

This is indicated for furcation involvement of lower molars where there is extensive bone resorption around one of the roots. It must be ensured that adequate restoration of the remaining half of the crown is possible before embarking on this procedure. A buccal & lingual flaps are raised. The sectioning process is begun at the roof of the furcation , extending upwards to divide the tooth. The remaining root is scaled and planed. The remaining half of the crown is carefully contoured and smoothed and the flaps are repositioned to eliminate any pocketing. After healing the tooth will be crowned usually forming part of the bridge to replace the missing portion.

The risk of leaving “over hangs” of the tooth substance behind during tooth hemisection and root resection is an incitement to carry out these procedures after flap elevation.

Fig3A,B&C

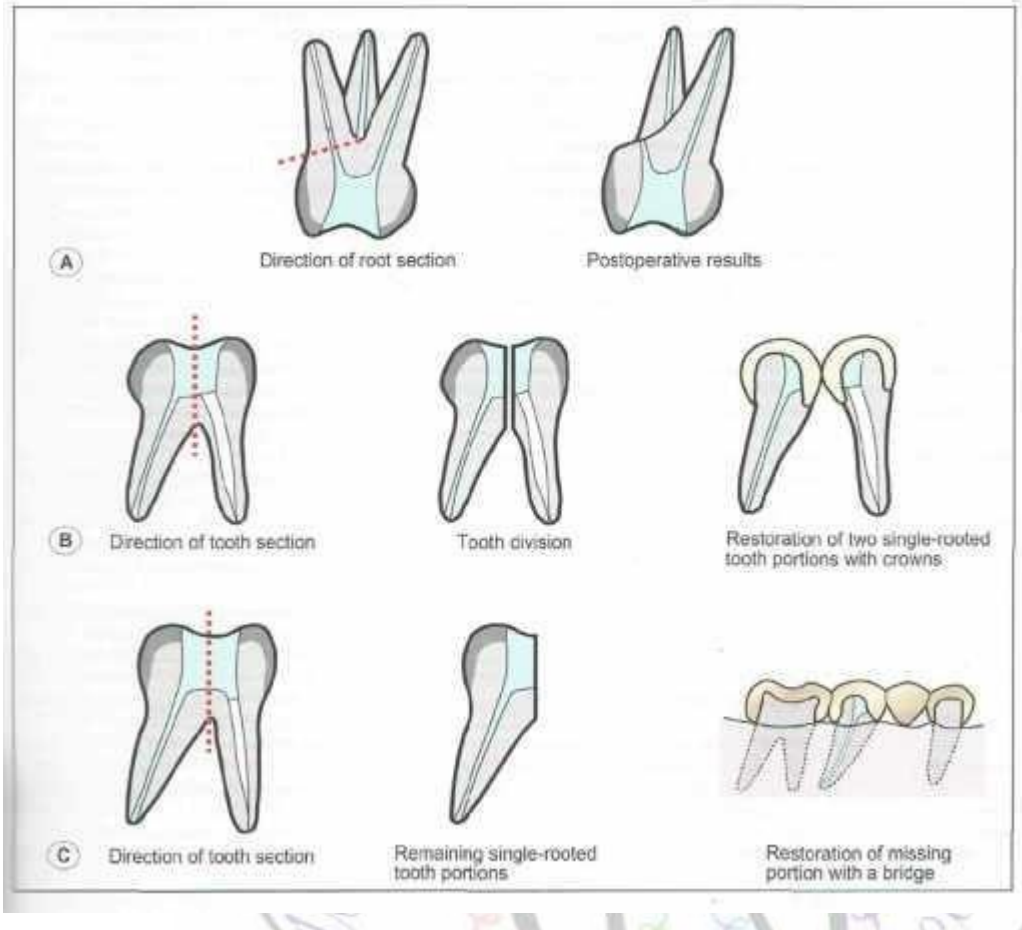

The root resection & hemisection should be preceded by endodontic treatment for the root that will be retained in the place. A small cavity is made at the entrance of the canal of the root to be removed & packed with amalgam to produce a permanent seal at the point of amputation. Also during endodontic treatment, we may found curved & calcified root that should be scarified) .

- In selection of root to be retained following root seperation, the following factors should be considered:

1. The amount of supporting tissues remaining around the various roots . (we should maintain the root with more bony support).
2. The stability of the individual roots.
3. The root and root canal anatomy with respect to endodontic and restorative treatment procedures (curved, narrow & obliterated root should be sacrificed).
4. The periapical condition of the roots
5. The position of the various teeth (roots) in the alveolar process in relation to adjacent and opposing teeth (to be used as abutment for bridge or other restorative treatments).
6. The oral hygiene of the patient
7. General health of the patient
8. Neighboring teeth should be healthy.

In case where, for example, the furcation of a 1st mand. Molar is involved to extent which calls for root resection, it is usually easy to decide which root is preferable to maintain from the periodontal aspect.

If the amount of the remaining periodontium around the 2 roots is similar, it is often preferable from the endodontic point of view to maintain the distal root because this root has generally only one wide root canal and is therefore easily accessible for endodontic treatment .

Root resection of maxillary 1st premolars is possible only in rare cases due to the anatomy of the tooth.

The furca is often located at the apical level that the maintenance of one root serves no meaningful purpose. In most cases, therefore, a furcation involvement of degree III in maxillary 1st premolar leads to tooth extraction.

In cases of max.molars, when we have furcation involvement calls for root resection, we can preserve the 2 buccal roots (MB, DB) or the palatal root with one of these 2 roots , the decision depend on the previously discussed factors. We cannot maintain the palatal root only because of its relation to the neighboring & opposing teeth (cannot be used as abutment).

Tooth extraction:

The indications f or extraction are:

1. When the destruction of the periodontium has progressed to such a level that no root can be preserved.
2. When the maintenance of the affected tooth will not improve the overall treatment.
3. When treatment of furcation involved tooth will not result in condition which can be properly maintained by self performed plaque control measures.

Failures in furcation therapy could be due to:-

1. Inadequate plaque control.
2. Poor root resection technique.
3. Improper restorations.
4. Endodontic failures.
5. Cracked roots.
6. Root caries.

The best prognosis of furcation involvement treatments is obtained from the root resection& hemisection while the least prognosis is the tunnel preparation because the patient cannot remove the plaque completely from the central part of the furca so we will end with pulp involvement.

Regeneration of Furcation Defects :

Guided tissue regeneration (GTR) &Bone grafting:-

Some of the periodontal surgical techniques , not only aimed to eliminate the disease but also aim to produce regeneration of periodontal tissue which has been destroyed by disease ,& thereby produce increased attachment level .From these techniques are guided tissue regeneration& bone grafting .

GTR techniques have been successfully used to treat Class II furcation involvement on mandibular molars .less favorable results have been reported in other types of furcation defects. The aim of this procedure is the formation of new connective tissue attachment consisting of periodontal ligament fibers embedded into bone & cementum. Alveolar bone & cementum have good powers of regeneration provided that the necessary cell types & cell signals are present. The same is true for periodontal ligament, but for this to form a functional attachment the collagen fibers must become enclosed by newly formed bone on one surface & cementum on the other. This requires the regeneration of the three tissues to be finely integrated.

In GTR technique ,a barrier membrane is adapted to fit over the defect & the root of the tooth in order to guide the fibroblast cell of periodontal ligament to contact the root surface during healing & prevent other cells of oral epithelium ,gingival connective tissue from contacting the root surface so that leading to new connective tissue attachment (Fig4). These membranes are of two types:

1- Non – resorbable membranes.

2- Bioresorbable membranes.

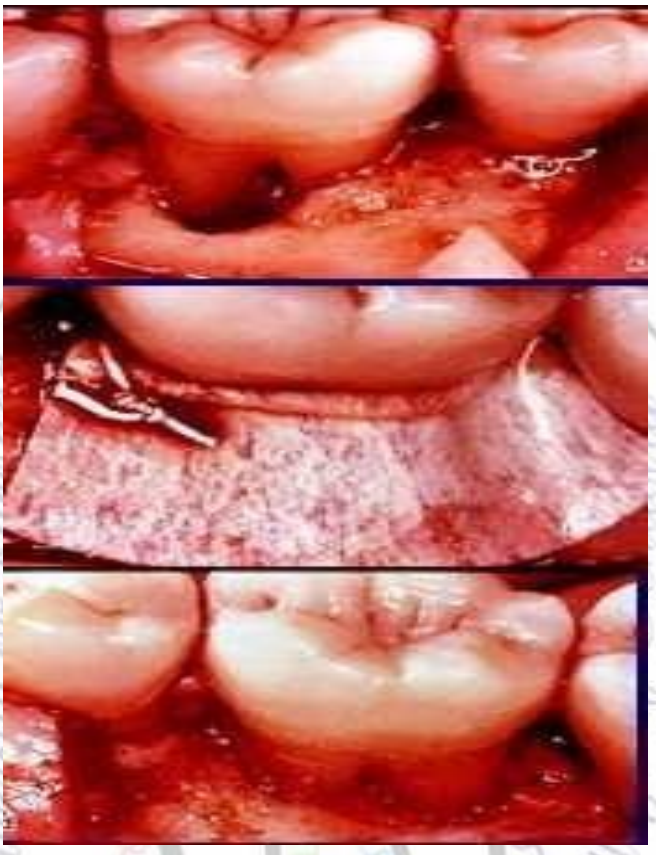

Fig 4) GTR

Bone substitute materials or bone grafting: An examples of bone graft are the following:

A-Autogenous bone grafting: Grafts transferred from one position to another within the same individual.

B-Allografts : Grafts transferred between genetically dissimilar members of the same species.

- Freeze, dried bone allograft
- Demineralized Freeze -dried bone

C-Xenografts: Grafts taken from a donor of another species.

D- Alloplastic materials: Synthetic or inorganic implant materials which are used as substitutes for bone grafts.

- Hydroxyapatite
- Tricalcium phosphate

Combinations of GTR with the use of bone grafts have been shown to have some advantages over either technique used alone. Clinical studies found a significantly greater gain of mean probing attachment with the combination compared to GTR alone.(see the figure below)