# Facial bones

## 1. ZYGOMATIC BONE (ZYGOMA)

➢ **Characteristics**

- Forms the majority of the skeleton of the cheek.
- Provides attachment of the masseter muscle.
- There are 2 zygomatic bones.

➢ **Parts:**

1. Frontal process
2. Temporal process
3. Maxillary process

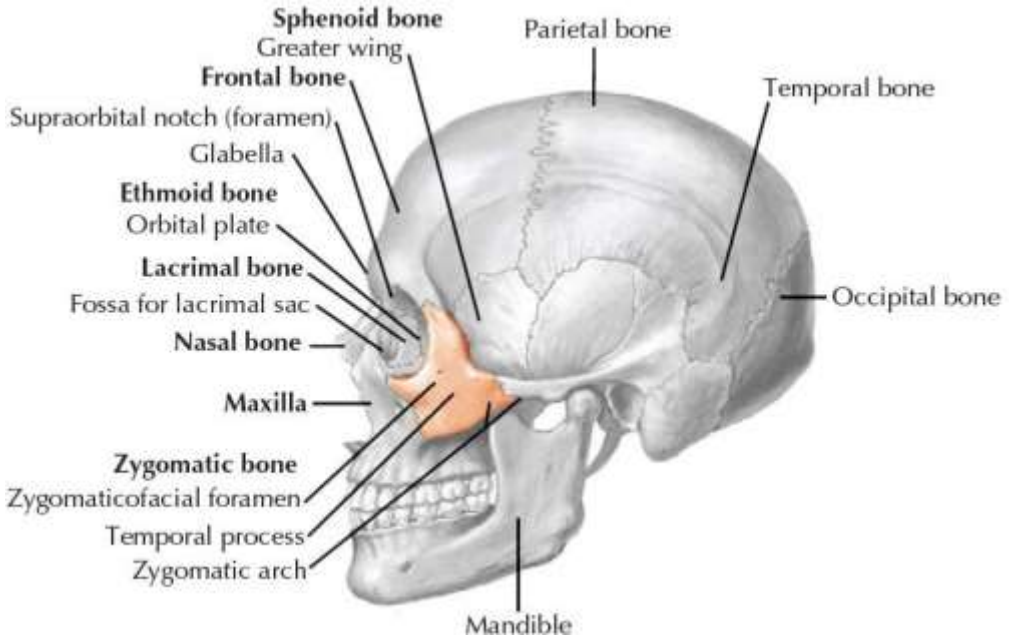

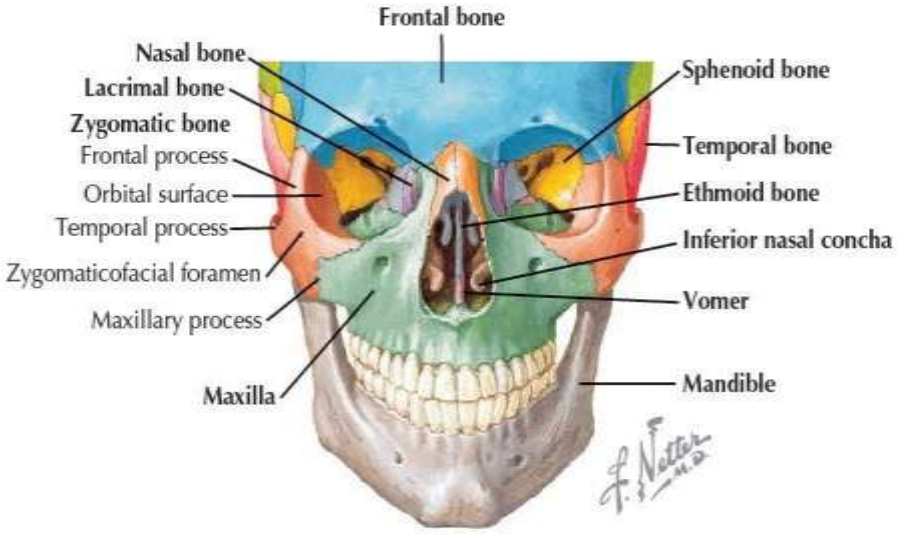


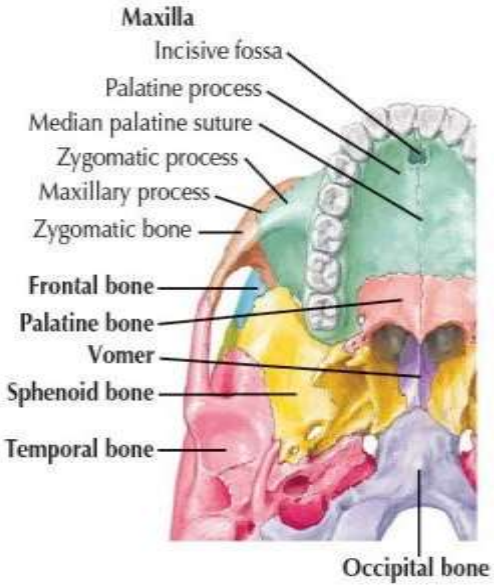


## 2. MAXILLARY BONES (MAXILLA)

➢ **Characteristics**

- Forms the majority of the skeleton of the face and the upper jaw.
- Contains the maxillary paranasal sinus.
- There are 2 maxilla bones (maxillae)

**Parts:**

1. Body
2. Frontal process
3. Zygomatic process
4. Palatine process

5. Alveolar process

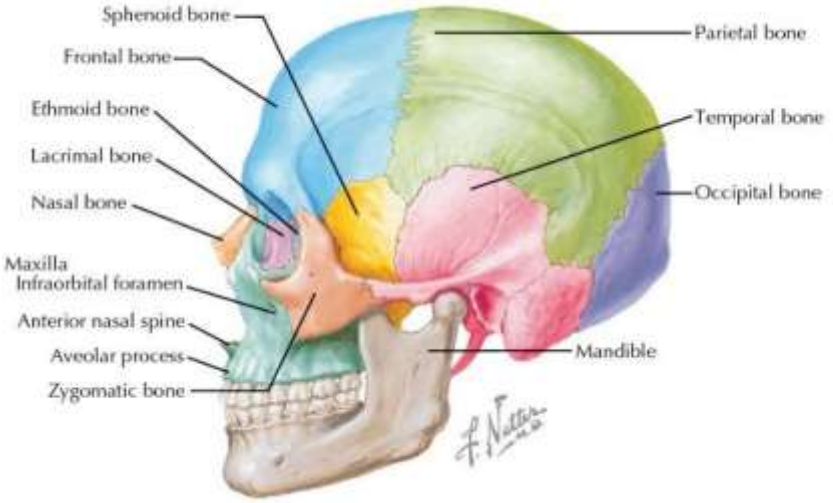


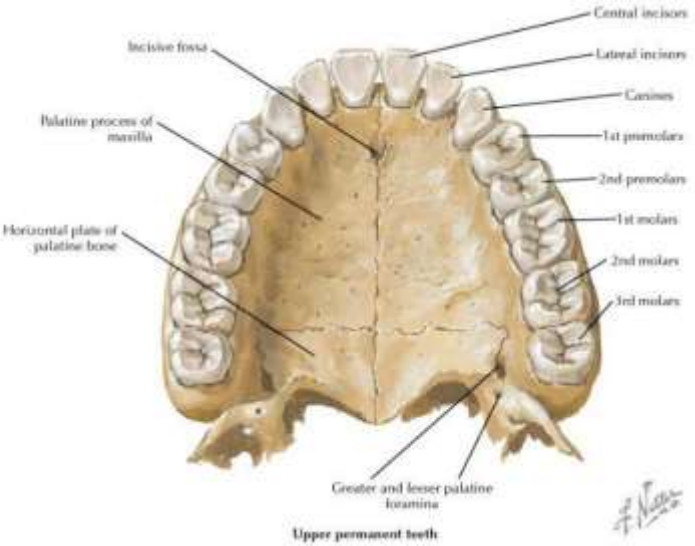


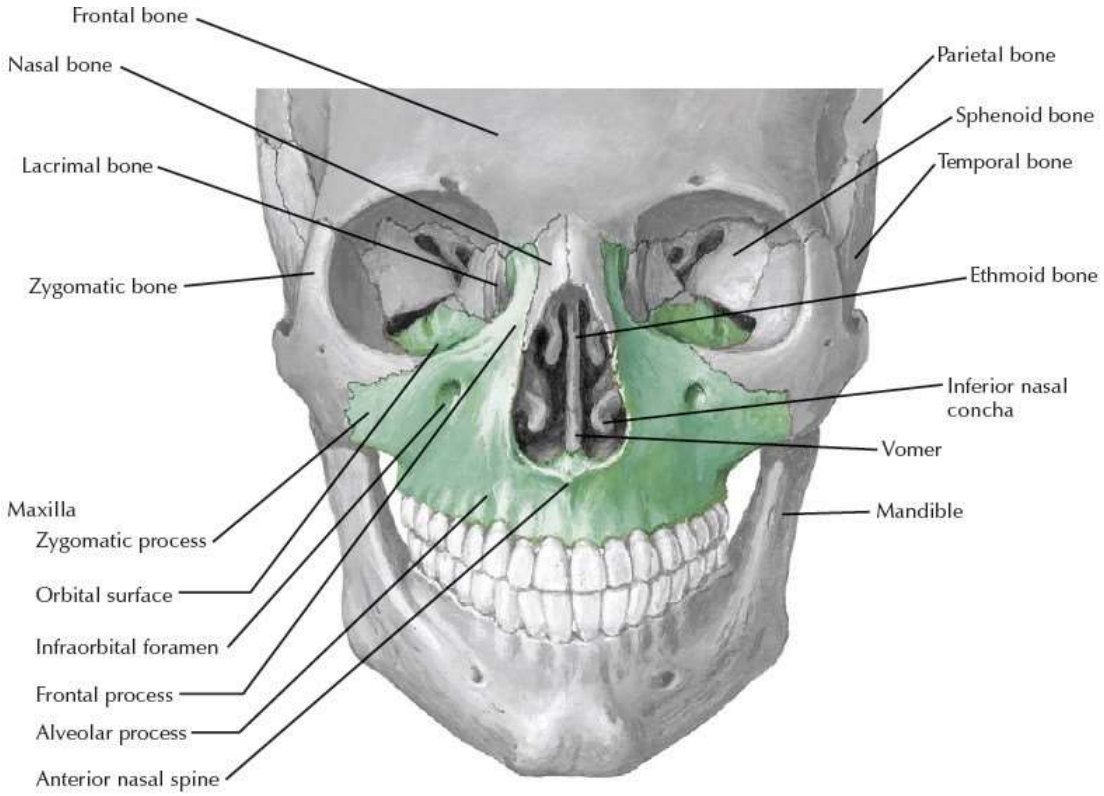


## 3. NASAL BONE

- **Characteristics**
  - Inferior portion forms the superior margin of the nasal aperture.
  - Forms the bridge of the nose.
  - There are 2 nasal bones.

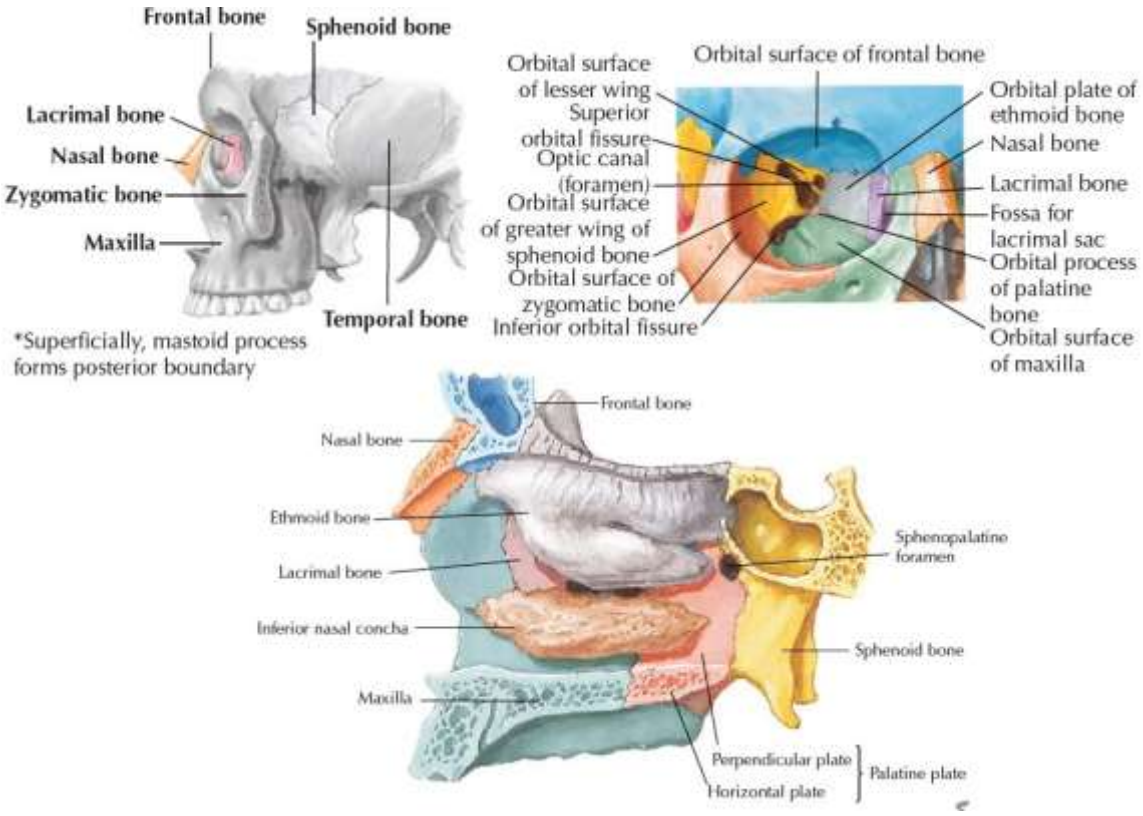


- Inferior portion of the nasal bones attaches with the lateral nasal cartilages and septal cartilage.

### 4. LACRIMAL BONE

➢ **Characteristics**

- Lacrimal bone issmall and rectangular in shape and very thin and fragile
- There are 2 lacrimal bones
- Forms a small portion of the medial wall of the orbit

### 5. VOMER

➢ **Characteristics**

- Shaped like a “plough”
- Forms the posterior inferior part of the nasal septum
- There is 1 vomer bone

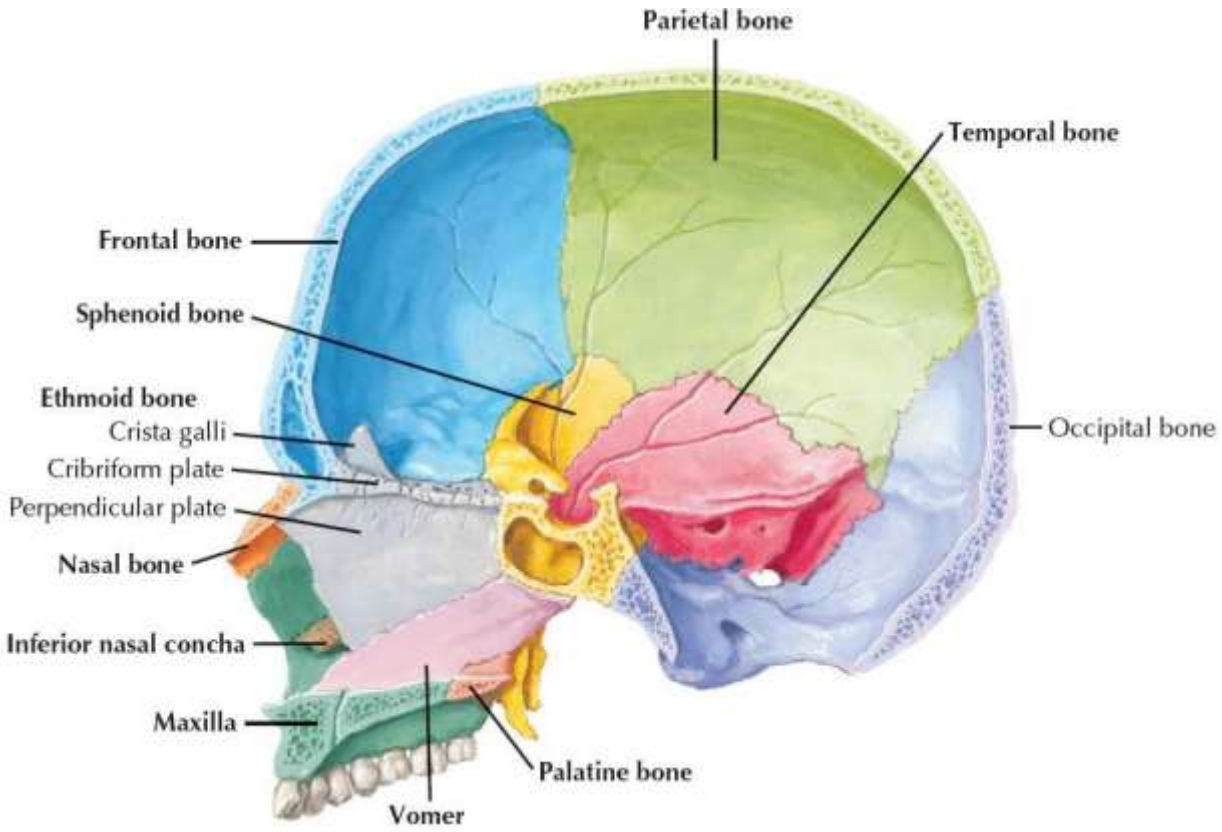


## 6. PALATINE BONE

- **Characteristics**
  - Forms part of the nasal cavity and the hard palate, it is L-shaped
  - There are 2 palatine bones

## 7. INFERIOR NASAL CONCHA

- **Characteristics**
  - Is described as a curved bone that forms part of the lateral wall of the nasal cavity.
  - There are 2 inferior nasal conchae.
  - Lies within a curve in the lateral wall of the nasal cavity.

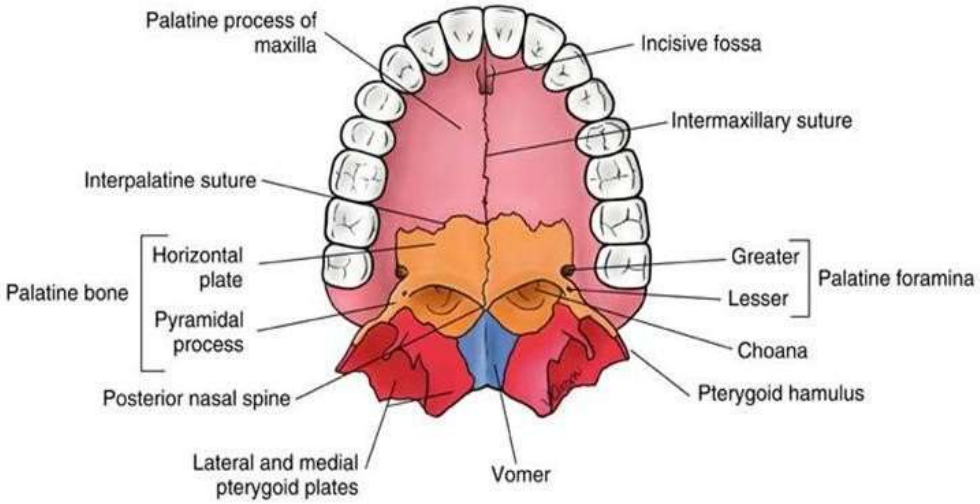


## MANDIBLE

**Characteristics**

- Forms the lower jaw
- Described as horse shoe shaped
- All muscles of mastication attach to the mandible
- There is 1 mandible

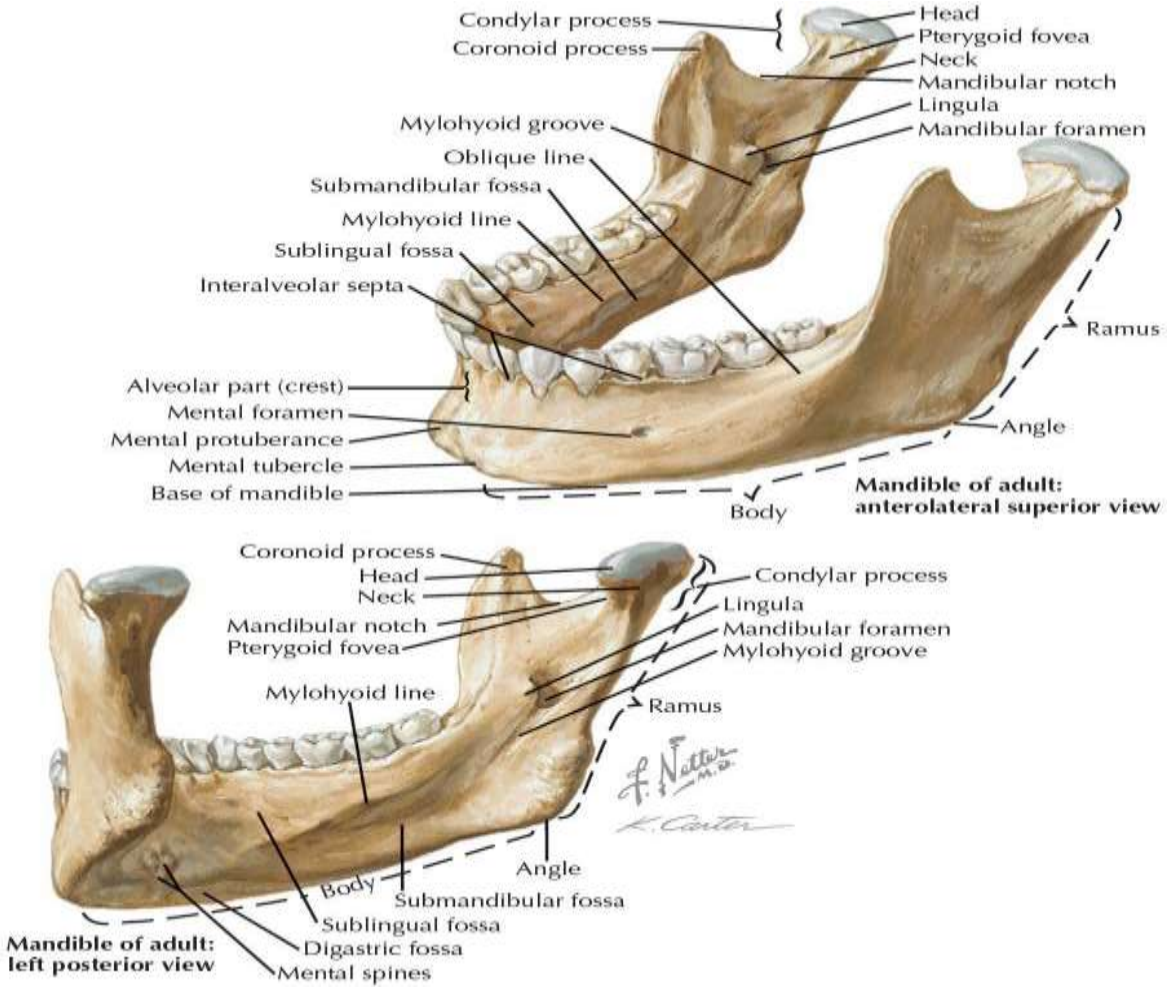
Condylar process
Coronoid process
Head
Pterygoid fovea
Neck
Mandibular notch
Lingula
Mandibular foramen
Mylohyoid groove
Oblique line
Submandibular fossa
Mylohyoid line
Sublingual fossa
Interalveolar septa
Ramus
Alveolar part (crest)
Mental foramen
Mental protuberance
Mental tubercle
Base of mandible
Angle
Body
Mandible of adult:
anterolateral superior view
Coronoid process
Head
Neck
Mandibular notch
Pterygoid fovea
Condylar process
Lingula
Mandibular foramen
Mylohyoid groove
Mylohyoid line
Ramus
Angle
Body
Submandibular fossa
Sublingual fossa
Digastric fossa
Mental spines
Mandible of adult:
left posterior view