Skeletal system of the body

❖ Axial skeleton

- Skull

The skull is composed of several separate bones united at immobile joints called sutures. The connective tissue between the bones is called a sutural ligament. The mandible is an exception to this rule, for it is united to the skull by the mobile *temporomandibular joint.*

The skull is composed of 22 bones, 8 of these bones form the **cranium** (which contains the brain and meninges), and 14 of these form the **face**. The **vault** is the upper part of the cranium, and the **base of the skull** is the lowest part of the cranium.

☒ **Cranium** consists of the following bones, two of which are paired :

- Frontal bone: 1
- Parietal bones: 2
- Occipital bone: 1
- Temporal bones: 2
- Sphenoid bone: 1
- Ethmoid bone: 1

☒ **Facial** bones consist of the following, two of which are single:

- Zygomatic bones: 2
- Maxillae: 2
- Nasal bones: 2
- Lacrimal bones: 2
- Vomer: 1
- Palatine bones: 2
- Inferior conchae: 2
- Mandible: 1

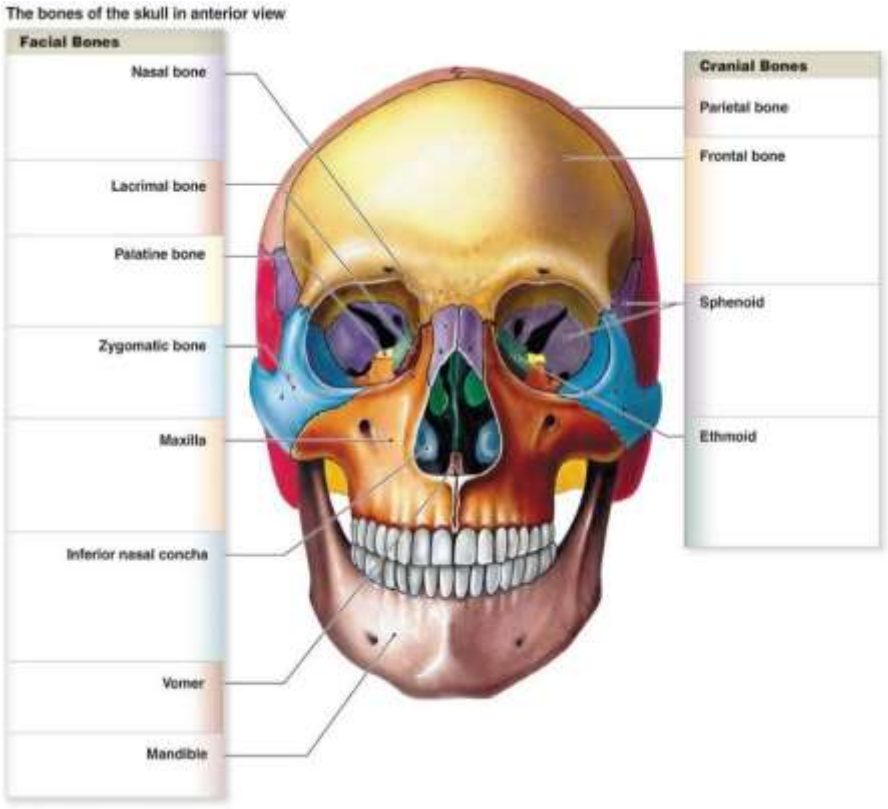

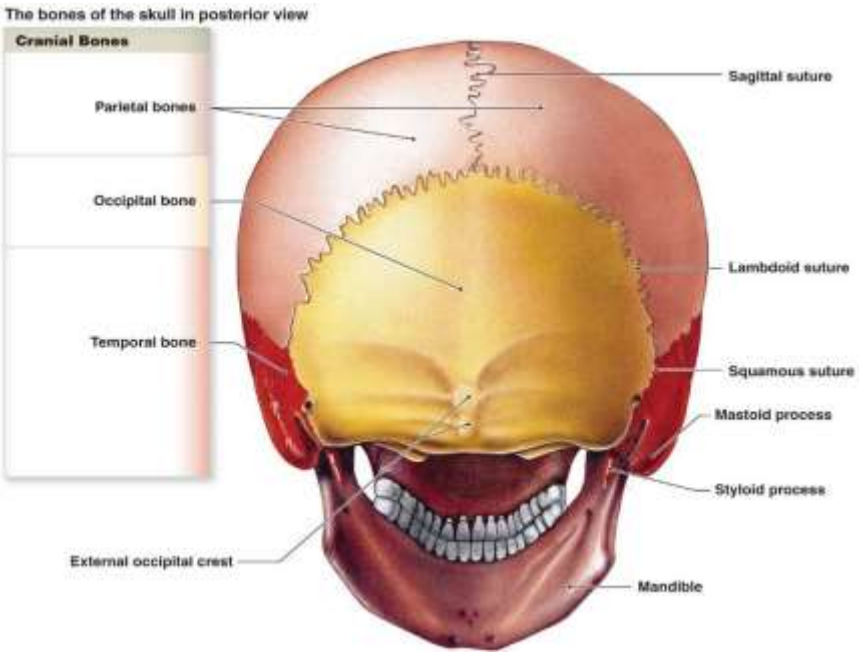

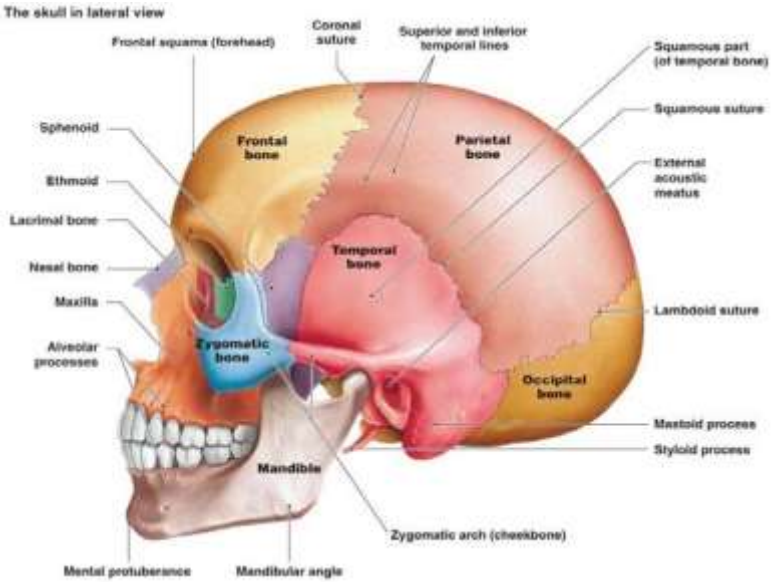

☒Cranium

1. **FRONTAL BONE**

1. Orbital portion

- Forms the roof of the orbit and floor of the anterior cranial fossa.

2. Nasal portion

- Articulates with the nasal bones and the frontal process of the maxilla to form the root of the nose.

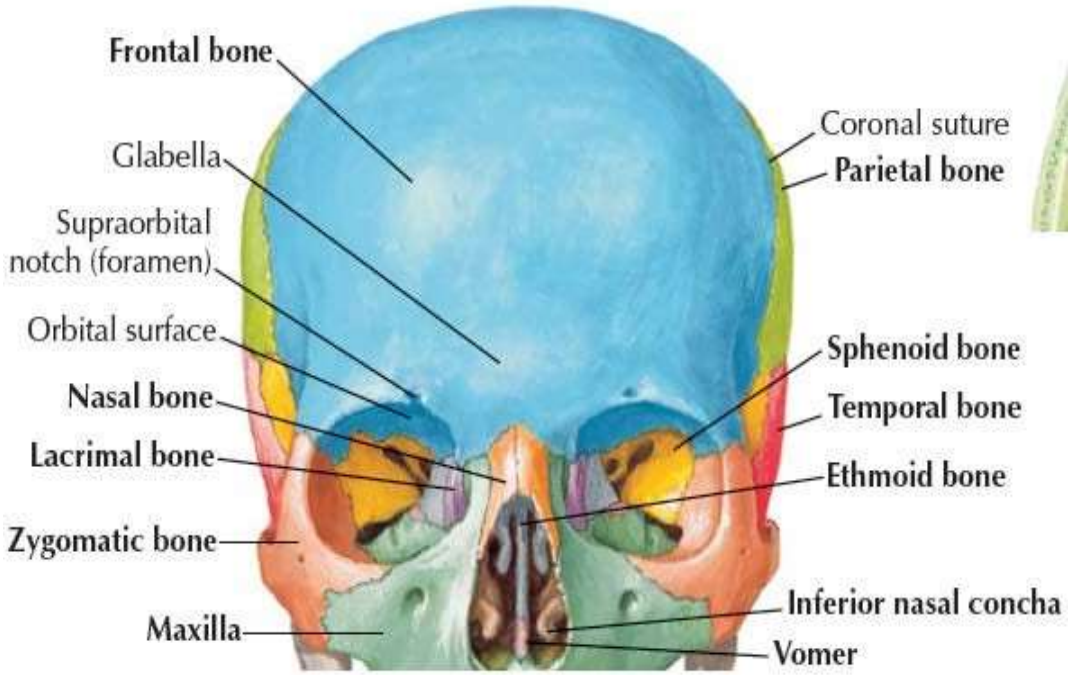

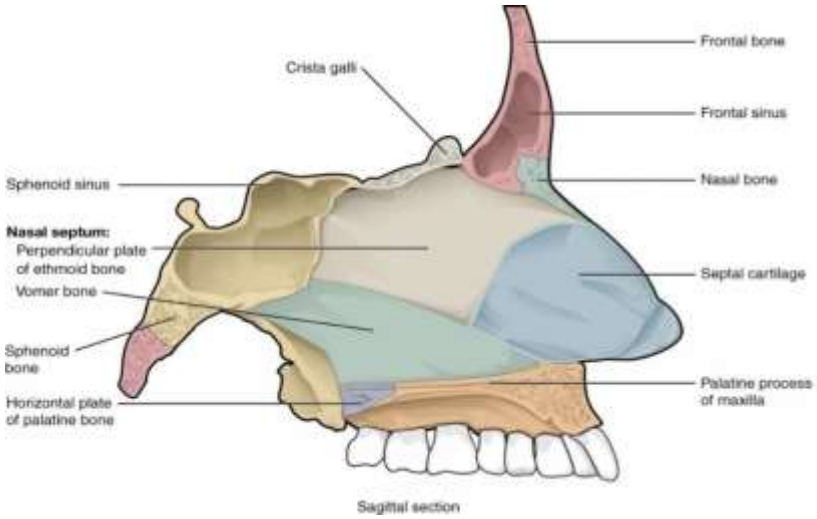

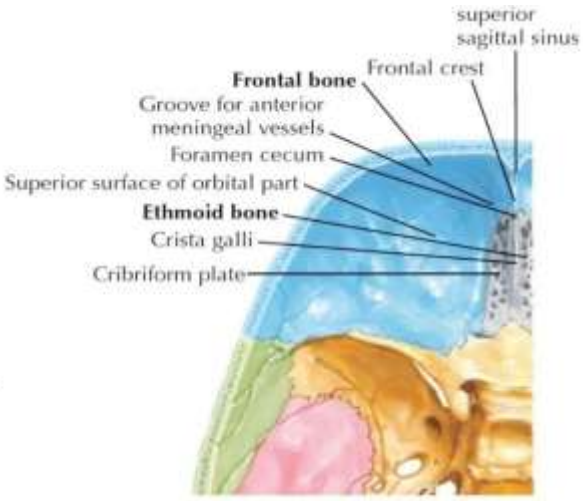

Borders	Coronal suture separates it from the parietal bone Sphenofrontal suture separates it from the sphenoid bone Zygomaticofrontal suture separates it from the zygomatic bone Nasofrontal suture separates it from the nasal bone Frontomaxillary suture separates it from the maxilla
Articulations	Twelve bones: the sphenoid, the ethmoid, two parietals, two nasals, two maxillae, two lacrimals, two zygomatics

2. PARIETAL BONE

➢ Characteristics

- Forms the majority of the cranial vault
- The four corners of the parietal are not ossified at birth and give rise to the fontanelles.
- There are 2 parietal bones.
- Has parietal foramen

1.

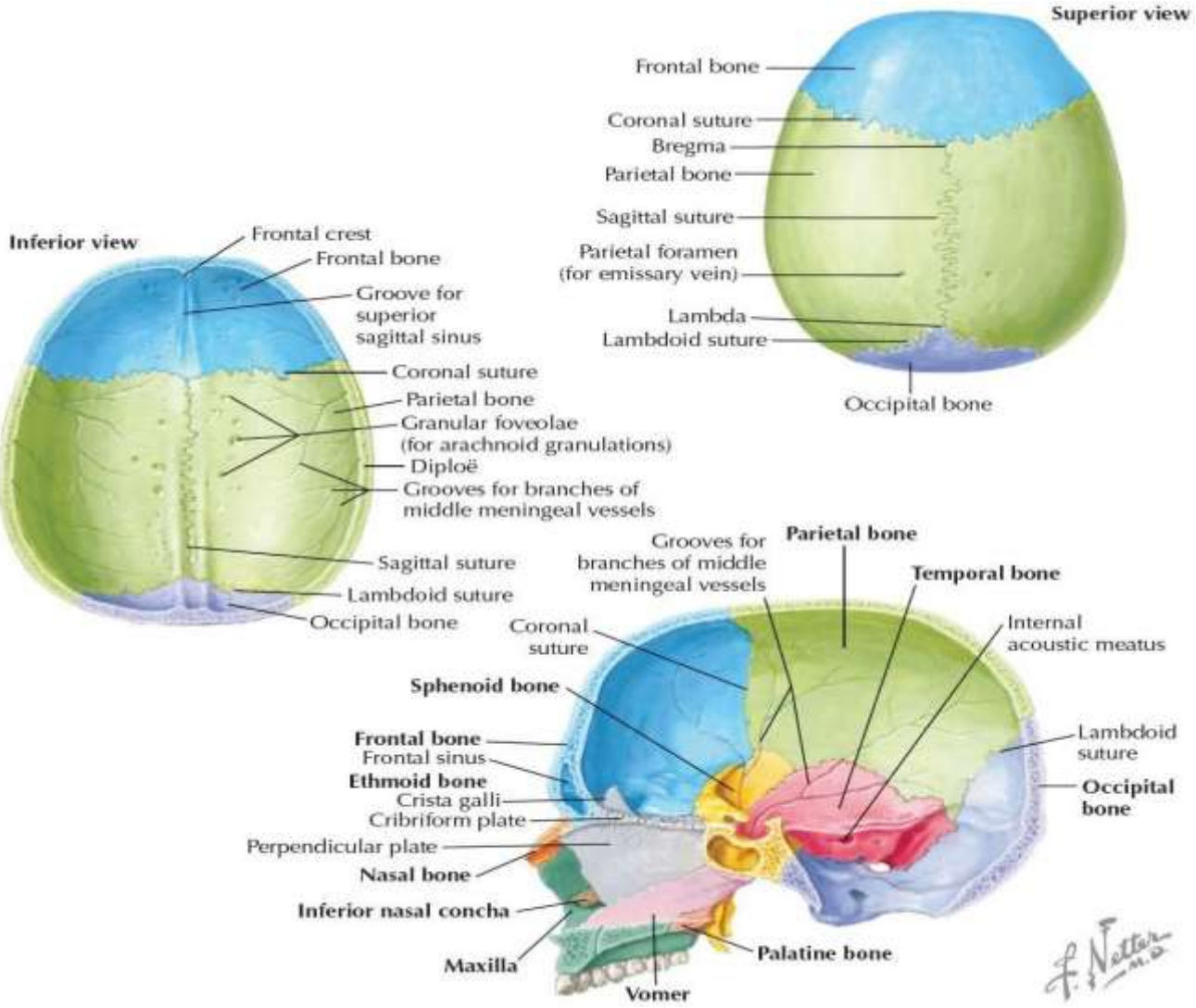

3. OCCIPITAL BONE

- **Characteristics**
  - Forms the posteriorpart of the cranial vault.
  - Articulates with the atlas.
  - There is 1 occipital bone.
  - .

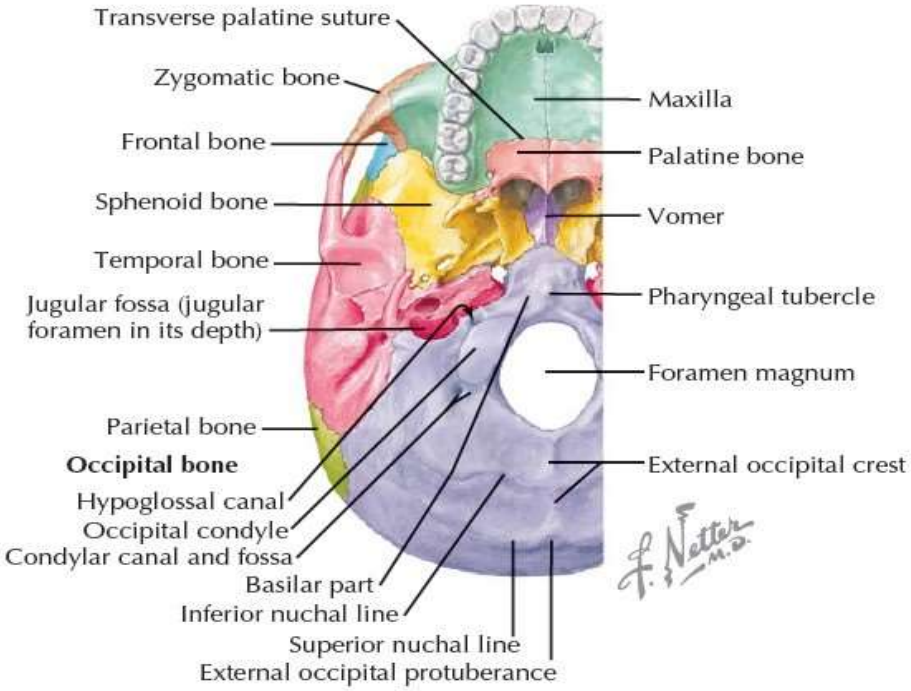
Transverse palatine suture
Zygomatic bone
Frontal bone
Sphenoid bone
Temporal bone
Jugular fossa (jugular foramen in its depth)
Parietal bone
Occipital bone
Hypoglossal canal
Occipital condyle
Condylar canal and fossa
Basilar part
Inferior nuchal line
Superior nuchal line
External occipital protuberance
Maxilla
Palatine bone
Vomer
Pharyngeal tubercle
Foramen magnum
External occipital crest
F. Netter M.D.

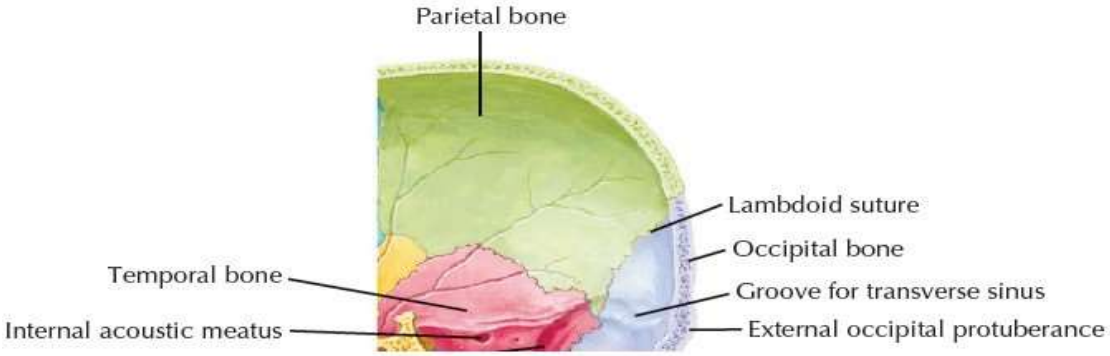
Parietal bone
Lambdoid suture
Occipital bone
Temporal bone
Groove for transverse sinus
Internal acoustic meatus
External occipital protuberance

4. TEMPORAL BONE

- **Characteristics**
  - Help form the base and the lateral walls of the skull.
  - House the auditory and vestibular apparatuses.
  - Contain mastoid air cells.
  - There are 2 temporal bones.
- **Parts:**

1. **<u>Squamous part:</u>**
   - The largest portion of the bone.
   - Three portions to the squamous part:
2. **<u>Petrous part:</u>**
   - Forms the solid portion of bone.
   - The auditory and vestibular apparatuses are located within the petrous part.
3. **<u>mastoid part</u> :**

- extends posteriorly and has large mastoid air cells.
- superior serrated edge for the articulation with the mastoid angle of the parietal bone, posterior also serrated for articulation with the inferior border of the occipital bone, anterior fused with the squamous part.

4. **Tympanic part:**

A plate of bone forming the anterior,posterior, and inferior portions of the external acoustic meatus.

- Anterior part forms the posterior portion of the glenoid fossa

5. **Styloid process:**

- A projection from the temporal bone.
- The stylomastoid foramen lies posterior to this process.

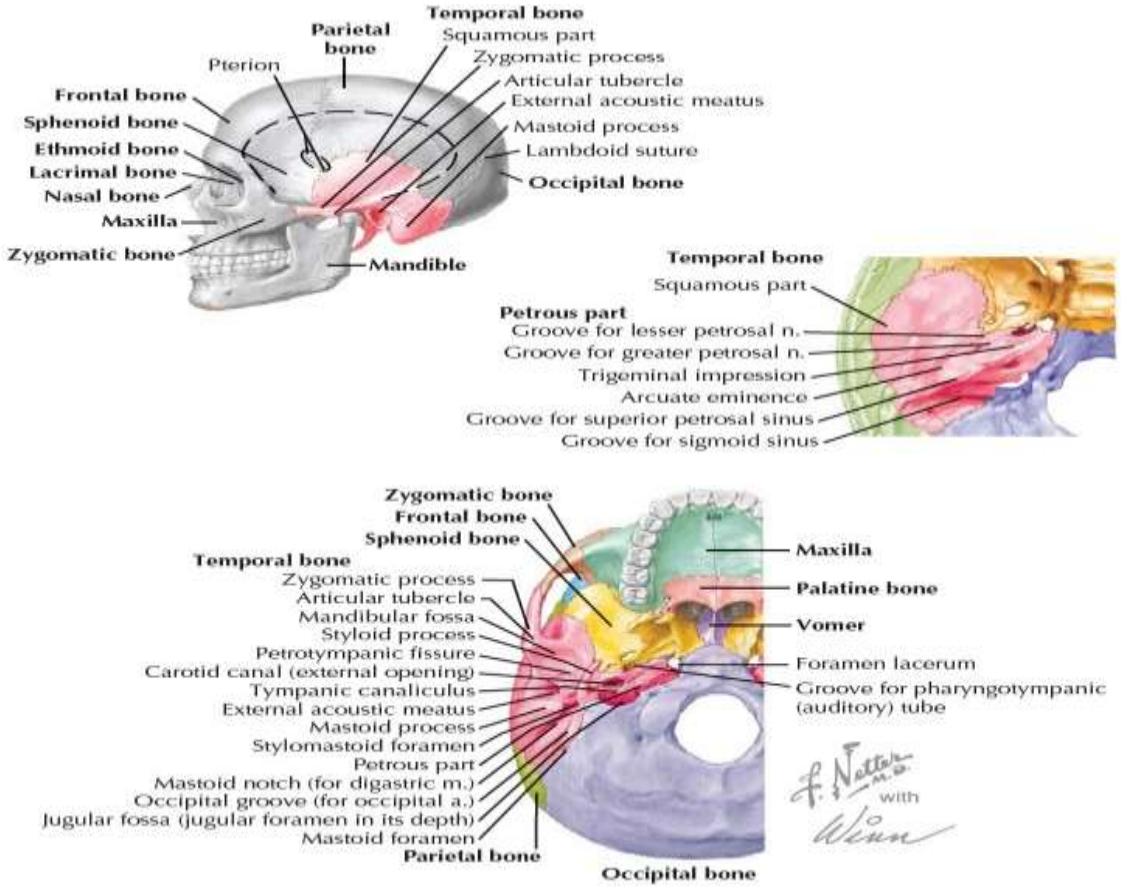

5. SPHENOID BONE

- **Characteristics**

- Contains the sphenoid paranasal sinus.
- There is 1 sphenoid bone.

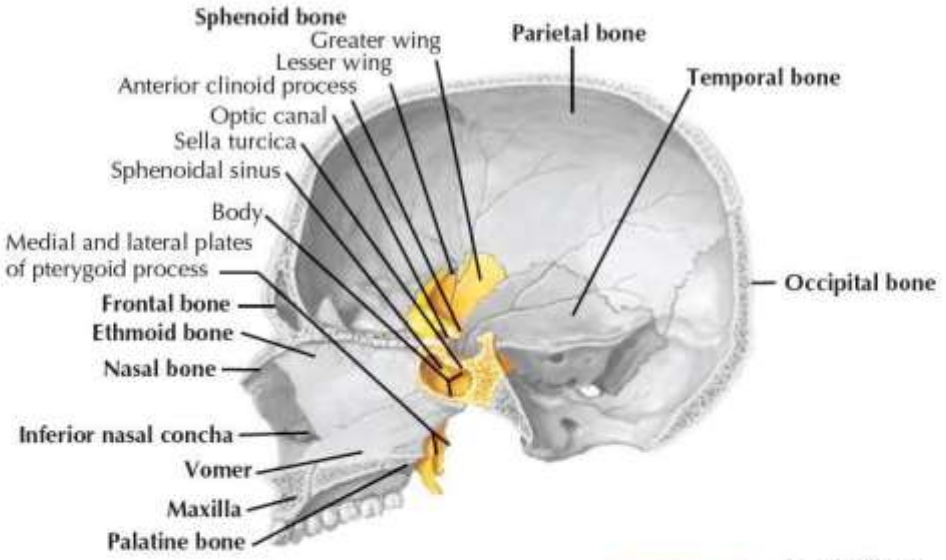
Sphenoid bone
Greater wing
Lesser wing
Anterior clinoid process
Optic canal
Sella turcica
Sphenoidal sinus
Body
Medial and lateral plates of pterygoid process
Frontal bone
Ethmoid bone
Nasal bone
Inferior nasal concha
Vomer
Maxilla
Palatine bone
Parietal bone
Temporal bone
Occipital bone

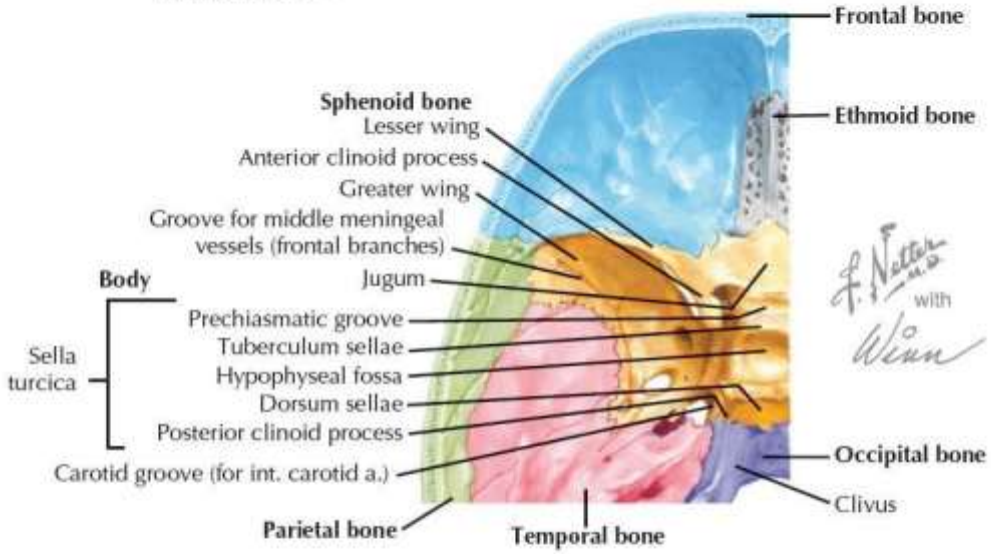
Frontal bone
Sphenoid bone
Lesser wing
Anterior clinoid process
Greater wing
Groove for middle meningeal vessels (frontal branches)
Jugum
Body
Sella turcica
Prechiasmatic groove
Tuberculum sellae
Hypophyseal fossa
Dorsum sellae
Posterior clinoid process
Carotid groove (for int. carotid a.)
Ethmoid bone
Occipital bone
Clivus
Parietal bone
Temporal bone
with

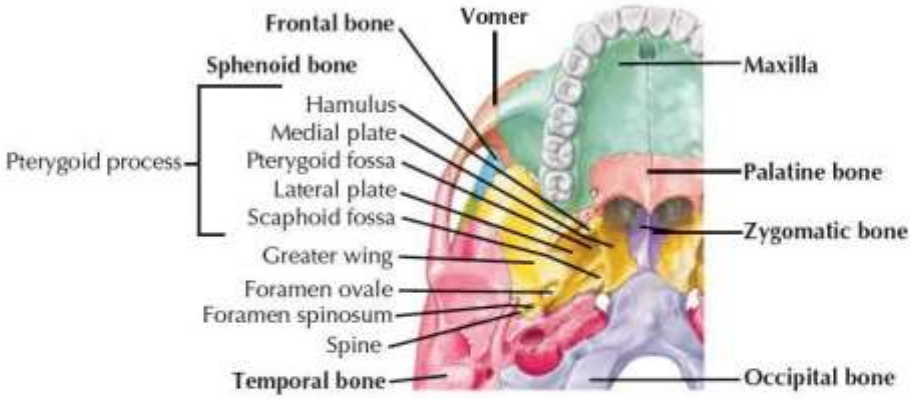
Frontal bone
Vomer
Sphenoid bone
Maxilla
Hamulus
Medial plate
Pterygoid process
Pterygoid fossa
Lateral plate
Palatine bone
Scaphoid fossa
Zygomatic bone
Greater wing
Foramen ovale
Foramen spinosum
Spine
Temporal bone
Occipital bone

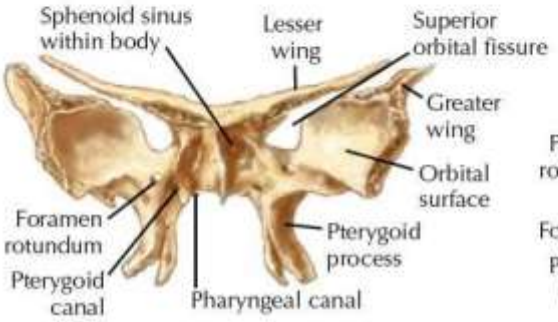
Sphenoid sinus within body
Lesser wing
Superior orbital fissure
Greater wing
Orbital surface
Foramen rotundum
Pterygoid process
Pterygoid canal
Pharyngeal canal

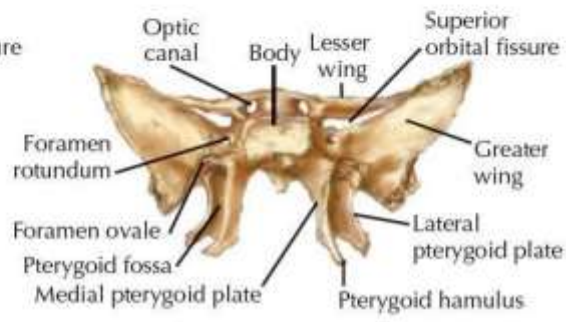
Optic canal
Body
Lesser wing
Superior orbital fissure
Foramen rotundum
Greater wing
Foramen ovale
Lateral pterygoid plate
Pterygoid fossa
Medial pterygoid plate
Pterygoid hamulus

6. ETHMOID BONE

- **Characteristics**

- A porous bone that forms the major portion of the middle part of the face **between the orbits.**
- Helps form the orbit, nasal cavity, nasal septum, and anterior cranial fossa.
- There is 1 ethmoid bone

- **Parts:**

1. <u>Perpendicular plate</u>

- A flat plate that descends from the cribriform plate to form part of the nasal septum.
- Articulates with the vomer inferiorly.

2. <u>Cribriform plate</u>

- A horizontal bone that forms the superior surface of the ethmoid and it contains numerous foramina for the olfactory nerve.

3. <u>Ethmoid labyrinth</u>

- The largest part of the ethmoid bone.

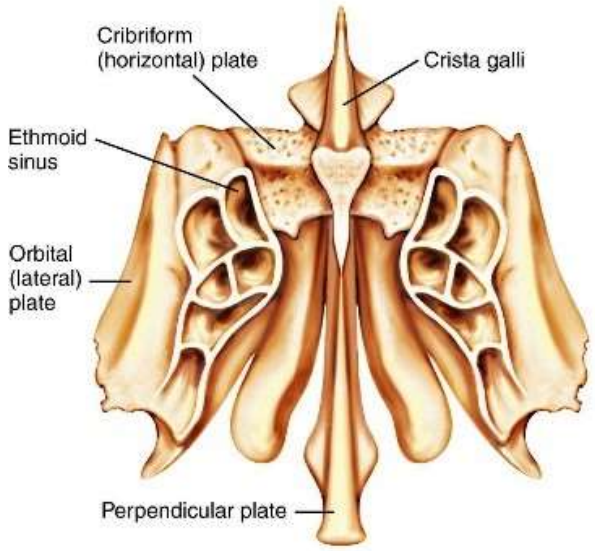

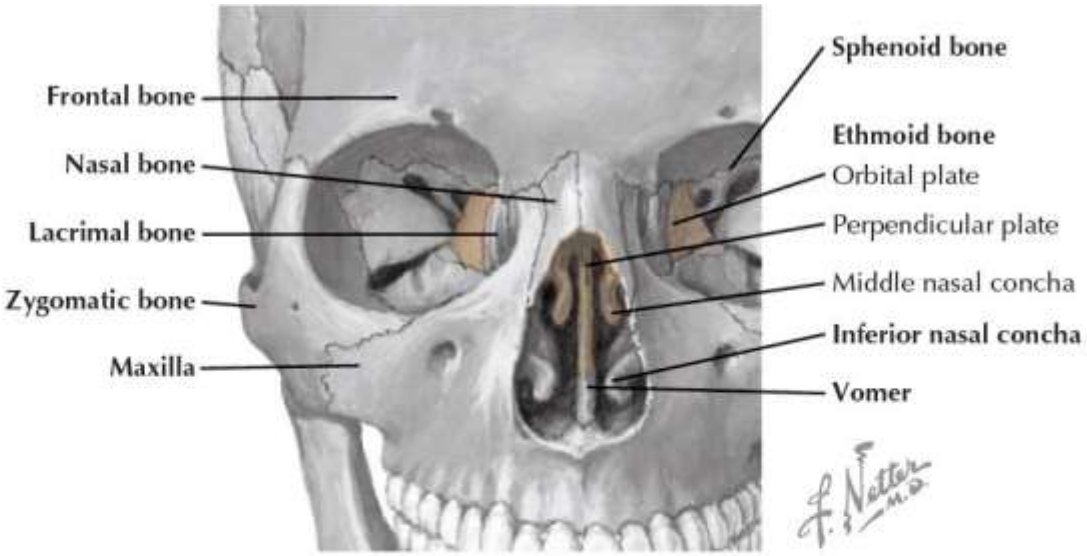
Frontal bone
Nasal bone
Lacrimal bone
Zygomatic bone
Maxilla
Sphenoid bone
Ethmoid bone
Orbital plate
Perpendicular plate
Middle nasal concha
Inferior nasal concha
Vomer

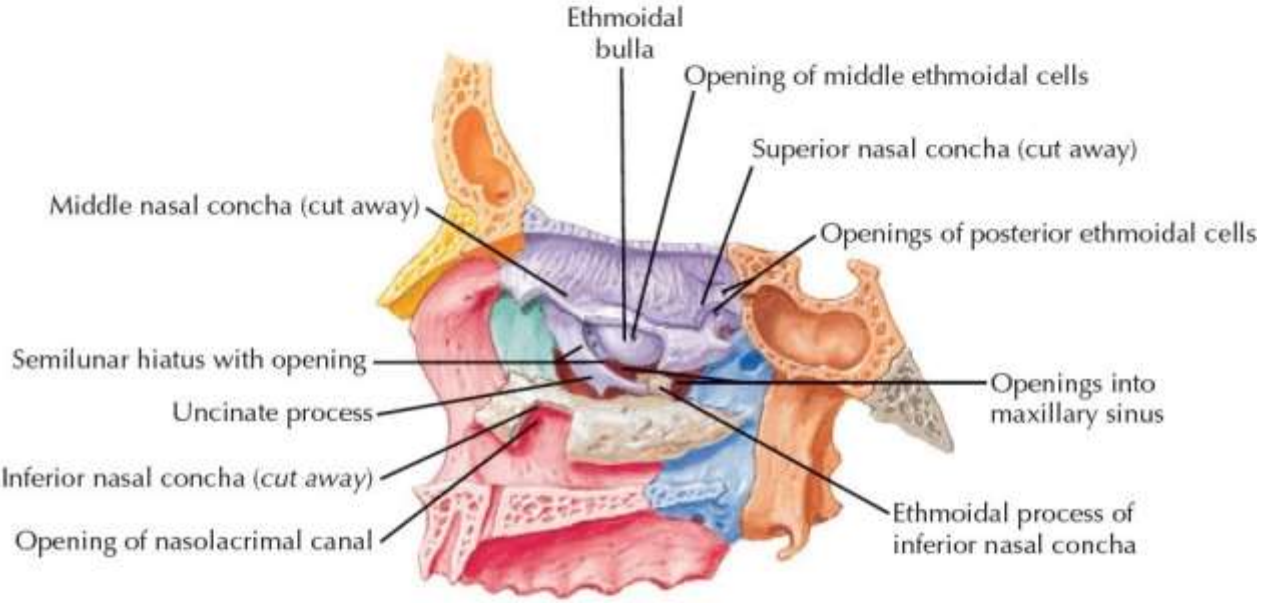
Ethmoidal bulla
Opening of middle ethmoidal cells
Superior nasal concha (cut away)
Middle nasal concha (cut away)
Openings of posterior ethmoidal cells
Semilunar hiatus with opening
Openings into maxillary sinus
Uncinate process
Inferior nasal concha (cut away)
Ethmoidal process of inferior nasal concha
Opening of nasolacrimal canal

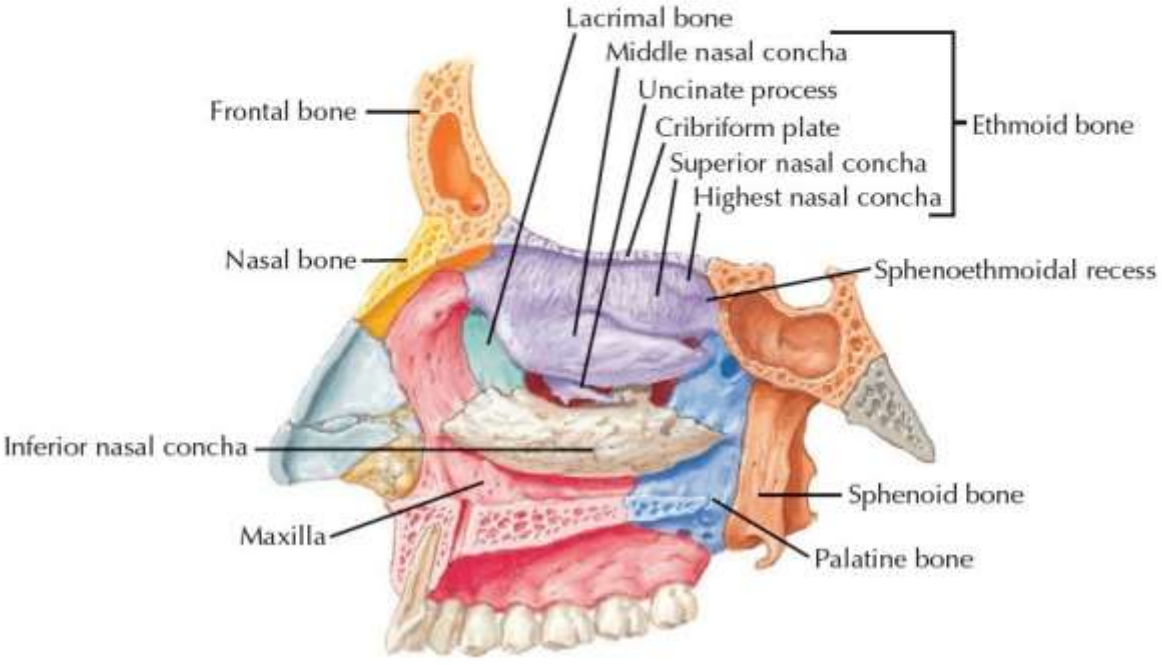
Lacrimal bone
Middle nasal concha
Uncinate process
Frontal bone
Cribriform plate
Ethmoid bone
Superior nasal concha
Highest nasal concha
Nasal bone
Sphenoethmoidal recess
Inferior nasal concha
Sphenoid bone
Maxilla
Palatine bone