Lecture 1 Human Anatomy

Anatomy is the science of the structure and function of the body.

Clinical anatomy is the study of the macroscopic structure and function of the body as it relates to the practice of medicine and other health sciences.

Descriptive Anatomic Terms

- **Terms Related to Position:**

All descriptions of the human body are based on the assumption that the person is standing erect, with the upper limbs by the sides and the face and palms of the hands directed forward. This is the so-called **anatomic position**. The various parts of the body are then described in relation to certain imaginary planes.

- **Median Sagittal Plane**

This is a vertical plane passing through the center of the body, dividing it into equal right and left halves. Planes situated to one or the other side of the median plane and parallel to it are termed paramedian.
A structure situated nearer to the median plane of the body than another is said to be medial to the other. Similarly, a sructure that lies farther away from the median plane than another is said to be lateral to the other.

- **Coronal Planes**

These planes are imaginary vertical planes at right angles to the median plane.

- **Horizontal, or Transverse Planes**

These planes are at right angles to both the median and the coronal planes.
The terms anterior and posterior are used to indicate the front and back of the body, respectively.

To describe the relationship of two structures, one is said to be anterior or posterior to

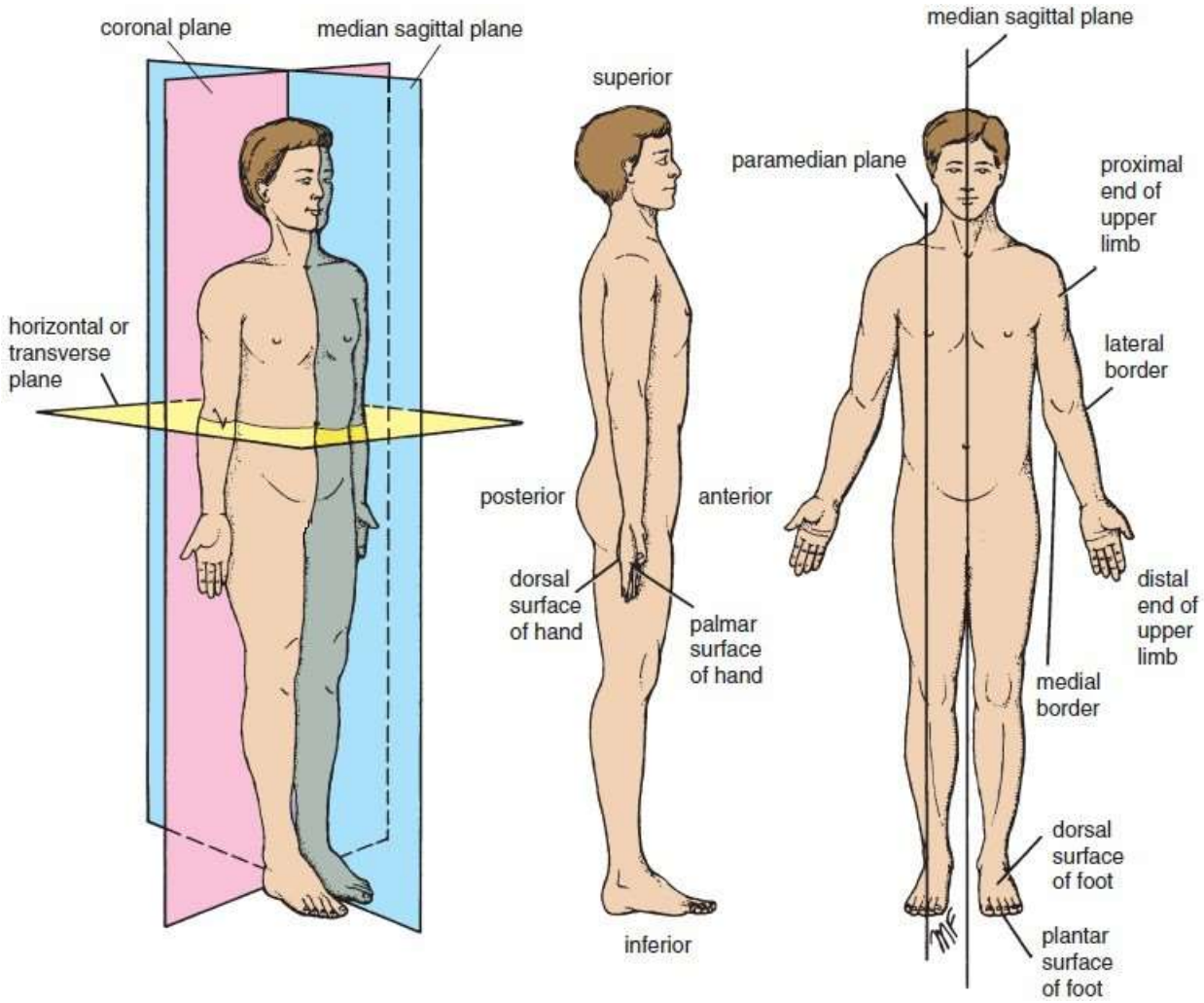

the other insofar as it is closer to the anterior or posterior body surface.
In describing the hand, the terms palmar and dorsal surfaces are used in place of anterior and posterior, and in describing the foot, the terms plantar and dorsal surfaces are used instead of lower and upper surfaces.

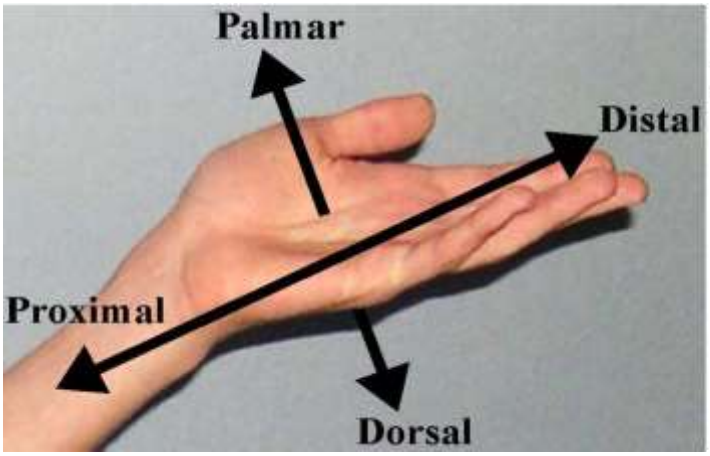



The terms **proximal and distal** describe the relative distances from the roots of the limbs; for example, the arm is proximal to the forearm and the hand is distal to the forearm.

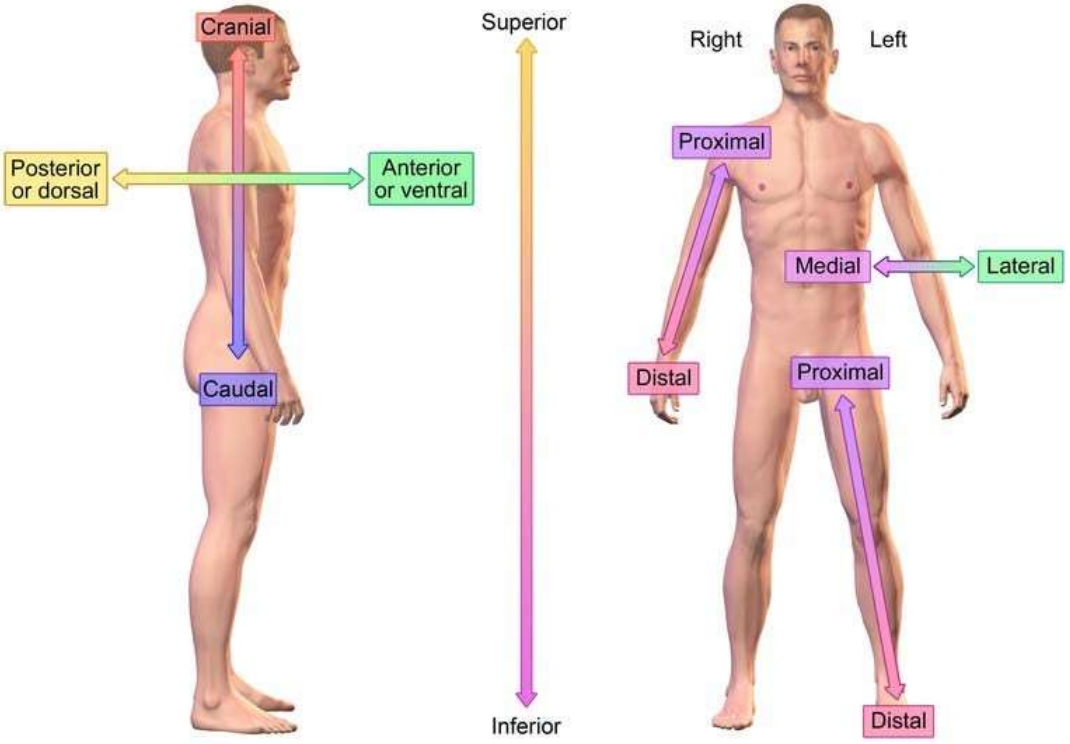

Directional References

The terms **superficial and deep** denote the relative distances of structures from the surface of the body, and the terms superior and inferior denote levels relatively high or low with reference to the upper and lower ends of the body.

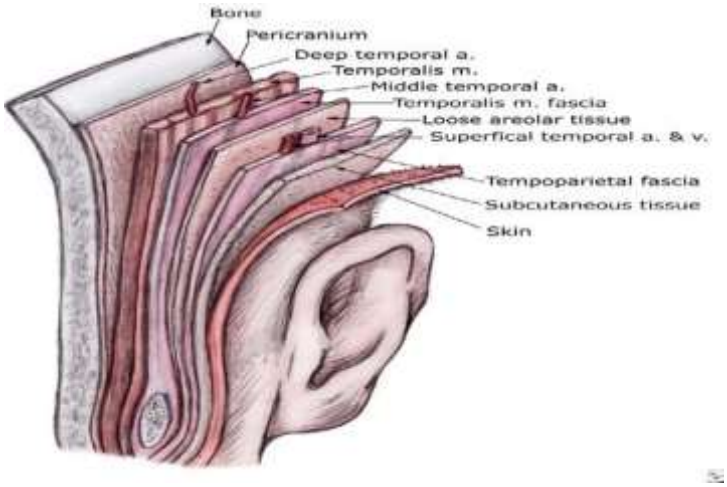

The terms **internal and external** are used to describe the relative distance of a structure from the center of an organ or cavity; for example, the internal carotid artery is found inside the cranial cavity and the external carotid artery is found outside the cranial cavity.

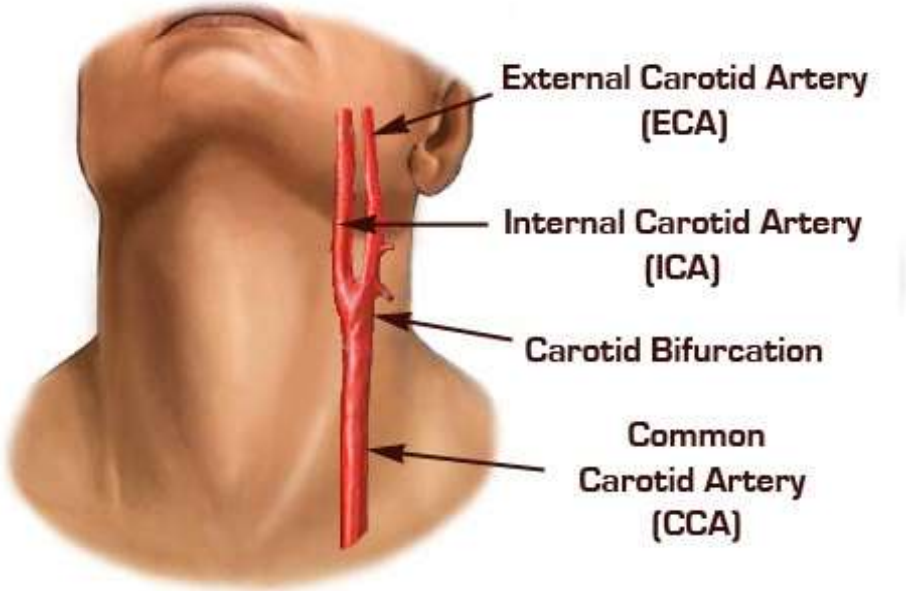

The term **ipsilateral** refers to the same side of the body;for example, the left hand and the left foot are ipsilateral. **Contralateral** refers to opposite sides of the body; forexample, the left eye and the right ear are contralateral.
The **supine position of the body** is lying on the back. The **prone position is** lying face downward.

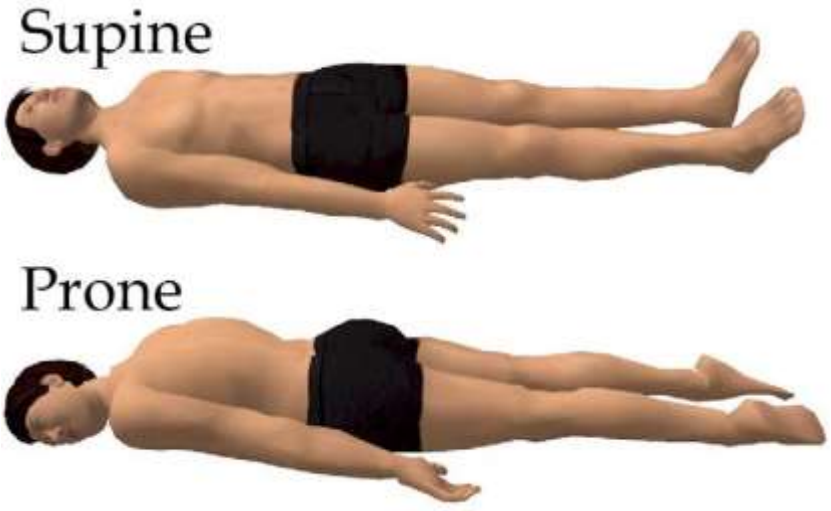

- **Terms Related to Movement**

A site where two or more bones come together is known as a **joint**. Some joints have no movement (sutures of the skull), some have only slight movement (superior tibiofibularjoint), and some are freely movable (shoulder joint).



Shoulder joint



Superior tibiofibular joint



Sutures of the skull

Flexion is a movement that takes place in a sagittal plane. For example, flexion of the elbow joint approximates the anterior surface of the forearm to the anterior surface of the arm. It is usually an anterior movement, but it is occasionally posterior, as in the case of the knee joint.
Extension means straightening the joint and usually takes place in a posterior direction. Lateral flexion is a movement of the trunk in the coronal plane.

Abduction is a movement of a limb away from the midline of the body in the coronal plane.
Adduction is a movement of a limb toward the body in the coronal plane. In the fingers and toes, abductionis applied to the spreading of these structures and adductionis applied to the drawing together of these structures.

Rotation is the term applied to the movement of a part of the body around its long axis. Medial rotation is the movement that results in the anterior surface of the part facing medially.

Lateral rotation is the movement that results in the anterior surface of the part facing laterally.

Circumduction is the combination in sequence of the movements of flexion, extension, abduction, and adduction.

Inversion is the movement of the foot so that the sole faces in a medial direction. **Eversion** is the opposite movement of the foot so that the sole faces in a lateral direction.

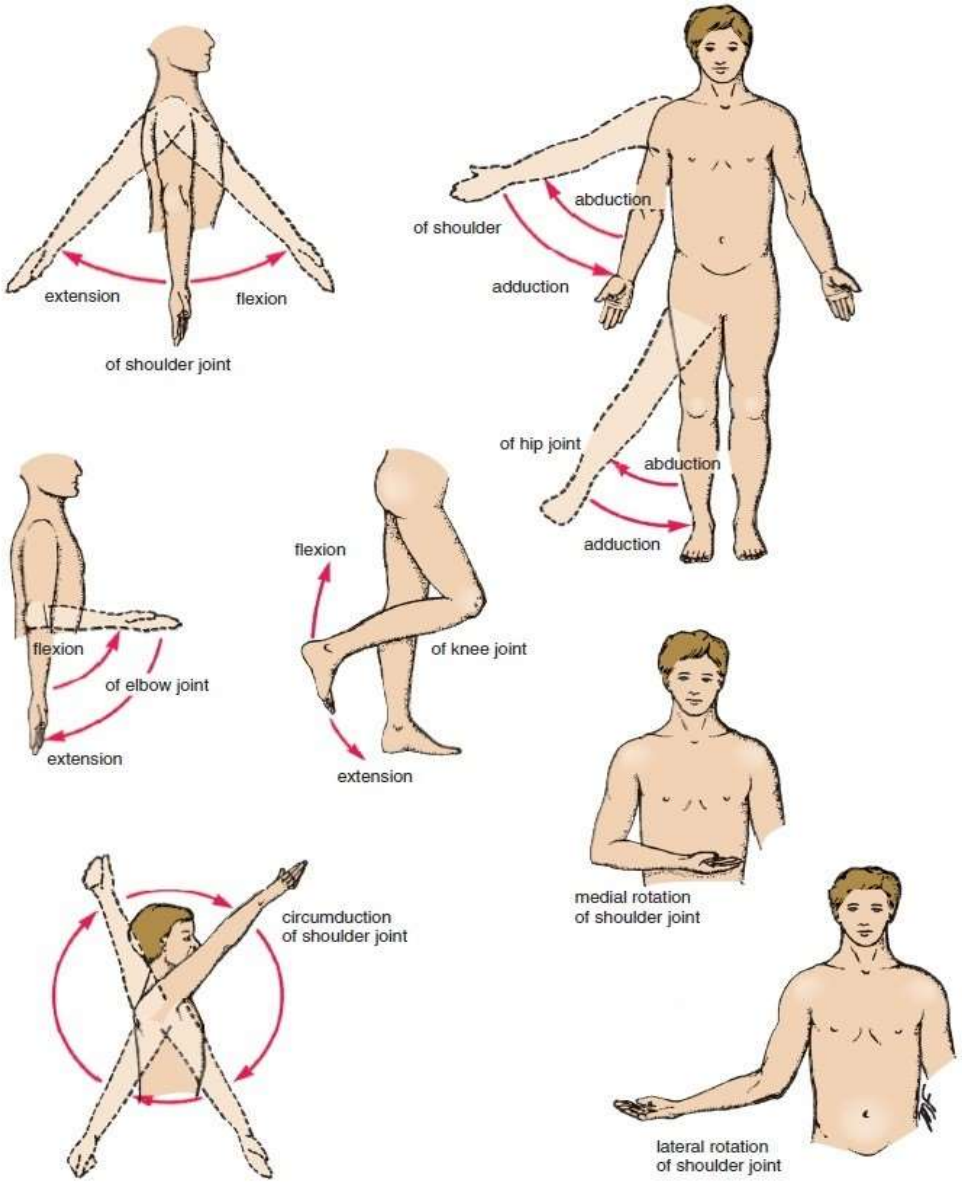

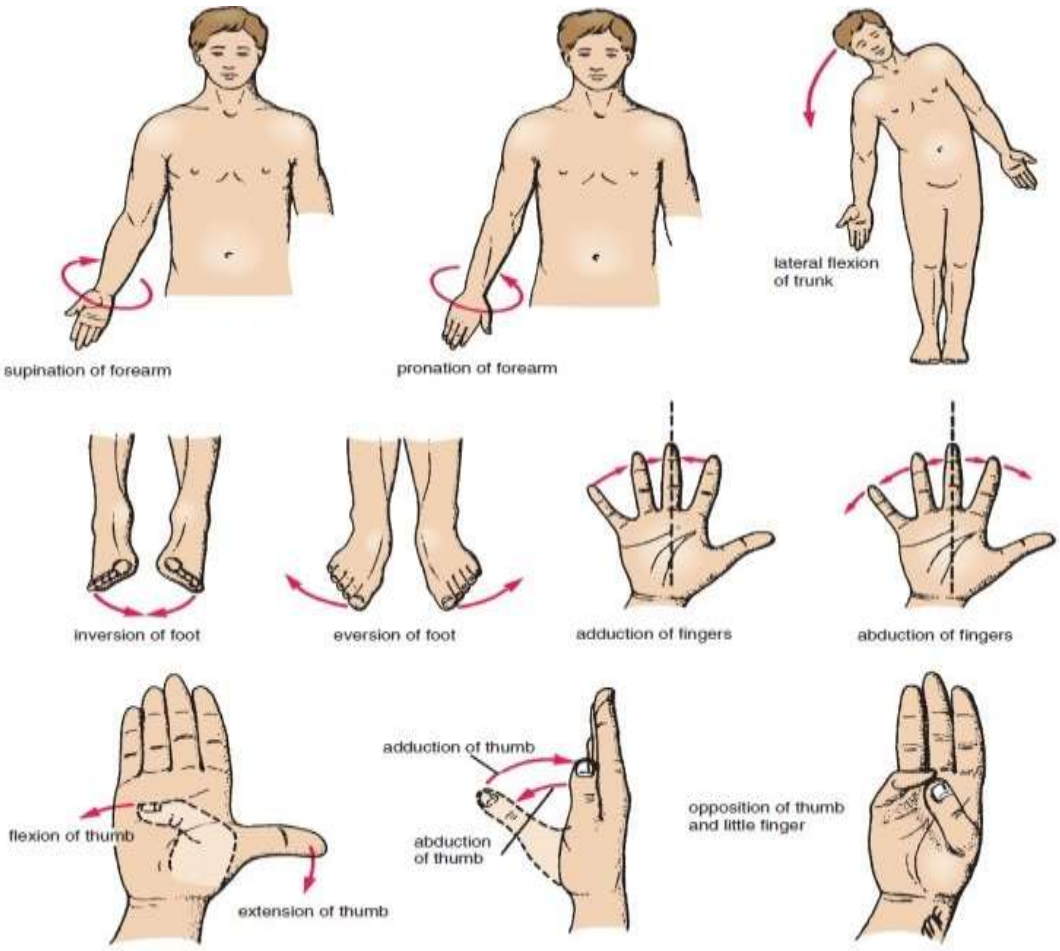



Protraction is to move forward; **retraction** is to move backward (used to describe the forward and backward movement of the jaw at the temporomandibular joints).