Skin Histology

Skin Histology lab IST ST ASHUR MED COLL Professor Ali Altimimi

Professor Ali Altimimi,Prof. of Micro Anatomy & Histopathology , MbCHB,MSC,PHD,MD.Royal College London

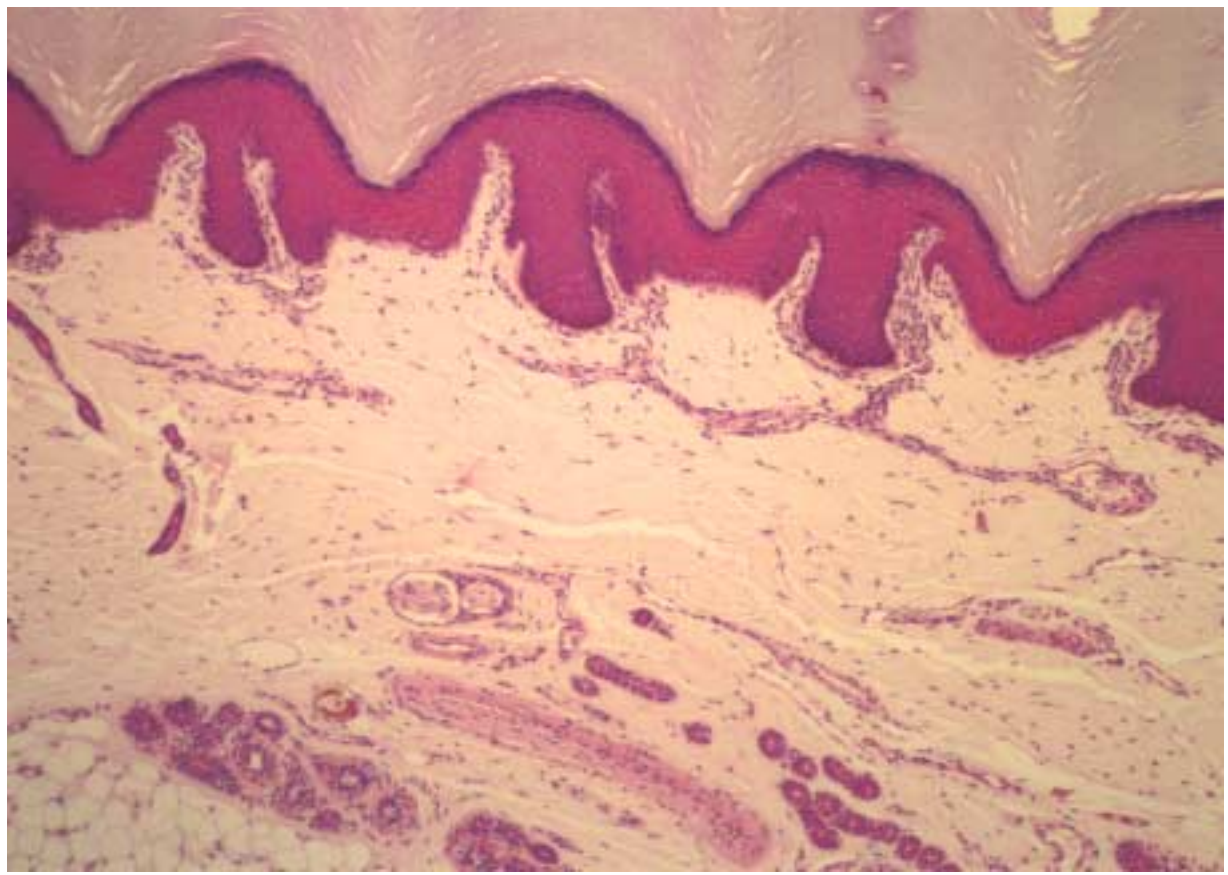

Protection Sensation Thermoregulation Metabolism

Layers of Skin

1) **Epidermis**
   - ➡ **stratified squamous epithelium**
   - ➡ **epidermal ridges**
2) **Dermis**
   a) **papillary layer**
      small blood vessels, lymph & nerves
      fine collagen & elastic fibers
   b) **reticular layer**
      vascular plexus, lymph, nerves & appendages
      compact collagen fibers & thick elastic fibers
3) **Hypodermis (subcutaneous)**
   - ➡ **mainy adipose tissue**

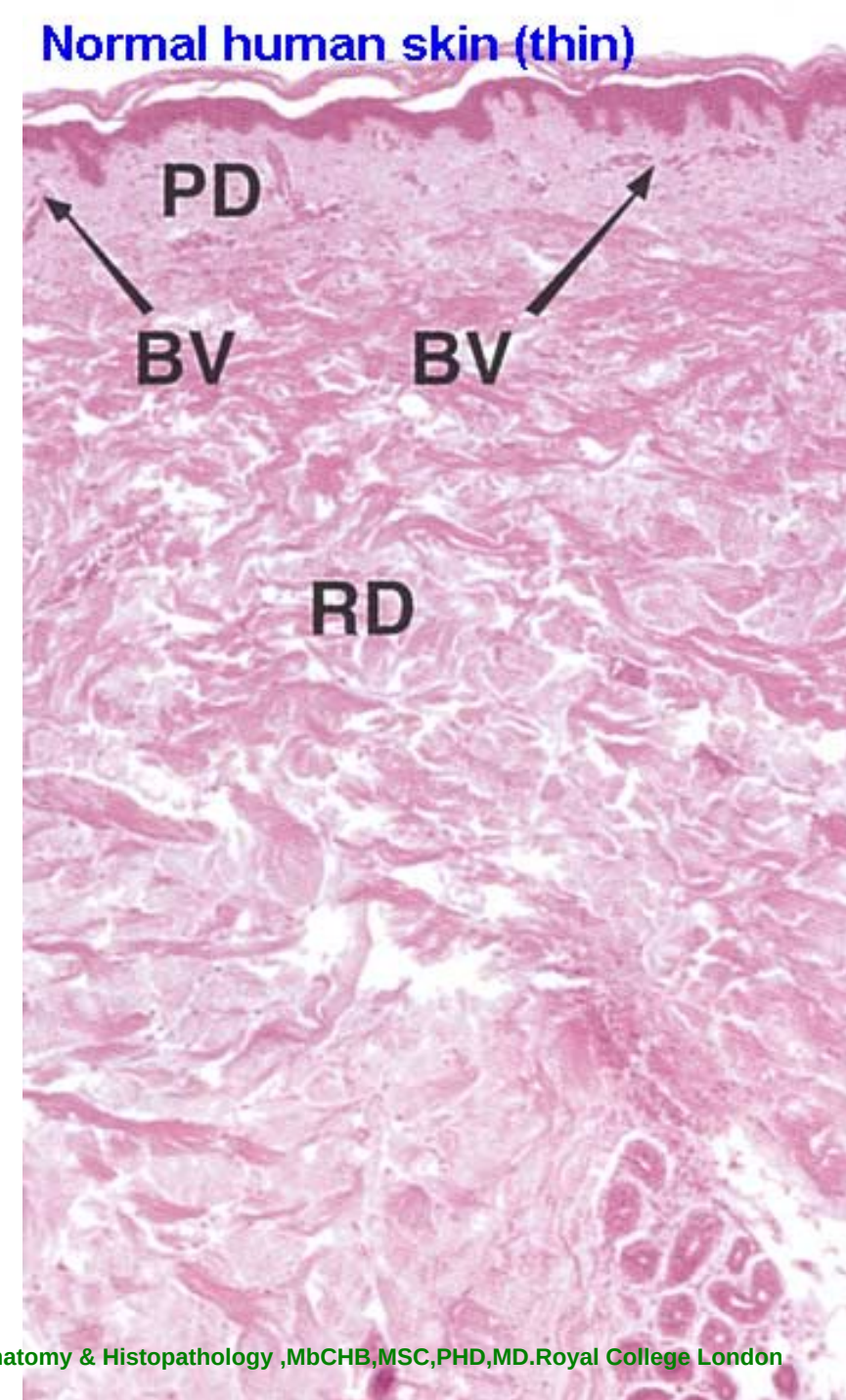

Wheater's Functional Histology

Epidermis

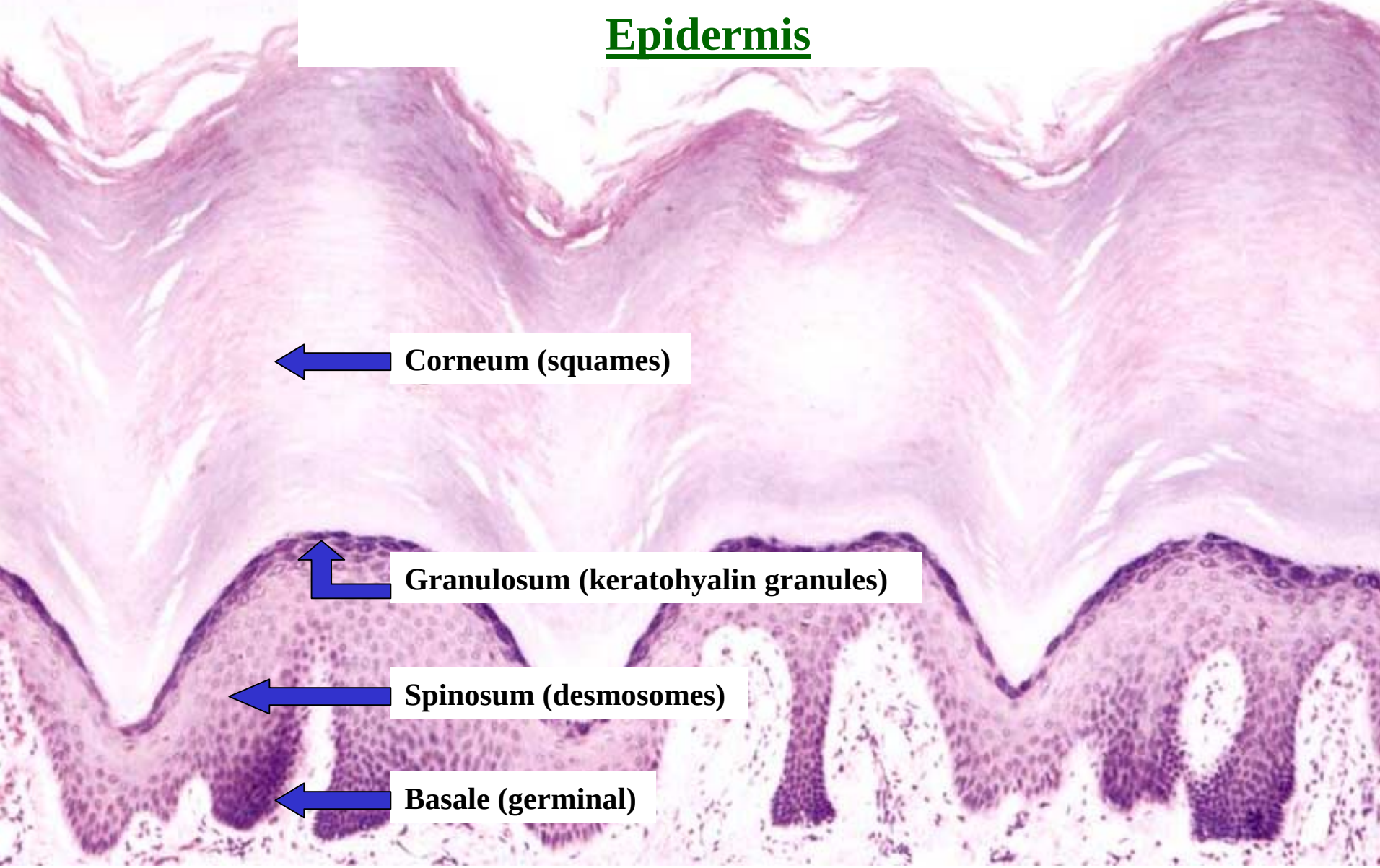

4 distinct cell types: 1) Keratinocyte, 2) Melanocyte, 3) Langerhans cell, 4) Merkel cell

Wheater's Functional Histology

Dermo-epidermal Junction

1) Hemidesmosome
   a) germinal cell
      -keratin filaments
      -cytoplasmic plaque
      -plasma membrane
      -transmembrane linkers
2) Basal lamina
   a) lamina lucida
      -anchoring proteins
   b) lamina densa
      -crosslinking fibrils
3) Subjacent connective tissue
   a) collagen fibers
   b) elastic fibers

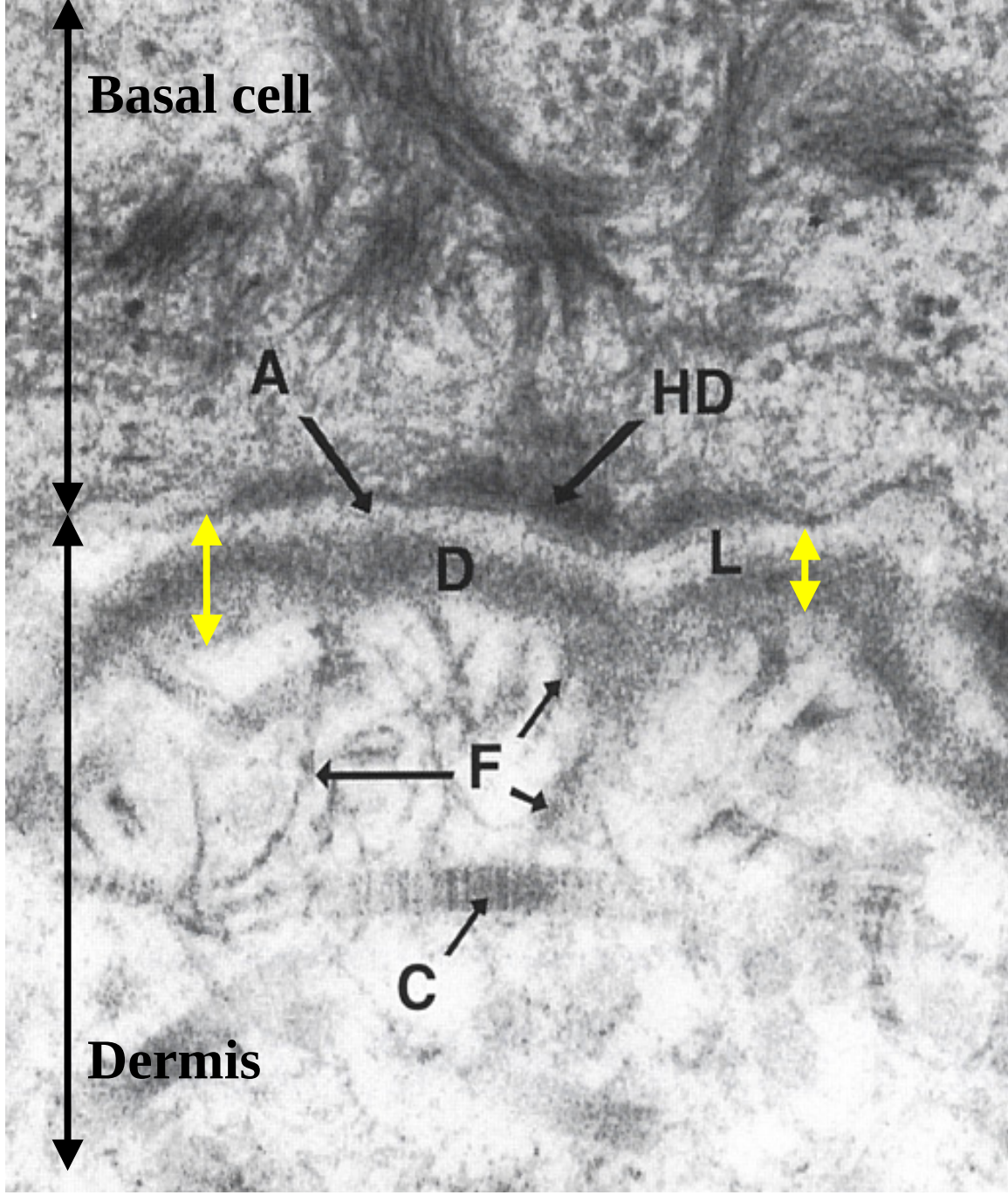



Melanocyte: neural crest origin; no desomosomal attachments

Wheater's Functional Histology

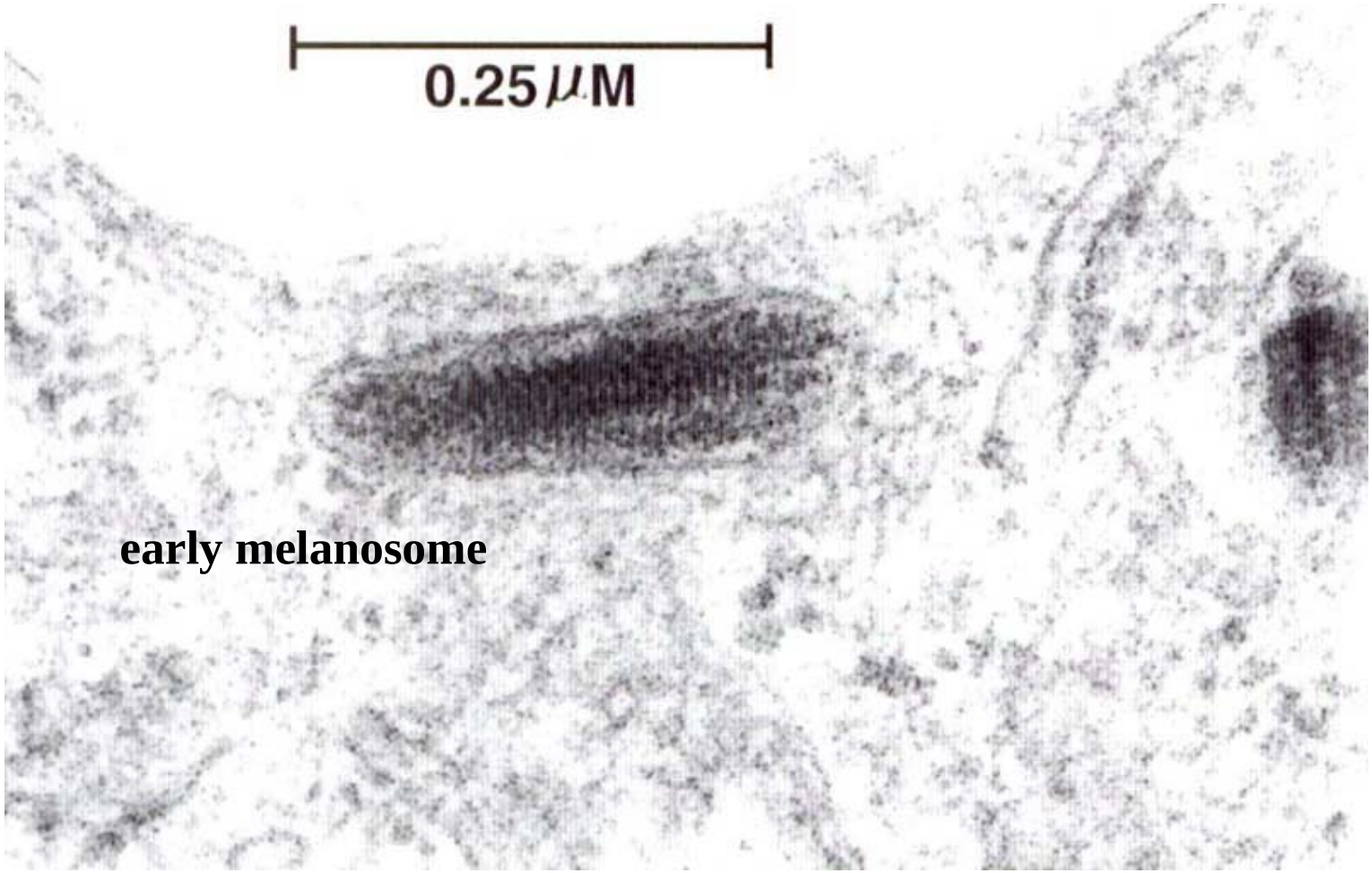

tyrosine → 3,4-dihydroxyphenylalanine (DOPA) → melanin

Wheater's Functional Histology

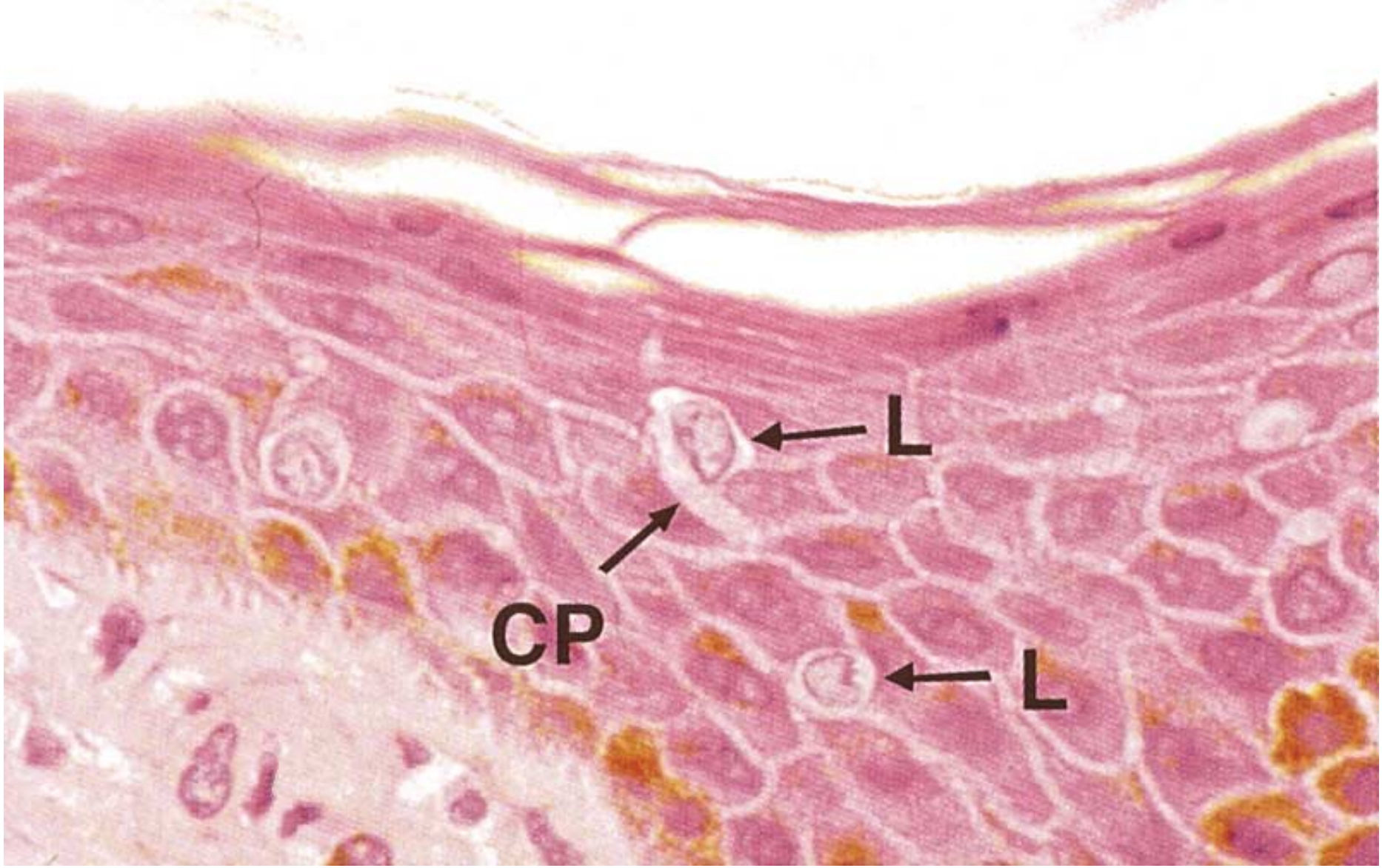

Langerhans cell: dendritic processes; antigen presentation

Wheater's Functional Histology



Desmosomes: false intercellular bridges

Wheater's Functional Histology

Keratin Filaments

-dense cytoplasmic bundles

-crosslinked by filaggrin to form large aggregates

-concentrated at cell periphery in projections that terminate at desomosomal junctions

-crucial for structural integrity, stability, and continuity of the epithelium

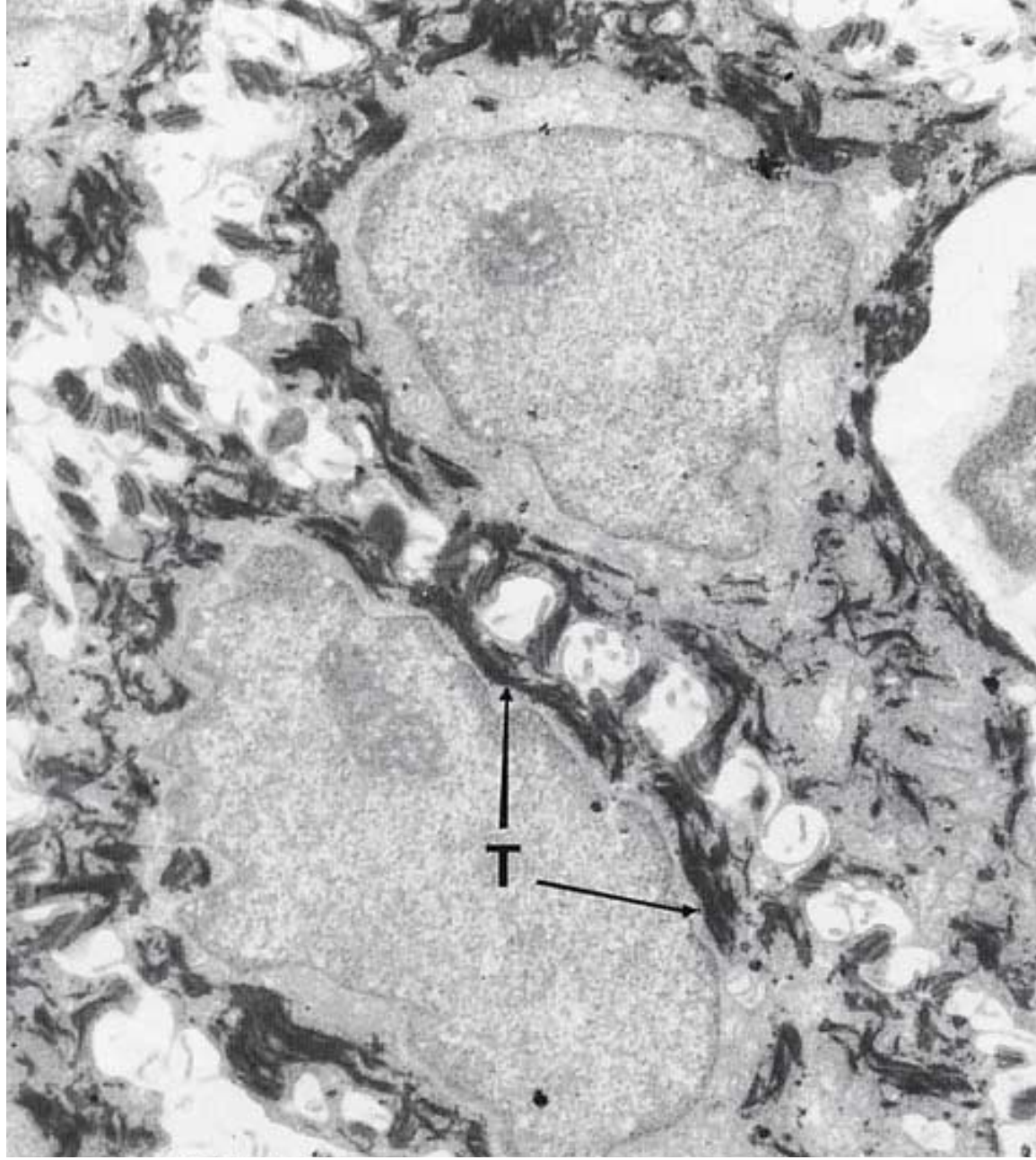

Wheater's Functional Histology

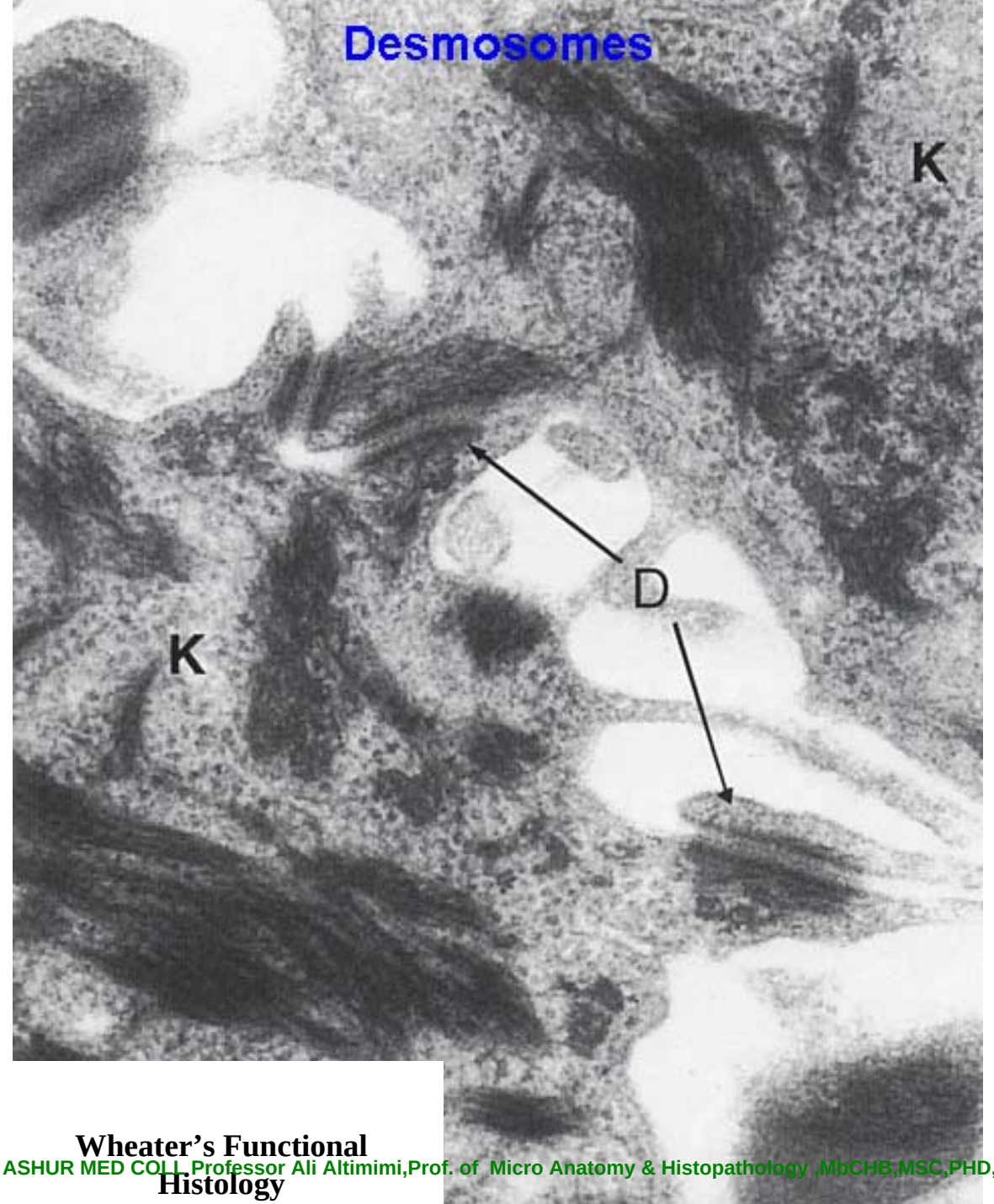

Wheater's Functional Histology

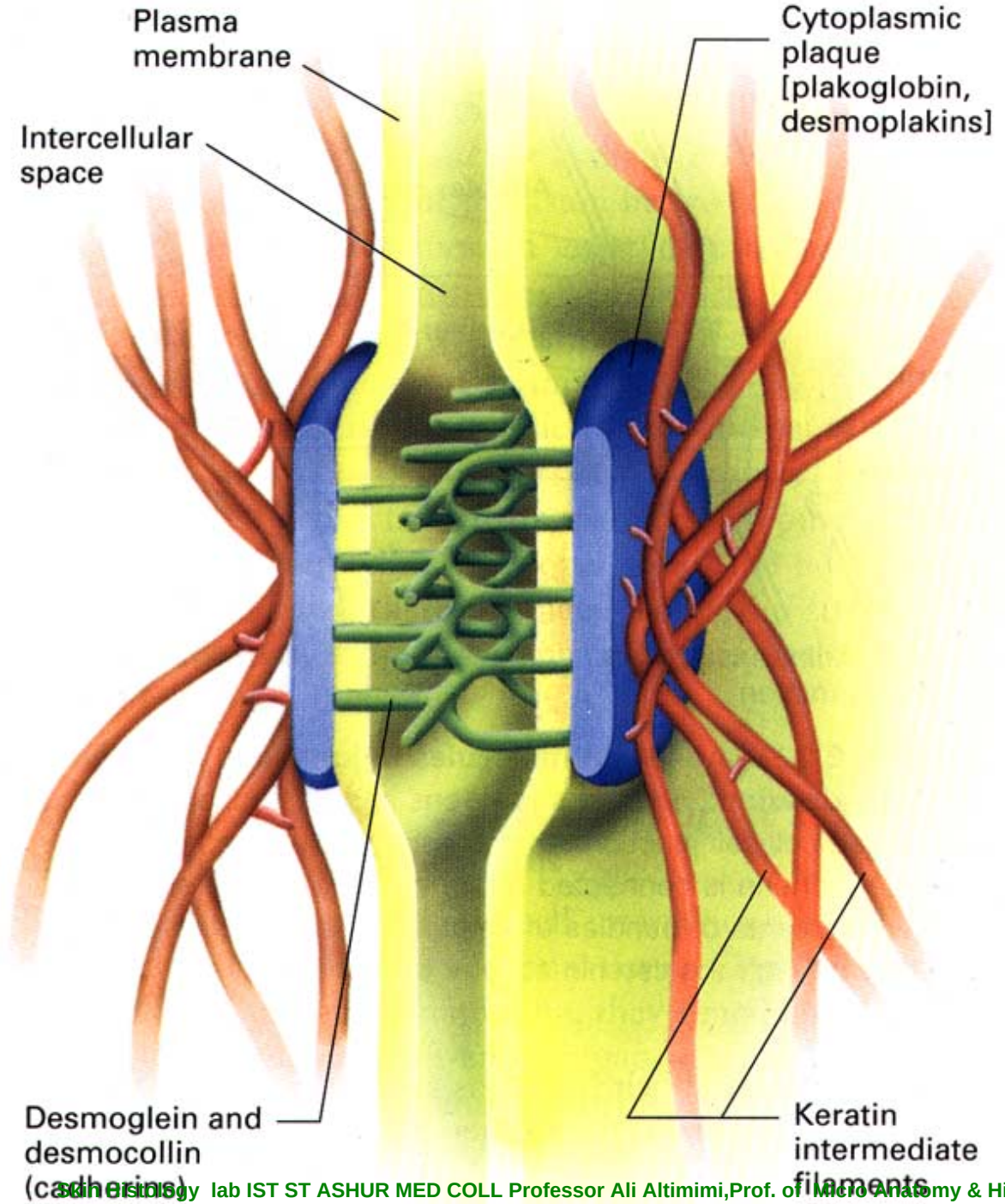

Desomosome Structure

1) adaptor proteins (e.g. plakoglobin) attach keratin filaments to the cytoplasmic plaque

2) transmembrane linkers (e.g. desmoglein) connect adjacent cells

a) cytoplasmic domain binds the adaptor

b) extracellular domain associates with linker on apposing cell (via homophilic interaction)

From Molecular Cell Biology

Keratohyaline Granules

-rich in sulfated amino acids (cysteine)

-contain membranous lamellar bodies consisting of glycolipids (acylglucosylceramide)

-eventually secreted and deposited between keratinocytes

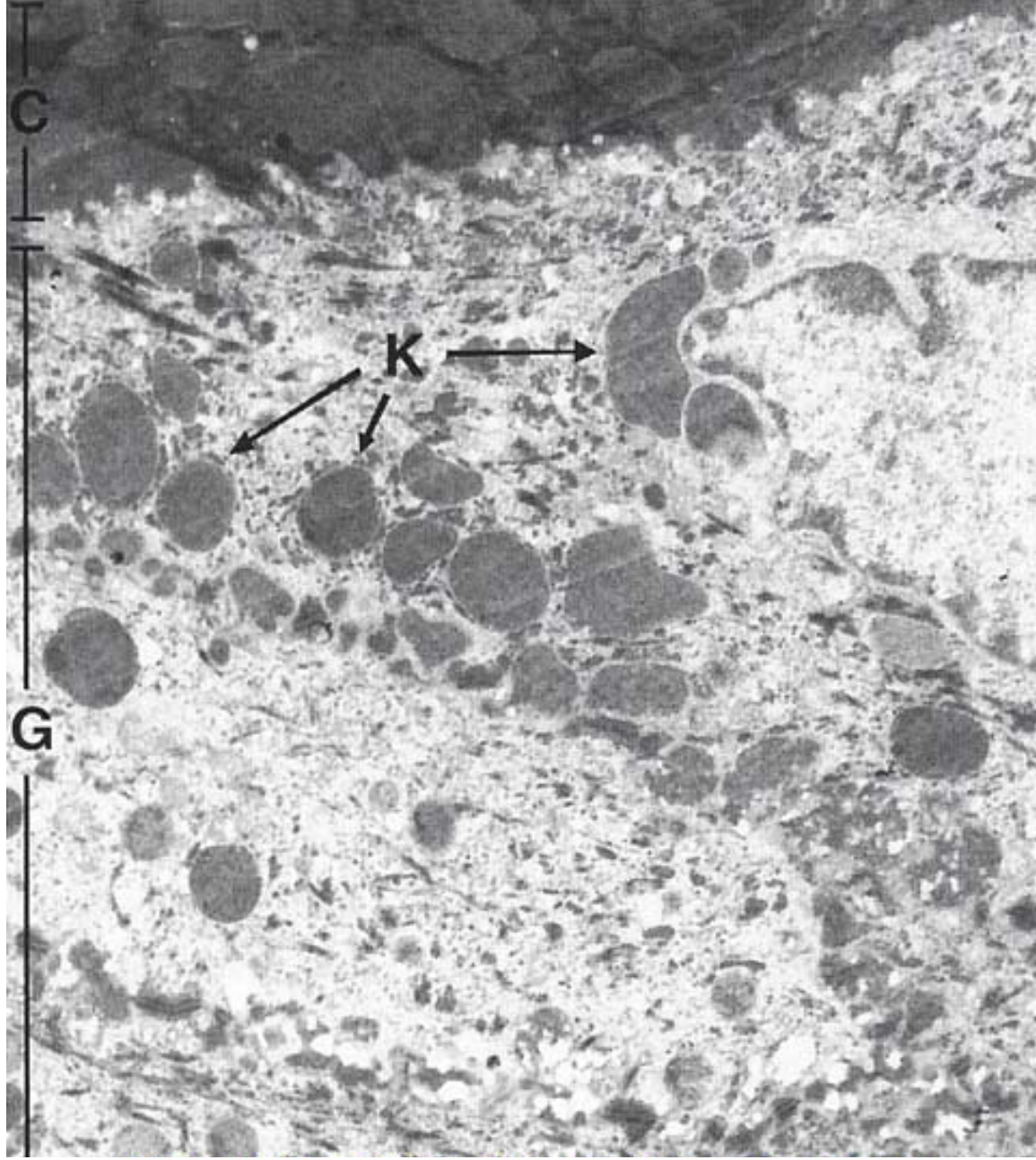

Skin Appendages

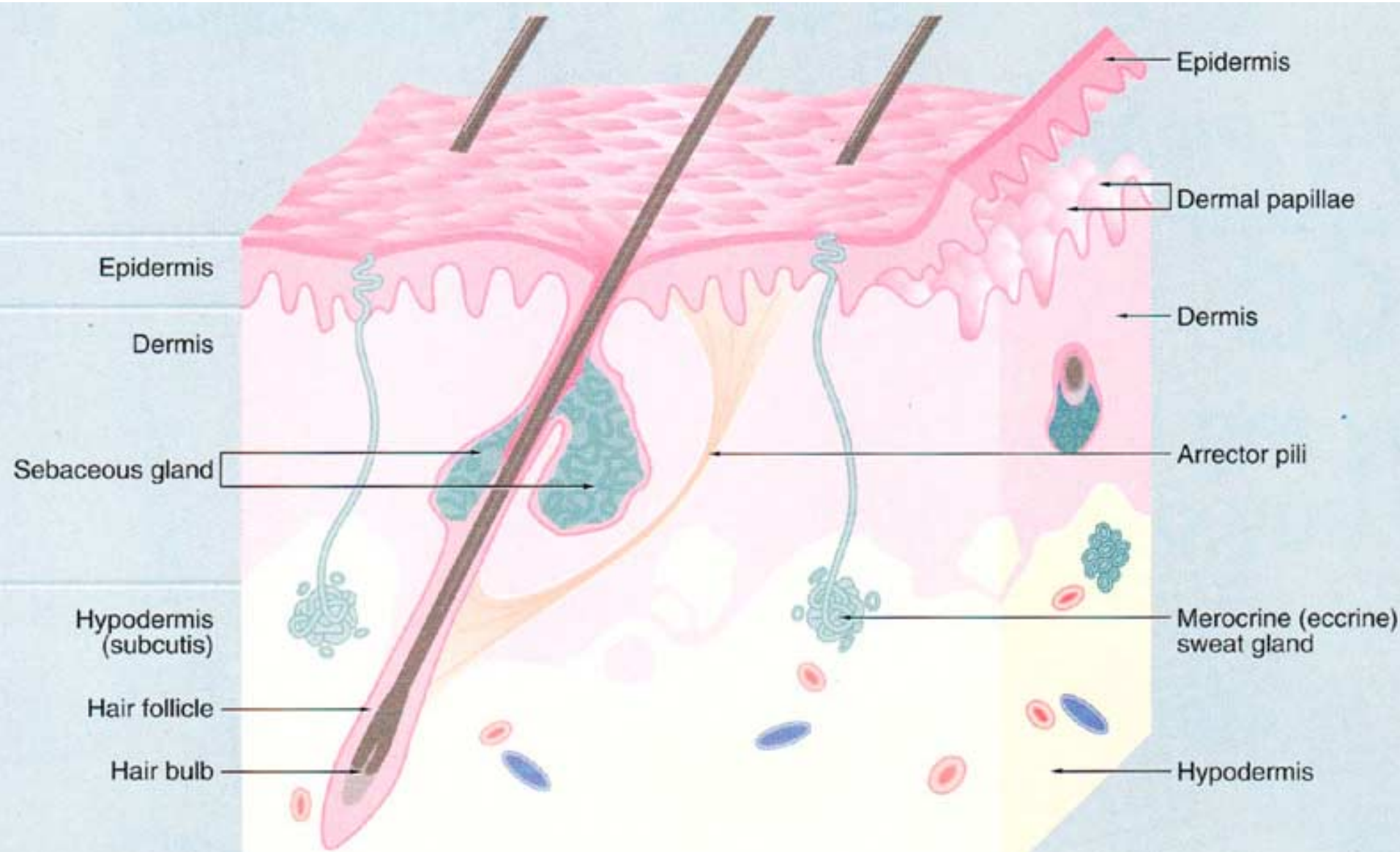

Wheater's Functional Histology

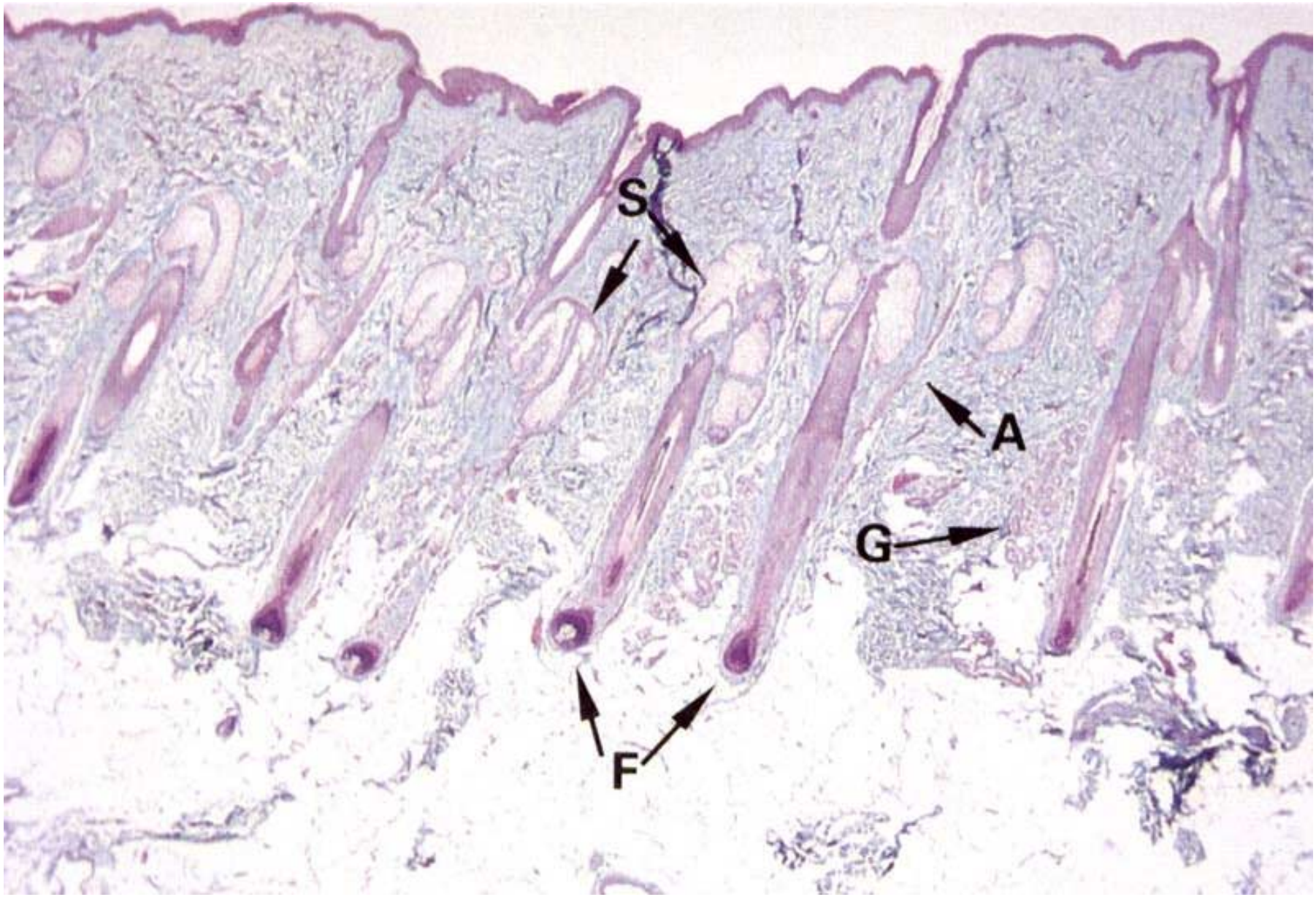

Scalp

Wheater's Functional Histology

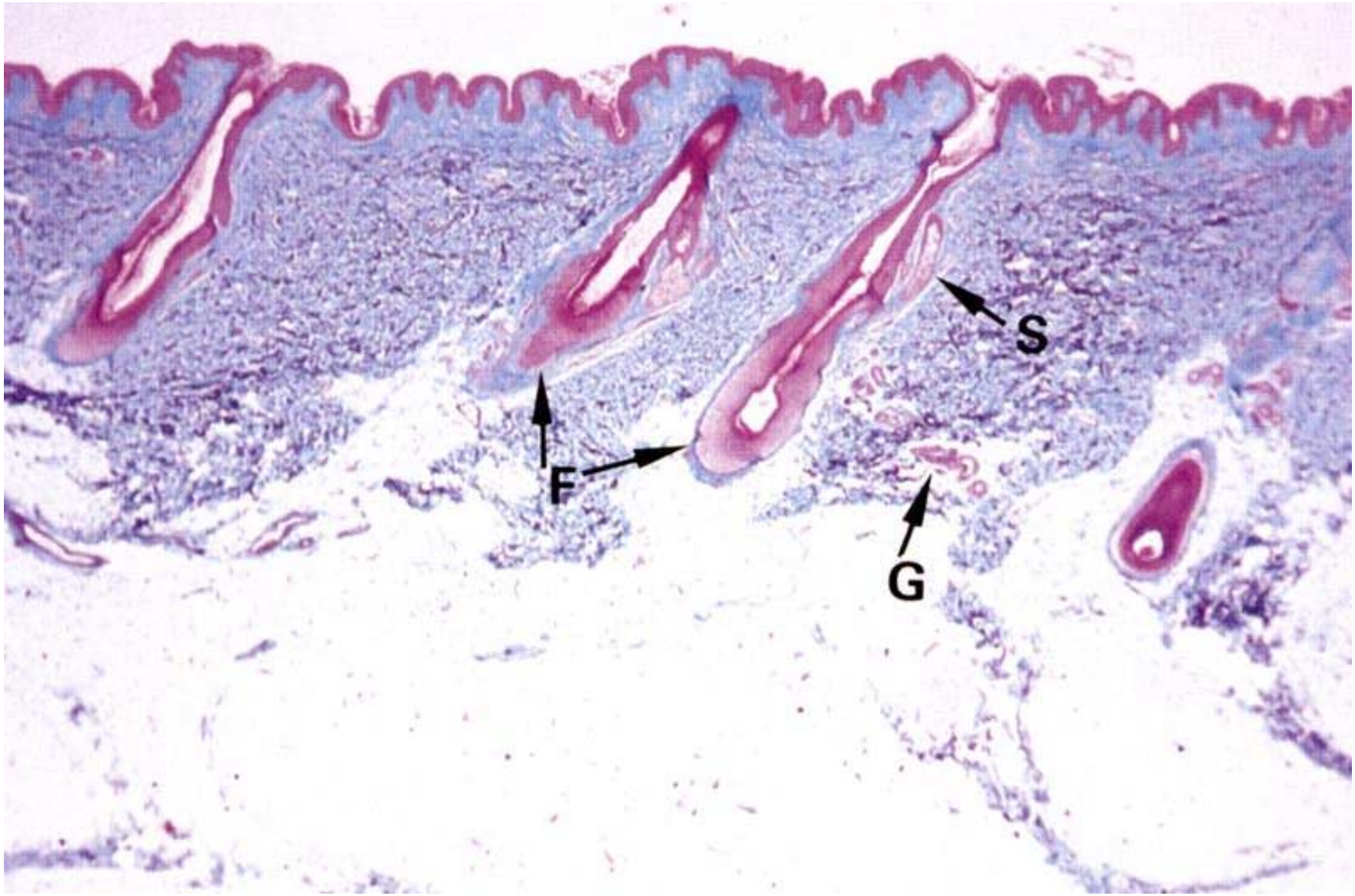

Abdomen

Wheater's Functional Histology

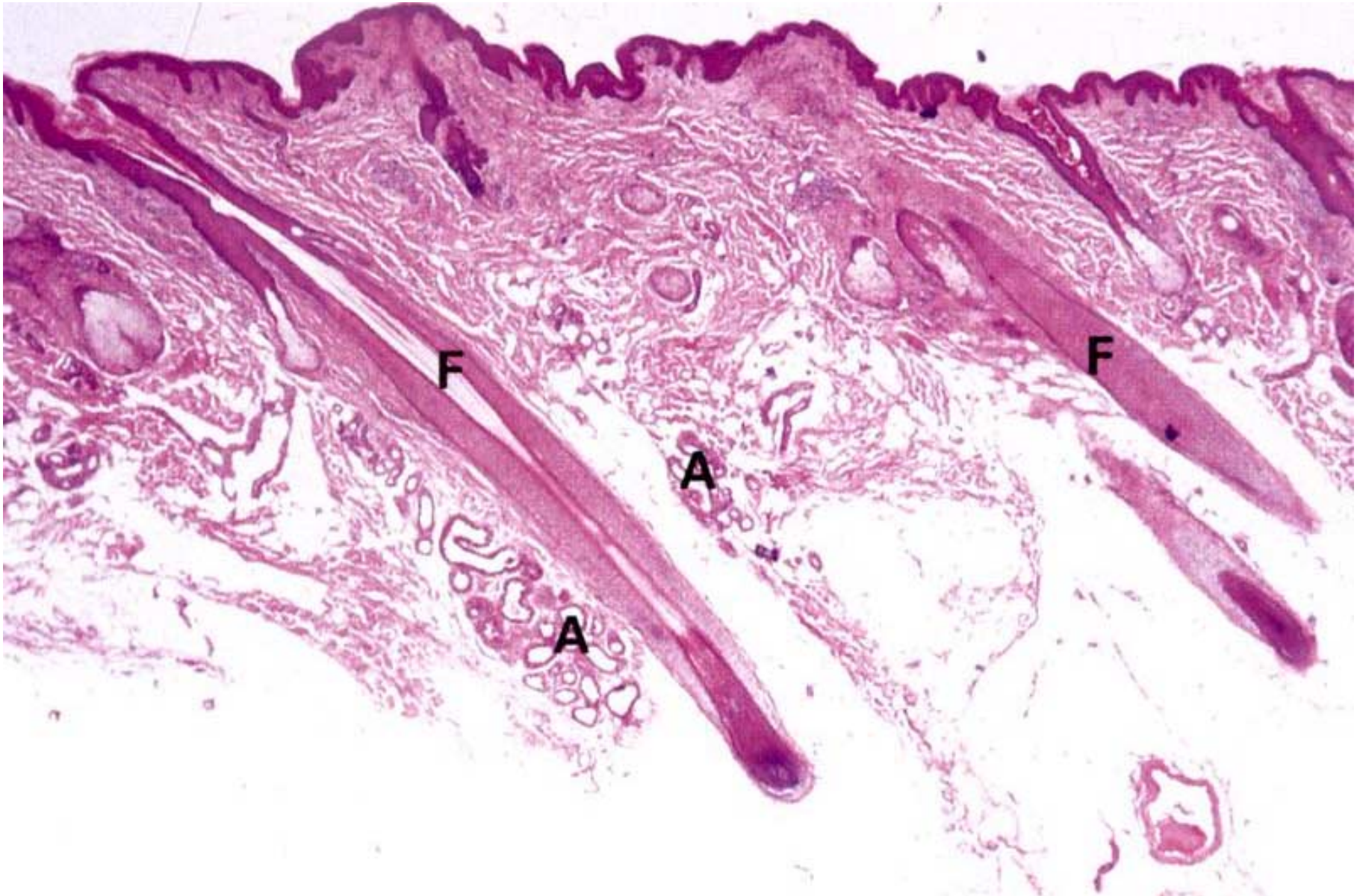

Pubic

Wheater's Functional Histology

Hair Follicle

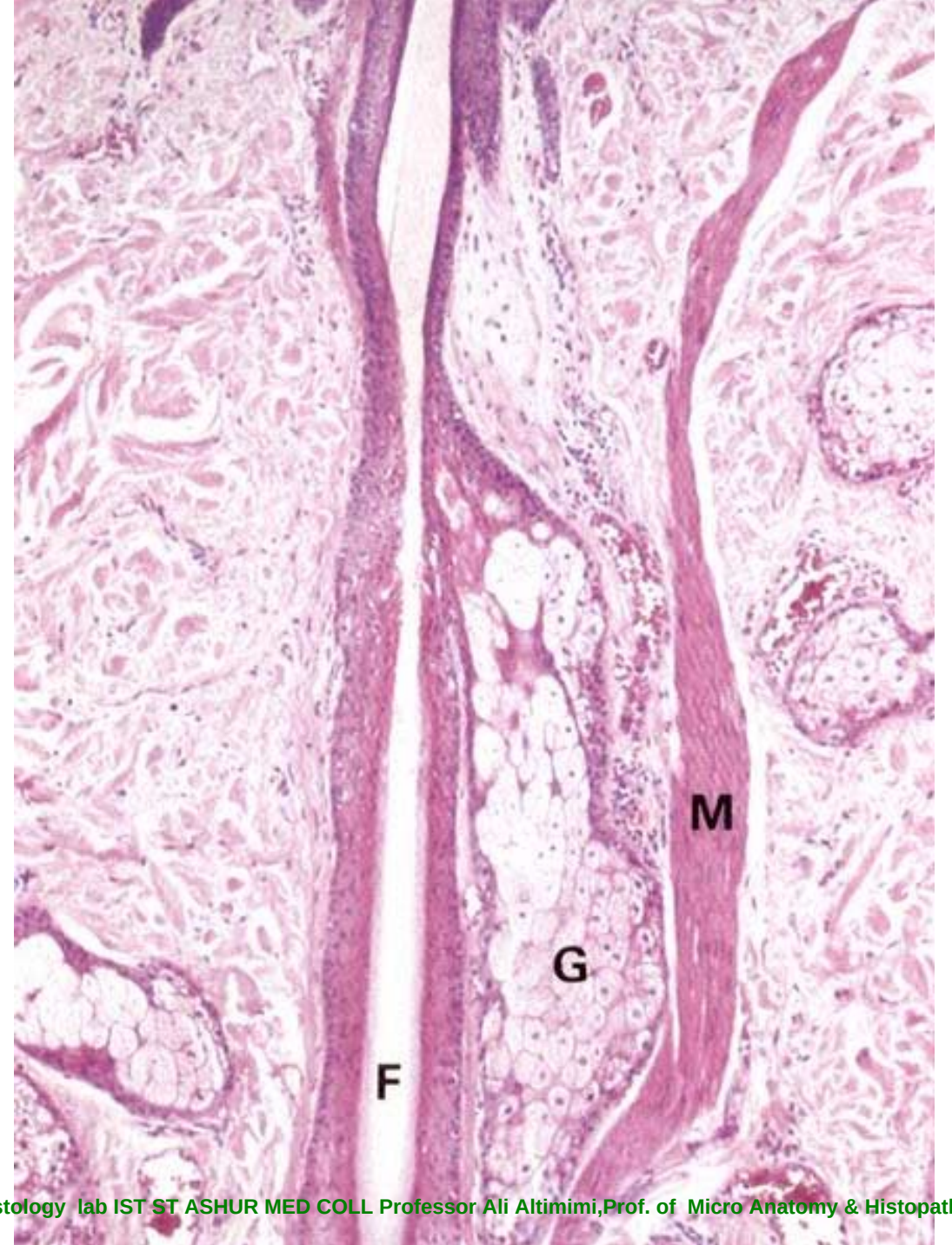

Wheater's Functional Histology



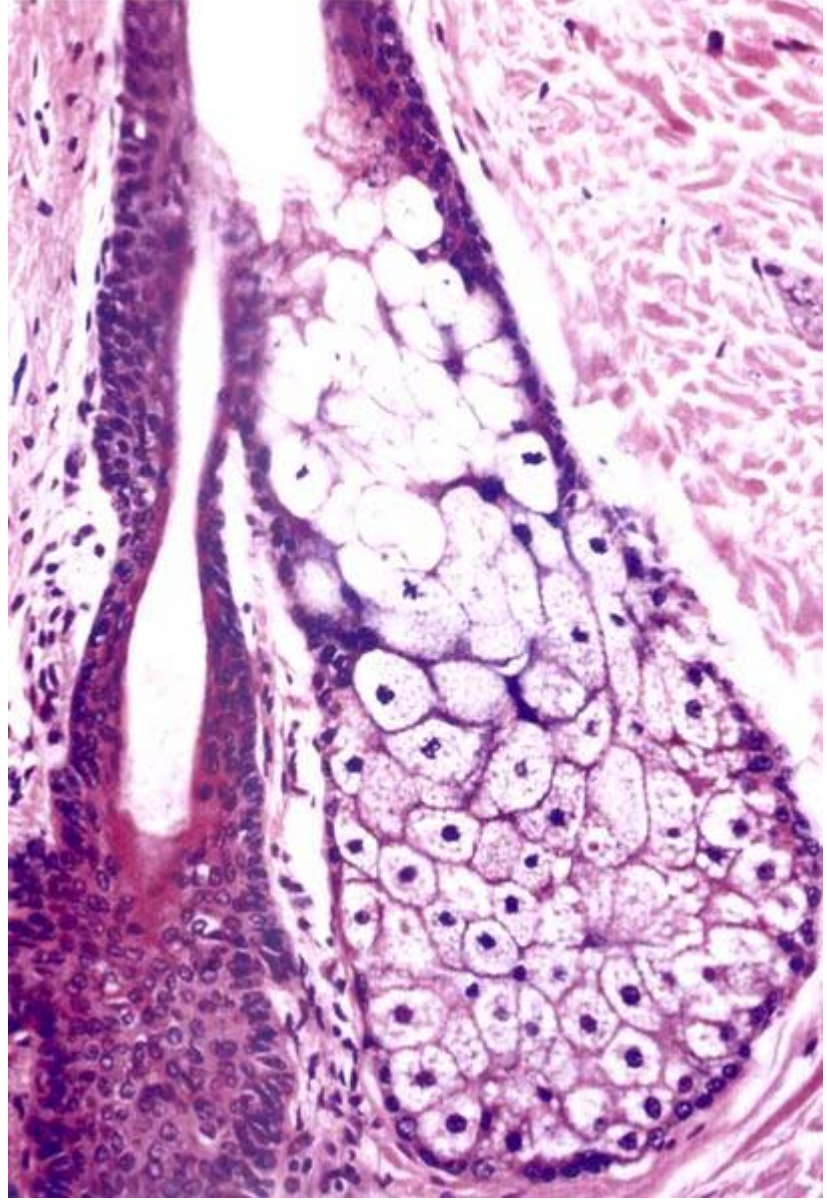

Sebaceous Glands

Wheater's Functional Histology

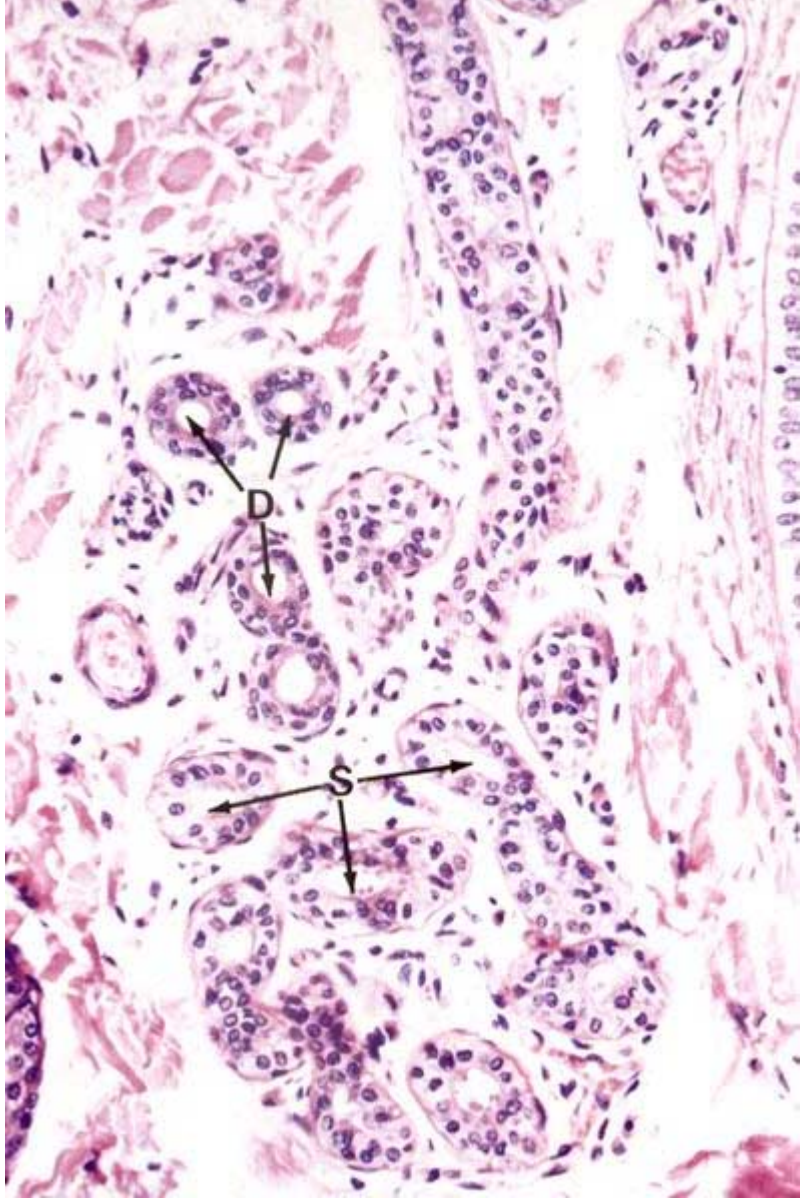

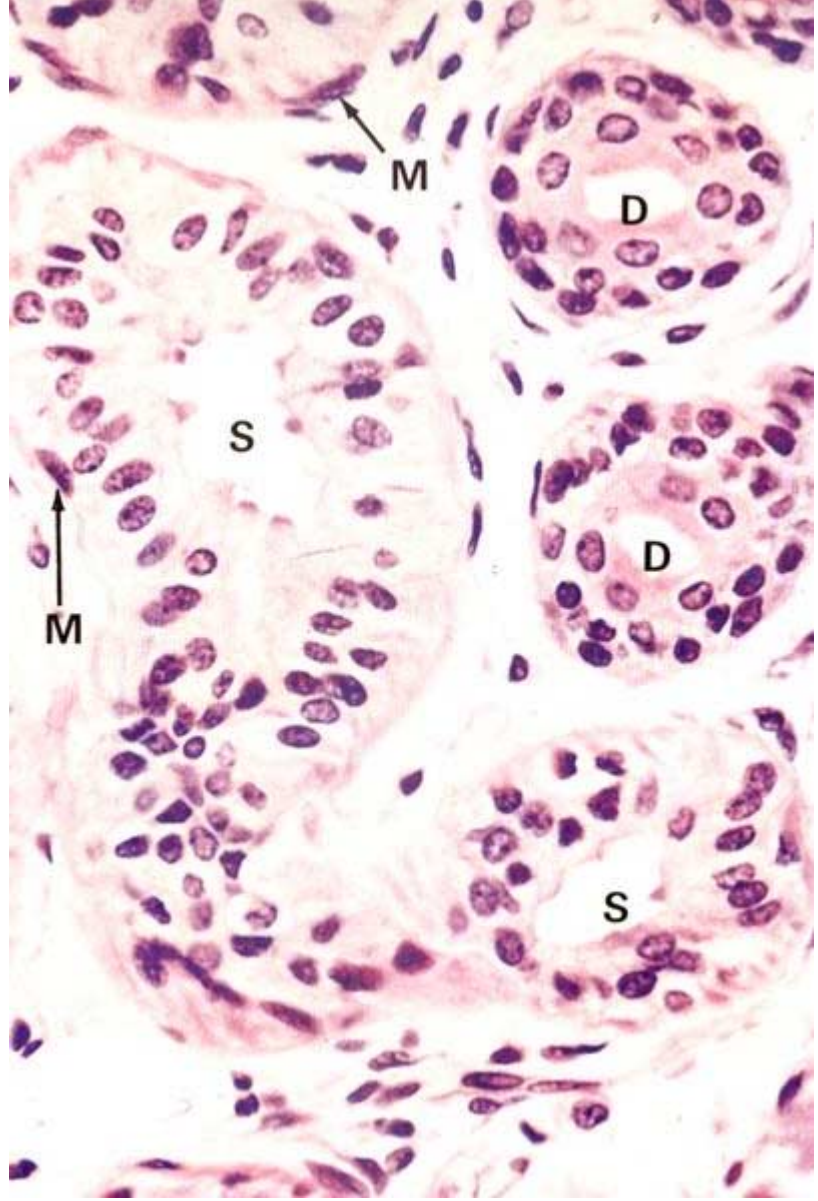

Merocrine (eccrine) Sweat Glands

Wheater's Functional Histology

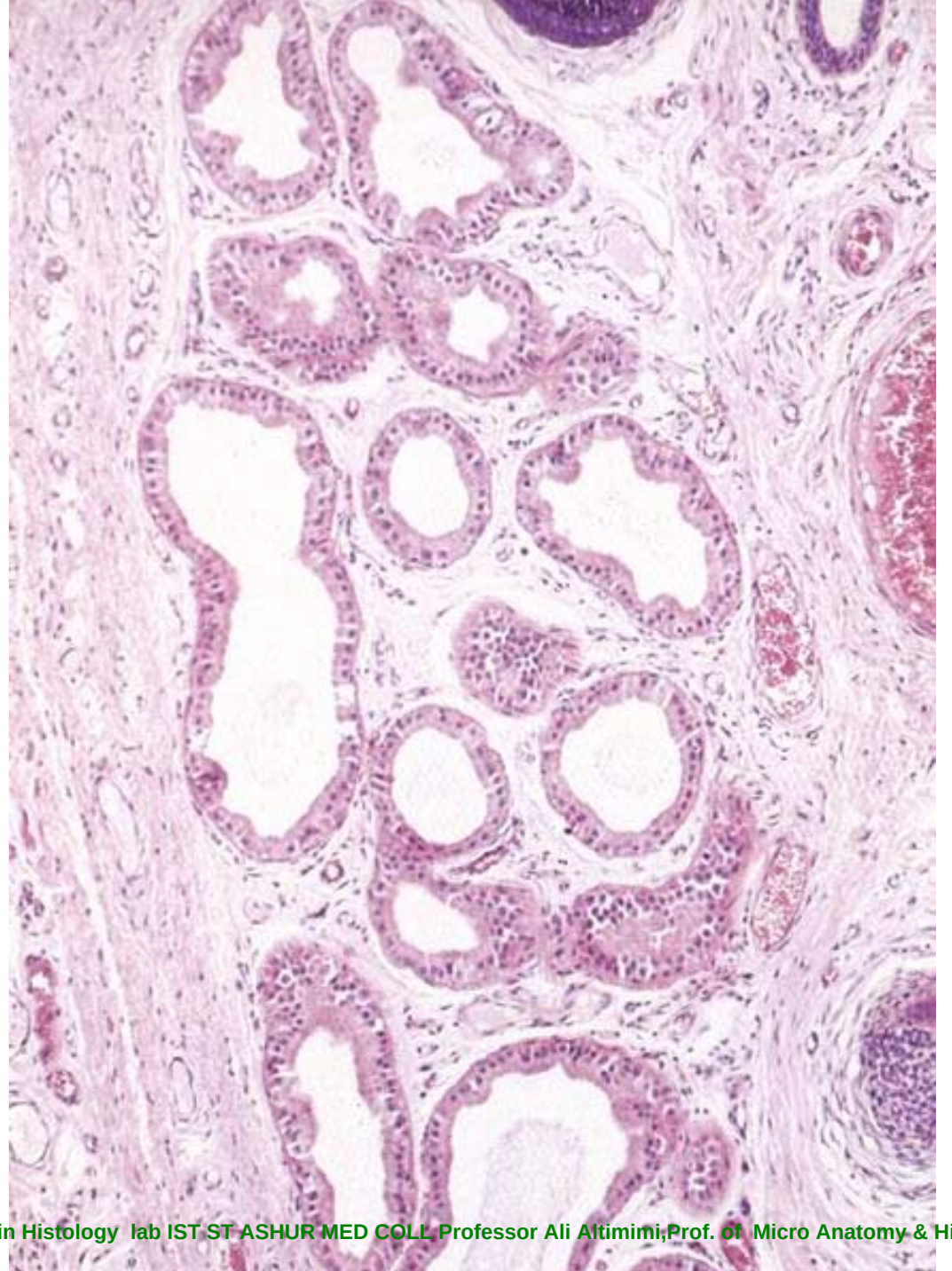

Apocrine Sweat Glands

-associated with
hair follicles

-store secretory products
in lumen

-straight duct,
non-resorptive

-inactive until puberty

Wheater's Functional Histology

Circulation

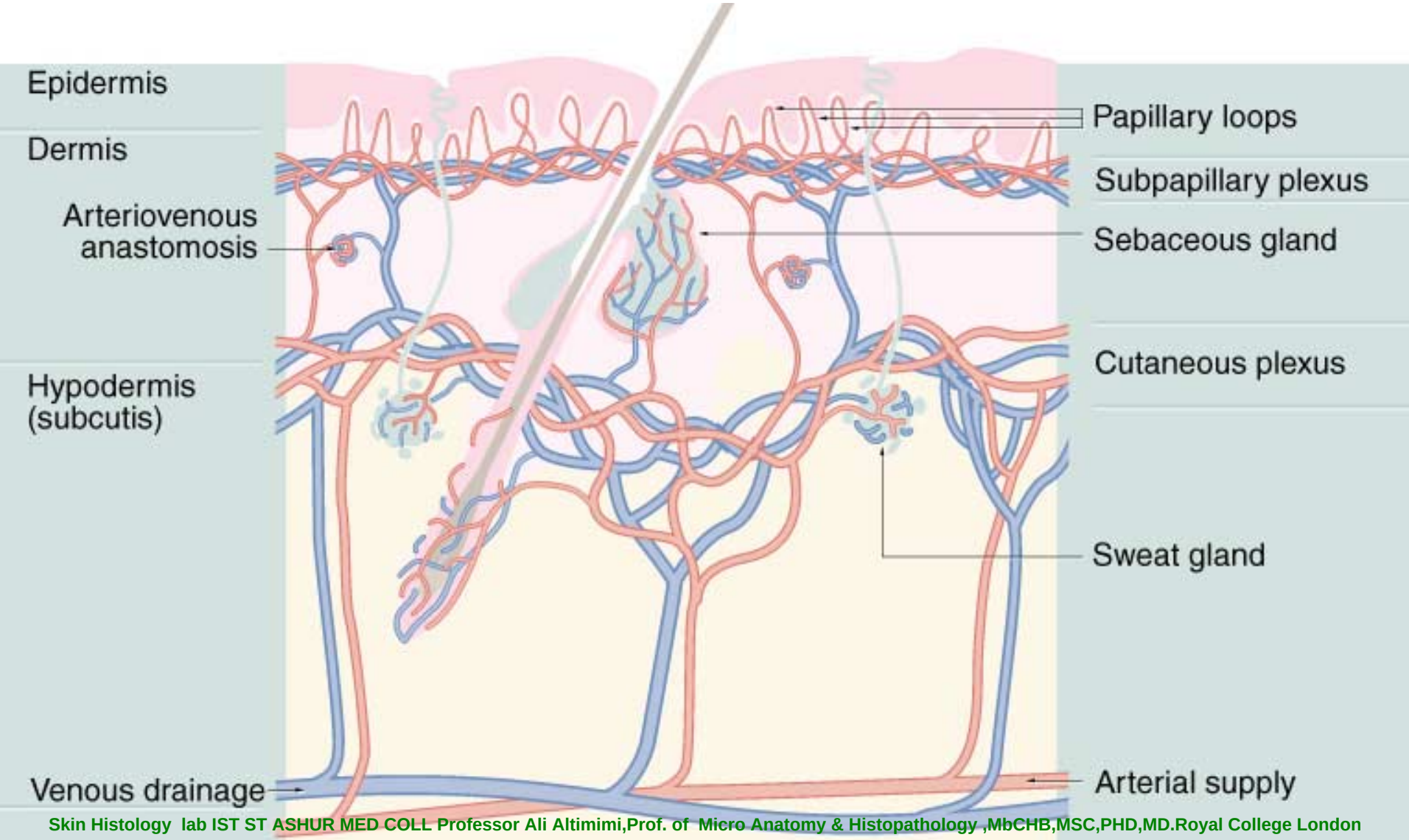

The Normal Wound Healing Response

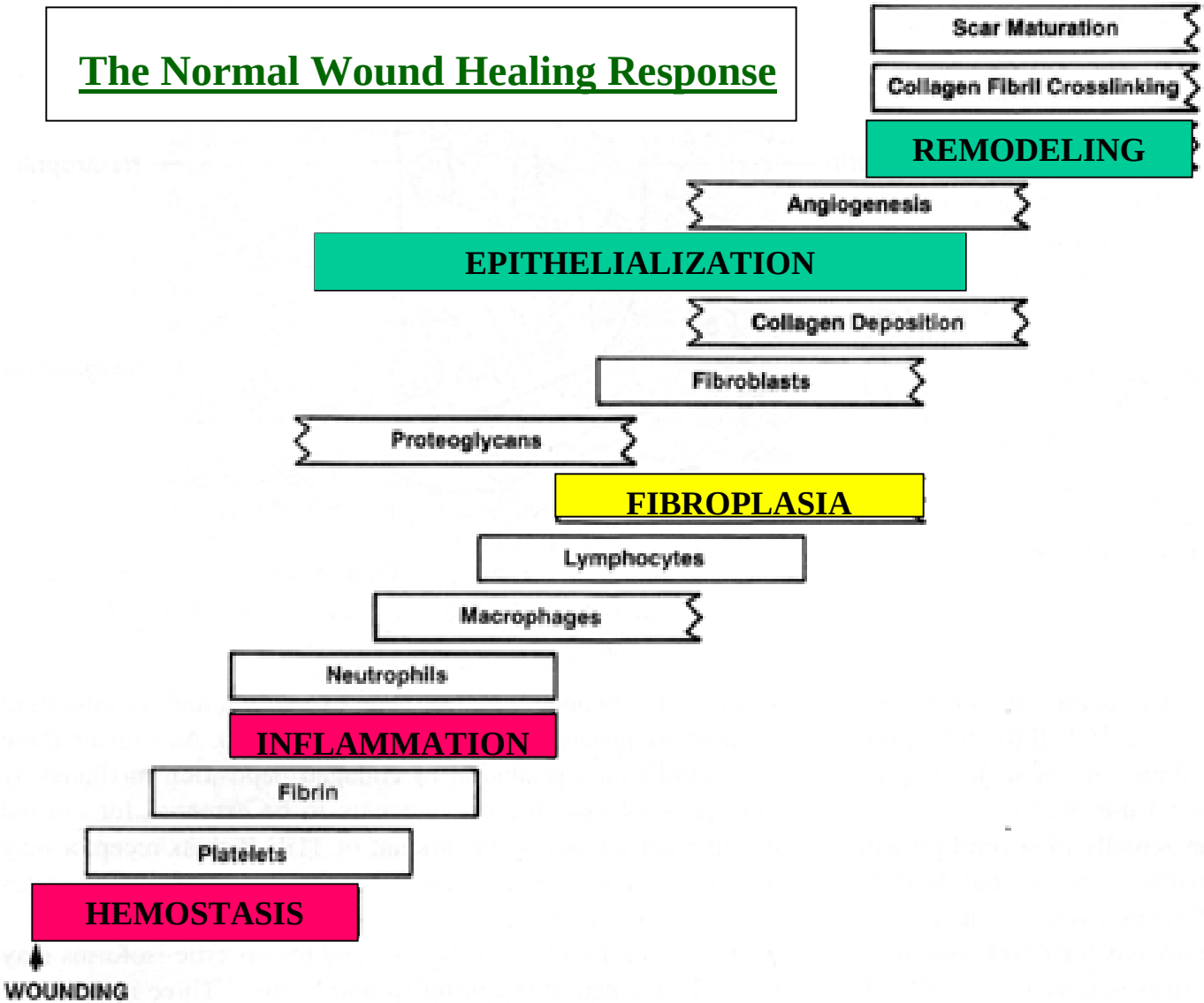

FIG. 8-9. *Sequence of events in wound healing. (Modified from: Mast BA: The skin, in Cohen IK, Diegelmann RF, Lindblad WJ (eds): Wound Healing: Biochemical and Clinical Aspects, chap 22. Philadelphia, WB Saunders, 1992, with permission.)*

Principles of Surgery

Skin Scar from Biopsy

- fibroelastic tissue forms scar
- no skin appendages
- progressive reduction in cellularity
- progressive loss of capillaries
- contraction of scar

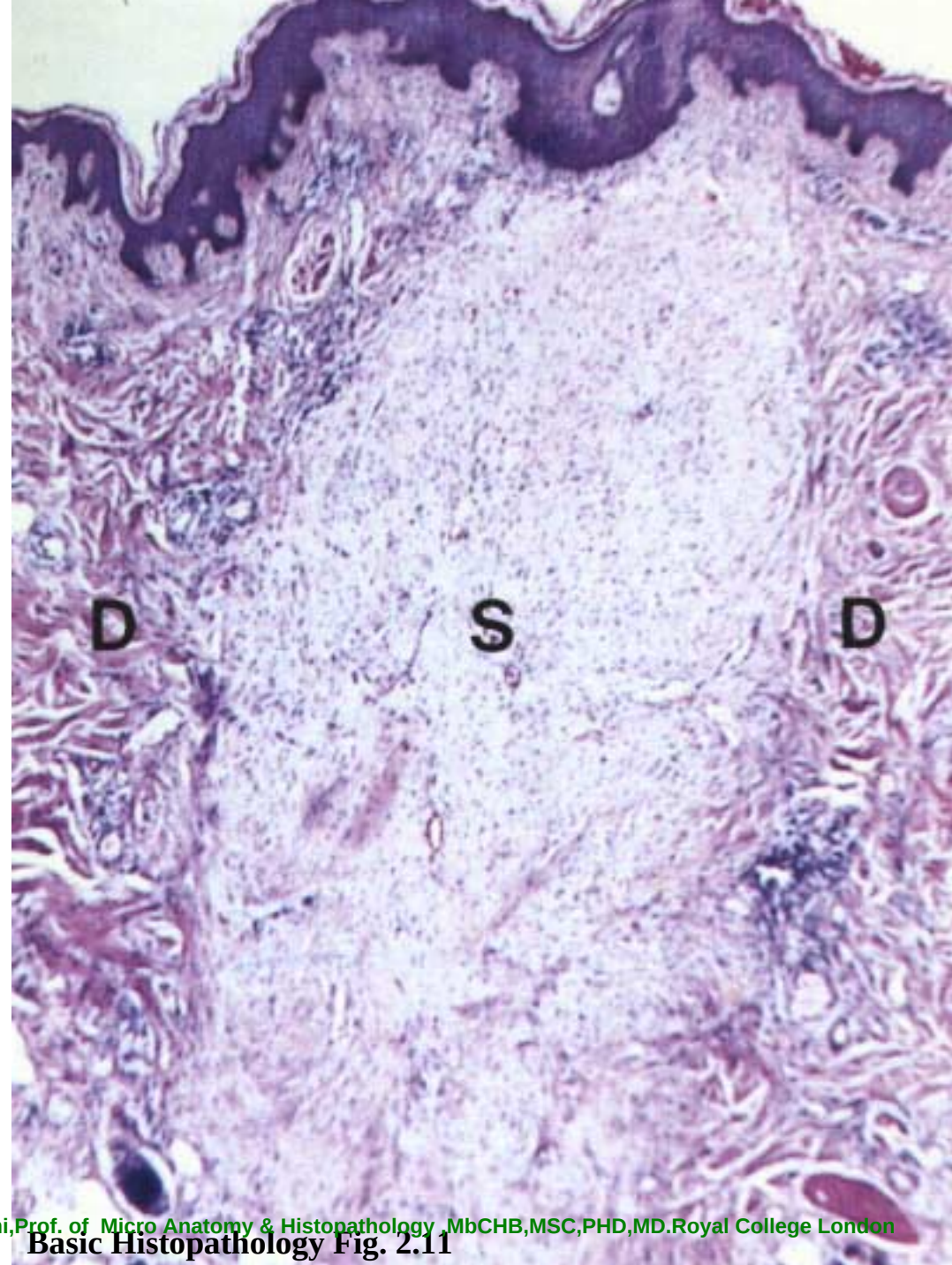

Basic Histopathology Fig. 2.11