Histology of Bone and Cartilage

Objectives :

- **By the end of this lecture, the student should describe the microscopic structure, distribution and growth of the different types of:**
  - **(1) Cartilage.**
  - **(2) Bone.**

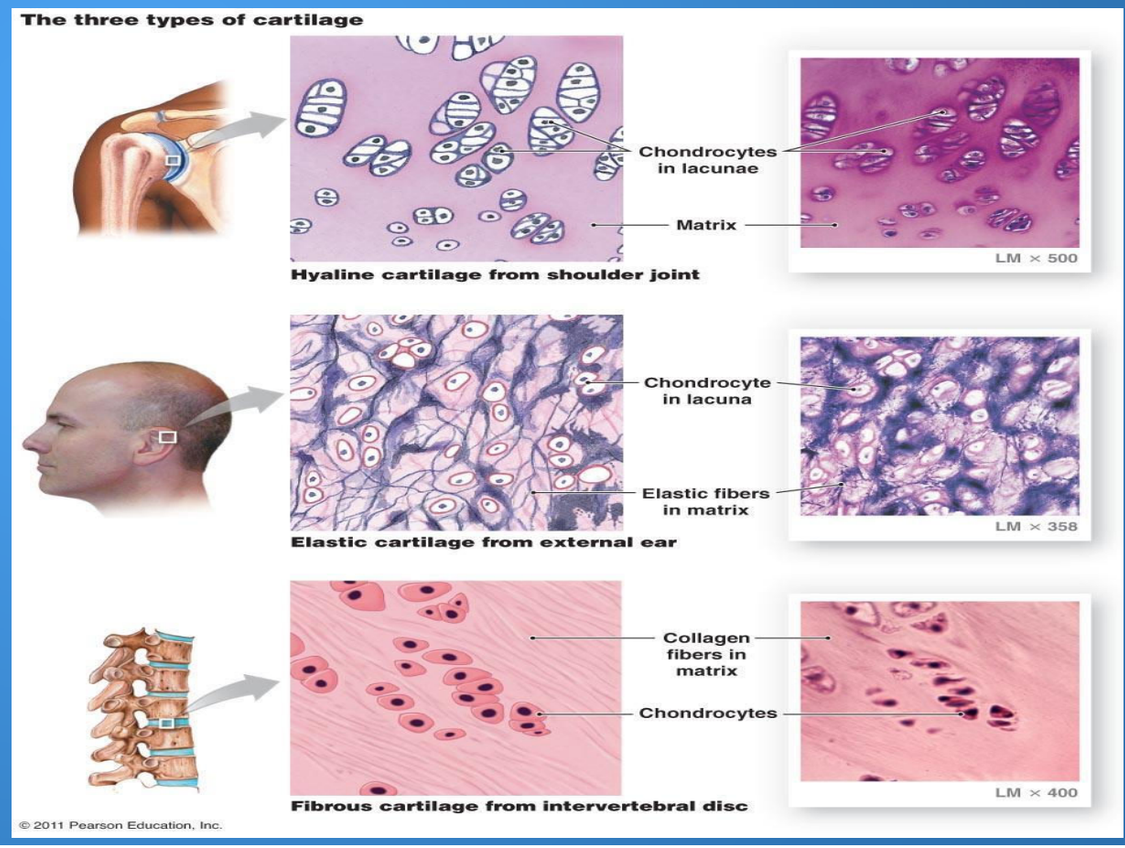

Cartilage

- Cartilage is a specialized type of **connective tissue** with a **rigid** (rubber like)matrix.
- Cartilage is usually **nonvascular** (avascular).It gets blood from perichondrium

The three types of Cartilage:

1) Hyaline cartilage (most common in the human body)
2) Elastic cartilage
3) Fibrocartilage

NOTE: all types of cartilage have collagen type II

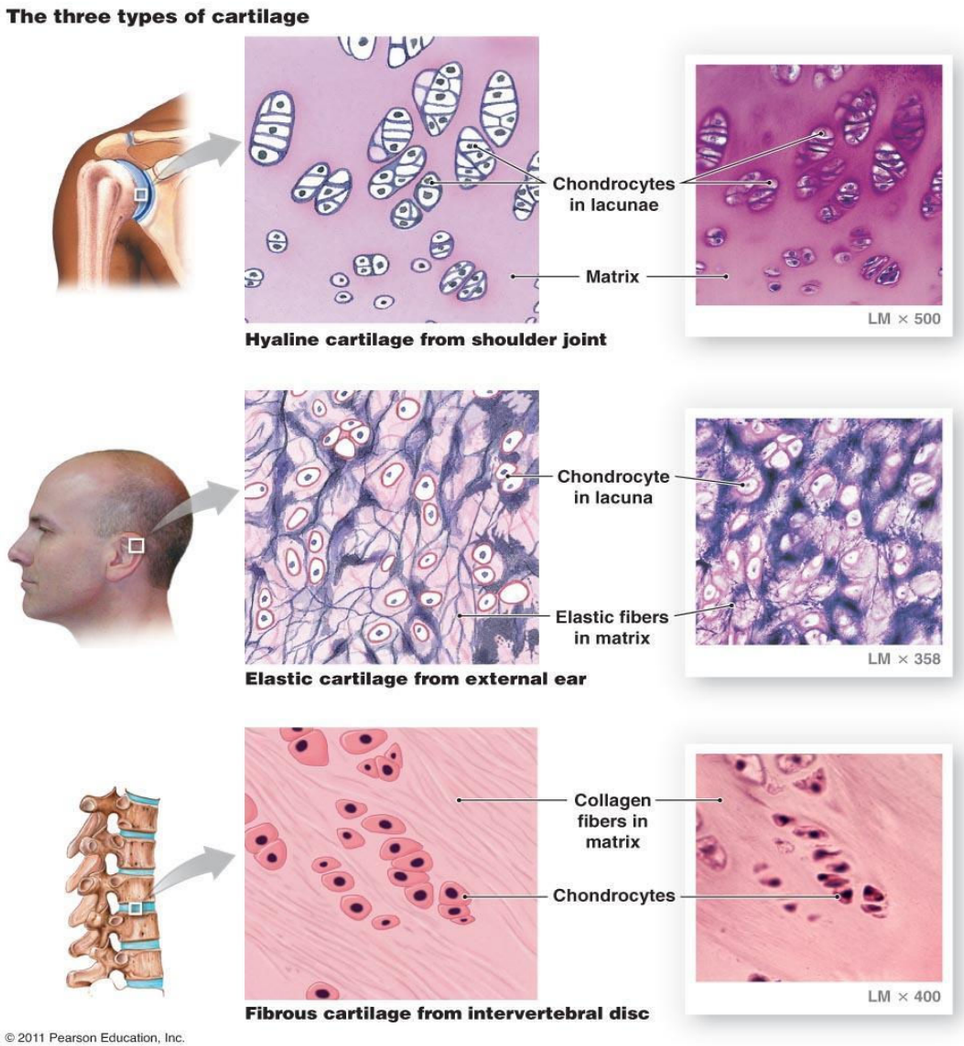

Hyaline cartilage "most common"	Perichondrium: (supplies cartilage with O2 and nutrients) -Vascular C.T Membrane of 2 layers 1) Outer layer: Dense fibrous C.T layer .(irregular collagen fibers) 2) Inner layer: Chondrogenic (cellular), with Chondroblasts (no lacuna-active cells) they secrete cartilage matrix and give rise to chondrocytes. Very Important note : the outer layer of perichondrium is formed of collagen type I . BUT when we describe the hyaline cartilage and its collagen type we say that the collagen is mainly type II	Cells (Chondrocytes): 1) Young chondrocytes: small and single (normally it is always singular , never in groups) 2) Mature chondrocytes: large and single or in groups (cell nests) - Both types are in their lacuna (space between cytoplasm and capsule) Chondrocyte = lacuna + capsule	Matrix: - Homogenous - Basophilic - Collagen type II (REMEMBER ALL TYPES OF CARTILAGE HAVE COLLAGEN TYPE II)	Sites: -Foetal skeleton (هيكل العظمي للجنين) -Costal cartilage (connects ribs to sternum) -Bones articular surfaces (between bones) -Nose -Trachea & Bronchi	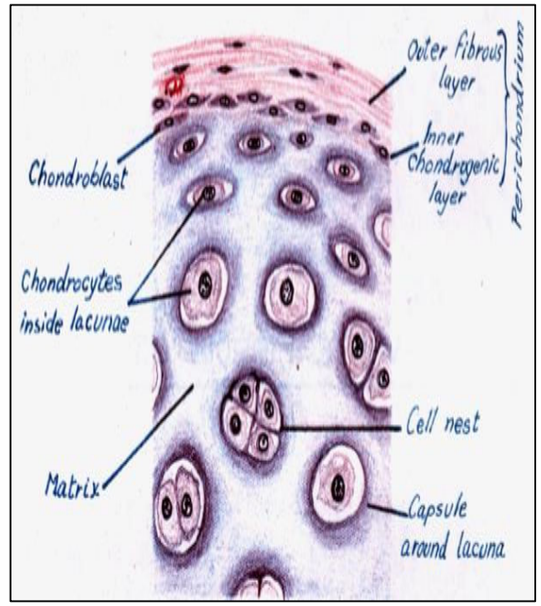
Elastic cartilage	Similar to hyaline cartilage.		Matrix: - Elastic fibers + collagen type II زي الرموش	Sites: -External ear -Epiglottis (found in larynx it closes the air way when you eat)	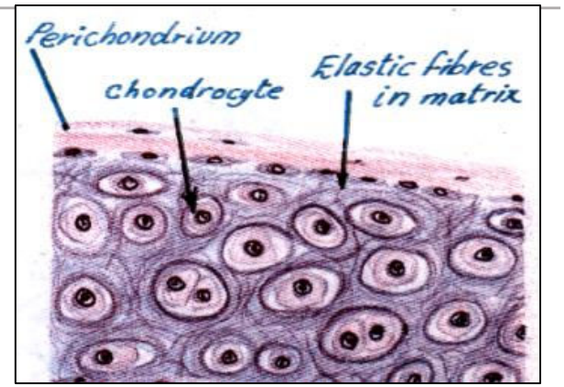
firbrocartilage	No Perichondrium	Cells (Chondrocytes): Rows of chondrocytes in their lacuna separated by parallel bundles of Collagen type 1.(We took in foundation that collagen always tend to form bundles)	Matrix: - Collagen type I Thus it is pinkish red in color.	Intervertebral disks.	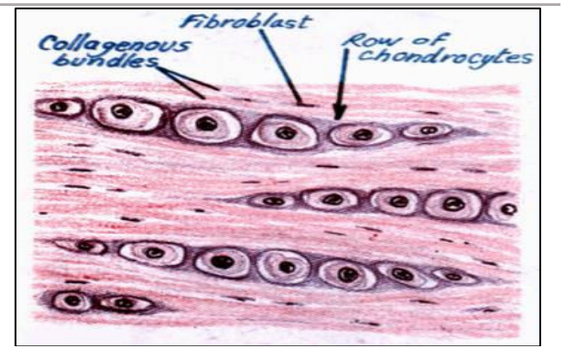

BONE

- Bone is a specialized type of ***connective tissue*** with a ***hard*** matrix.

Functions:

a) body support.

b) protection of vital organs as brain & bone marrow.

c) calcium store.

The two types of bone are :

1) Compact bone .
2) Spongy (cancellous) bone.

Components of Bones

1)Bone cells : 4 types

2)Bone matrix (calcified osteoid tissue):

- hard because it is calcified (Calcium salts).
- It contains type I collagen fibers.
- It forms bone lamellae and trabeculae

3)Periosteum

4)Endosteum

Bone cells

Osteogenic Cells:
Bone forming cell

In periosteum & endosteum

* (It's the stem cell of the bone)

Fate:
Give rise to osteoblasts

NO Lacunae

Osteoblasts:
Bone forming cell

In periosteum & endosteum .
(can't divide)
Origin: osteogenic cells

Function: They secrete the bone matrix and deposit Ca salts in it

Fate: change to osteocytes
NO Lacunae

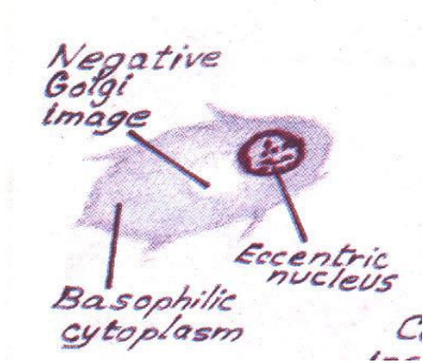

Osteocytes :
Bone forming cell

Branched cells.
Present singly in lacunae and their branches run in the canaliculi.

canaliculi

Origin : osteoblasts .
Function: They maintain the bone matrix

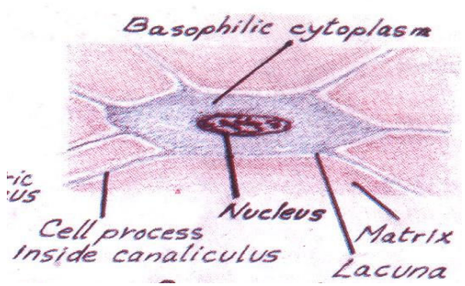

Osteoclasts:
Bone destructive cell

Large multinucleated cells on bony surfaces , in Howship's lacunae.
(when many monocytes are fused together they form the osteoclasts and that's why they're multinucleated .)

They have striated or ruffled borders .(microvilli like)

cytoplasm is rich in lysosomes

Origin: blood monocytes
Function: bone resorption.

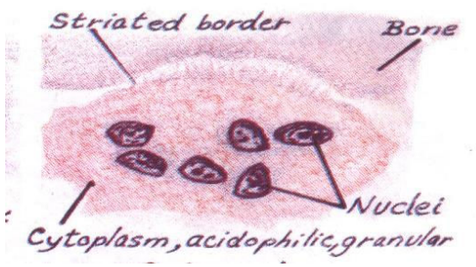

Compact bone

It is found in the diaphysis of long bones .

Consists of :

1) Periosteum .
   - ➢ Outer fibrous layer
   - ➢ Inner osteogenic layer.
2) Endosteum.
3) Bone lamellae .
4) Bone cells.

Bone Lamellae:

1- **Haversian Systems (Osteons):**

- Longitudinal cylinders.
- Each is formed of concentric bone lamellae & a Haversian canal, running in the center.
- Volkmann's canals: connect the Haversian canals together. They run obliquely or transversely.

2. **External Circumferential Lamellae.**

3- **Internal Circumferential Lamellae.**

4- **Interstitial Lamellae:** between osteons.

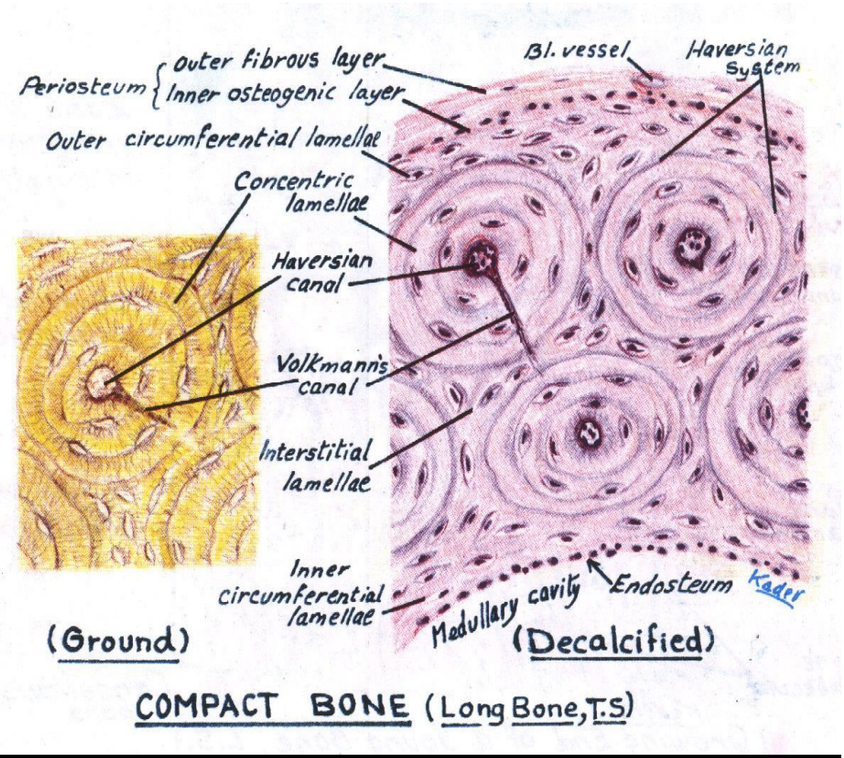

COMPACT BONE (Long Bone, T.S)

Spongy bone

In is found flat bones & epiphysis of long bones.

It **Consists of :**

1. Periosteum.
2. Endosteum.
3. Irregular bone trabeculae.
   - are formed of irregular bone lamellae separated by osteocytes inside lacunae.
4. Many irregular red bone marrow spaces.
5. Bone Cells.

NO HAVERSIAN SYSTEMS (NO OSTEONS).

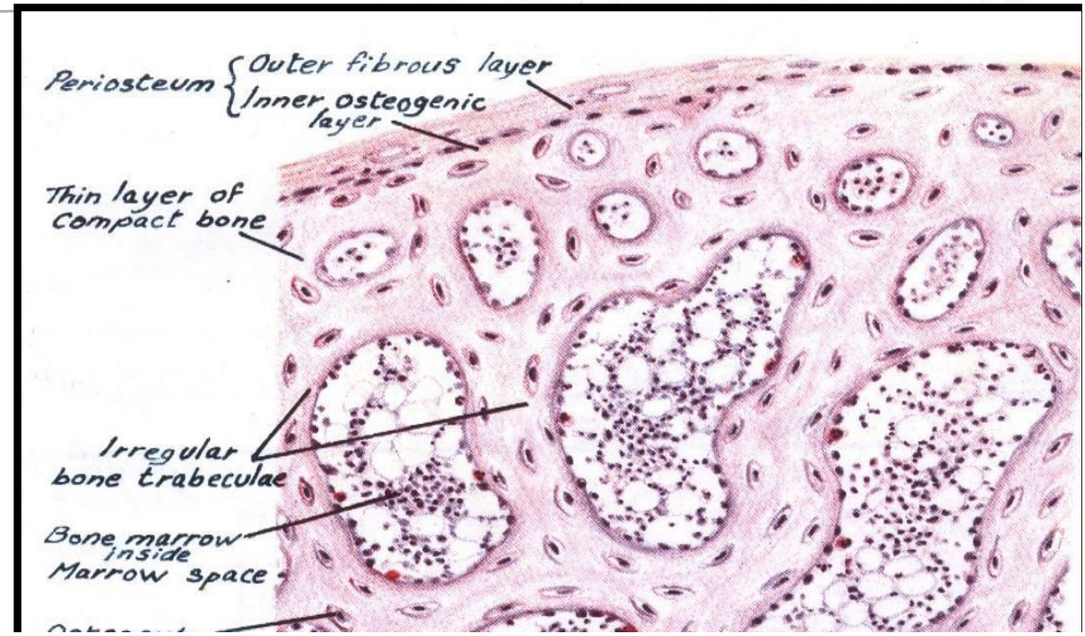

Growth of Cartilage and Bones

	Appositional growth (increase in width)	*Interstitial growth* (increase in length)
Cartilage	**Produced by the activity of**: **Chondroblast** In the inner chondrogenic layer 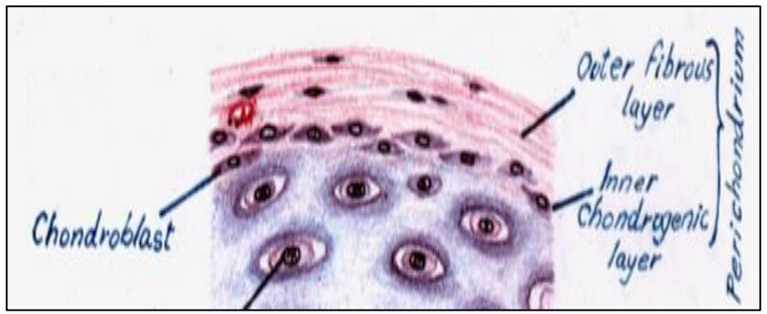	**Produced by division and activity of**: **Mature Chondrocyte** 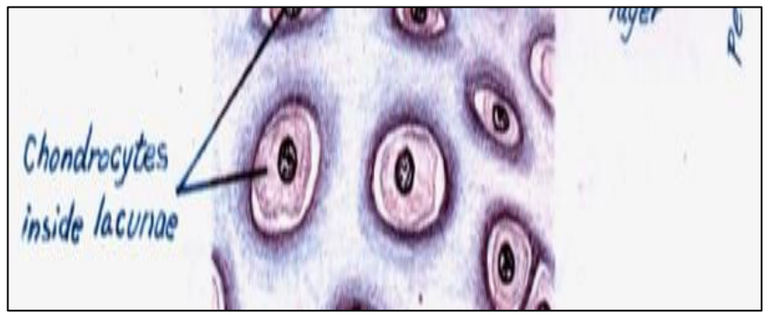
	Appositional growth (increase in width)	*Growth in length* (increase in length)
Bone	• Is produced by the activity of osteoblasts. • It leads to increase in width.	• Is produced by the activity of epiphyseal plate of cartilage.

NOTE: Because the ground substance and ECF in the cartilage are rubbery it gives space for expansion, but in bones the ground substance and ECF are hard so the osteocyte can not divide in the lacunae because there is no space and hard so it is unable to expand.

* EXTRA SLIDE

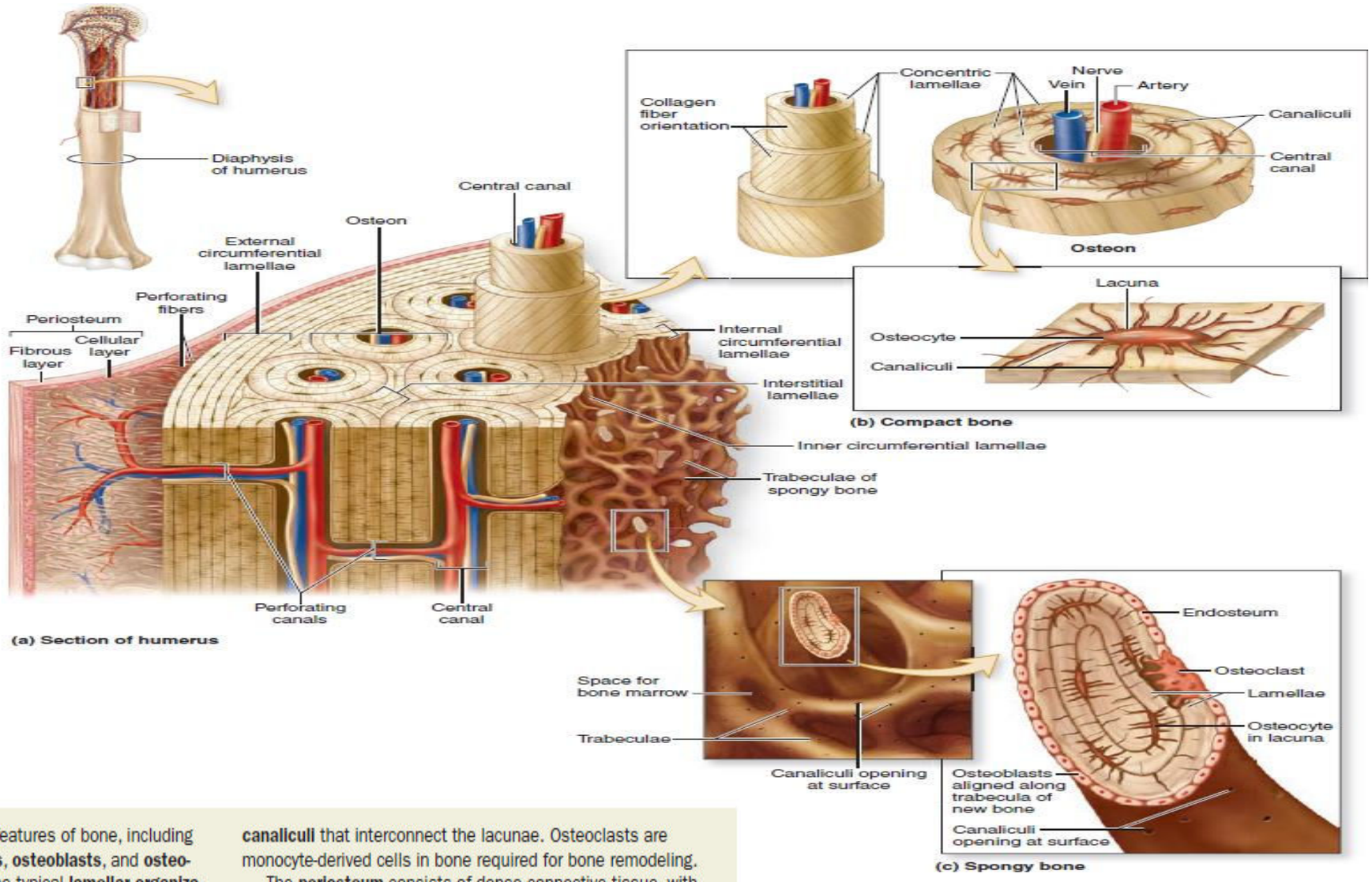

A schematic overview of the basic features of bone, including the three key cell types: **osteocytes**, **osteoblasts**, and **osteoclasts**; their usual locations; and the typical **lamellar organization** of bone. Osteoblasts secrete the matrix that then hardens by calcification, trapping the differentiating cells now called **osteocytes** in individual **lacunae**. Osteocytes maintain the calcified matrix and receive nutrients from microvasculature in the central canals of the osteons via very small channels called **canaliculi** that interconnect the lacunae. Osteoclasts are monocyte-derived cells in bone required for bone remodeling.

The **periosteum** consists of dense connective tissue, with a primarily fibrous layer covering a more cellular layer. Bone is vascularized by small vessels that penetrate the matrix from the periosteum. **Endosteum** covers all **trabeculae** around the marrow cavities.

+ Extra notes 3 minutes will help you understand the lecture more :)

- hyaline = glassy. - Blast = active cell. - Lacunae = spaces.
- Cartilage is usually avascular, but the perichondrium is VASCULAR to supply it.
- Mature chondrocytes are the only ones that divide.
- Fetal skeleton changes from cartilage to bone during child growth.
- Hyaline cartilage is in the joints for making their surfaces smooth and to prevent the friction.
- Fibrocartilage receives a very poor blood supply -because it doesn't have perichondrium- so for example if someone is injured in their intervertebral disk it is
almost impossible for it to heal so it is most likely replaced. note that there is no perichondrium so the cell must get its nutrients from neighboring cells.
- Spaces inside spongy bones contain bone marrow.
- Spongy bones are the main source of bone marrow after old age. (The bone marrow found in the shaft of compact bone is converted into fat).
- Function of canaliculi: communication between cells and transport the nutrition into the bone marrow of the cell. (We can find canaliculi only in bone.)
- Q: Can we find canaliculi on chondrocyte? NO
- Ca is important for muscles contraction. if we were on a diet or the level of Ca in blood decreased for any reason osteoclasts will start to free Ca from bones. So,
the Ca level in blood will be raised but in bone will be decreased. (lose its balance)
- Bone forming cells: osteogenic, osteoblast and osteocytes.
- Bone destruction cell: osteoclasts. (Osteoclasts are responsible for bone modulation "sculpture" in case of injury, it removes the extra bone tissue after the healing of fracture)
- Haversian systems are made of Haversian canals which carry the blood vessels (arteries and veins), nerves, and possibly lymph vessels through it. Around the canals in whorl-like arrangements are the osteocytes entrapped within the bony matrix (concentric bone lamellae).
- Volkmann's canal is not part of the Haversian system, it is only a way to communicate with other Haversian systems
- Bones are highly vascular while cartilage is avascular. Remember: bones fractures are dangerous because fractured bones may cut vessels causing hemorrhage

SUMMARY

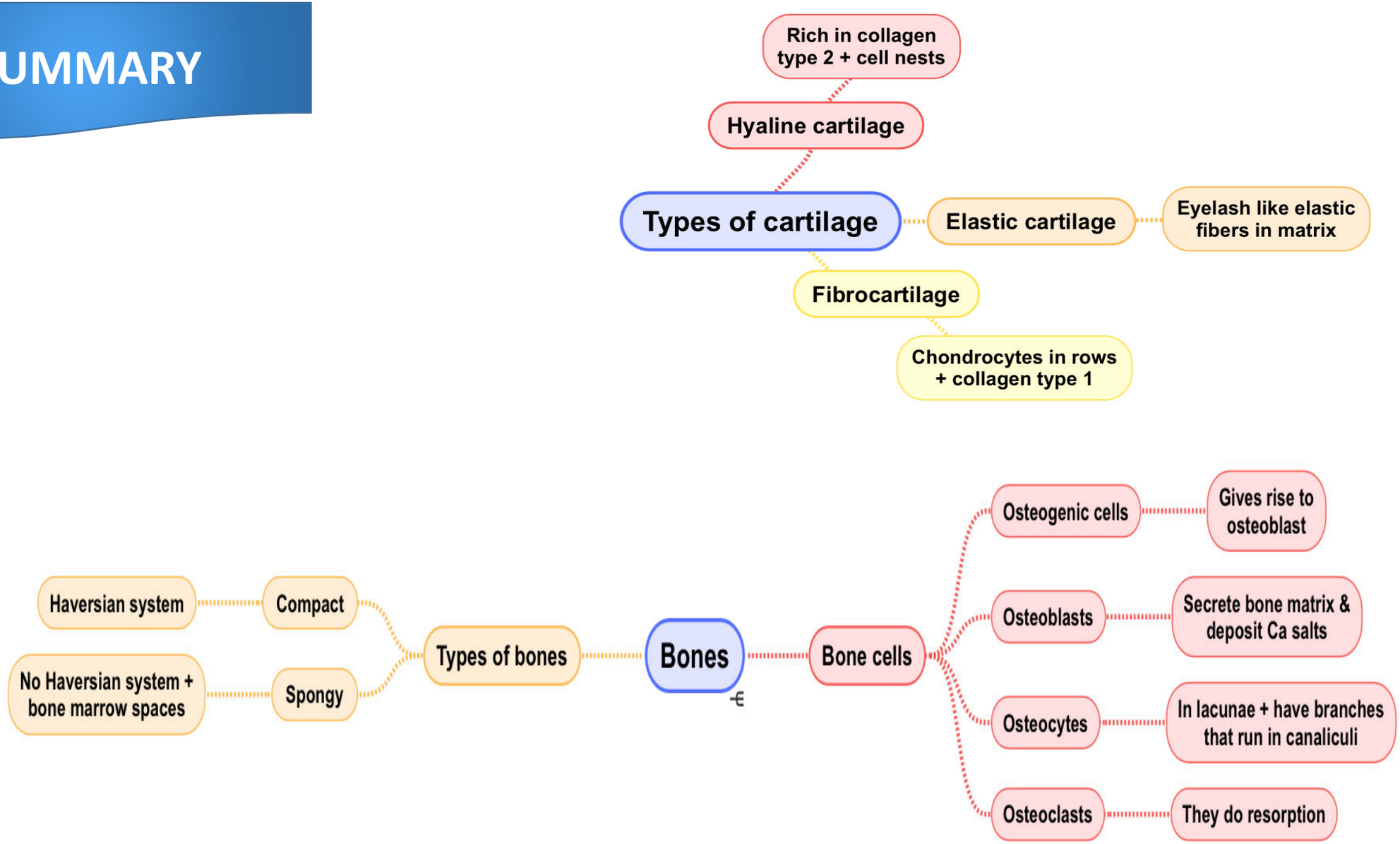
Rich in collagen type 2 + cell nests
Hyaline cartilage
Types of cartilage
Elastic cartilage
Eyelash like elastic fibers in matrix
Fibrocartilage
Chondrocytes in rows + collagen type 1
Haversian system
Compact
No Haversian system + bone marrow spaces
Spongy
Types of bones
Bones
Bone cells
Osteogenic cells
Gives rise to osteoblast
Osteoblasts
Secrete bone matrix & deposit Ca salts
Osteocytes
In lacunae + have branches that run in canaliculi
Osteoclasts
They do resorption

QUESTIONS

1.Cartilage is a specialized type of C.T. with a hard matrix.
A)True
B)False

2.In Hyaline cartilage, inner chondrogenic layer contains chondroblasts with lacunae.
A)True
B)False

3.The chondrocytes could be ……. which are large and found either singly or in groups, or ……. which are small and present singly only.
A)Young Chondrocytes – Mature Chondrocytes
B) Mature Chondrocytes – Young Chondrocytes

4.Which of the following is NOT considered a site of hyaline cartilage?
A)Foetal skeleton.
B)Costal cartilages.
C) Articular surfaces of bones.
D) External ear.

5.Which type of cartilages is rich in collagen type I?
A)Hyaline cartilage
B)Elastic cartilage
C)Fibrocartilage

6. Elastic cartilage contain …….fibers .
A)Collagen type 1
B)Collagen type 2
C)Elastic
D)All of the above

7.Appositional growth leads to:
A)Decrease in length
B)Increase in length
C) Decrease in width
D) Increase in width

8. Interstitial growth is produced by division and activity of mature chondrocytes.
A) True
B) False

9.Fibrocartilage (found in intervertebral disk) requires long healing process when it's get injured because the lack of
A)Elastic fibers
B)Perichondrium
C)Stroma
D)Haversian system

1)B
2)B
3)B
4)D
5)C
6)C
7)D
8)A
9)B

QUESTIONS

1.who's rest in howship lacuna
A)Osteoclast
B)Osteocyte
C)Monocyte
D)Osteoblast

2.trabeculae found in all bones
A)True
B)false

3.…….form bone matrix
A)osteoclast
B)osteocyte
C)osteoblast
D)osteogenic cell

4.Origin or osteoclasts?
A)Lymphocytes
B)Macrophages
C)Fibroblasts
D)Monocytes

5.Compact bone is found in the epiphysis.
A)True
B)False

6.Haversian Systems (Osteons) are only found in compact bone.
A) True
B) False

7.Appositinal growth in bone …….
A)Produced by osteoblast and lead to increase in length
B)Produced by osteoblast and lead to increase in width
C)Produced by epiphyseal plate and lead to increase in length
D)Produced by epiphyseal plate and lead to increase in width

8.Osteoclast originate from ……
A)Macrophage
B)Monocyte
C)Osteogenic cell
D)Giant cell

9.Fibrocartilage (found in intervertebral disk) requires long healing process when it's get injured because the lack of …….
A)Elastic fibers
B)Perichondrium
C)Stroma
D)Haversian system

1)A
2)B
3)C
4)D
5)B
6)A
7)B
8)B
9)B