Connective Tissue

Histology lab & Lec , TBL

- Connective tissue develops from mesenchyme
- GENERAL COMPOSITI ON of connective tissues:
- 1. Cells
- 2. Intercellular substance amorphous ground substance
- 3.fibers.

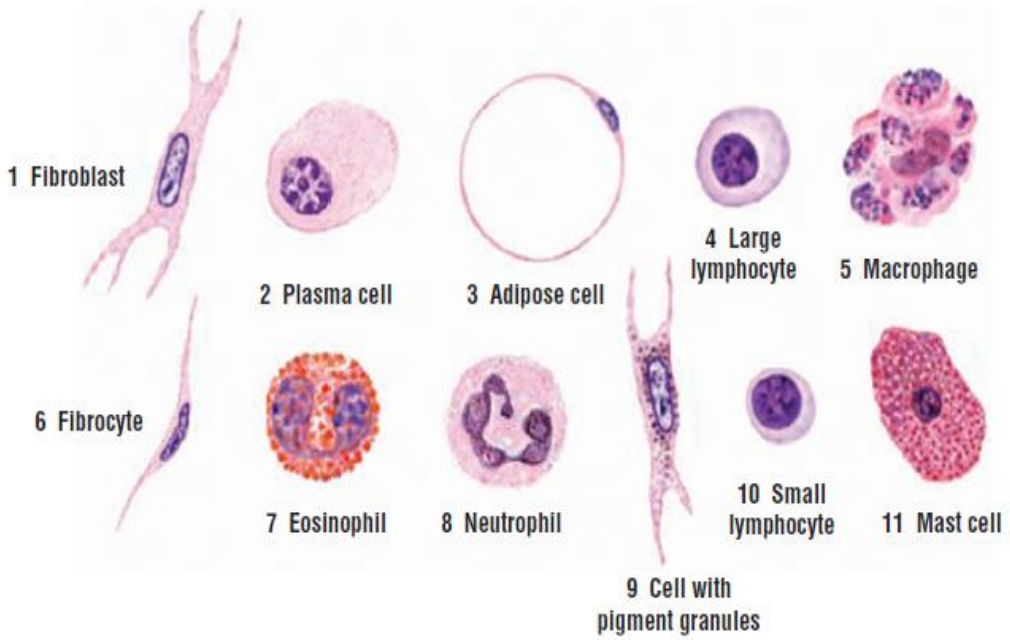

Cells of the Connective Tissue

- **fibroblasts** :- Fusiform-shaped fibroblasts synthesize all of the connective tissue fibers and the extracellular ground substance.
- **Adipose (fat) cells,** which may occur singly or in groups, these cells store fat. When adipose cells predominate, the connective tissue is called an **adipose tissue.**
- **Macrophages** or **histiocytes** are phagocytic cells and are most numerous in loose connective
- tissue. They have phagocytic activity and contain ingested material in their cytoplasm.
- **Mast cells:-** spherical cells usually closely associated with blood vessels, skin and in the digestive and respiratory organs.
- **Plasma cells** arise from the lymphocytes These cells are found in great abundance in loose connective tissue and lymphatic tissue of the respiratory and digestive tracts.
- **Leukocytes,** or white blood cells, neutrophils, and eosinophils, migrate into the connective tissue from the blood vessels. Their main function is to defense against bacterial invasion or foreign matter.

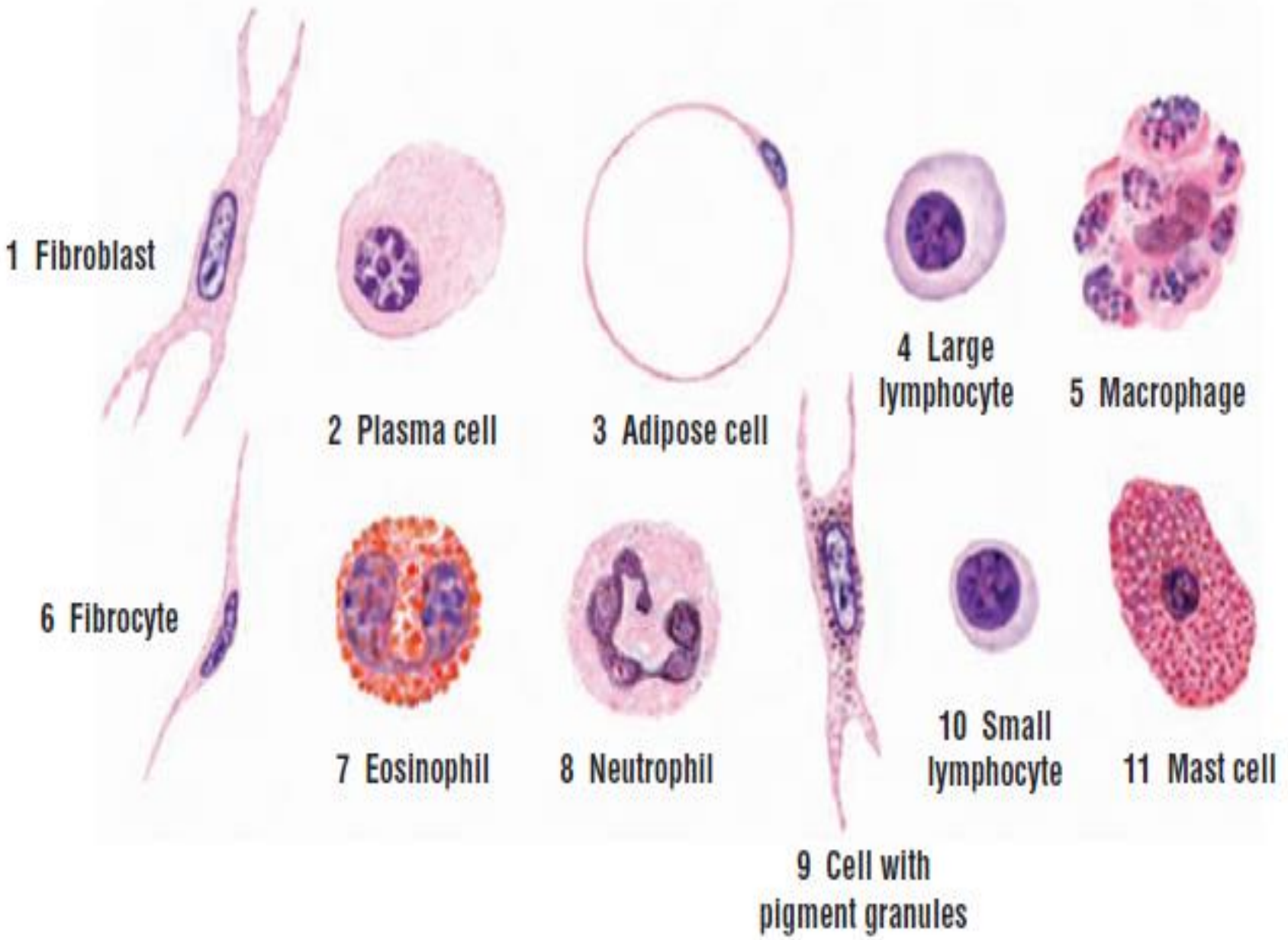
1 Fibroblast
2 Plasma cell
3 Adipose cell
4 Large lymphocyte
5 Macrophage
6 Fibrocyte
7 Eosinophil
8 Neutrophil
9 Cell with pigment granules
10 Small lymphocyte
11 Mast cell

INTERCELLULAR SUBSTANCE composition:

Amorphous ground substance: viscous, transparent

Contains:

1-water

2- ions

3-GAG – glycosaminoglycans.

4- PG – proteoglycans.

5- SGP – structural glycoproteins.

6– globular protein: fibronectin, laminin, chondronectin, osteonectin

- Function: interaction of neighbouring cells, adhesion of cells to their substrate

Fibers of the Connective Tissue

- Collagen
- elastic
- reticular fibers.

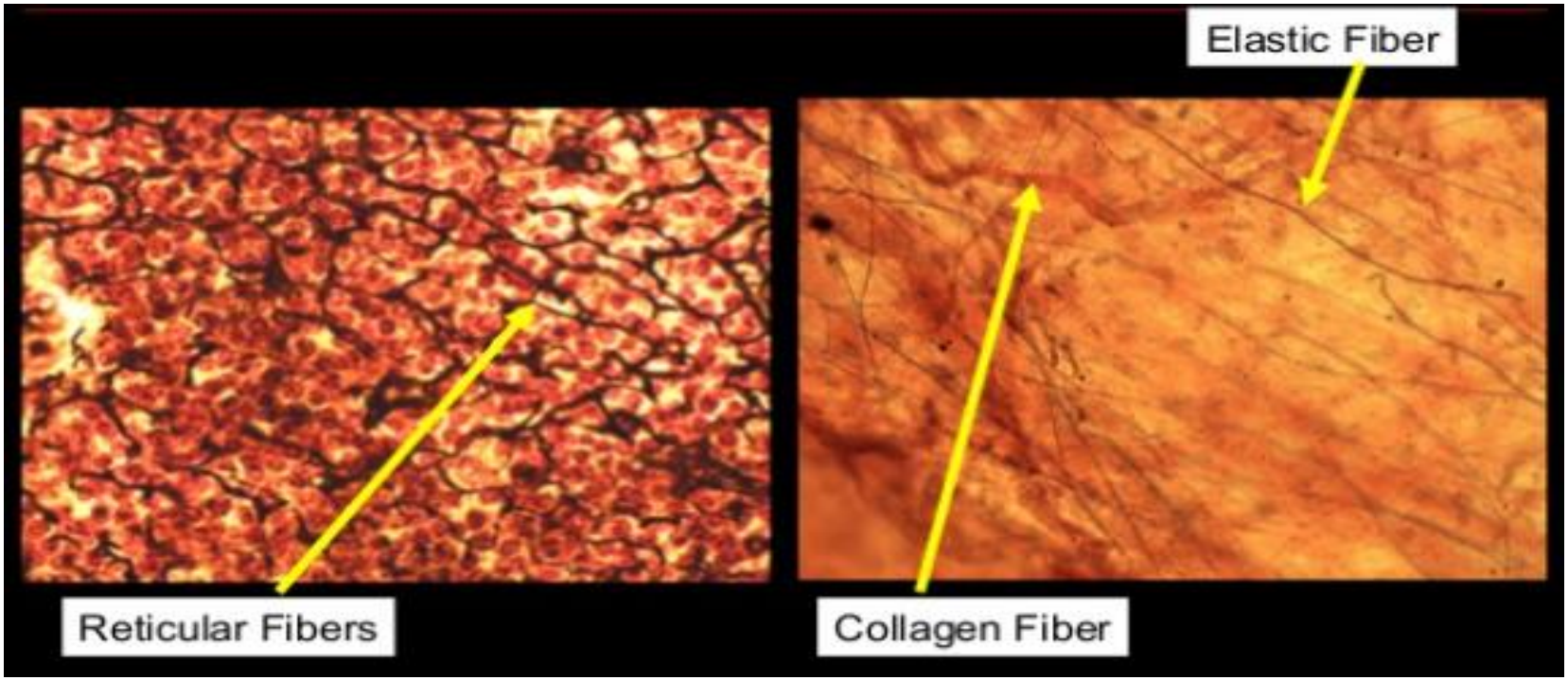

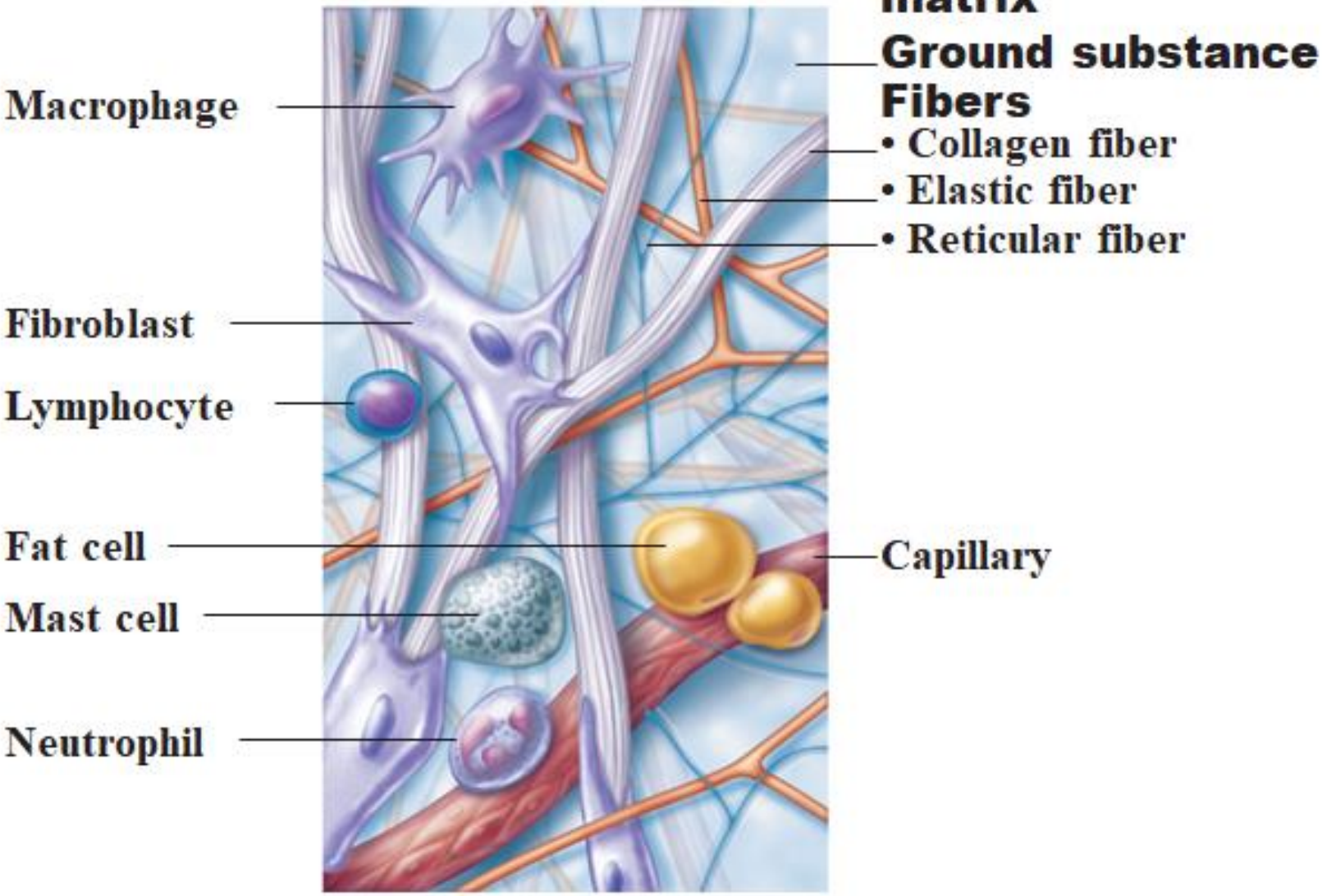
Cell types
Macrophage
Fibroblast
Lymphocyte
Fat cell
Mast cell
Neutrophil
Extracellular matrix
Ground substance
Fibers
• Collagen fiber
• Elastic fiber
• Reticular fiber
Capillary

Classification

- The connective tissue is classified depending on the amount, type, arrangement, and abundance of cells, fibers, and ground substance as :-

1. Connective tissue proper

a. loose connective tissue (areolar)

b. dense connective tissue

c. Adipose connective tissue

- regular dense connective tissue

- irregular dense connective tissue

2. Embryonic Connective Tissue

3. Fluid connective tissue:- Blood

4. Supporting connective tissue :-bone and cartilage

Loose Connective Tissue

- Loose connective tissue is more prevalent in the body than dense connective tissue.
- It is characterized by a loose, irregular arrangement of connective tissue fibers and abundant ground substance.
- fibroblasts, adipose cells, mast cells, and macrophages predominate in loose connective tissue.

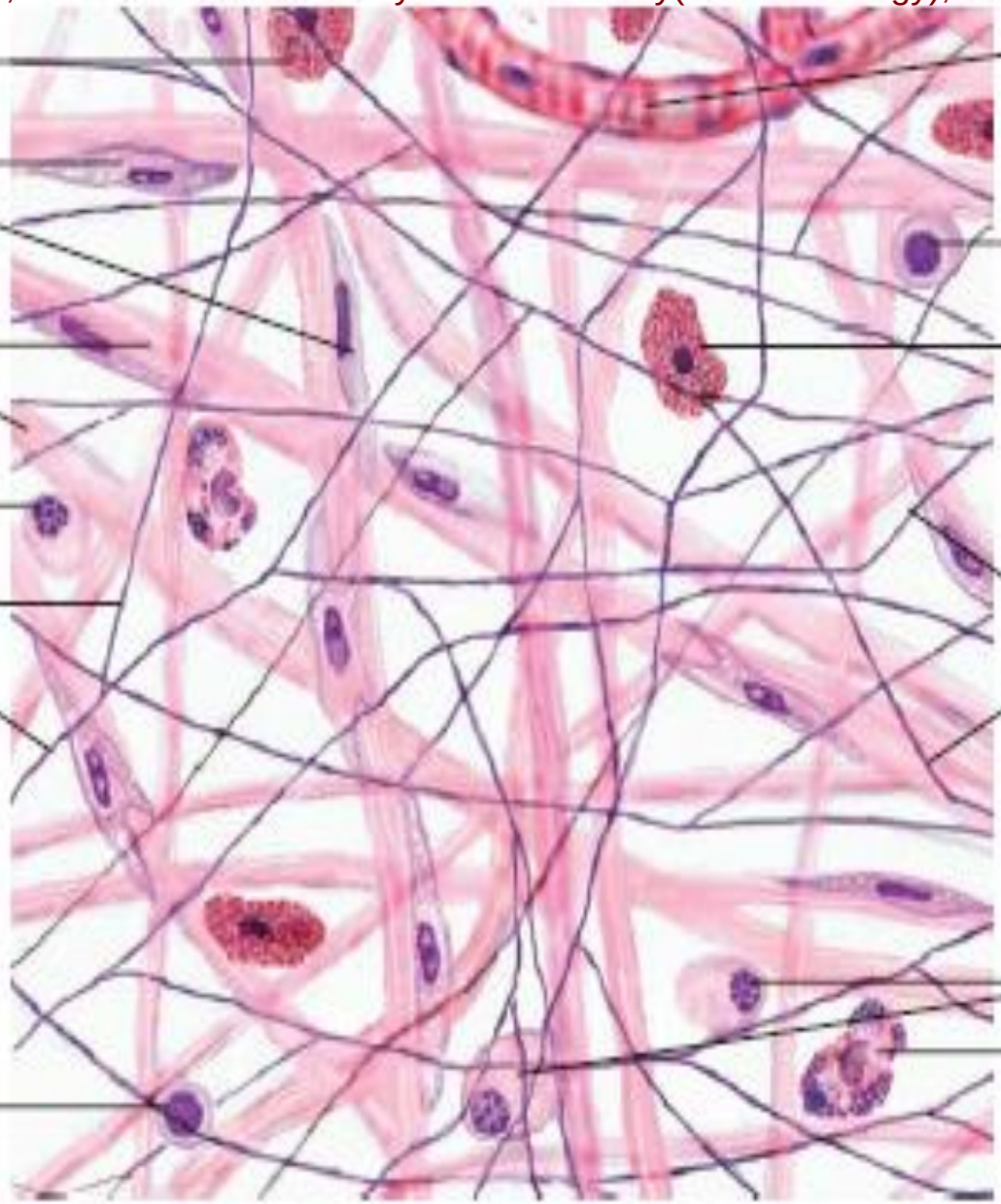
1 Mast cell
2 Fibroblasts
3 Collagen fibers
4 Plasma cell
5 Elastic fibers
6 Small lymphocyte
7 Capillary with erythrocytes
8 Large lymphocyte
9 Mast cell
10 Elastic fibers
11 Plasma cells
12 Macrophage with ingested particles

Professor Ali Altimimi,Prof. of Clinical Anatomy & Micoanatomy(HistoPathology),MbCHB,MSC,PHD,MD

loose connective tissue

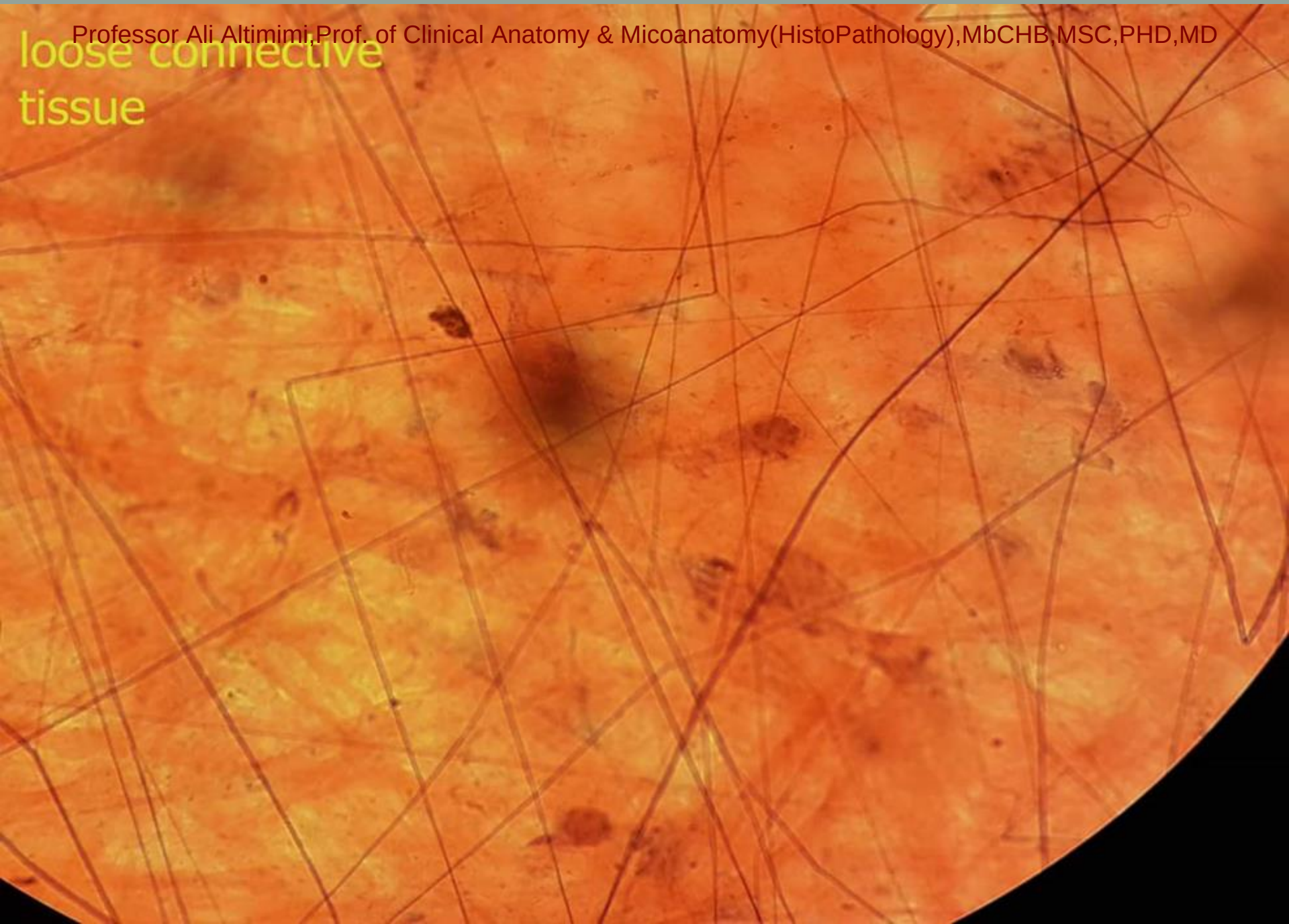

Dense Connective Tissue

- In contrast, dense connective tissue contains thicker and more densely packed collagen fibers, with fewer cell types and less ground substance.
- Has two types:-
- 1- Dense irregular connective tissue:- collagen fibers exhibit a random and irregular orientation it is present in the dermis

of skin, in capsules of different organs, and in areas that need strong support.

- 2- Dense regular connective tissue:- contains densely packed collagen fibers that exhibit a regular and parallel arrangement. This type of tissue is found in the tendons and ligaments.
- In both connective tissue types, fibroblasts are the most abundant cells, which are located between the dense collagen bundles.

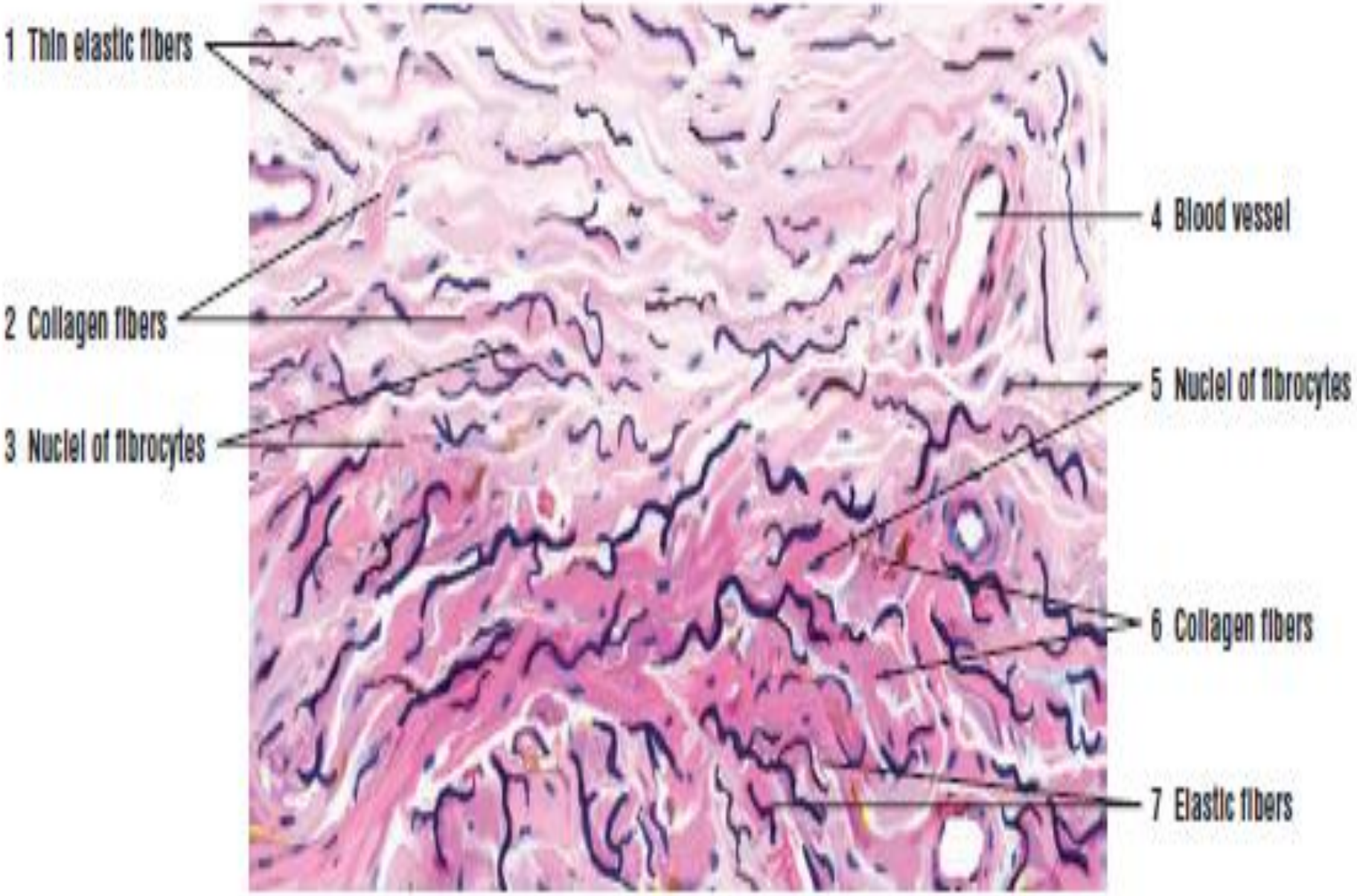
1 Thin elastic fibers
2 Collagen fibers
3 Nuclei of fibrocytes
4 Blood vessel
5 Nuclei of fibrocytes
6 Collagen fibers
7 Elastic fibers

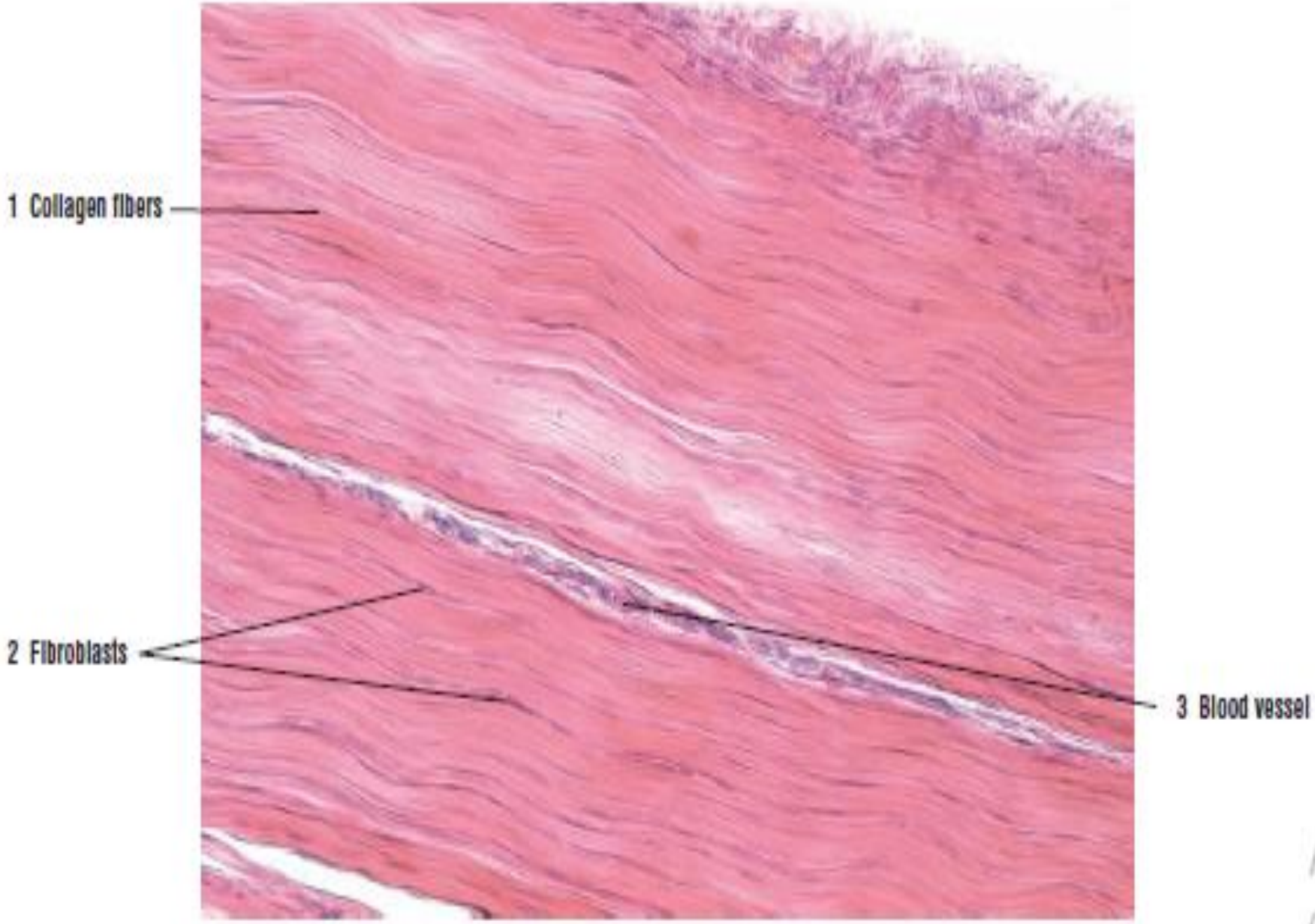
1 Collagen fibers
2 Fibroblasts
3 Blood vessel

Professor Ali Altimimi,Prof. of Clinical Anatomy & Micoanatomy(HistoPathology),MbCHB,MSC,PHD,MD

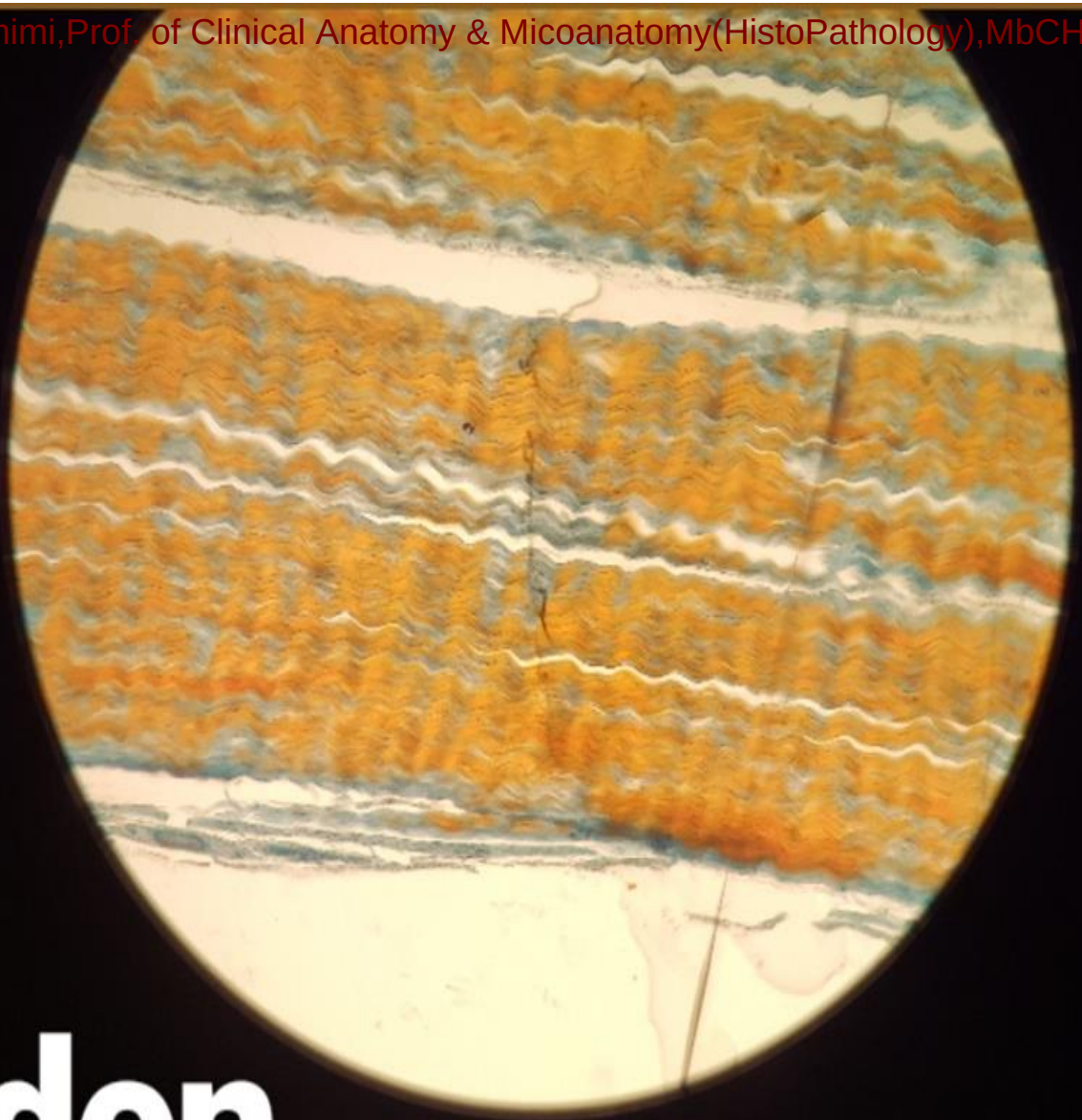

Tendon

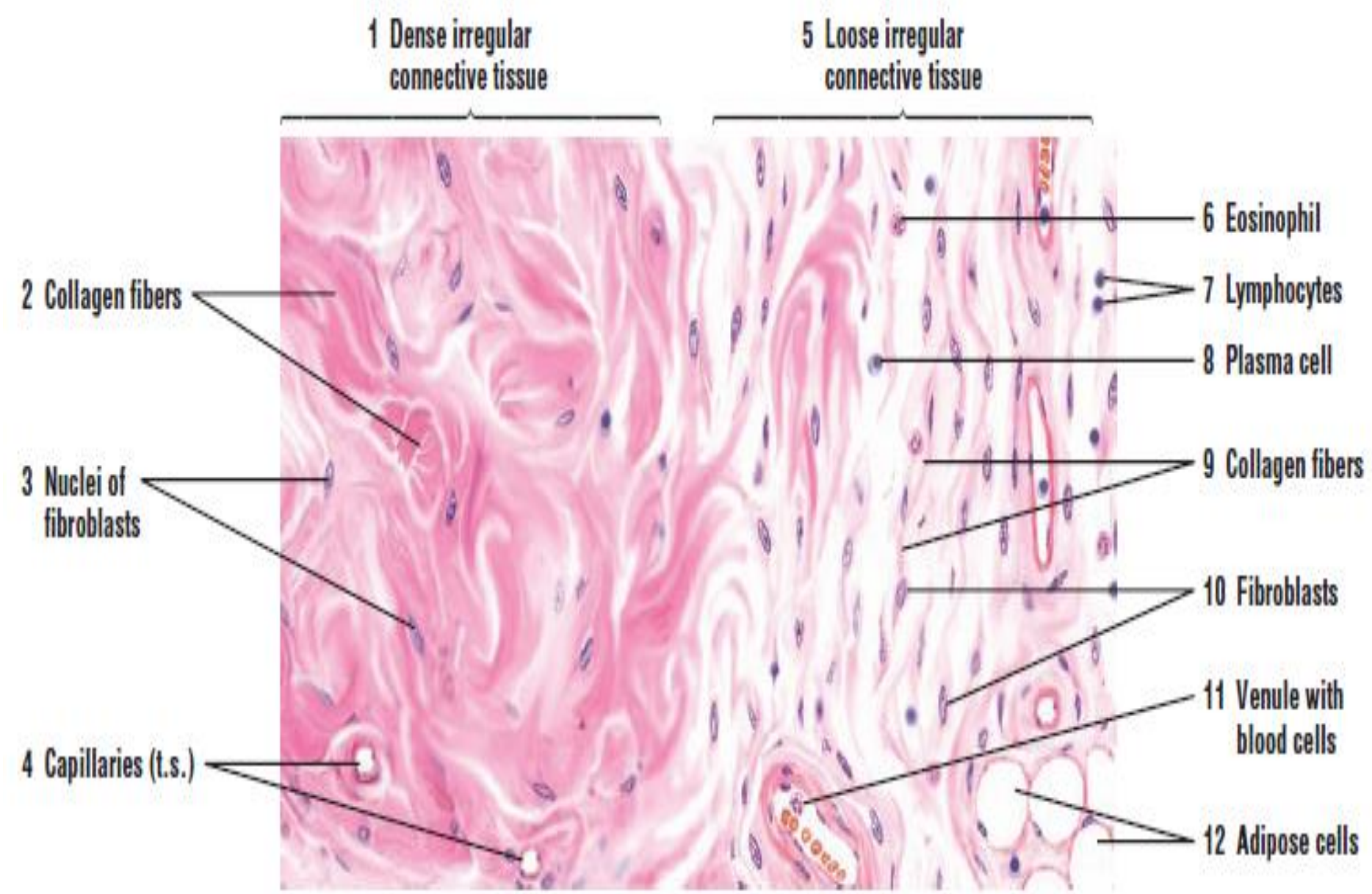
1 Dense irregular connective tissue
5 Loose irregular connective tissue
2 Collagen fibers
3 Nuclei of fibroblasts
4 Capillaries (t.s.)
6 Eosinophil
7 Lymphocytes
8 Plasma cell
9 Collagen fibers
10 Fibroblasts
11 Venule with blood cells
12 Adipose cells

Embryonic Connective Tissue

- The embryonic connective tissue resembles the mesenchyme or mucous connective tissue this is loose and irregular connective tissue. The difference in ground substance (semifluid versus jellylike).

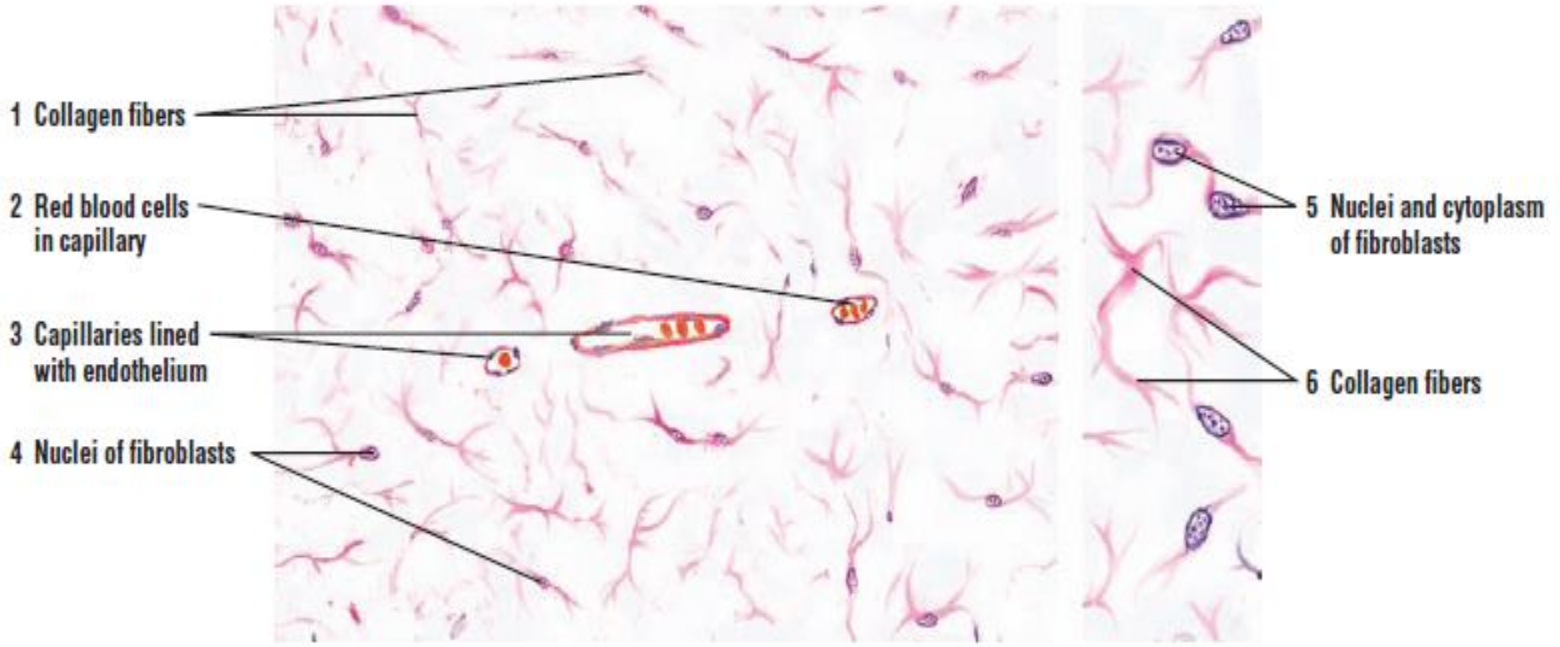

Supporting Connective Tissue

Cartilage (Hyaline- Elastic- Fibrocartilage)

Bone (compact – spongy)



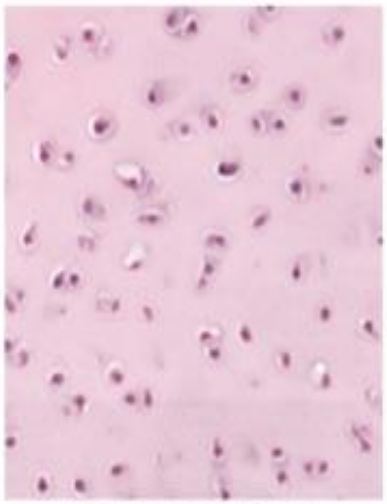

Hyaline cartilage

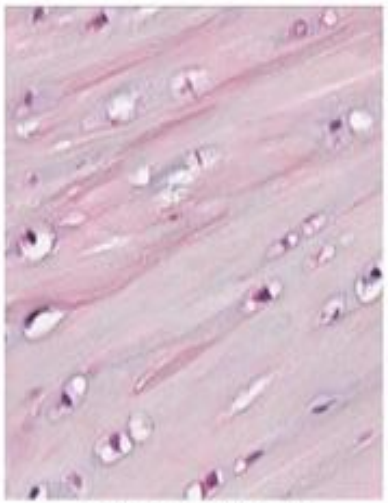

Fibrocartilage

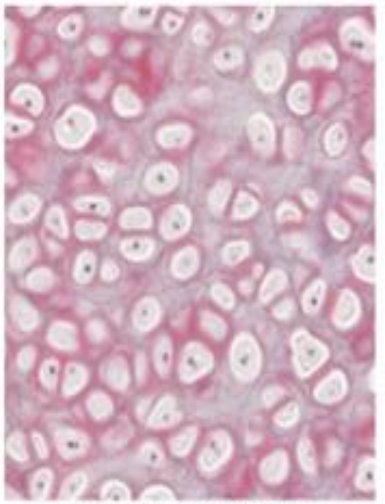

Elastic cartilage

Fluid connective tissue

- Blood and Lymph

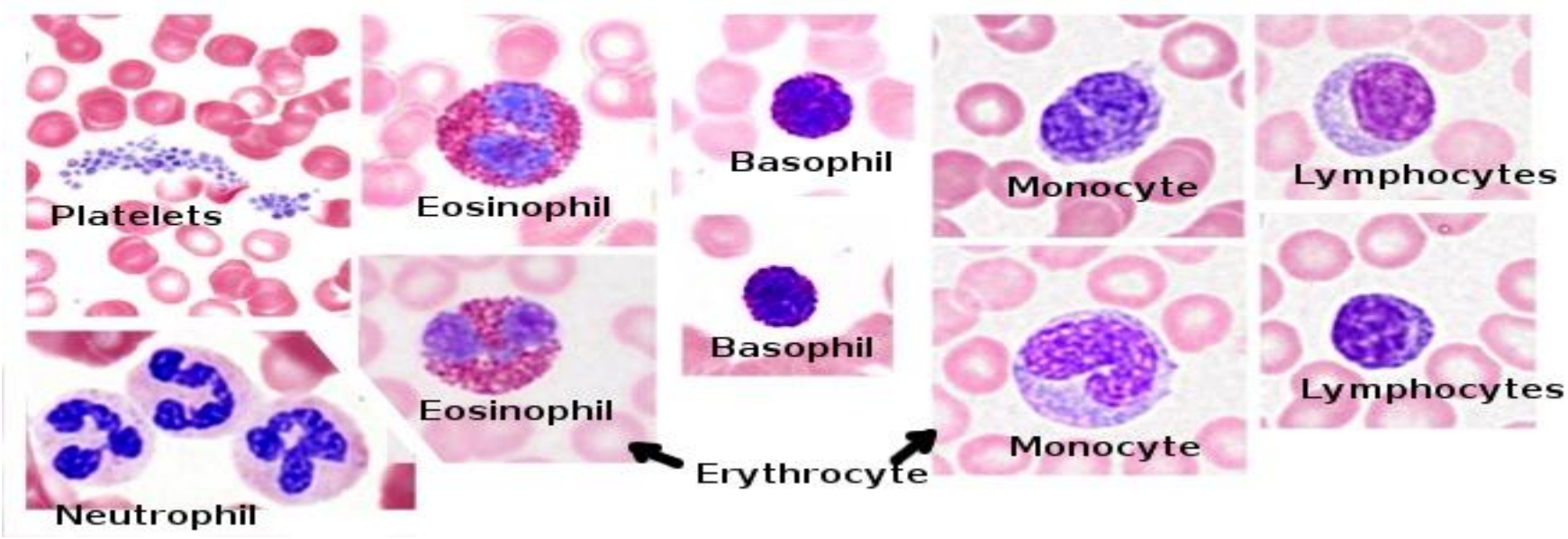

Adipose connective Tissue

- Contain large accumulations of adipose (fat) cells (4, 8) are organized into an adipose tissue.
- The two distinct types of adipose tissues in the body are **white adipose tissue** and **brown adipose tissue.** These adipose tissues represent the main sites of **lipid storage** and **metabolism** in the body.
- Adipocytes (fat cells) - unilocular or - multilocular
- Function: storage of energy - triglycerides (continuous turnover) in addition to mechanical and thermal protection

White Adipose (Fat) Cells

- Occur singly or in groups
- When adipose cells predominate, the connective tissue is adipose tissue
- Store fat (lipid) as single large droplet primarily as tryglycerides
- Appear as empty cells because lipid is dissolved during tissue preparation
- Distributed throughout body, serves as insulation, and forms fat pads for organ protection
- Highly vascularized owing to high metabolic activity
- Exhibit numerous receptors for different hormones that influence accumulation and release of lipid
- Secrete hormone leptin to increase lipid metabolism and to inhibit appetite

Brown Adipose Cells

- Cells smaller than white adipose cells; store lipid as multiple droplets
- Best developed in hibernating animals
- In newborns or animals emerging from hibernation, generates body heat
- Norepinephrine from sympathetic nervous system promotes hydrolysis of lipids

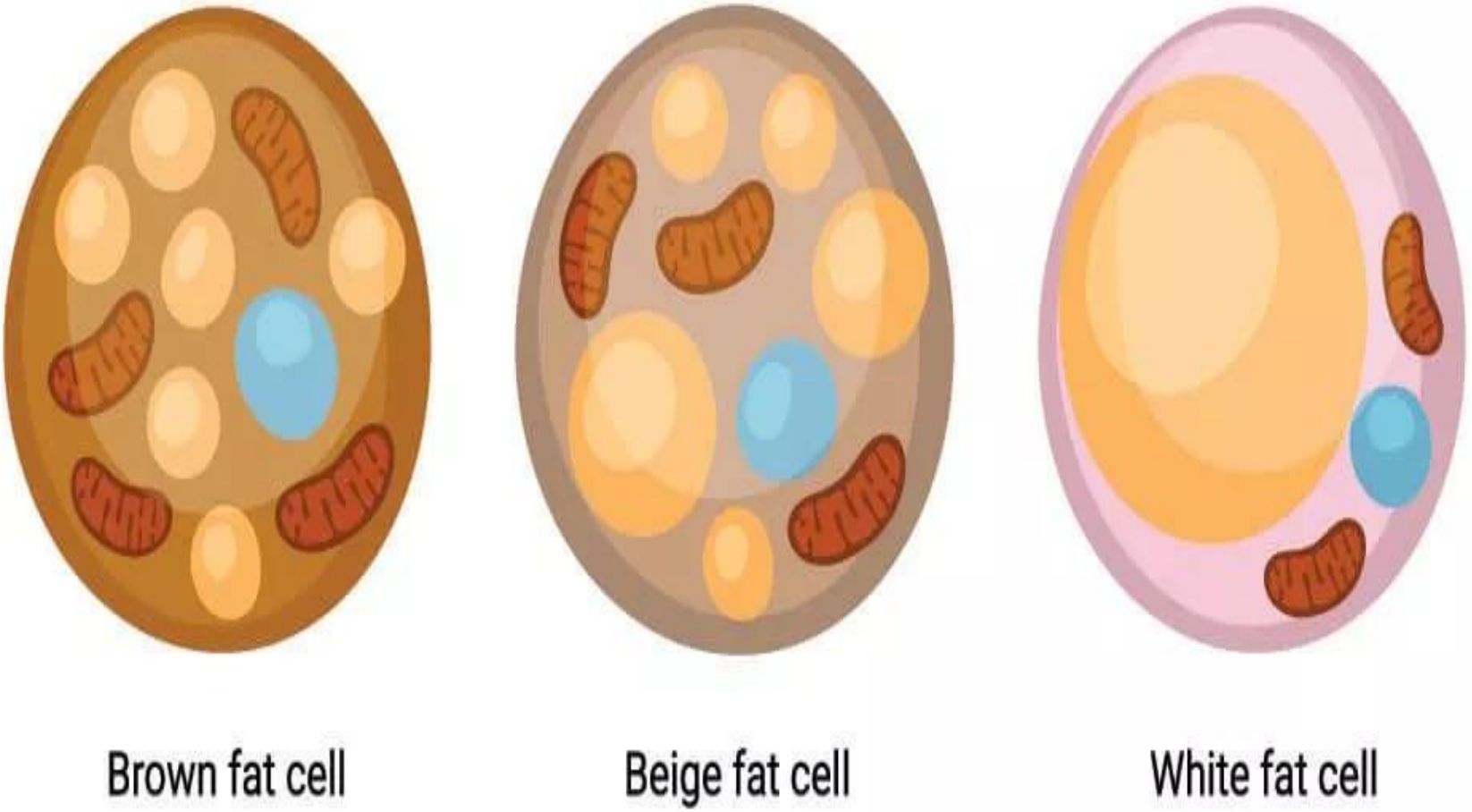
Brown fat cell
Beige fat cell
White fat cell

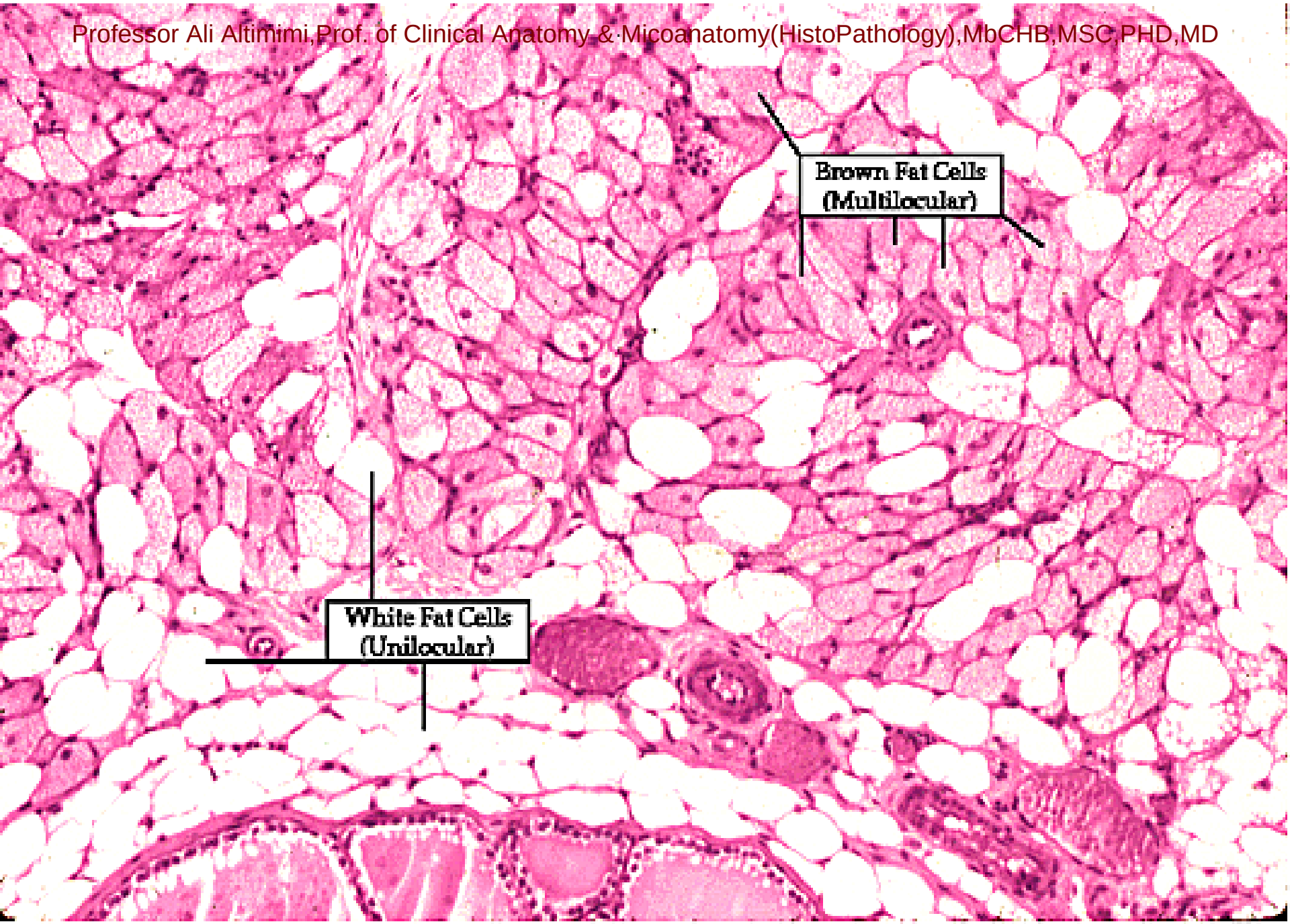
Brown Fat Cells
(Multilocular)
White Fat Cells
(Unilocular)

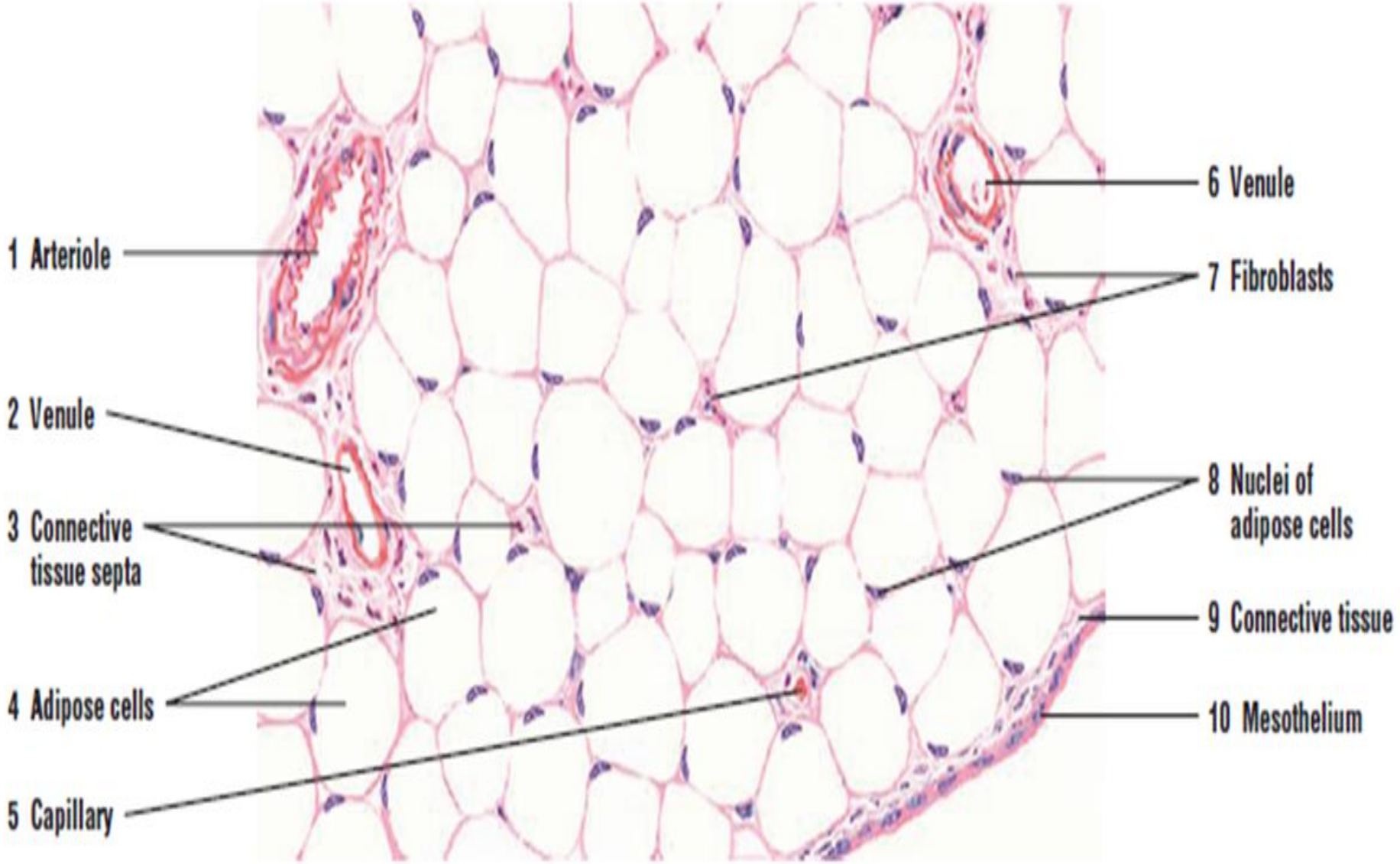
1 Arteriole
2 Venule
3 Connective tissue septa
4 Adipose cells
5 Capillary
6 Venule
7 Fibroblasts
8 Nuclei of adipose cells
9 Connective tissue
10 Mesothelium