Professor Ali Altimimi,Prof. of Clinical Anatomy , Micoanatomy & HistoPathology MbCHB, MSC, PHD, MD. Royal College England

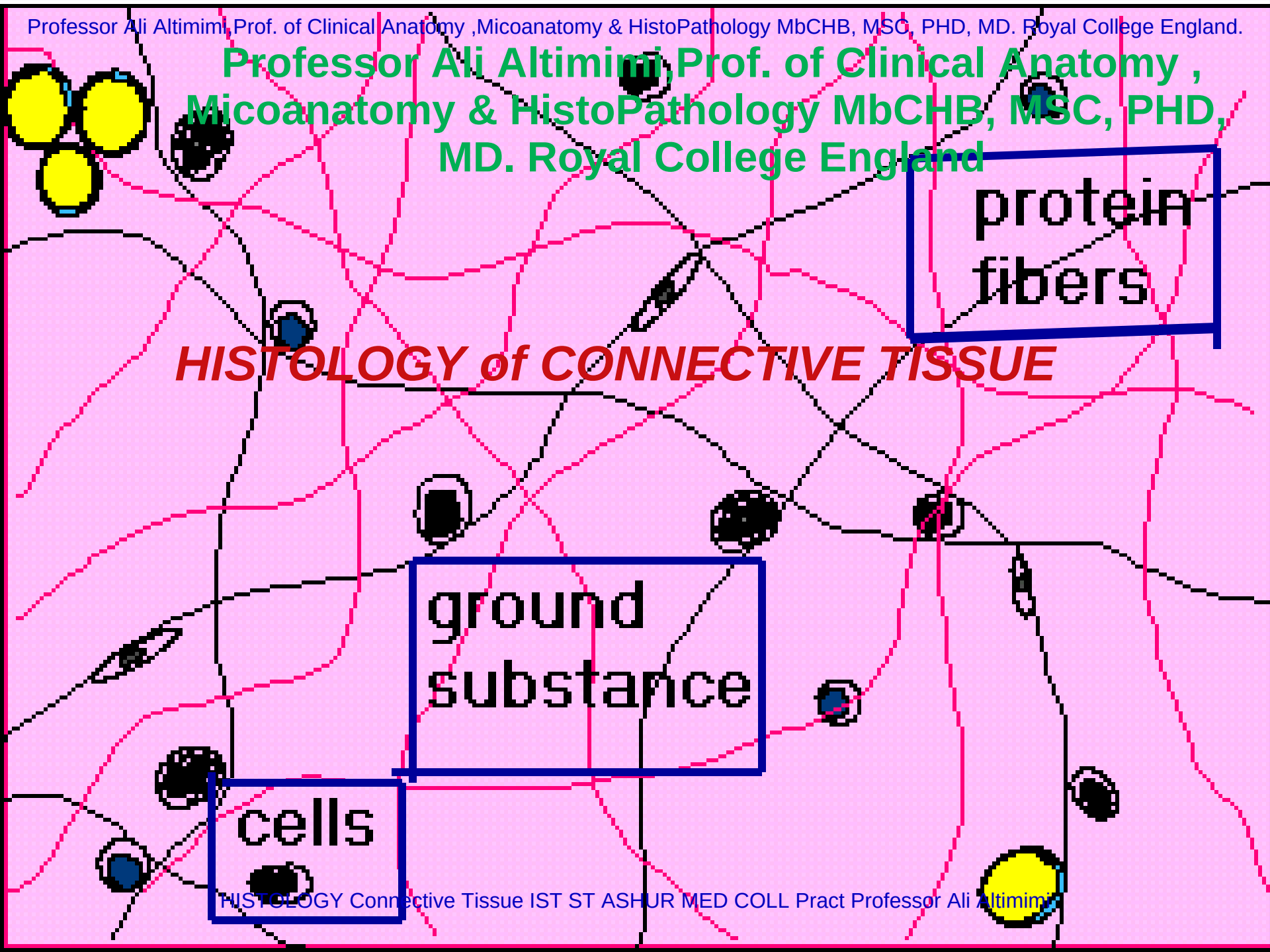

HISTOLOGY of CONNECTIVE TISSUE

HISTOLOGY of CONNECTIVE TISSUE

Professor Ali Altimimi,Prof. of Clinical Anatomy & Micoanatomy

INTRODUCTION

Connective tissue is one which gives structural and metabolic support to the organ and other tissue of the body

CONNECTIVE TISSUE

- ***GENERAL FEATURES***

- **1. Cells**
  2. Matrix
  -Fibers
  -Ground substance

CONNECTIVE TISSUE

- ***Cells***
- ***Fibers***
- ***Ground substance***

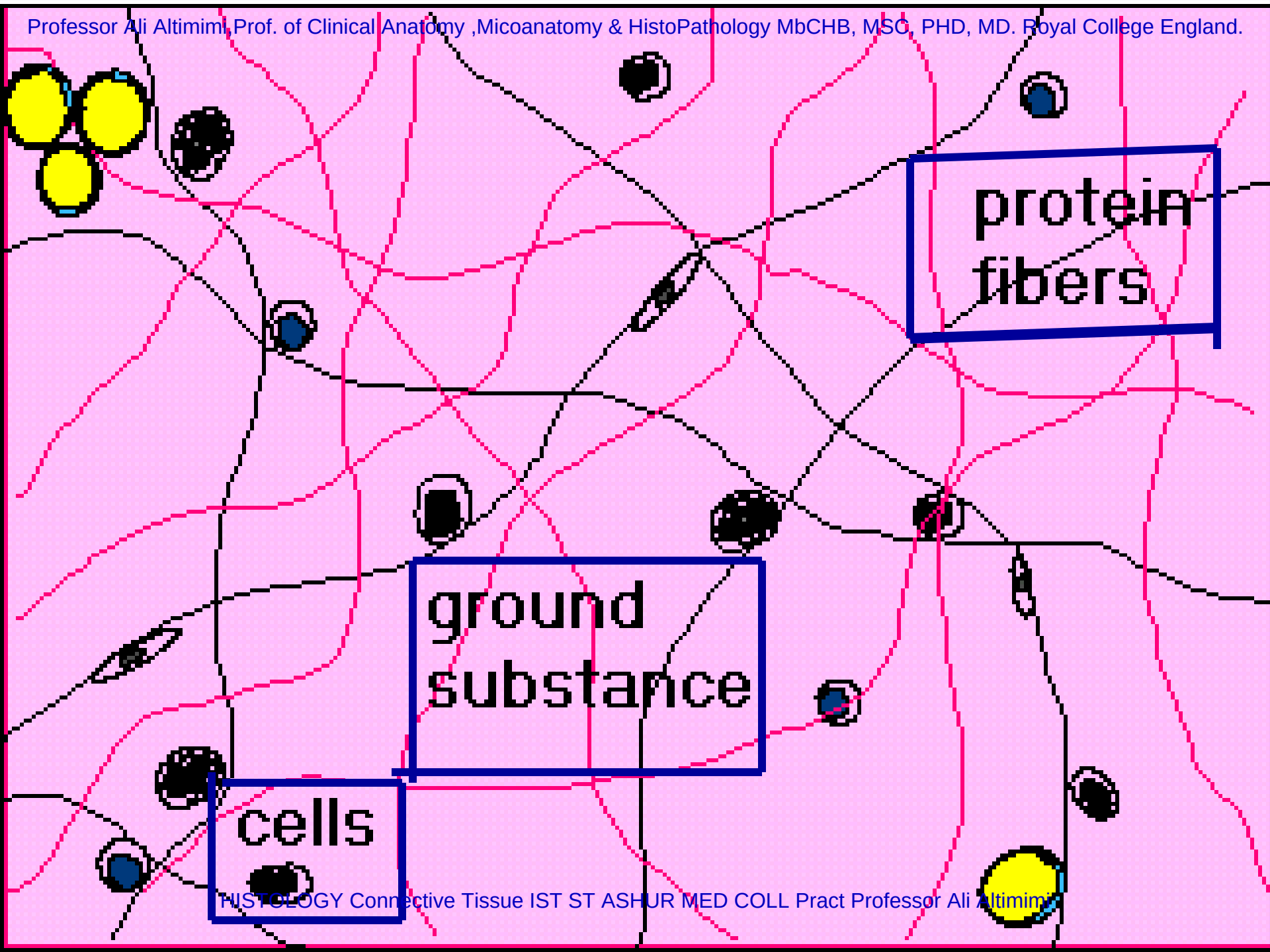
protein fibers
ground substance
cells

Cells of Connective Tissue

- **A. Fixed cells (intrinsic cells)**
  1. **Fibroblast**
  2. **Mesenchymal cells**
  3 **Macrophage(histiocyte)**
  4. **Adipocyte**
- **B. Free cells (extrinsic cells)**
  5. **Mast cell**
  6. **Plasma cells**
  7. **Leucocytes**

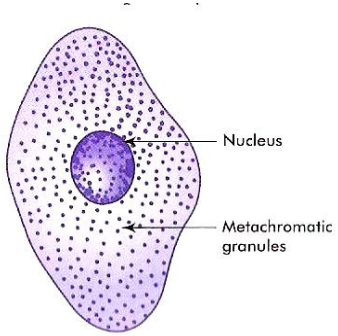

Fig. 4.6 Mast cell

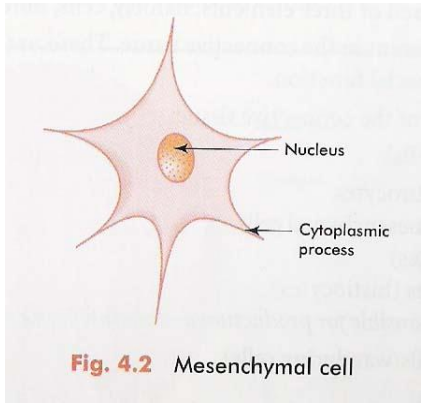

Fig. 4.2 Mesenchymal cell

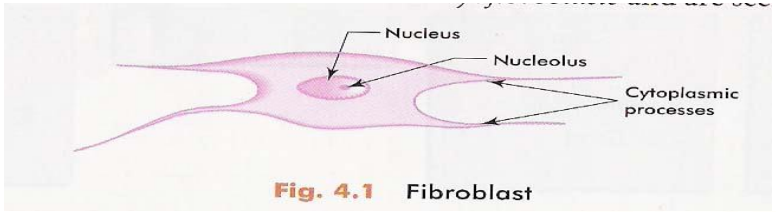

Fig. 4.1 Fibroblast

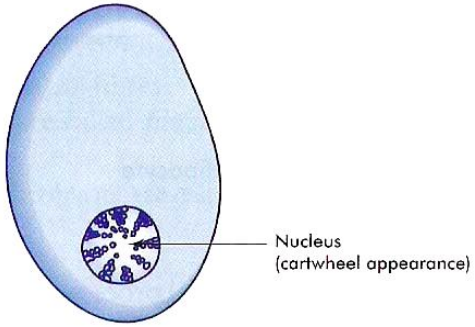

Fig. 4.5 Plasma cell

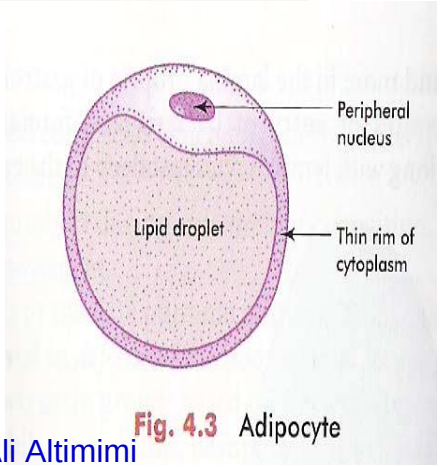

Fig. 4.3 Adipocyte

Fibroblast

- Most commonly seen
- Fusiform with slender cytoplasmic process
- Large oval nucleus,
- Responsible for production of fiber production
- Old cells are fibrocyte,
- Contractile Cells are myofibroblast

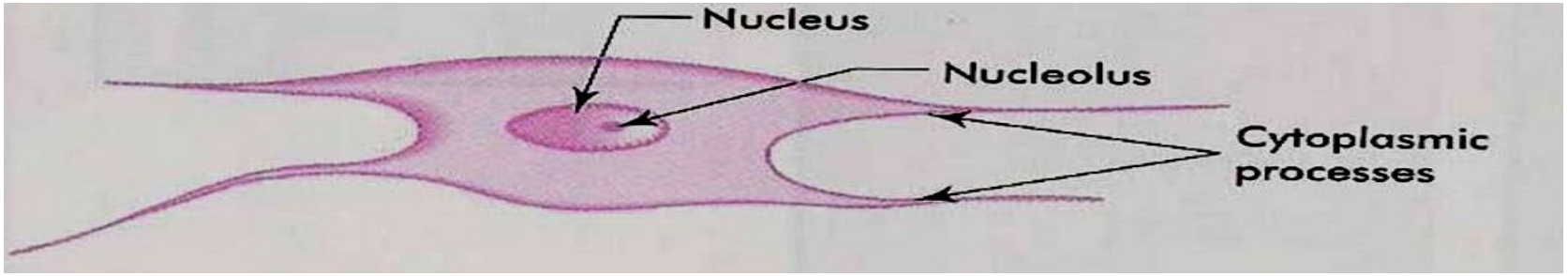



Fibroblast

Mesenchymal cells

- **Undifferentiated cells**
- **Stellate in shape,**
- **Cytoplasmic process,**
- **Pluripotenant cell**
- **Near blood vessels as Advential cell**

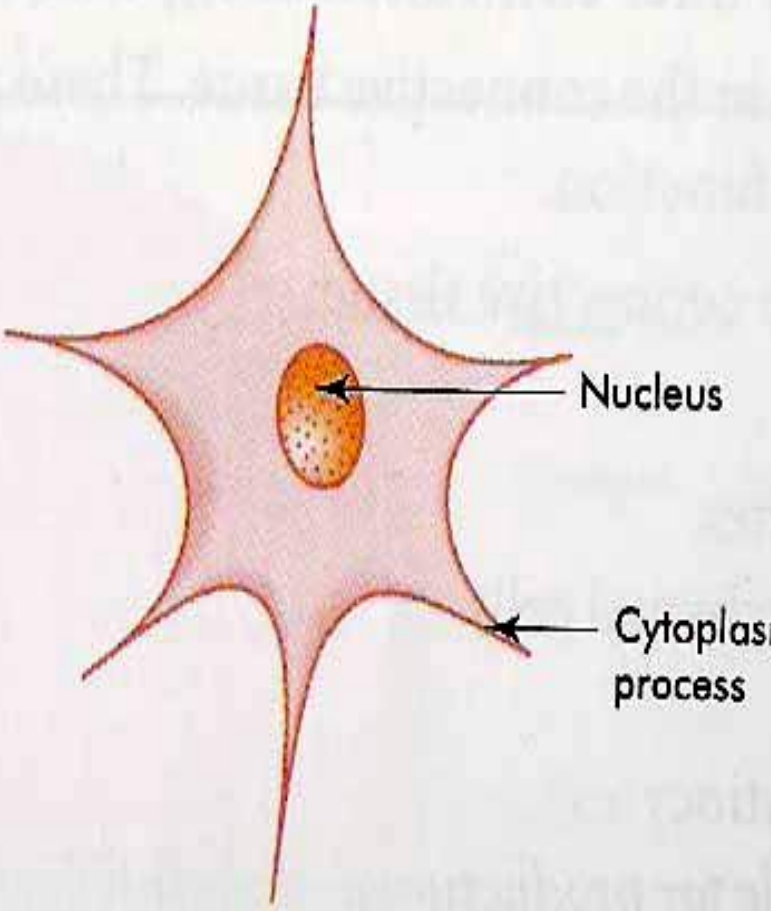

Fig. 4.2 Mesenchymal cell

Macrophages (Histiocytes)

- Free and Fixed type,
- Fixed Cells-
- Irregular Shape
- filopodia process,
- Dark indented eccentric nucleus,
- Derived from monocyte
- Involved in phagocytosis
- Fused to form giant cell.
- Free Cells- rounded, no filopodia

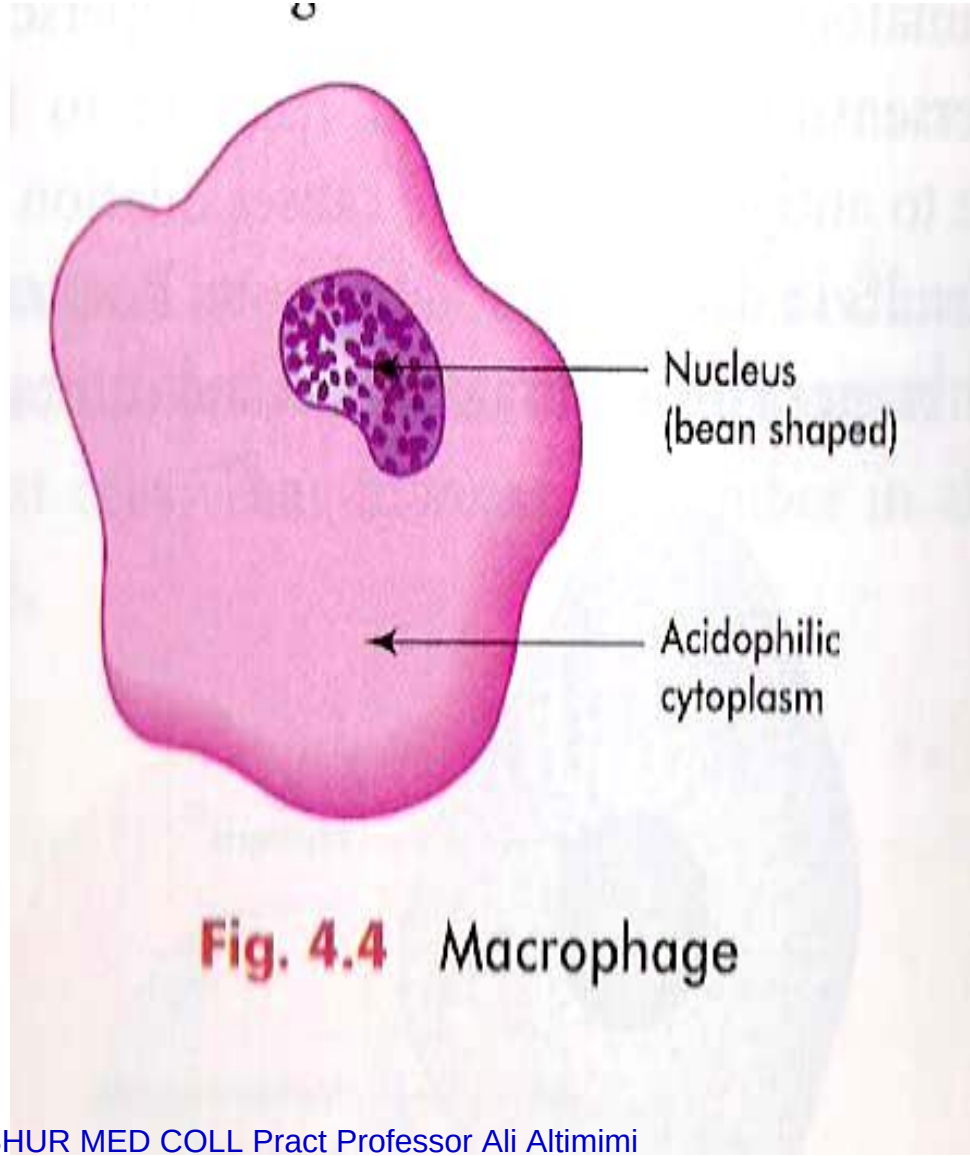

Fig. 4.4 Macrophage

Adipocytes

- **Store lipid**
- **Appears as empty space**
- **Incapable to division**
- **Aggregate in adipose tissue with reticular fibre**

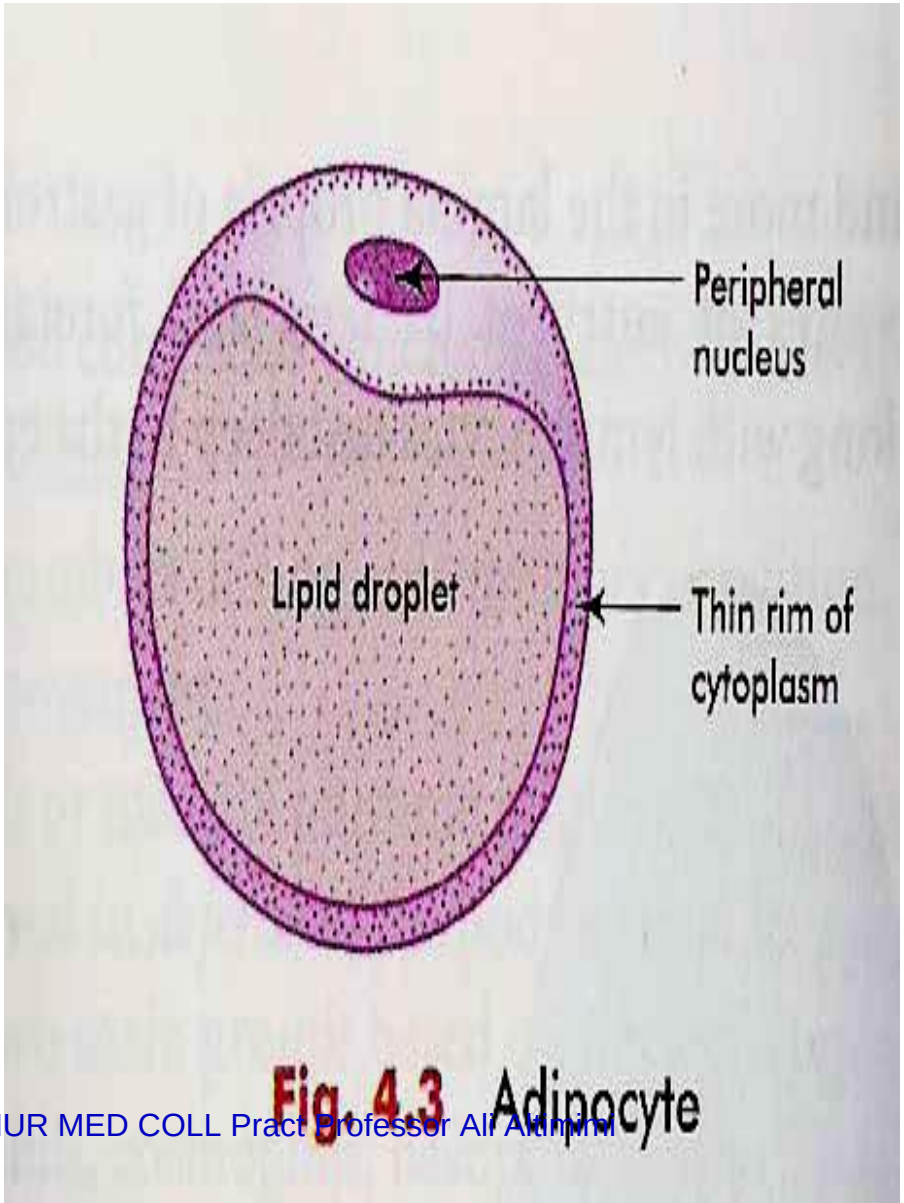

Plasma cells

- Oval **basophilic** cells,
- Eccentric nucleus
- **Heterochromatin** as **cartwheel nucleus**
- Derived from **B lymphocyte**
- Produces **immunoglobulin**
- Antibody collected as **Russell body**.
- Present in respiratory tract and gastrointestinal tract

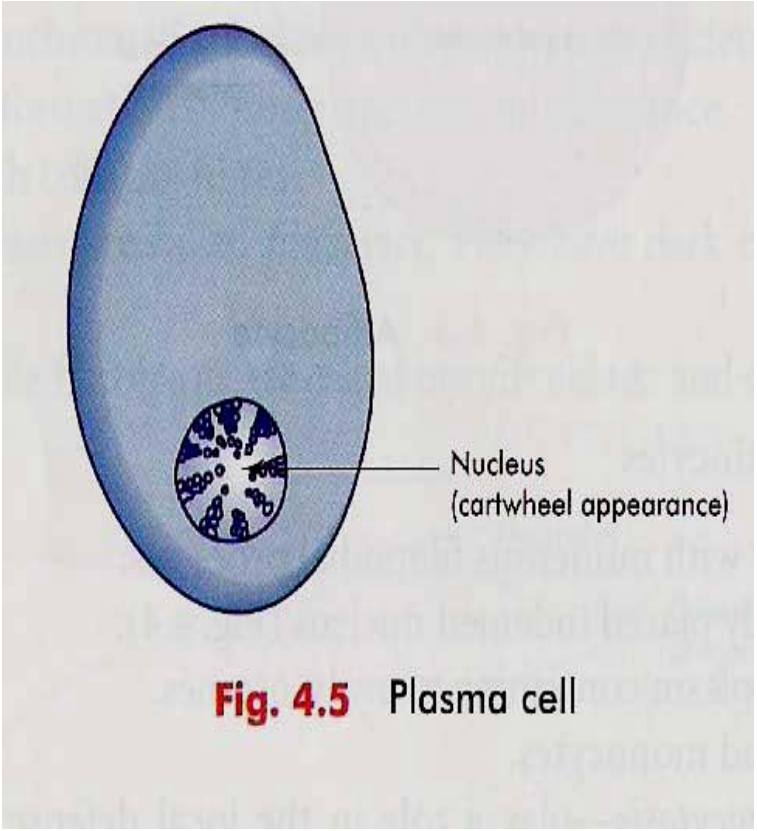

Fig. 4.5 Plasma cell

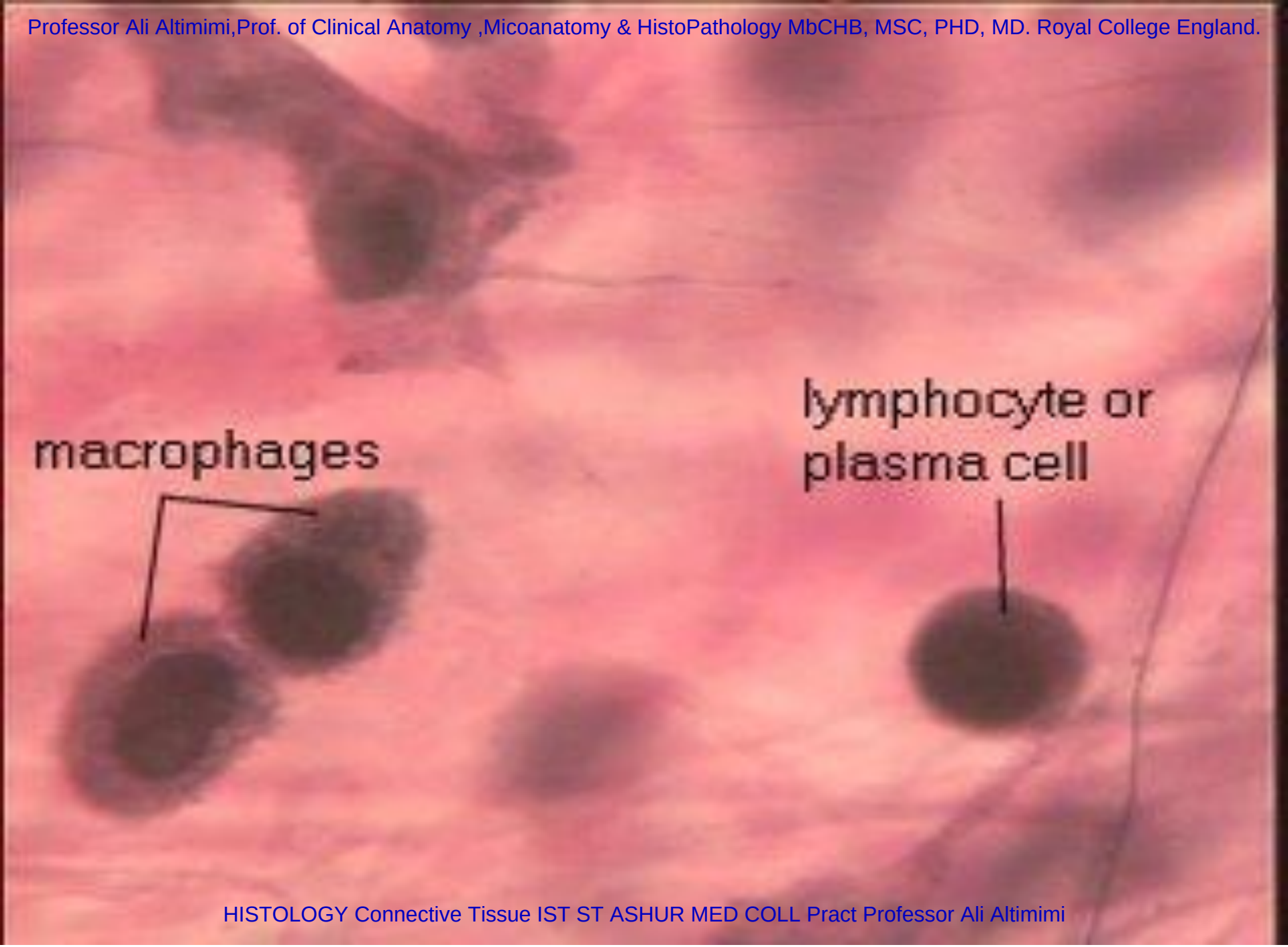
macrophages
lymphocyte or
plasma cell

Mast cell

- Round or Fusiform Shaped
- Mostly along blood vessels,
- Metachromatic granules in cytoplasm,
- Granules have Histamine or Heparin,
- Look like basophil, so called as connective tissue basophil .
- ***Connective tissue mast cell*** –heparin granule, present in skin.
- ***Mucosal mast cell*** –small, present in lamina propria of git and respiratory tract

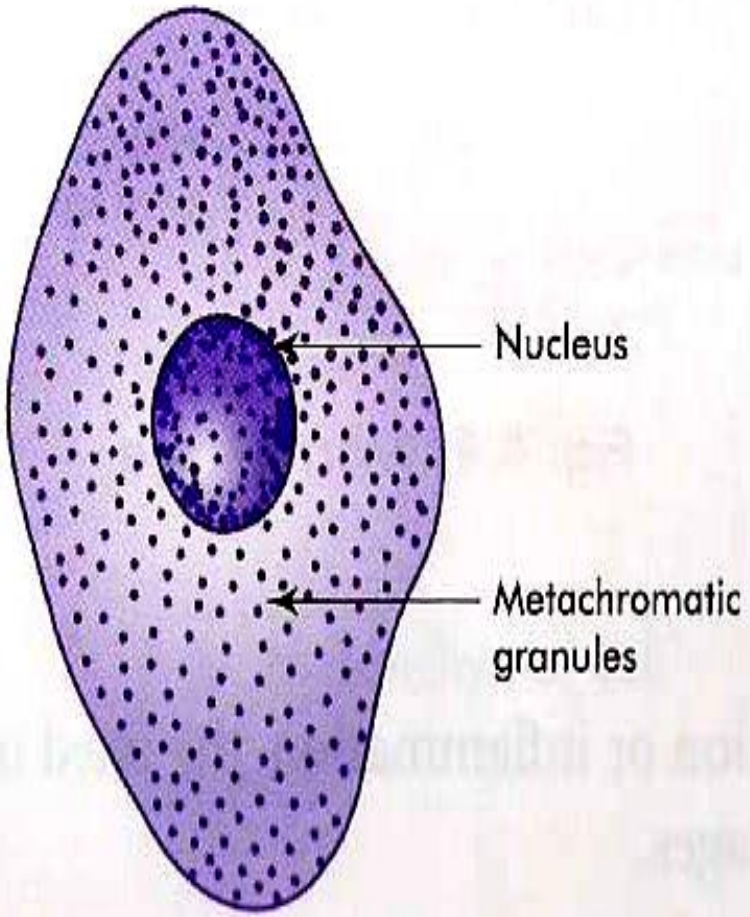

Fig. 4.6 Mast cell


mast cell

Leucocytes-

. **Granulocytes-**
Neutrophils,
Esinophils,
Basophiles

. **Agranulocytes**
Lymphocytes,
Monocytes

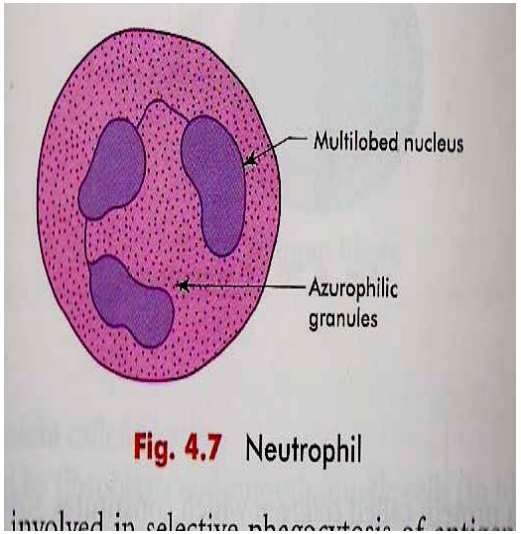

Fig. 4.7 Neutrophil

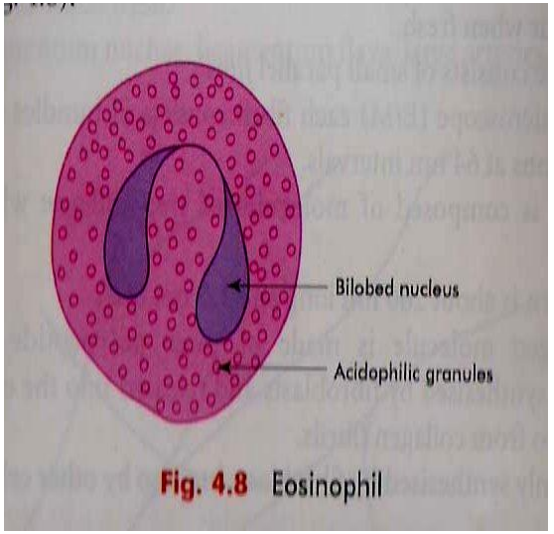

Fig. 4.8 Eosinophil

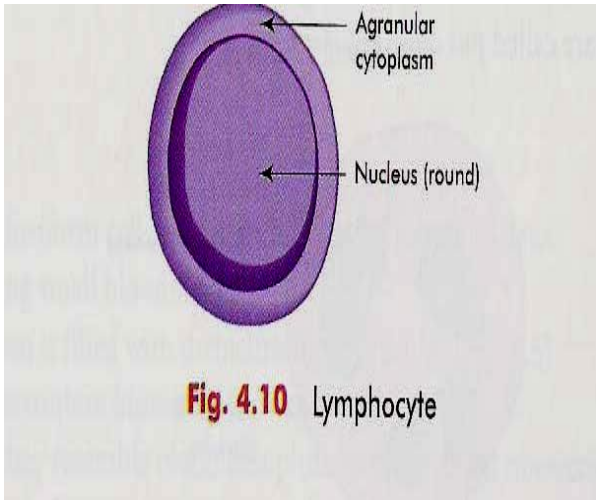

Fig. 4.10 Lymphocyte

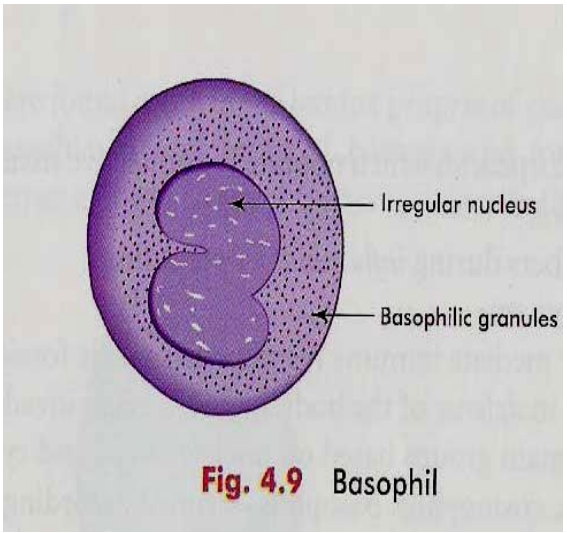

Fig. 4.9 Basophil

Leucocytes

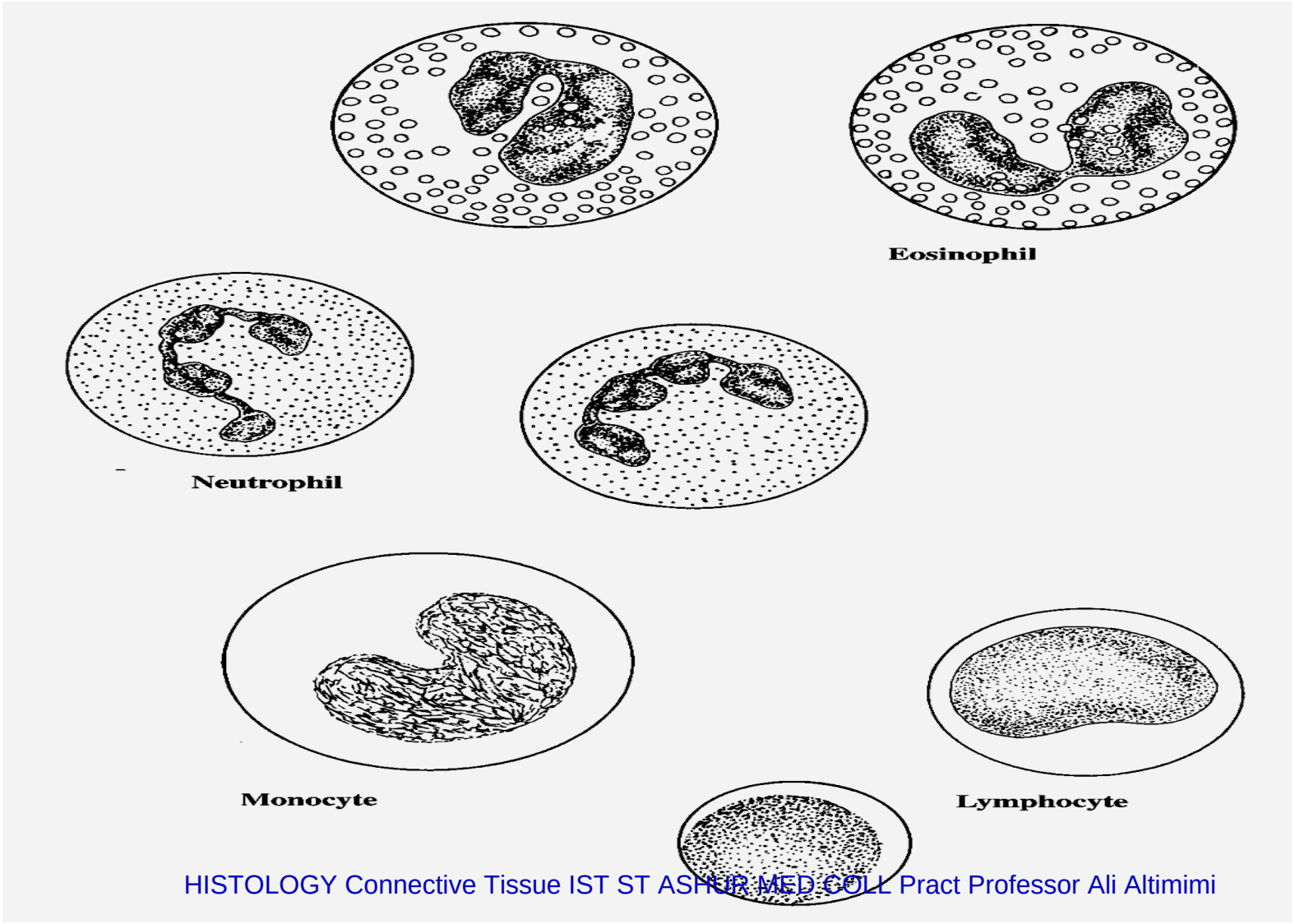

Collagen Fibre

- ***White*** **colour when fresh**
- **Do not branch,**
- **present in bundle**
- ***Collagen protein*** **forms Fibres**
- **Fibres composed of fibril than microfibrils**
- **Micro fibrils made up *tropocollagen***
- **Synthesized by *fibroblast***

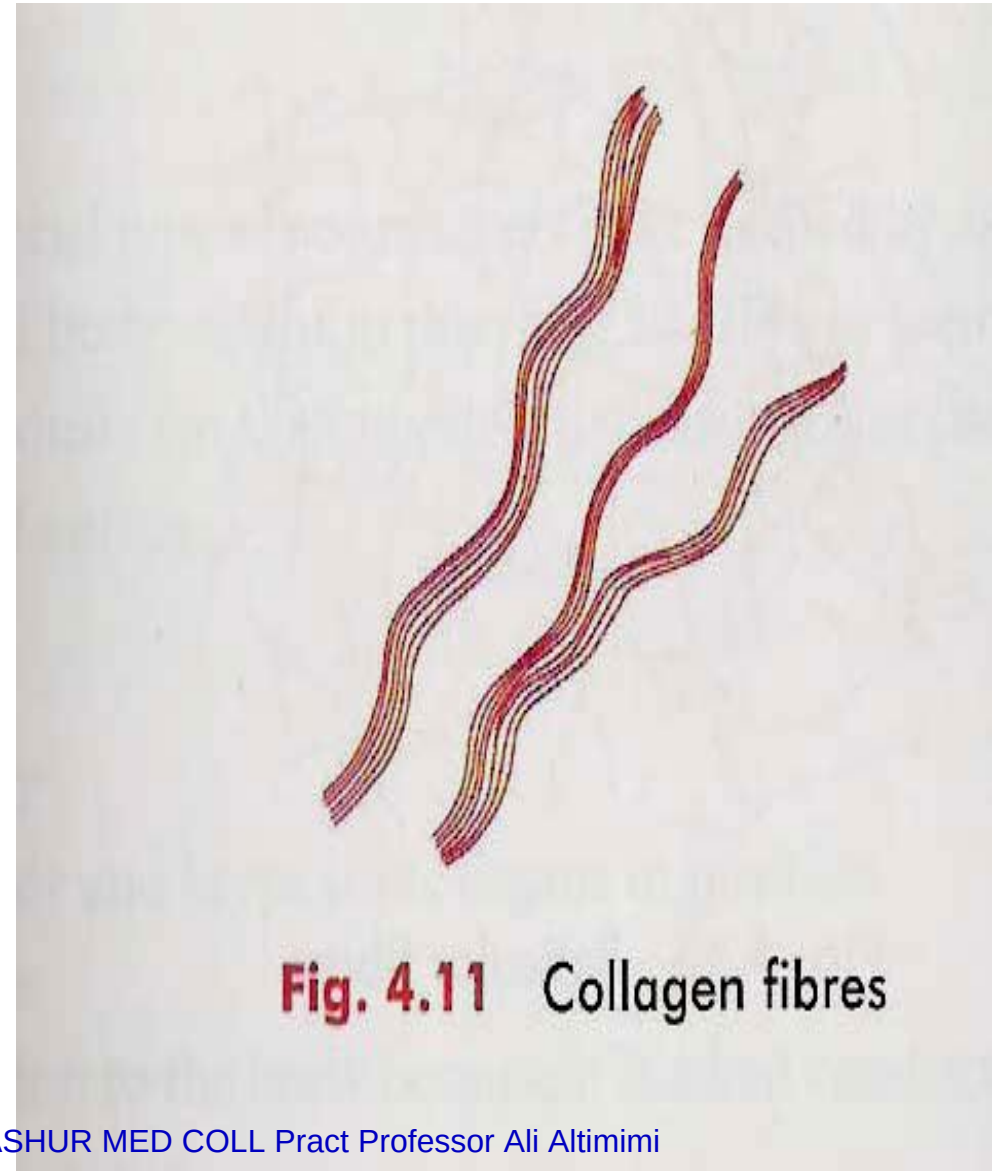

Fig. 4.11 Collagen fibres

Types

- **Type1-bones tendons**
- **Type2-cartilage**
- **Type3-reticular fibre**
- **Type4-basement membrane**
- **Type5-blood vessels**

Synthesis

- **Amino acids**



- **Procollagen**



- **Three chains**



- **Tropocollagen**



- **Collagen**

Elastic fibre

- Composed of elastin protein
- Singly present
- Branched and anastomose
- Can be stretched
- Synthesized by fibroblast
- Found in ligamentum flava, large arteries



Reticular fibre

- **Immature collagen fibre (type -3)**
- **Framework of lymphoid tissue**
- **Stained by silver salts (argyrophellic)**



Fig. 4.13 Reticular fibres

Ground substance

- **Polysacchrides - hexurate or galectose**
- **Carbohydrate protein complex (proteoglycanes)-**
- **1- *mucopolysacchride* (glucosaminoglycanes)**
- **NonSulphates-chondotine and hyluronic acid**
- **Sulphates - chondotinesulphate, heparitine sulphate, keratohyline**
- **2- *glycoprotienes*- fibronectine(dermis),chondronectine (cartilage), laminin (b.m)**
- **water & minerals**

Classification

Connective tissue

1.Ordinary connective tissue- Loose connective tissue

-Dense connective tissue

Regular

Irregular

2.connective tissue with special properties

Adipose tissue

Mucoid tissue

Reticular tissue

Pigmented tissue

3.Scleral connective tissue -Bone

-Cartilage

4.Lymphoid and hea ive tissue


reticular fibers
fixed macrophage
plasma cell
adipocytes (fat cells)
ground substance
blood vessel
mast cell
elastic fibers
collagen fibers
fibroblast
macrophage
mesenchymal cell
lymphocyte

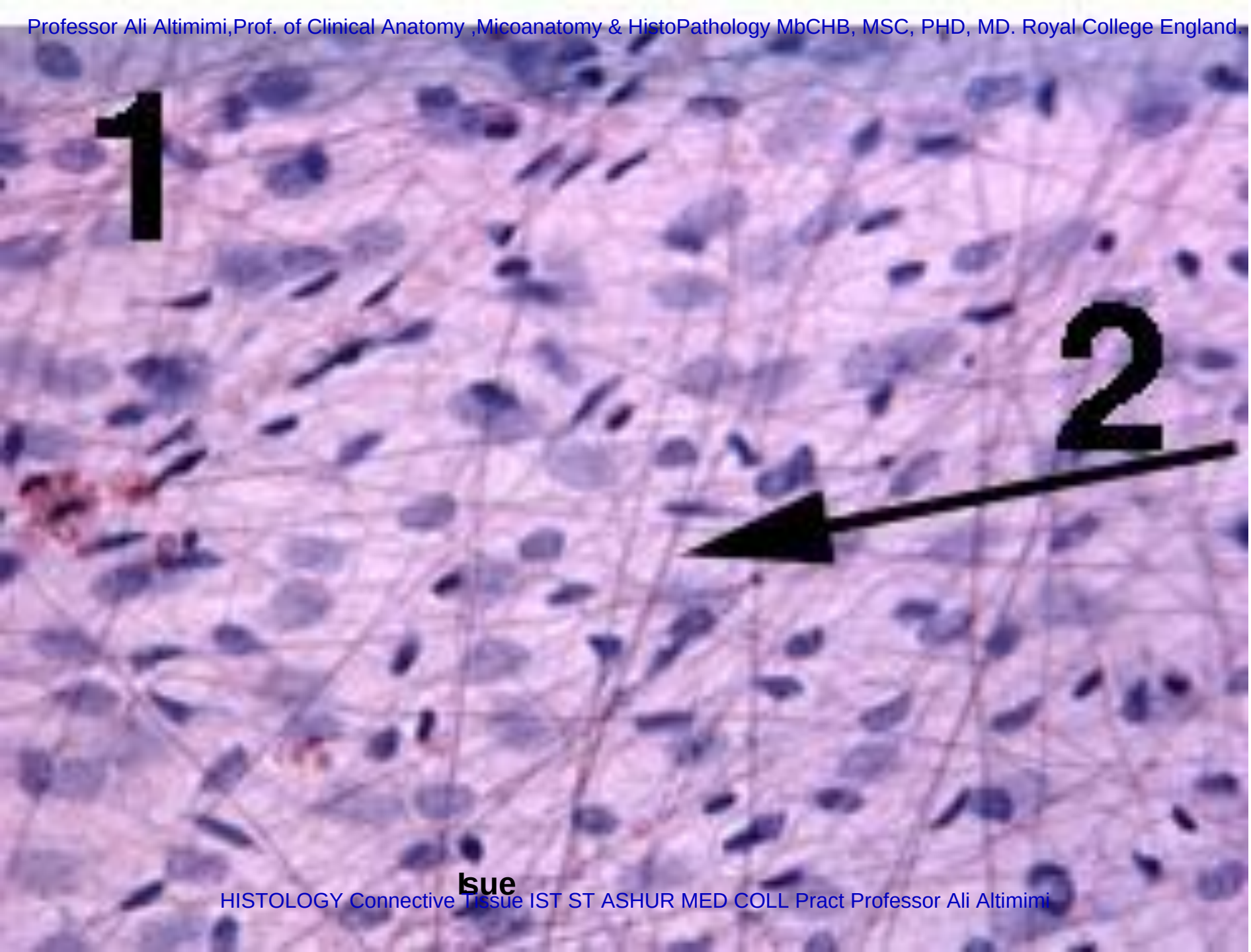

Isue

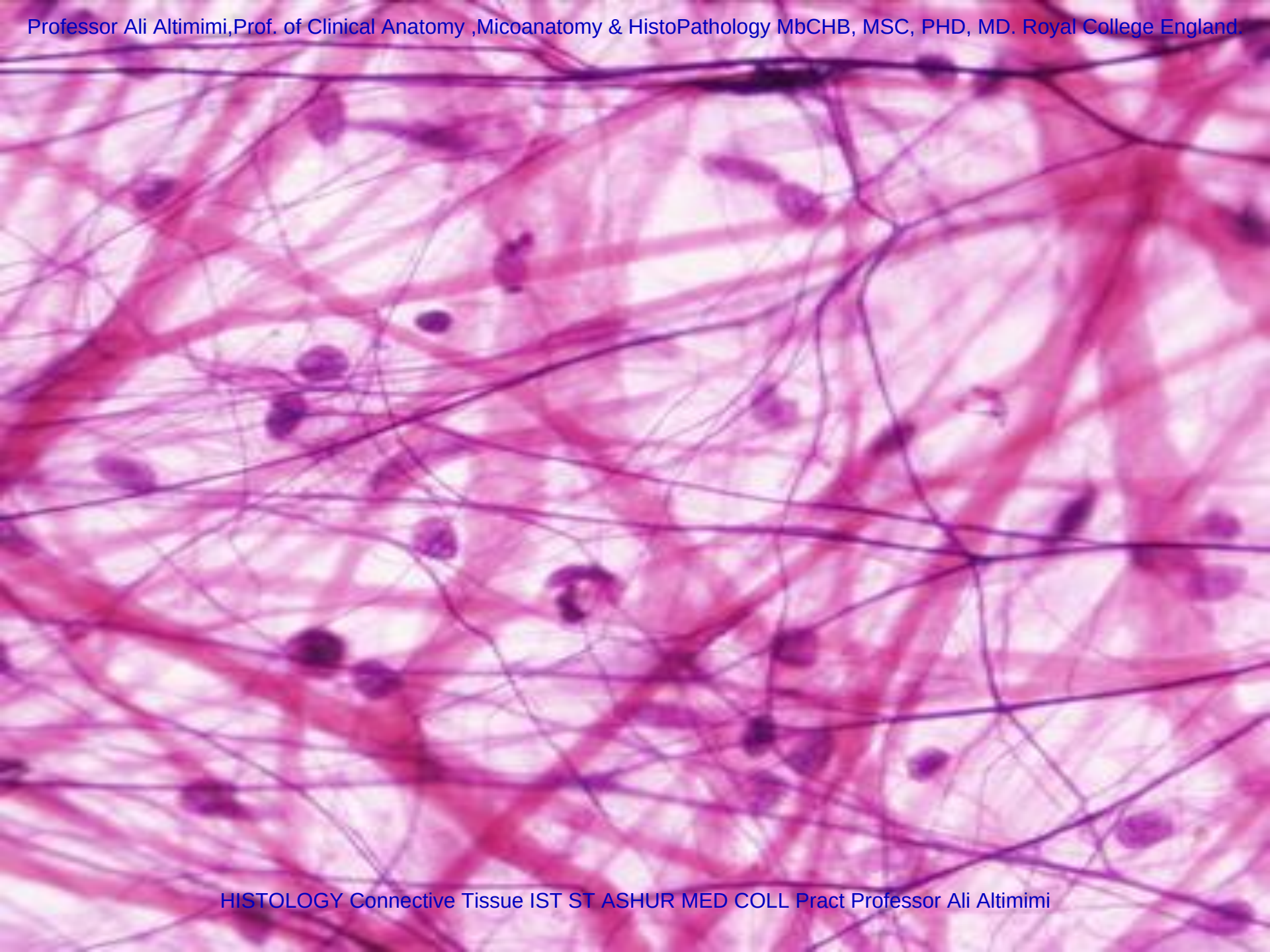

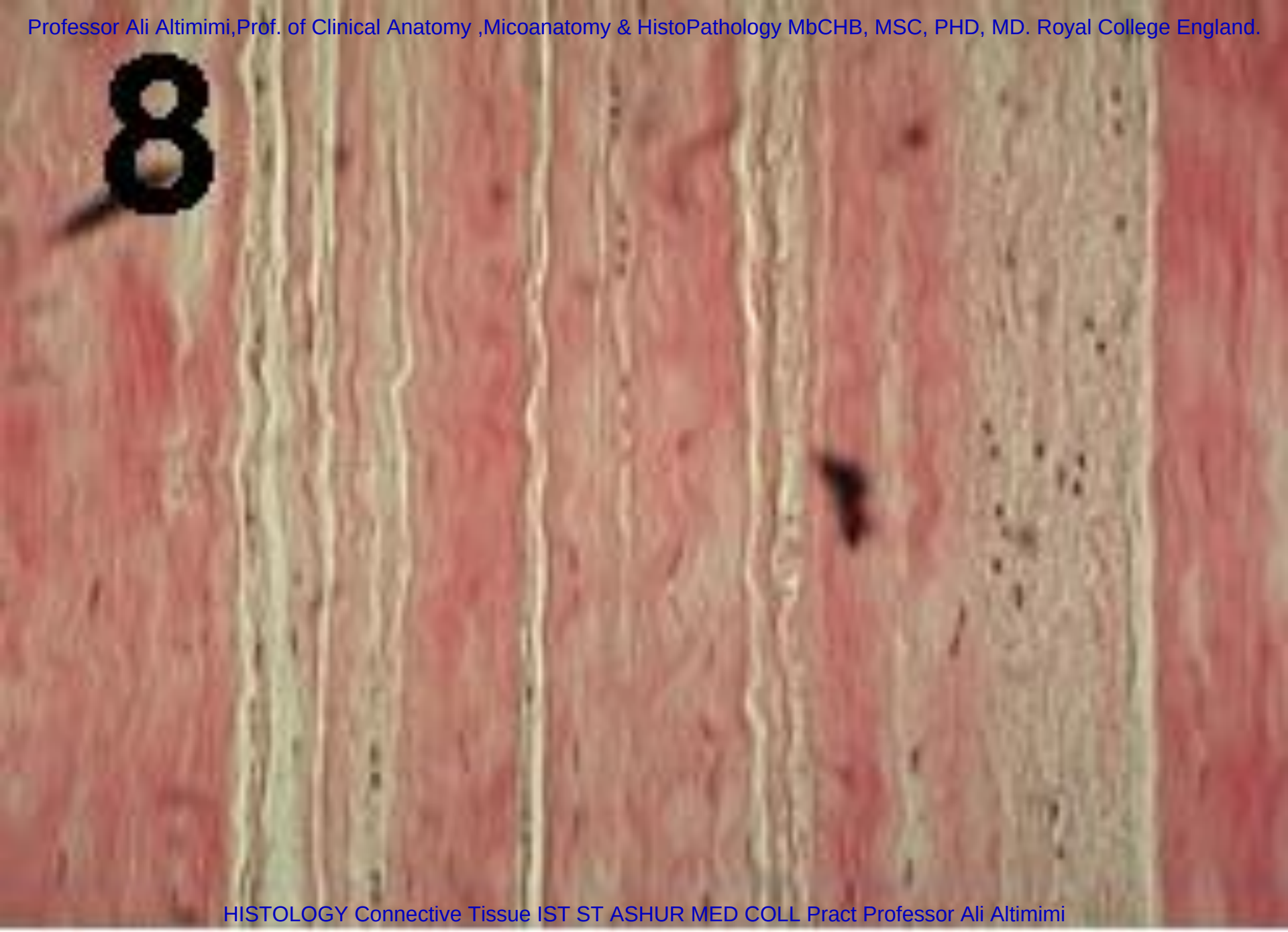
8

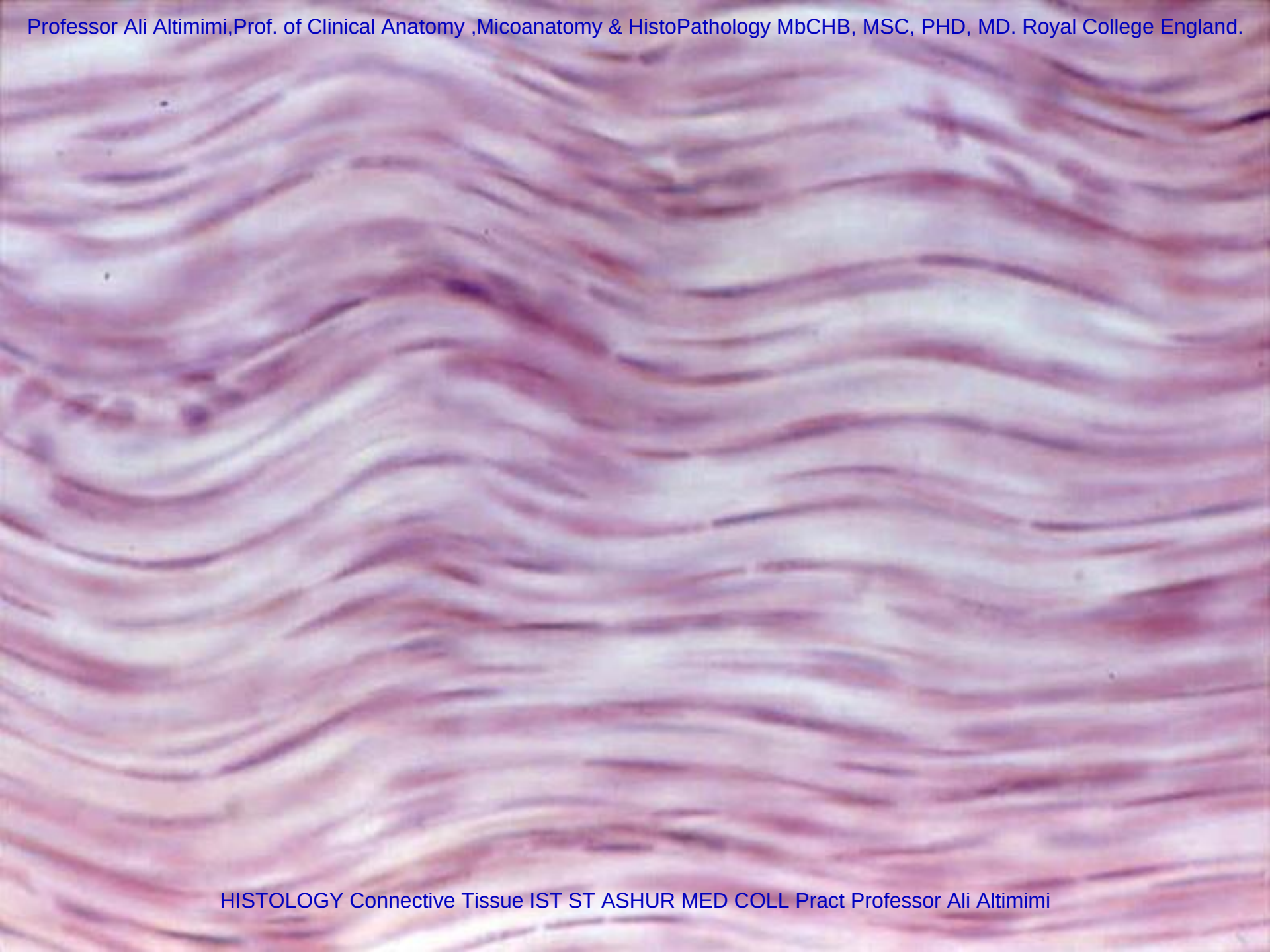

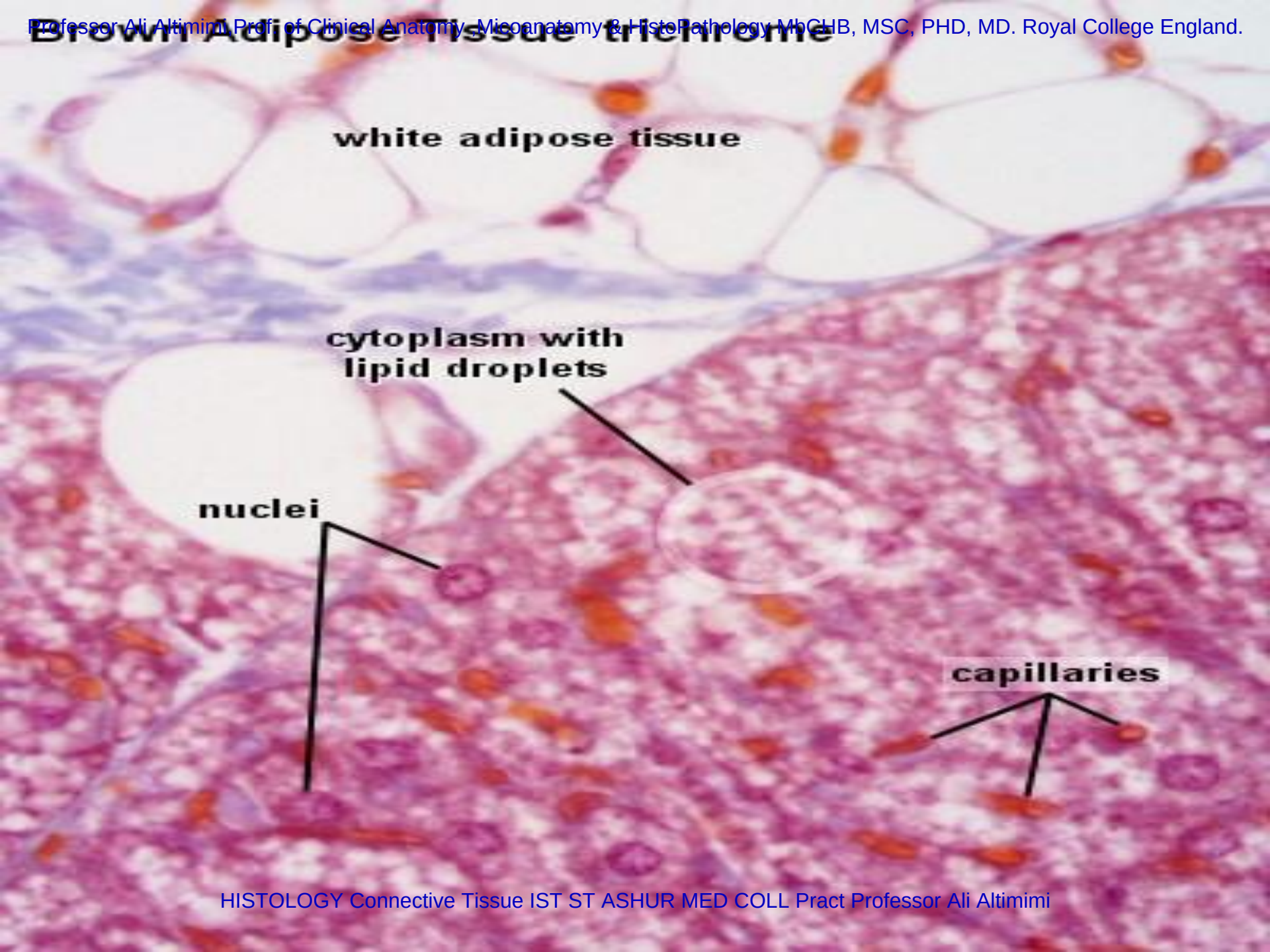
Brown Adipose Tissue trichrome
white adipose tissue
cytoplasm with
lipid droplets
nuclei
capillaries

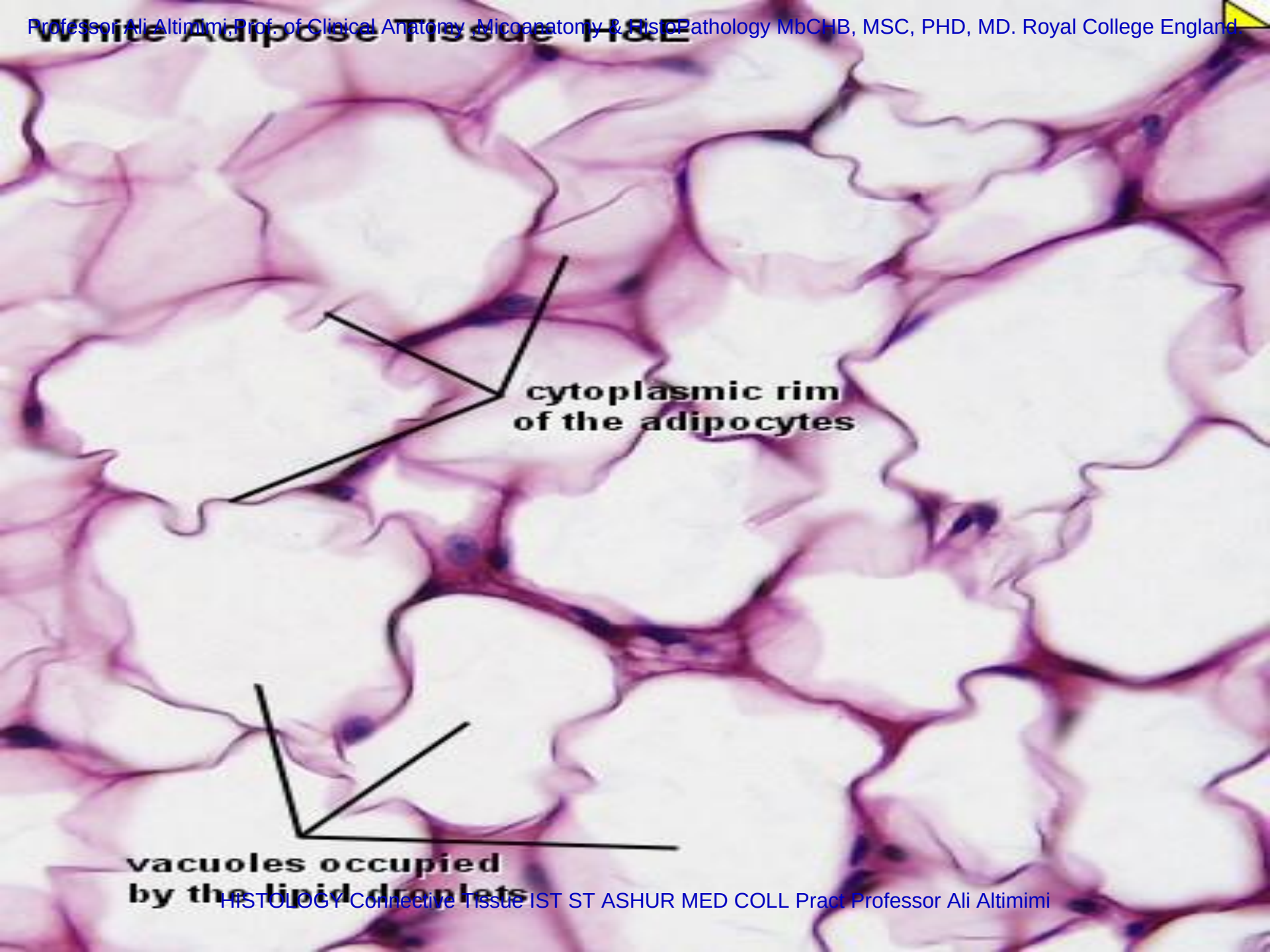
White Adipose Tissue H&E
cytoplasmic rim
of the adipocytes
vacuoles occupied
by the lipid droplets

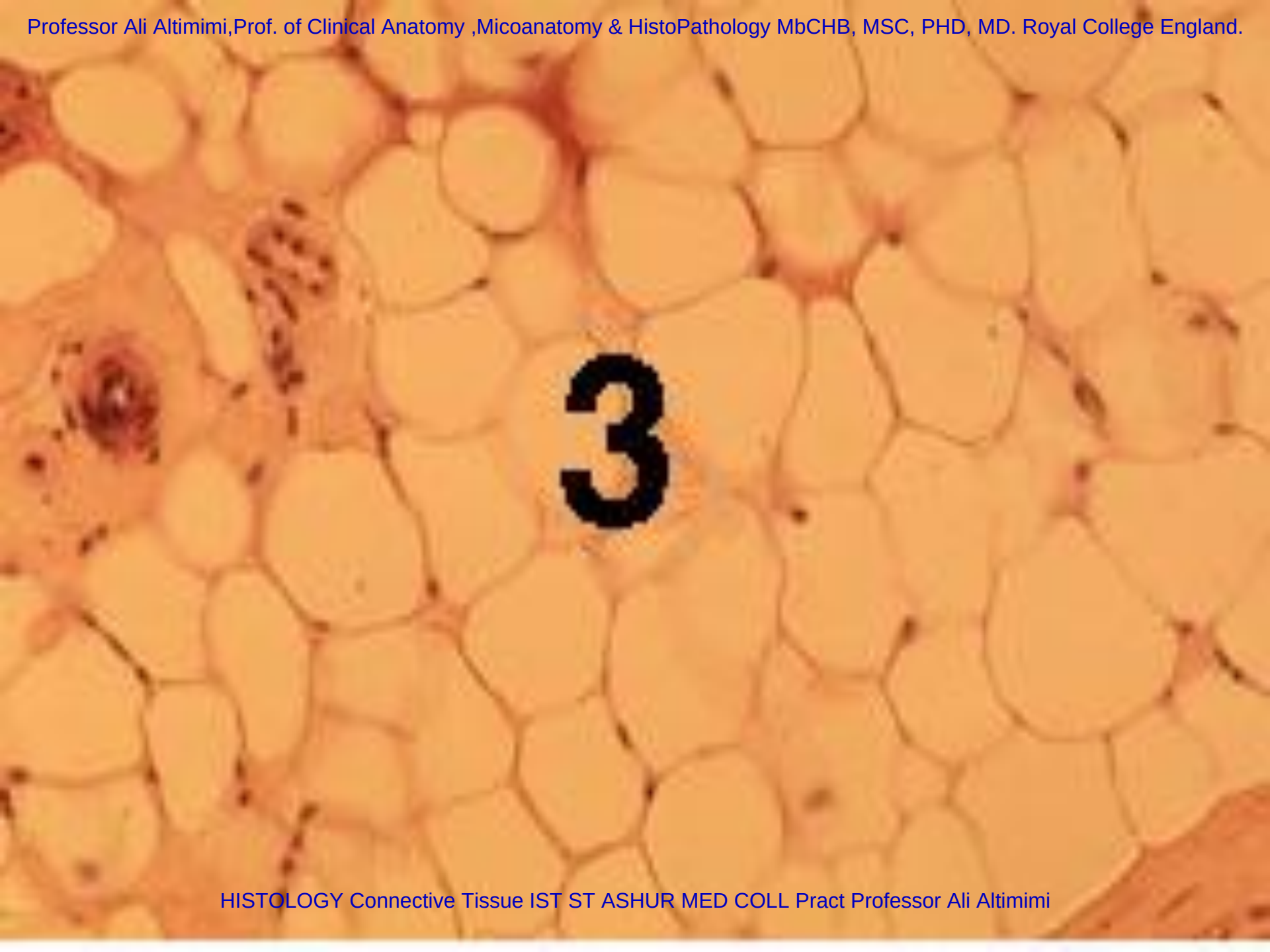
3

Umbilical Cord H&E

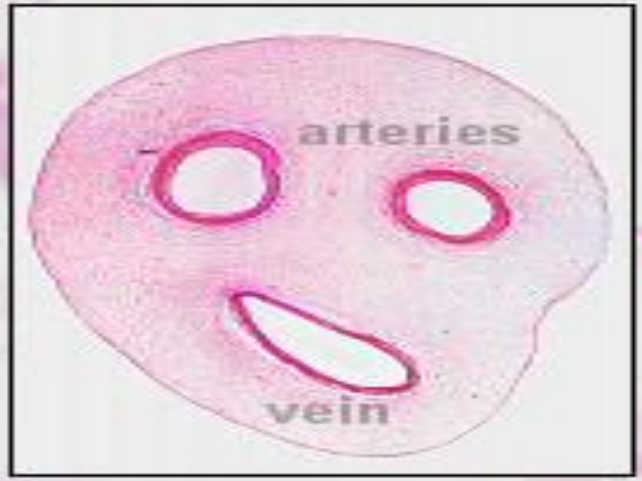

cell process

mesenchymal cells

collagen fibres

Foetal Kidney H&E

