Nasal Cavity

Professor Ali Altimimi,Prof. of clinical & Micro Anatomy, MbCHB, MSC,PHD,MD.Royal College England.
جامعة آشور ، كلية الطب البشري

Lesson Plan

- ❖ Introduction
- ❖ Parts of Nasal Cavity:
  - Vestibule
  - Nasal Cavity Proper

- ❖ Roof of Nasal Cavity
- ❖ Floor of Nasal Cavity

- ❖ Nasal Septum:
  - Introduction
  - Parts
  - Arterial Supply
  - Venous Drainage
  - Nerve Supply
  - Lymphatic Drainage
  - Applied Aspects

Introduction

- Internal nose is divided into right and left nasal cavities by a nasal septum.

- Each nasal cavity communicates with the exterior through nostril (naris).

- Each nasal cavity communicates with the nasopharynx through posterior nasal aperture (choana).

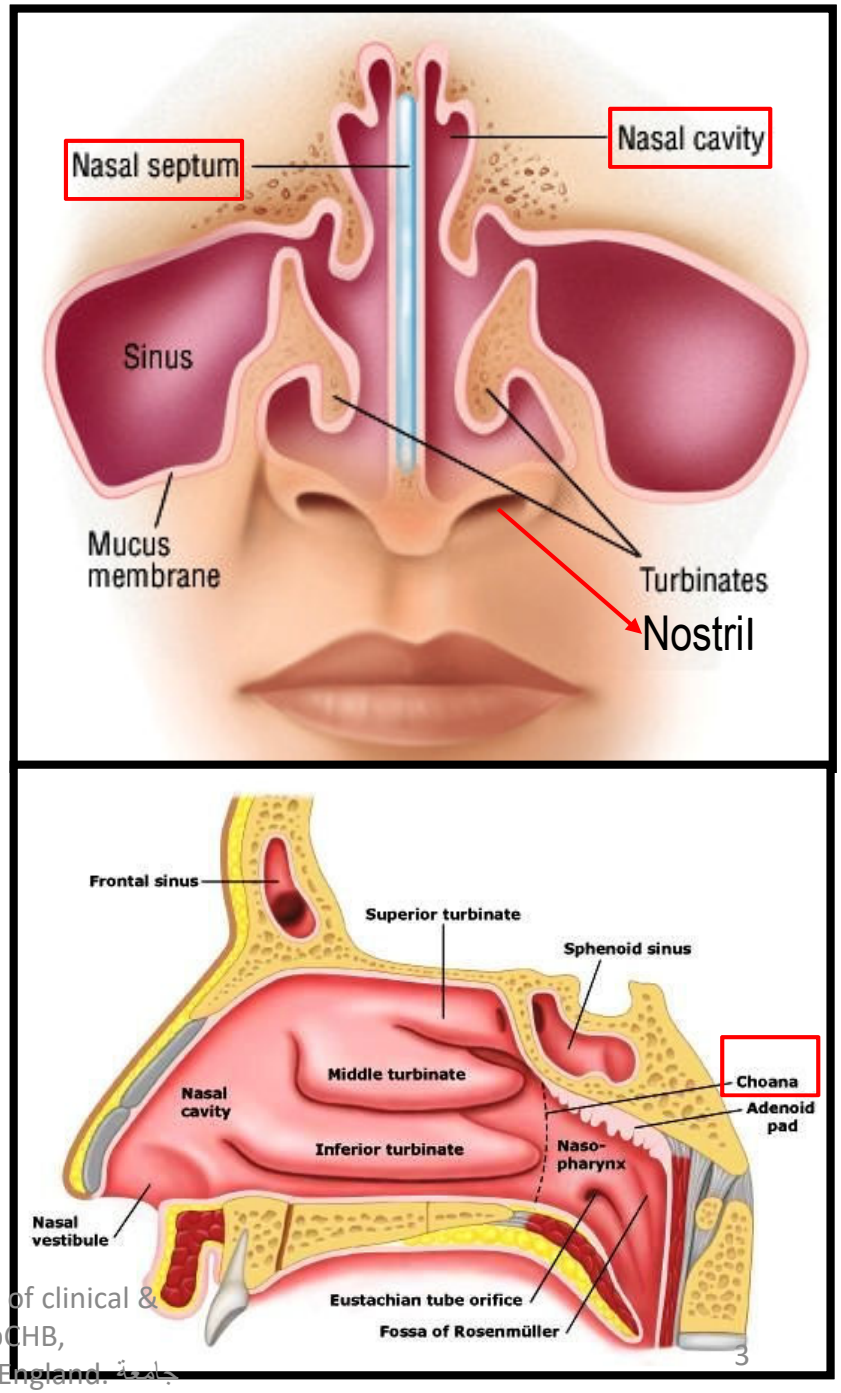

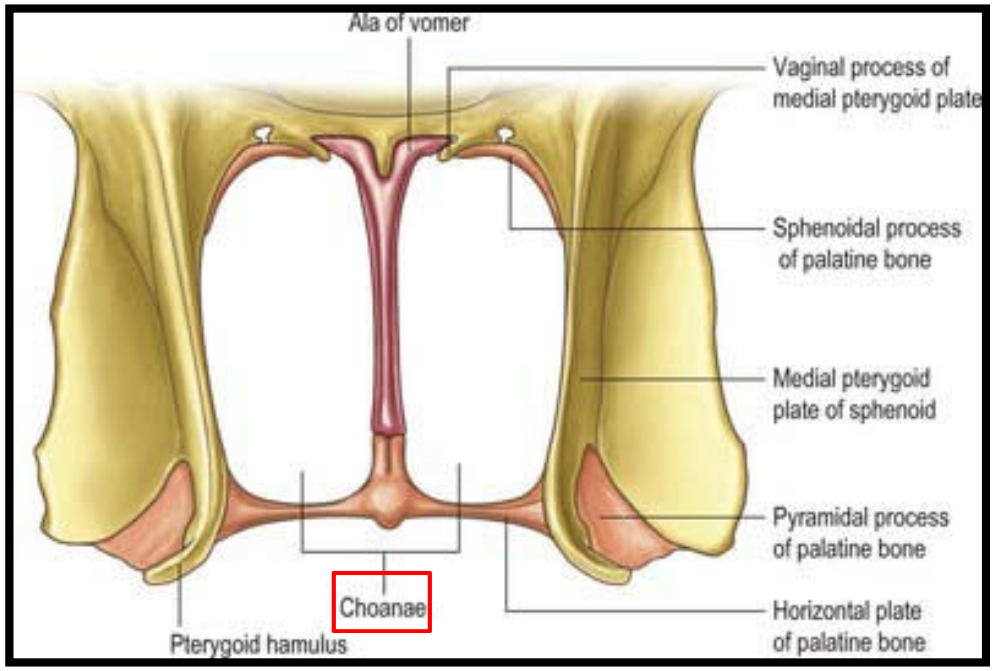

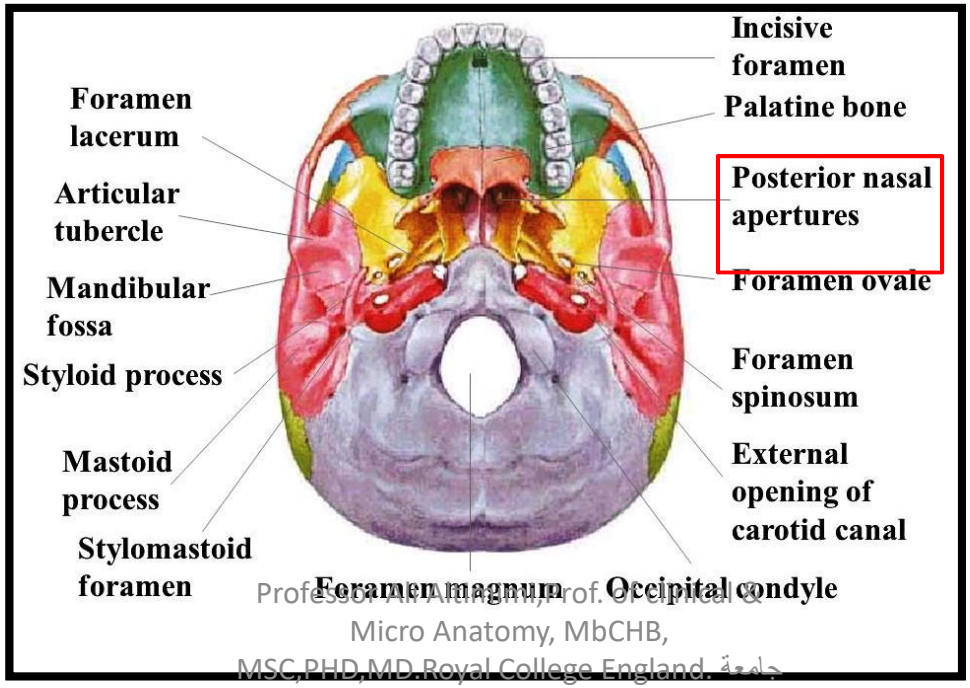

Professor Ali Altinshi, Prof. of Clinical & Micro Anatomy, MbCHB, MSC,PHD,MD.Royal College England. جامعة آشور ، كلية الطب البشري

Parts of Nasal Cavity

❖ 2 parts:

- Vestibule
- Nasal cavity proper

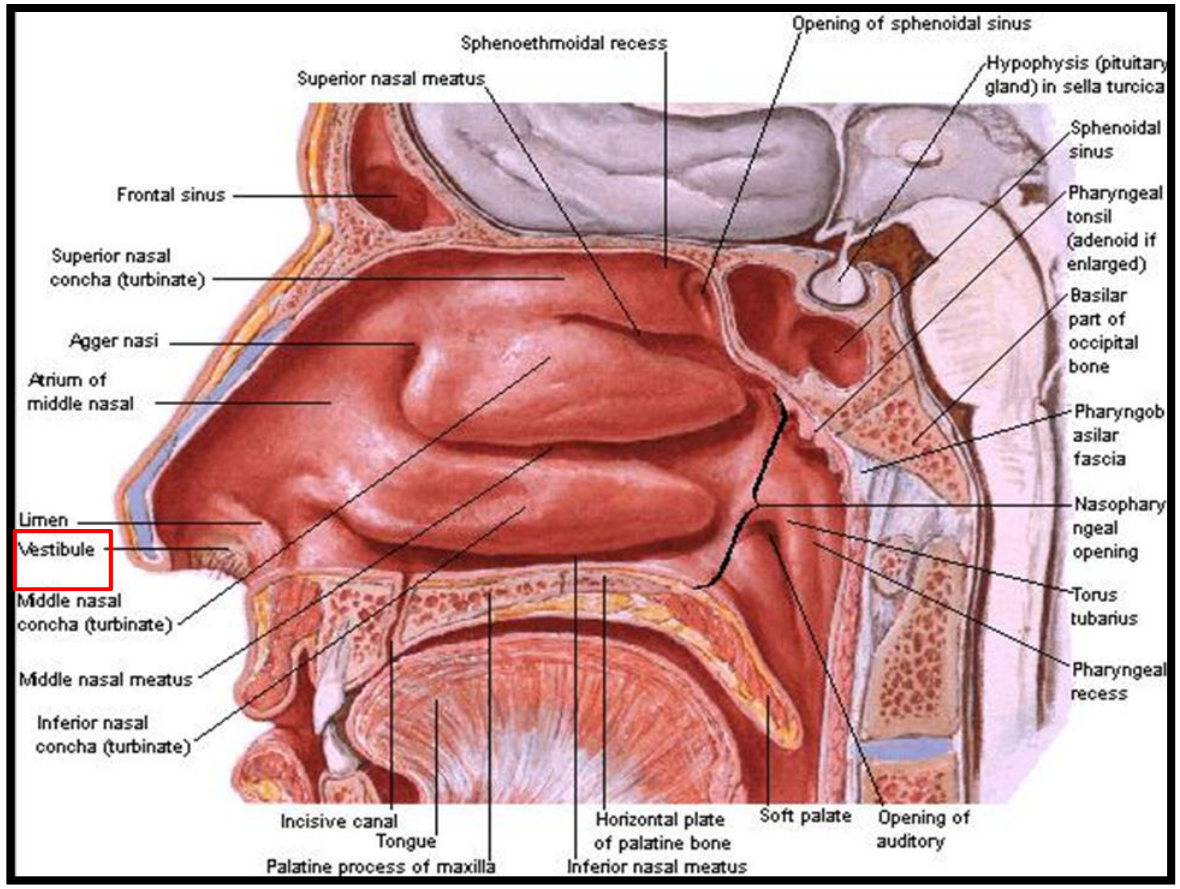

Vestibule-

- A small anteroinferior part.
- Lined by skin.

Nasal Cavity Proper-

- Large posterosuperior part.
- Lined by mucosa.

Vestibule

- Its upper limit on lateral wall of nasal cavity is marked by Limen nasi.
- Its medial wall is formed by columella.

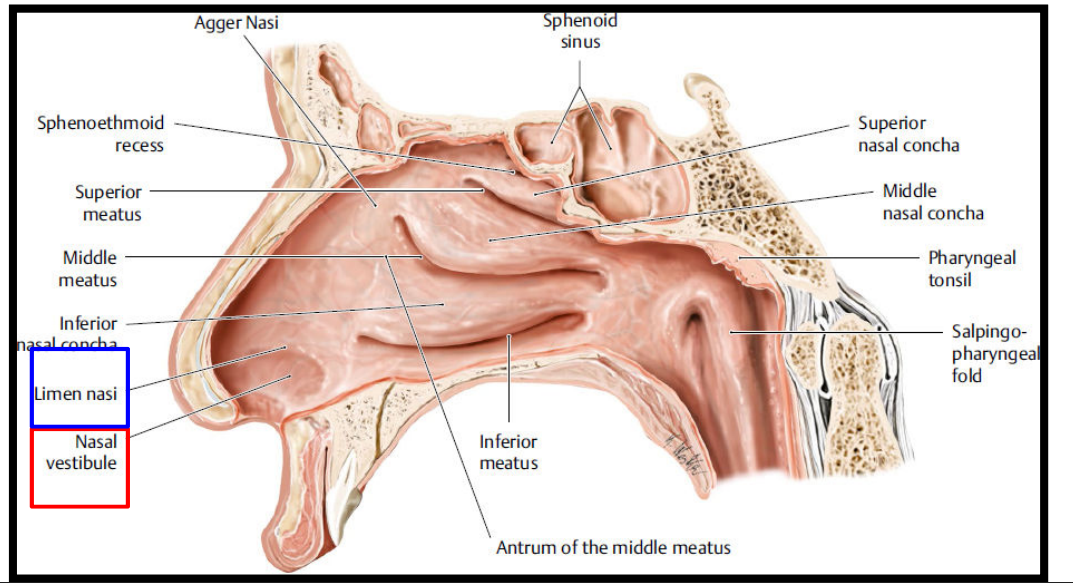

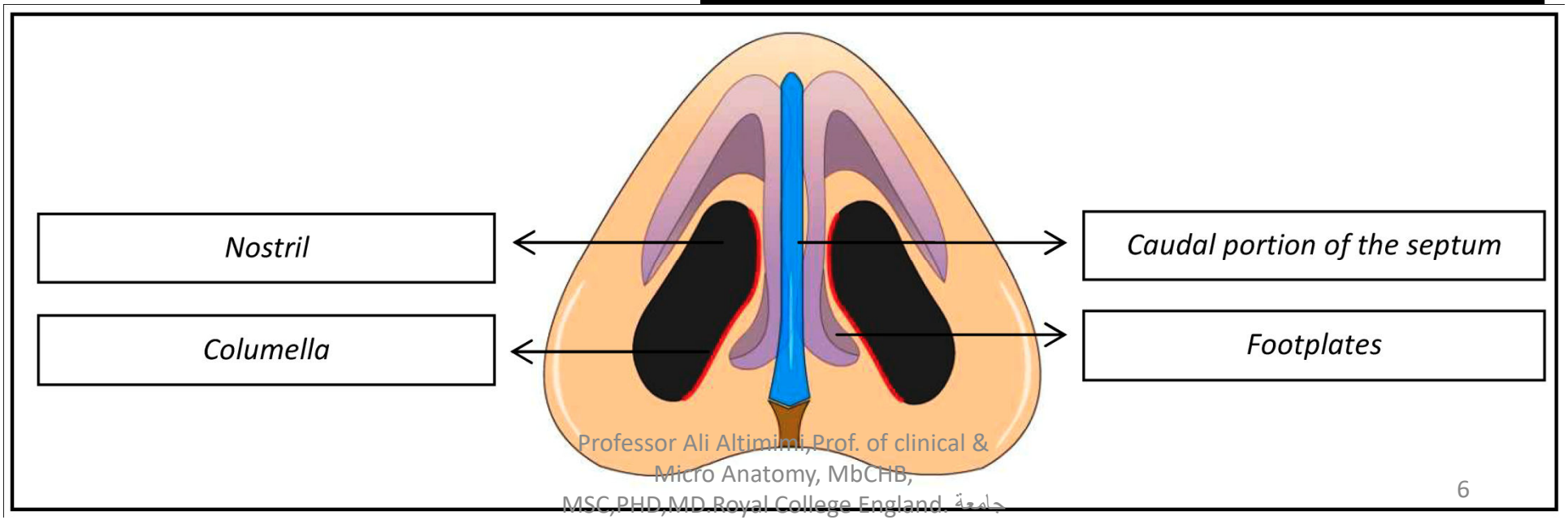

Nasal Cavity Proper

Boundaries-

- Roof.
- Floor.
- Medial wall (Nasal Septum).
- Lateral wall.

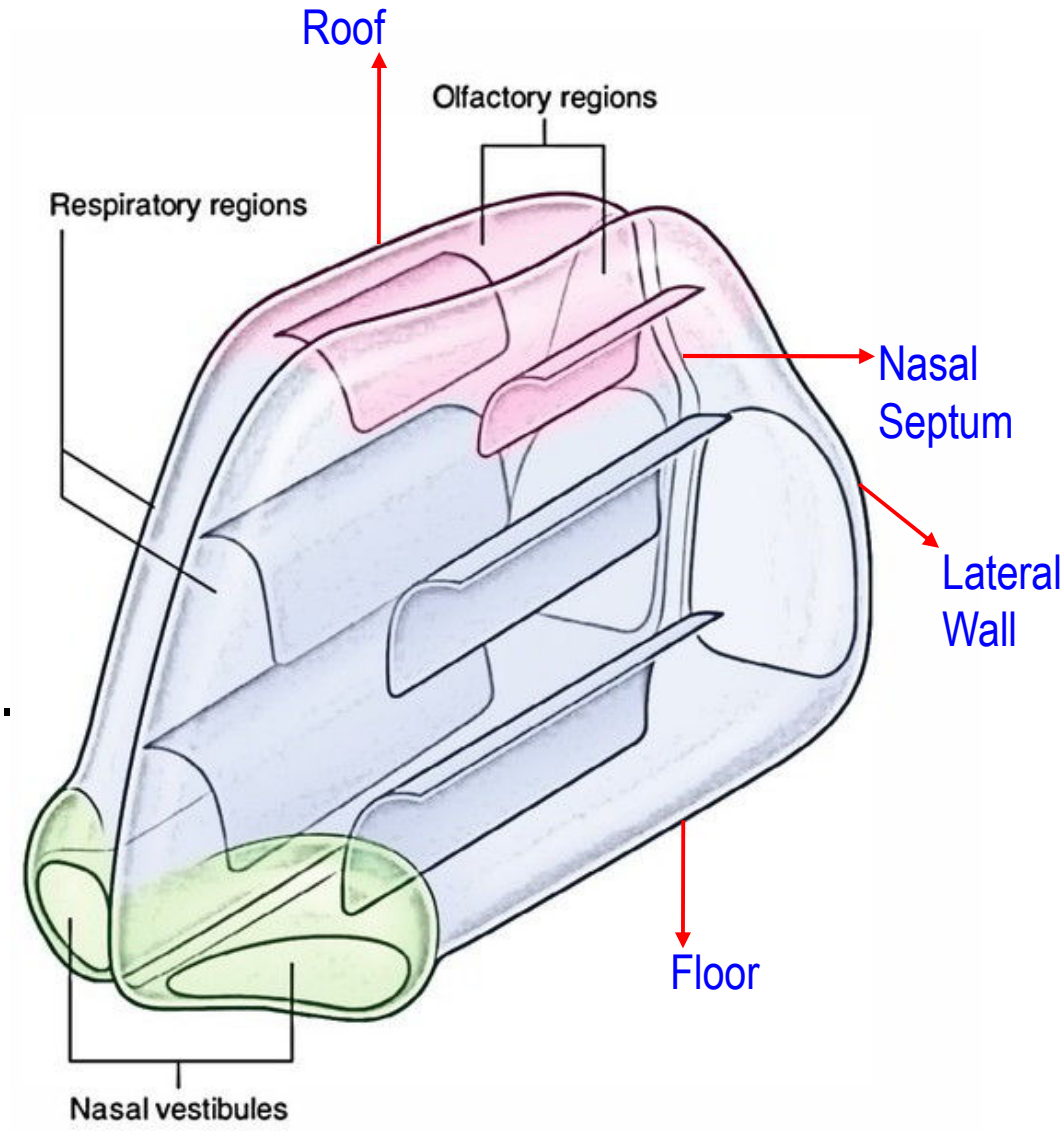

Roof of Nasal Cavity

❖ Divided into 3 parts:

- Anterior 1/3rd .
- Middle 1/3rd .
- Posterior 1/3rd .

Anterior 1/3rd –

- Slopes downwards and forward

Formed by:

- Nasal spine of Frontal bone.
- Nasal bone.
- Junction of Septal and Lateral cartilages

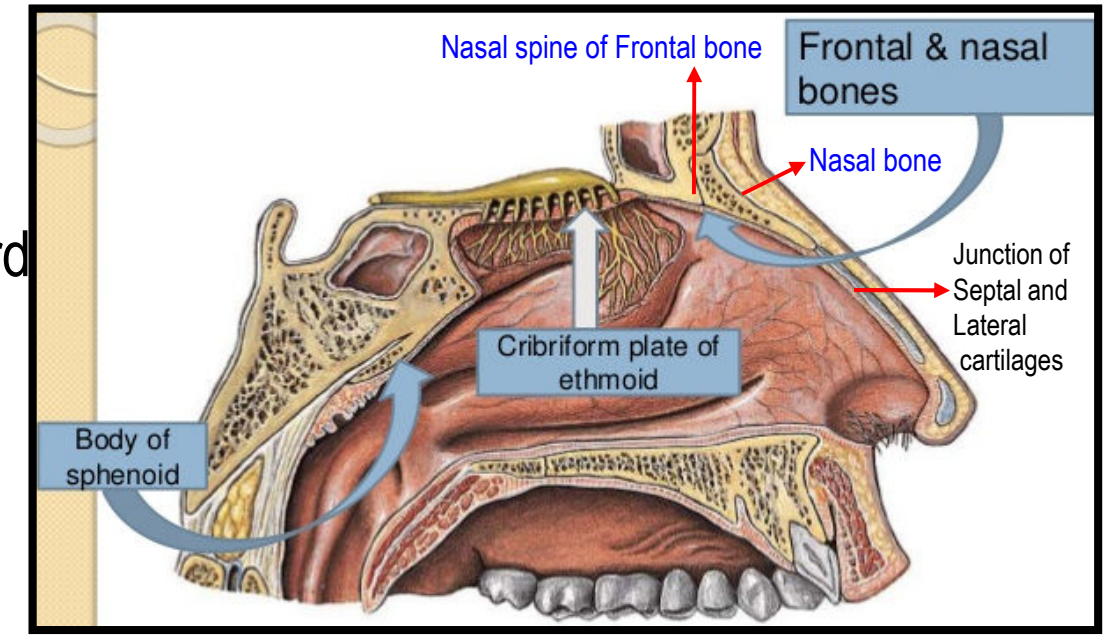

Roof of Nasal Cavity contd…

Middle 1/3rd –

- Horizontal.

Formed by:

- Cribriform plate of Ethmoid bone.
- Through the cribriform plate, olfactory nerves enter the cranial cavity.

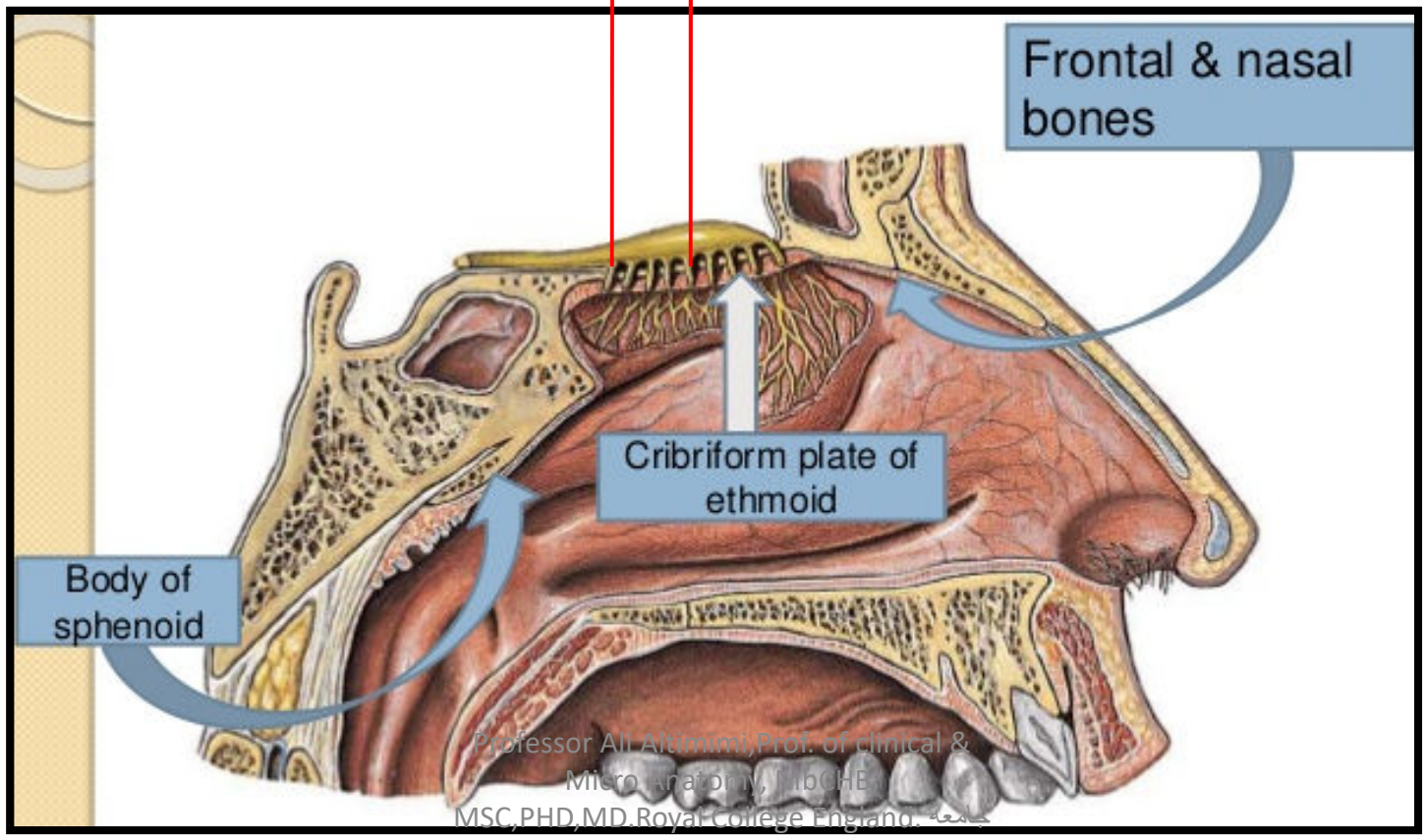

Professor Ali Altimimi,Prof. of clinical & Micro Anatomy, MbCHB, MSC,PHD,MD.Royal College England. جامعة آشور ، كلية الطب البشرى

Roof of Nasal Cavity contd…

Posterior 1/3rd –

- Slopes downwards and backwards.

Formed by:

- Anterior surface of body of Sphenoid bone.

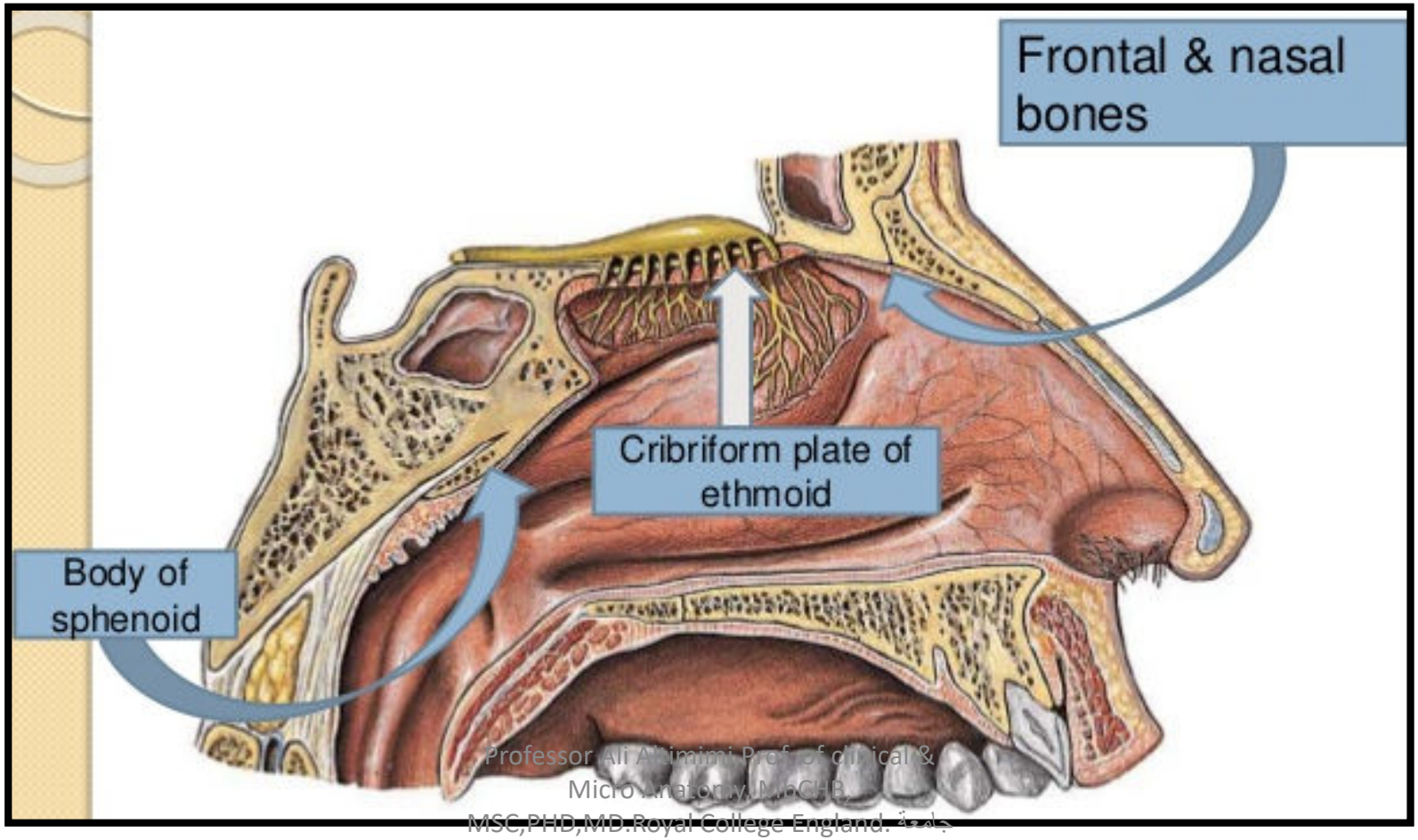

Floor of Nasal Cavity

- Almost horizontal.

Formed by:

- Upper surface of hard palate.

Anterior 3/4th –

- By palatine process of Maxilla.

Posterior 1/4th –

- Horizontal plate of Palatine bone.

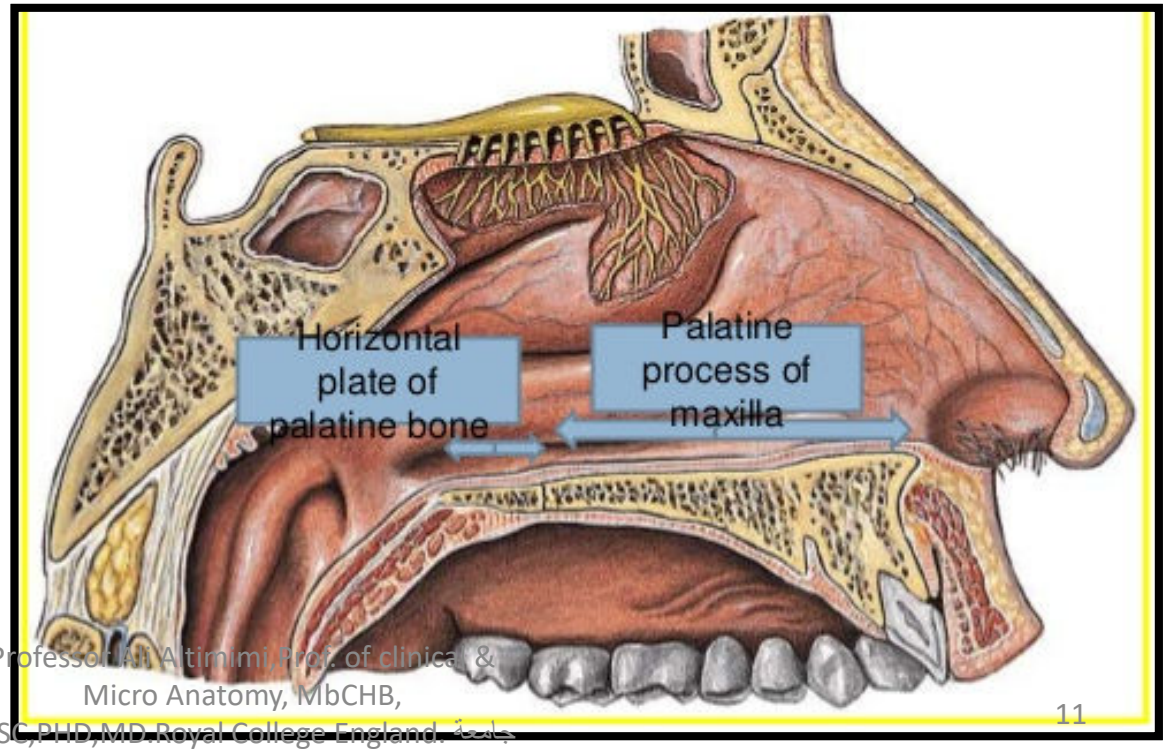

Nasal Septum

Introduction

- A median osseocartilaginous partition between two nasal cavities.

- Forms the medial wall of nasal cavity.

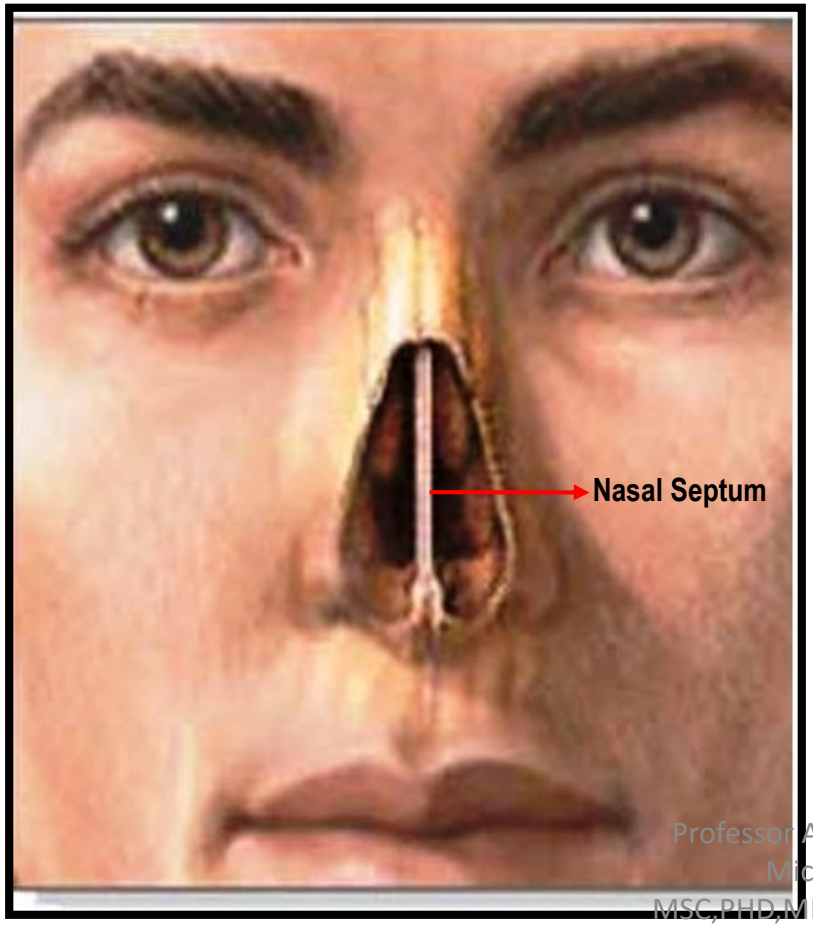

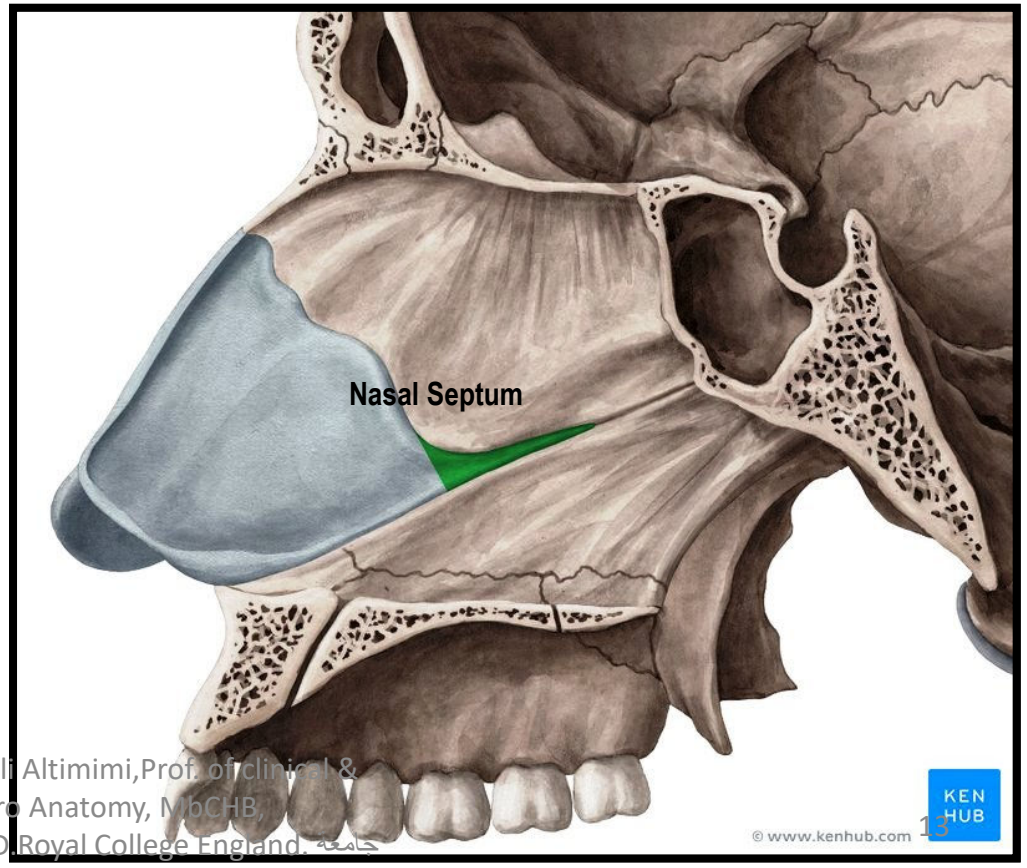

Parts of Nasal Septum

❖ 3 parts:

- Bony part.
- Cartilaginous part.
- Membranous part.

Framework of Bony Part-

I. Ethmoid- perpendicular plate

II. Vomer

III. Frontal - nasal spine

IV. Nasal- crest

V. Sphenoid- crest

VI. Maxilla- palatine process

VII. Palatine- horizontal plate

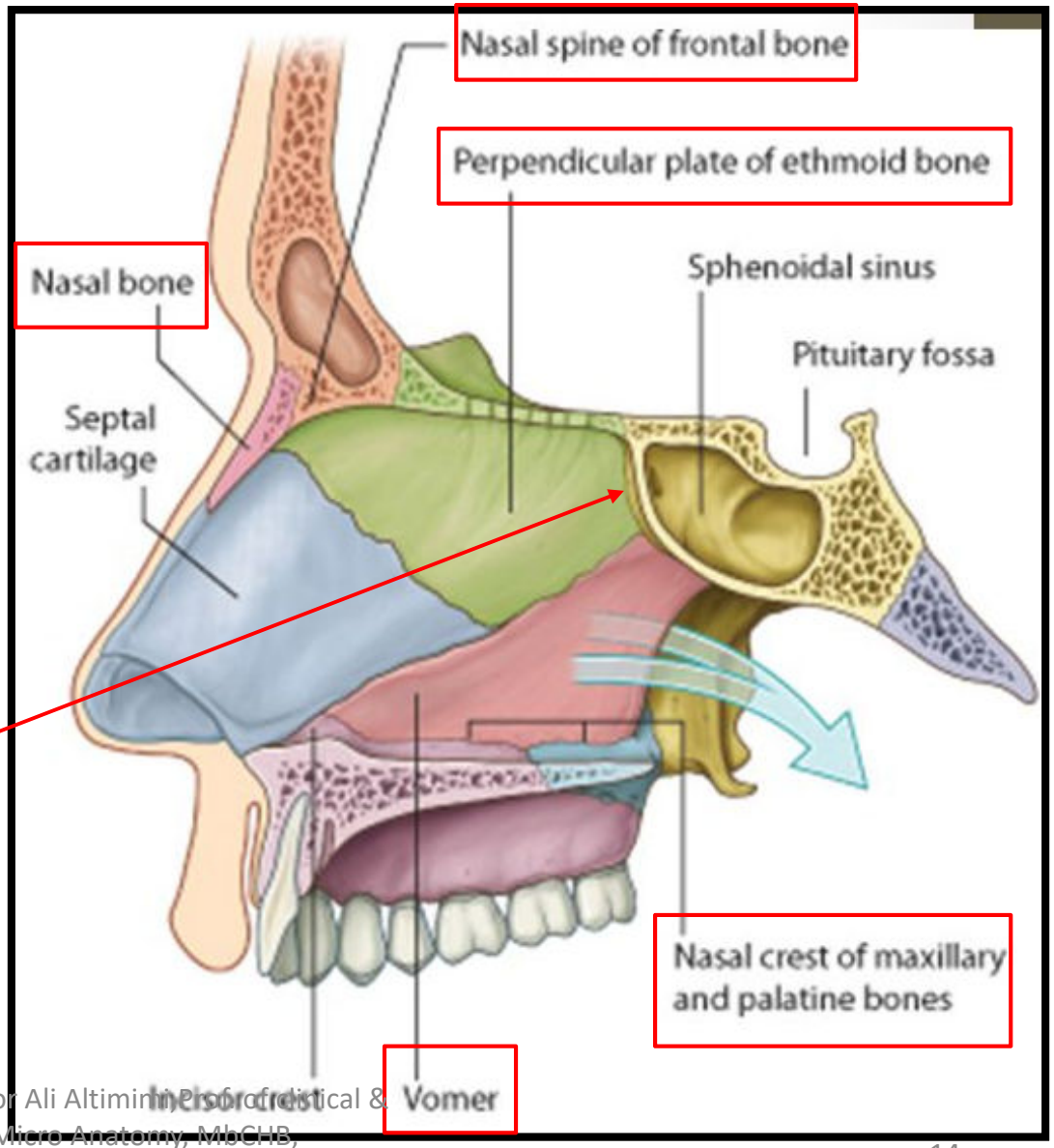

Cartilaginous Part

Framework of Cartilaginous Part-

- Septal cartilage
- Medial crura (septal processes) of 2 major alar cartilages.

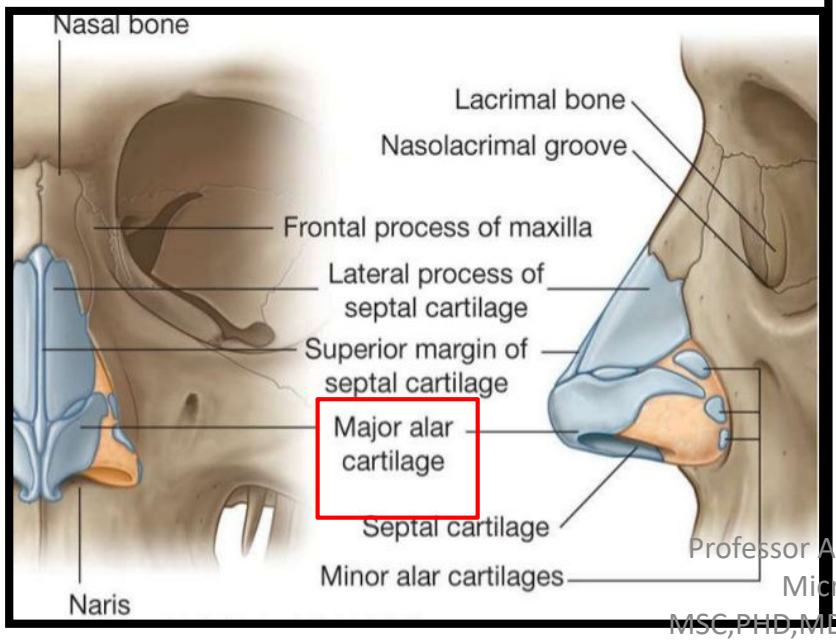

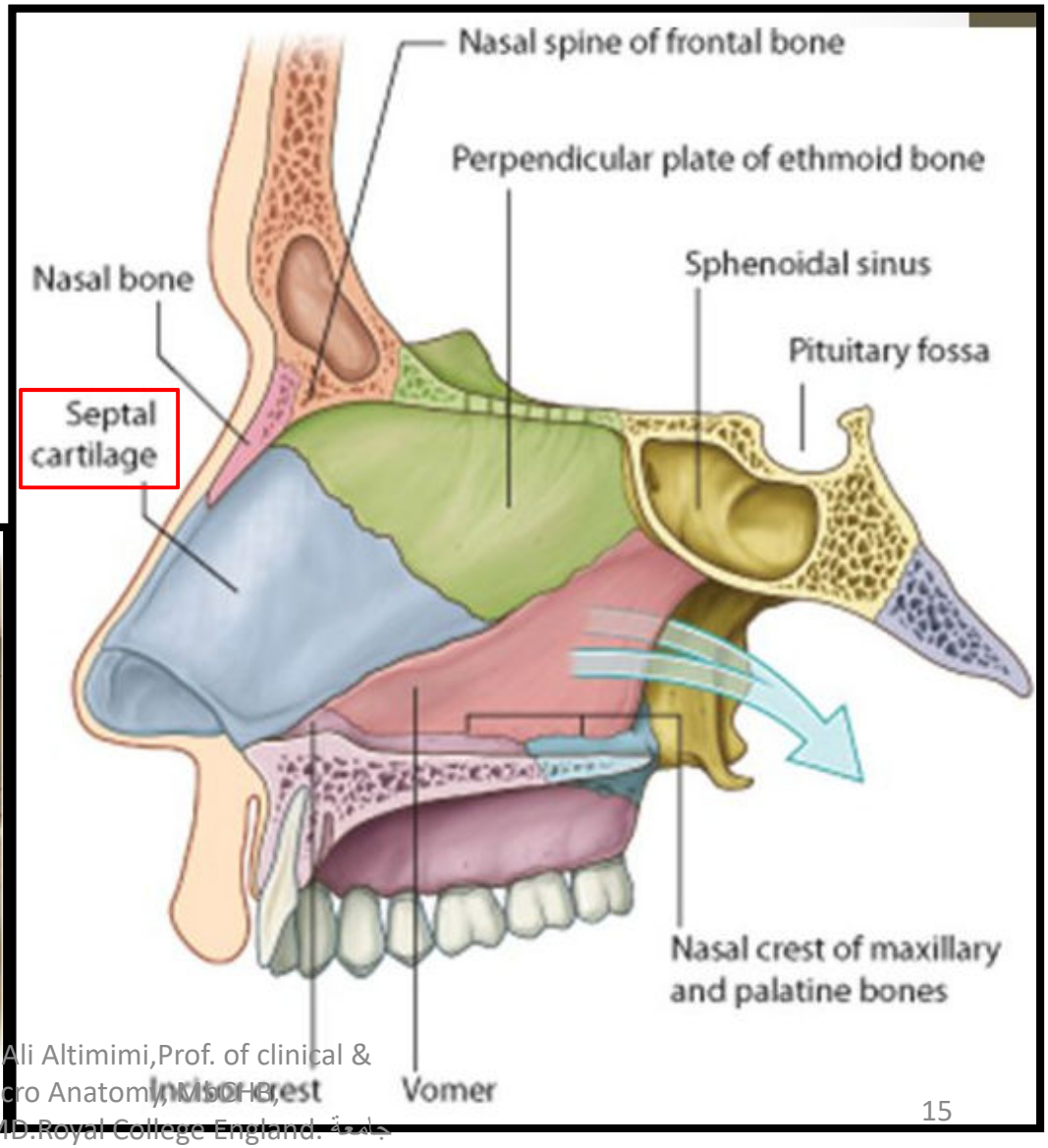

Cartilaginous Part contd…

Columellar Septum-

- Medial crura of 2 major alar cartilages are united together in the midline by a fibrous tissue to form columellar septum (columella).

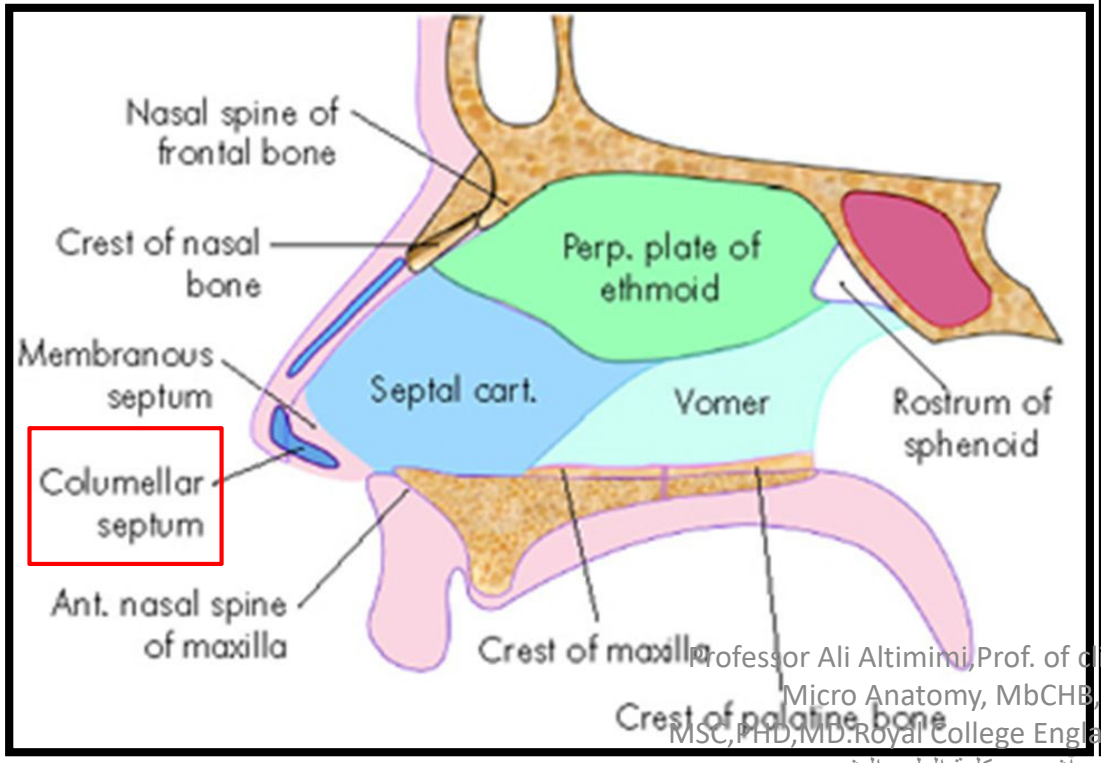

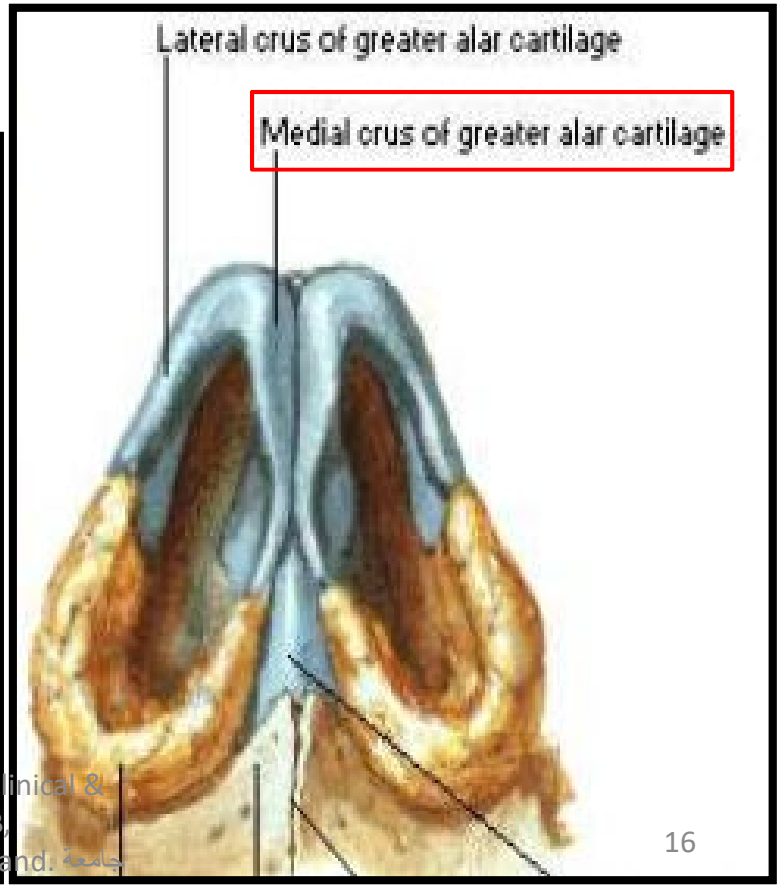

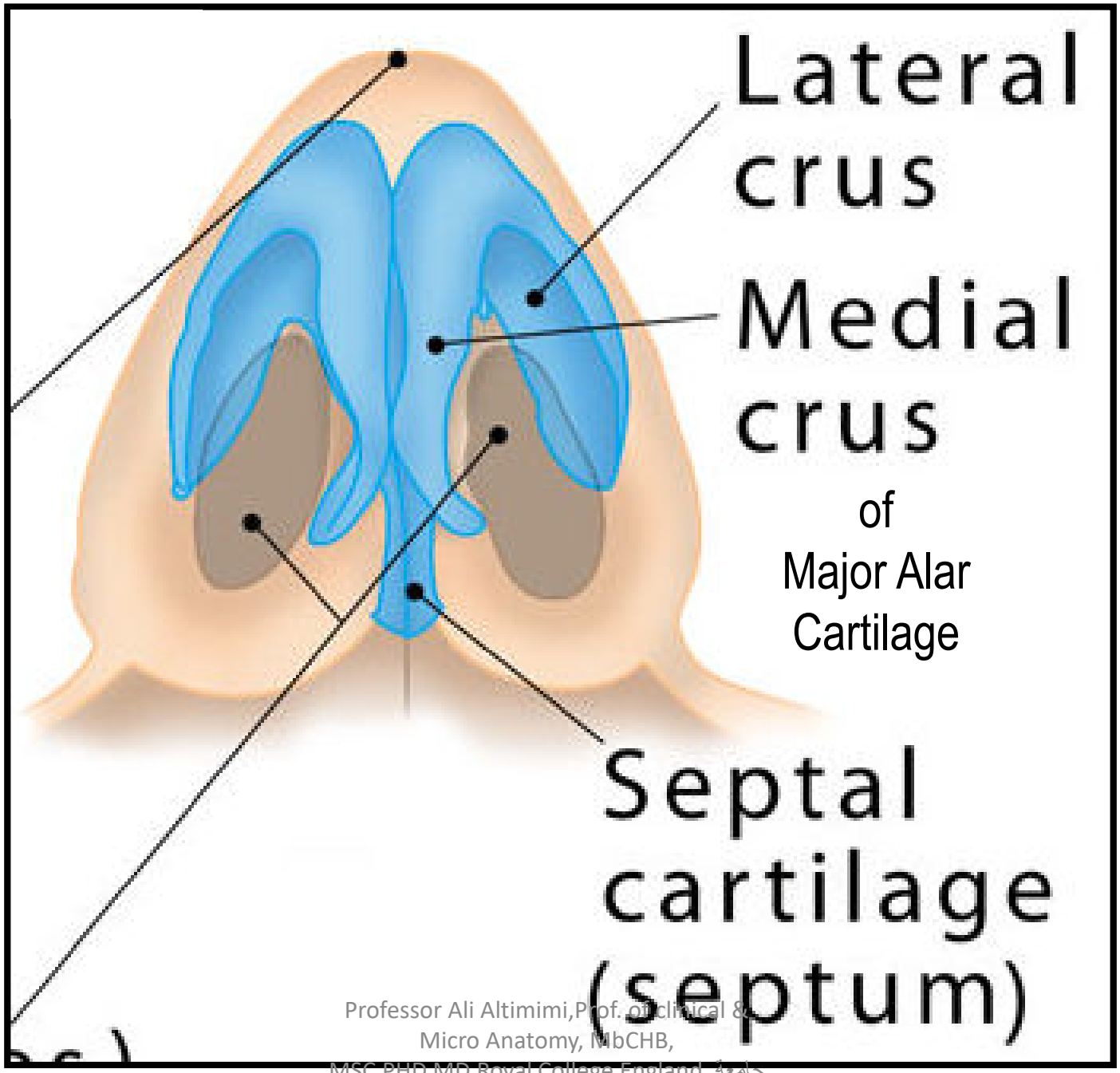
Lateral crus
Medial crus
of
Major Alar
Cartilage
Septal cartilage (septum)

Membranous Part

- Between the columella and caudal border of septal cartilage, a small portion of septum is made up of double layer of skin and is referred as membranous septum.

- Both columellar and membranous parts of the septum are freely movable from side to side.

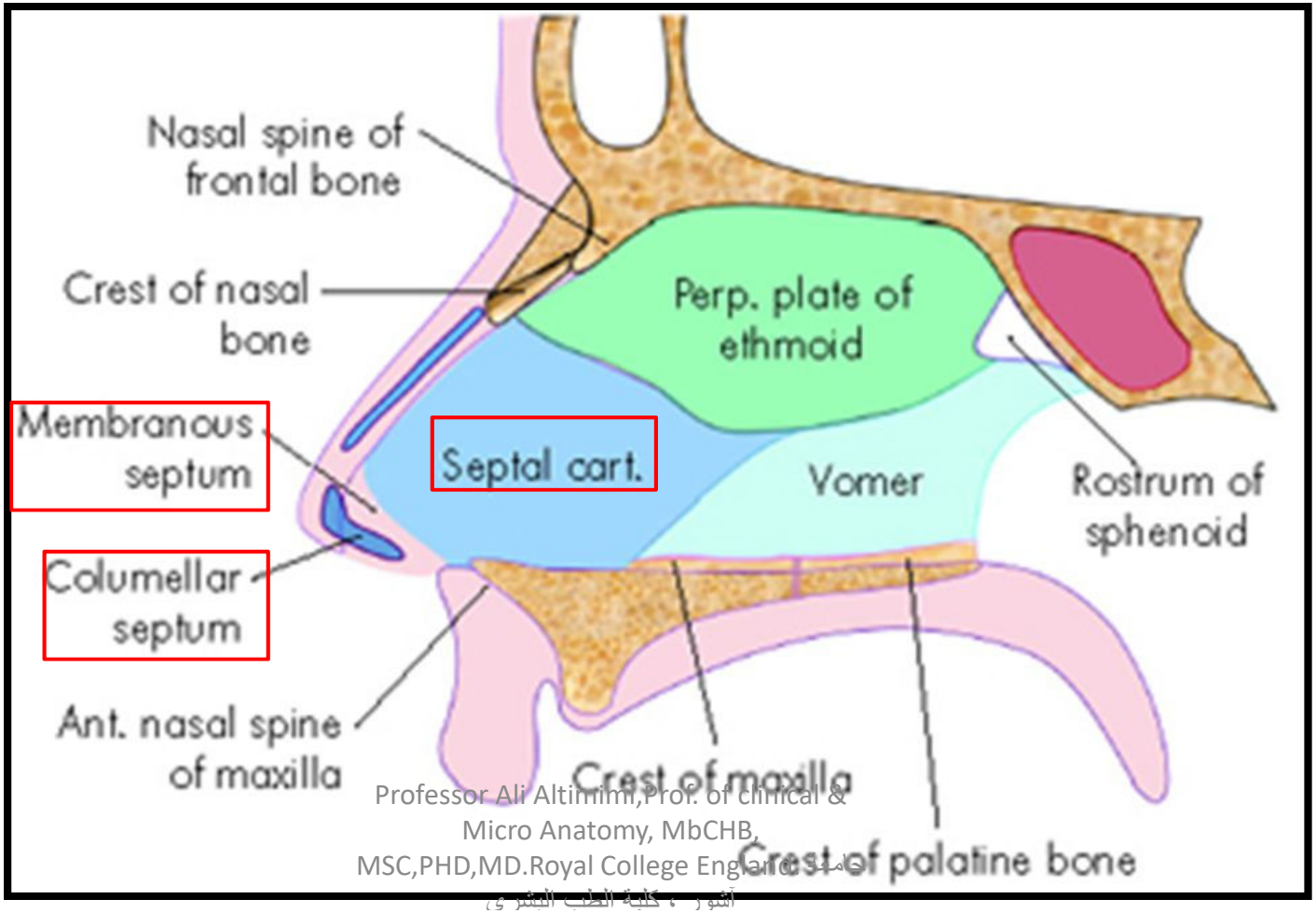

Arterial Supply of Nasal Septum

- Septal b/o Anterior Ethmoidal artery
- Septal b/o Posterior Ethmoidal artery
- Septal b/o Sphenopalatine artery
- Septal b/o Greater Palatine artery
- Septal b/o Superior labial artery

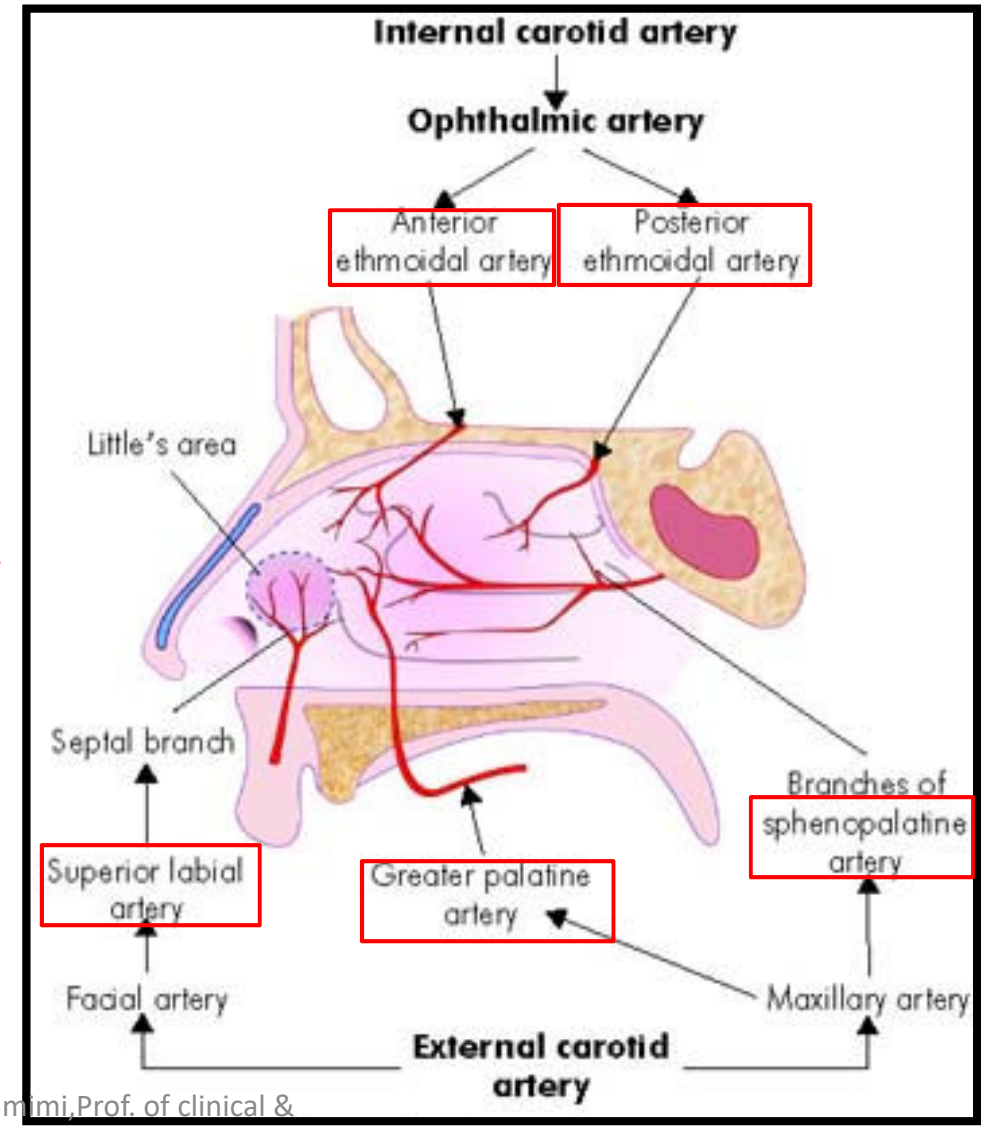

Little's Area

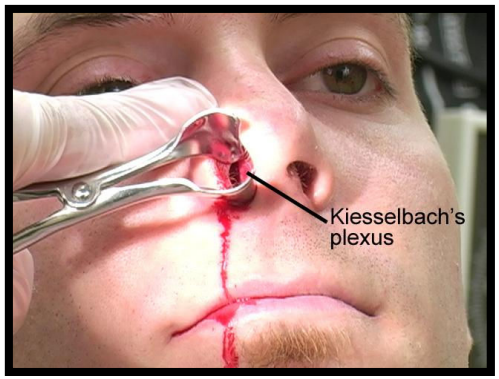

- ❖ An area in anteroinferior part of nasal septum just above the vestibule.
- ❖ It is highly vascular.
- ❖ In this area, an arterial plexus is formed by the following arteries:
  - Septal b/o Anterior Ethmoidal artery
  - Septal b/o Sphenopalatine artery
  - Septal b/o Greater Palatine artery
  - Septal b/o Superior labial artery.
- ❖ This plexus is known as Kiesselbach's plexus.

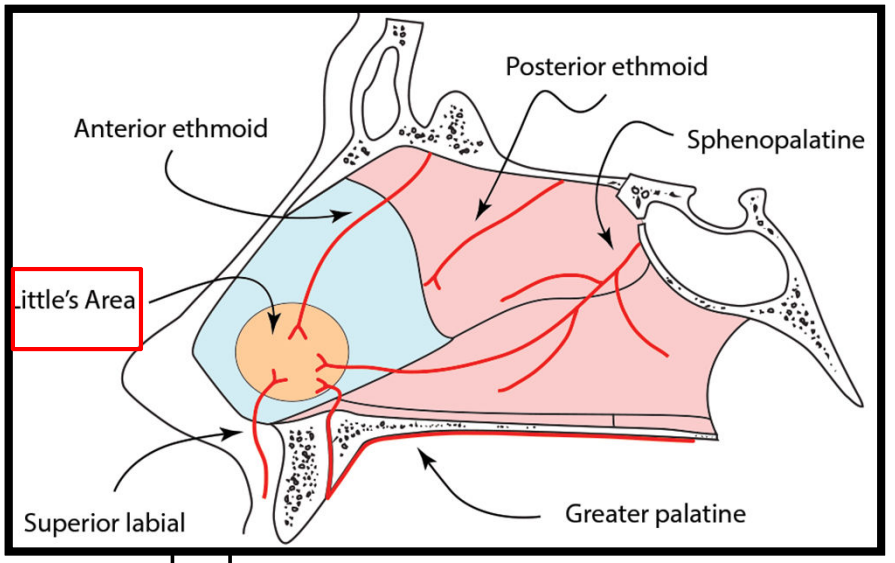

- ❖ In Little's area, submucous venous plexus is also more marked.

Applied aspect-

- Little's area is the **commonest site of epistaxis** (bleeding through the nasal cavity) in children and young adults usually due to finger nail trauma during pricking of nose.

Professor Ali Altaqimi Prof. of clinical & Micro Anatomy, MbCHB, MSC,PHD,MD.Royal College England. جامعة آشور ، كلية الطب البشري
20

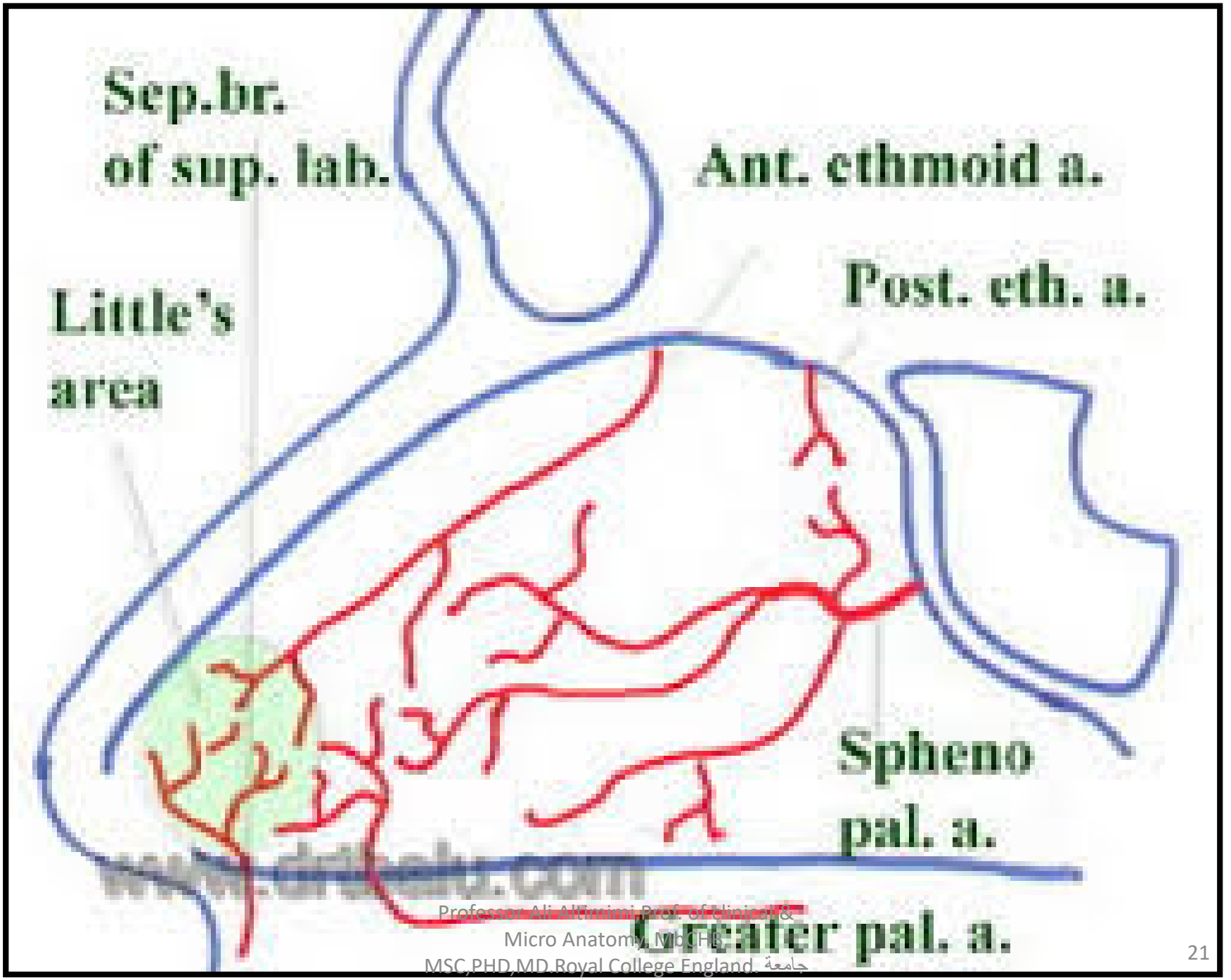

Professor Ali Al'Imimi Prof. of Clinical &
Micro Anatomy, MbChB,
MSC,PHD,MD,Royal College England. جامعة
آشور ، كلية الطب البشري

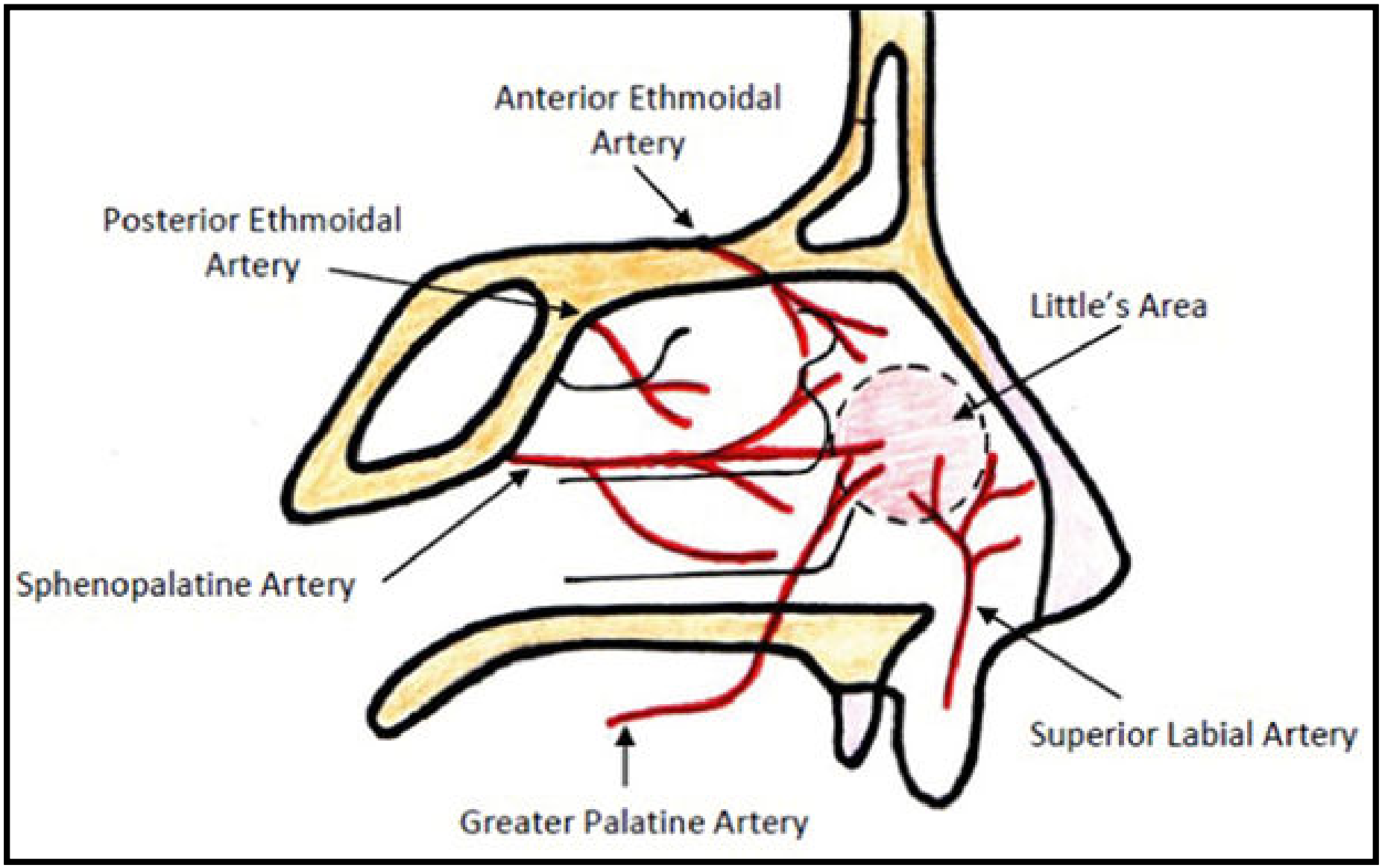
Anterior Ethmoidal Artery
Posterior Ethmoidal Artery
Little's Area
Sphenopalatine Artery
Superior Labial Artery
Greater Palatine Artery

Venous Drainage of Nasal Septum

❖In nasal septum, veins accompany the arteries.

❖A venous plexus is formed beneath the mucosa.

❖Veins drain into:

•Facial vein.

•Pterygoid venous plexus.

•Pharyngeal venous plexus.

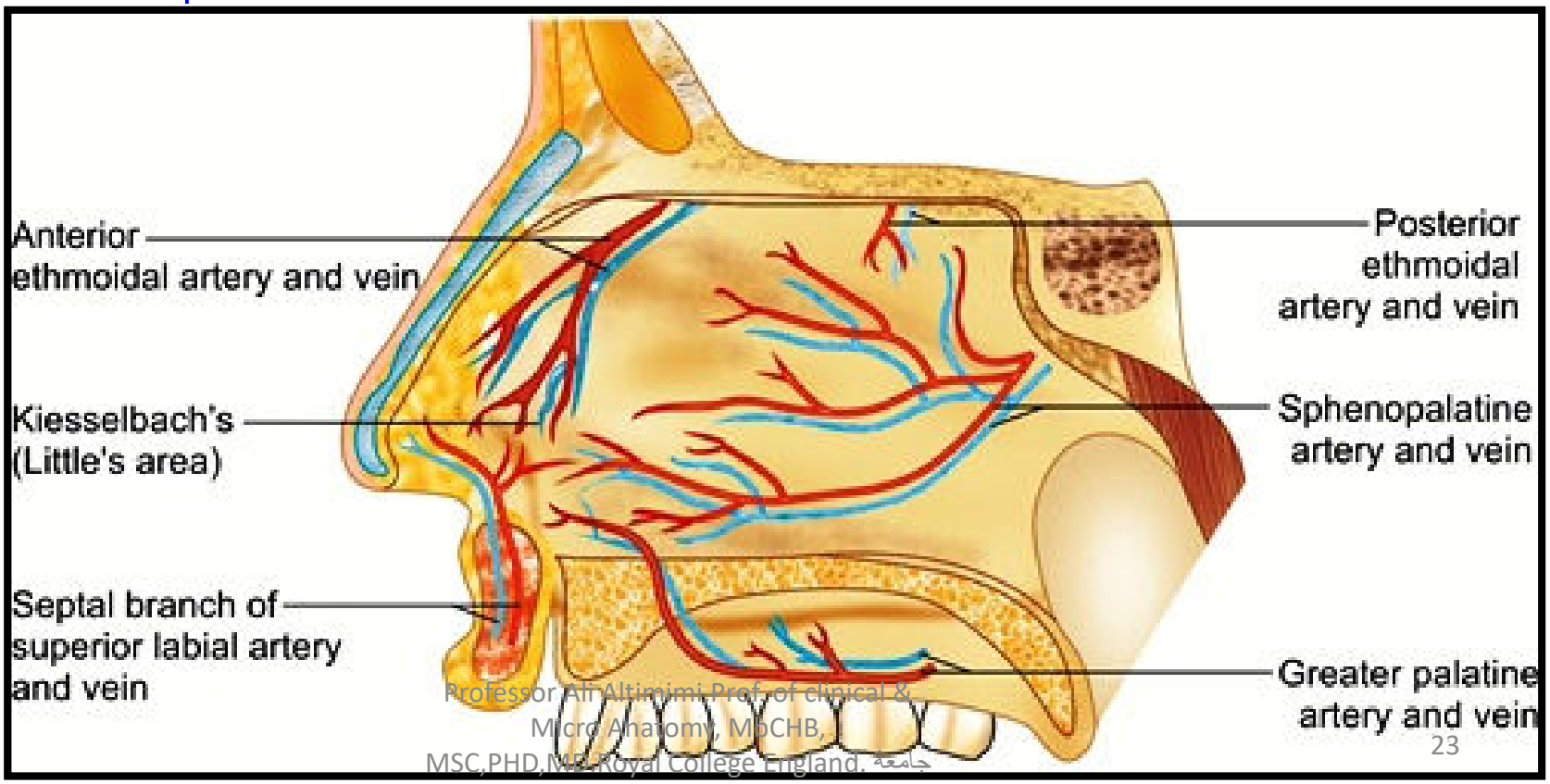

Professor Ali Altimimi,Prof.of clinical & Micro Anatomy, MBCHB, MSC,PHD,MRC Royal College England. جامعة آشور ، كلية الطب البشري

Nerve Supply of Nasal Septum

Anterosuperior Part-

• Internal nasal nerve (a branch of Anterior Ethmoidal Nerve).

Anteroinferior Part-

• Anterior Superior Alveolar Nerve (a branch of Infraorbital nerve).

Posterosuperior Part-

•Medial posterior superior nasal nerves (branches of Pterygopalatine ganglion).

Posteroinferior Part-

•Nasopalatine nerve (a branch of Pterygopalatine ganglion).

Olfactory Part (upper 1/3rd of nasal septum just below cribriform plate)-

• Olfactory Nerves.

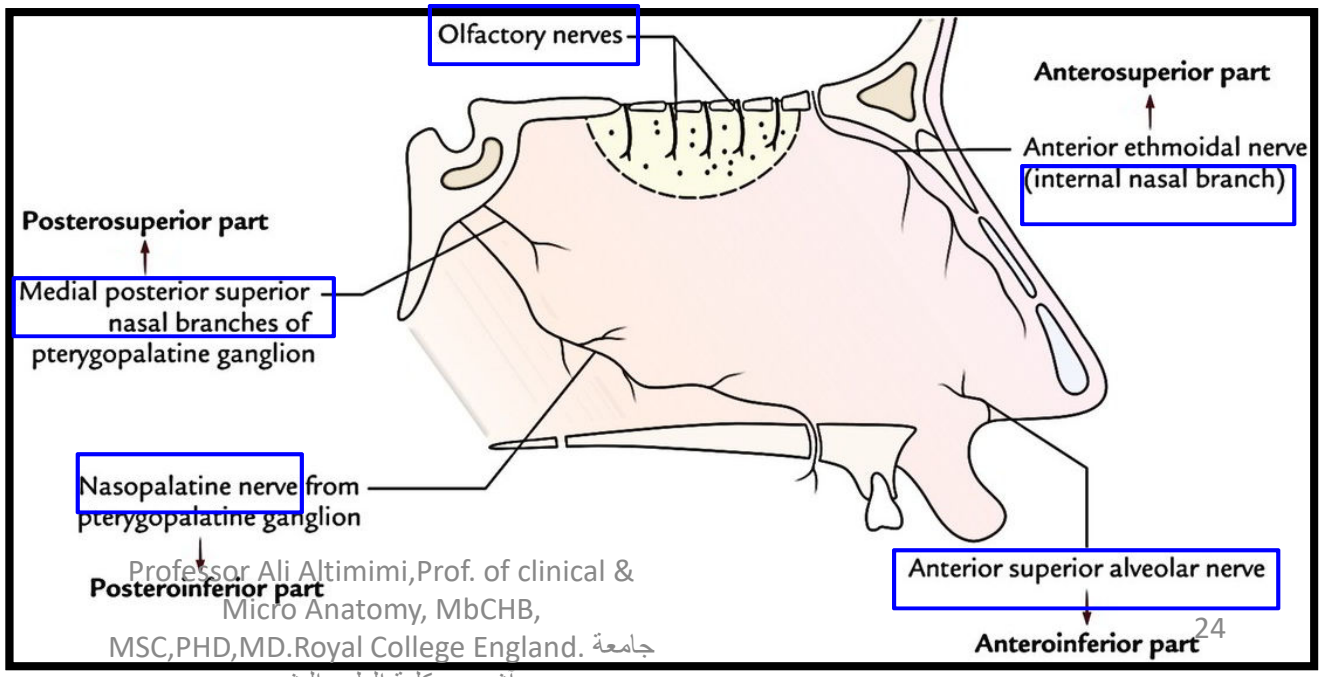

Lymphatic Drainage of Nasal Septum

Anterior ½-

- Drains into:
- Submandibular lymph nodes.

Posterior ½-

- Drains into:
- Retropharyngeal lymph nodes.

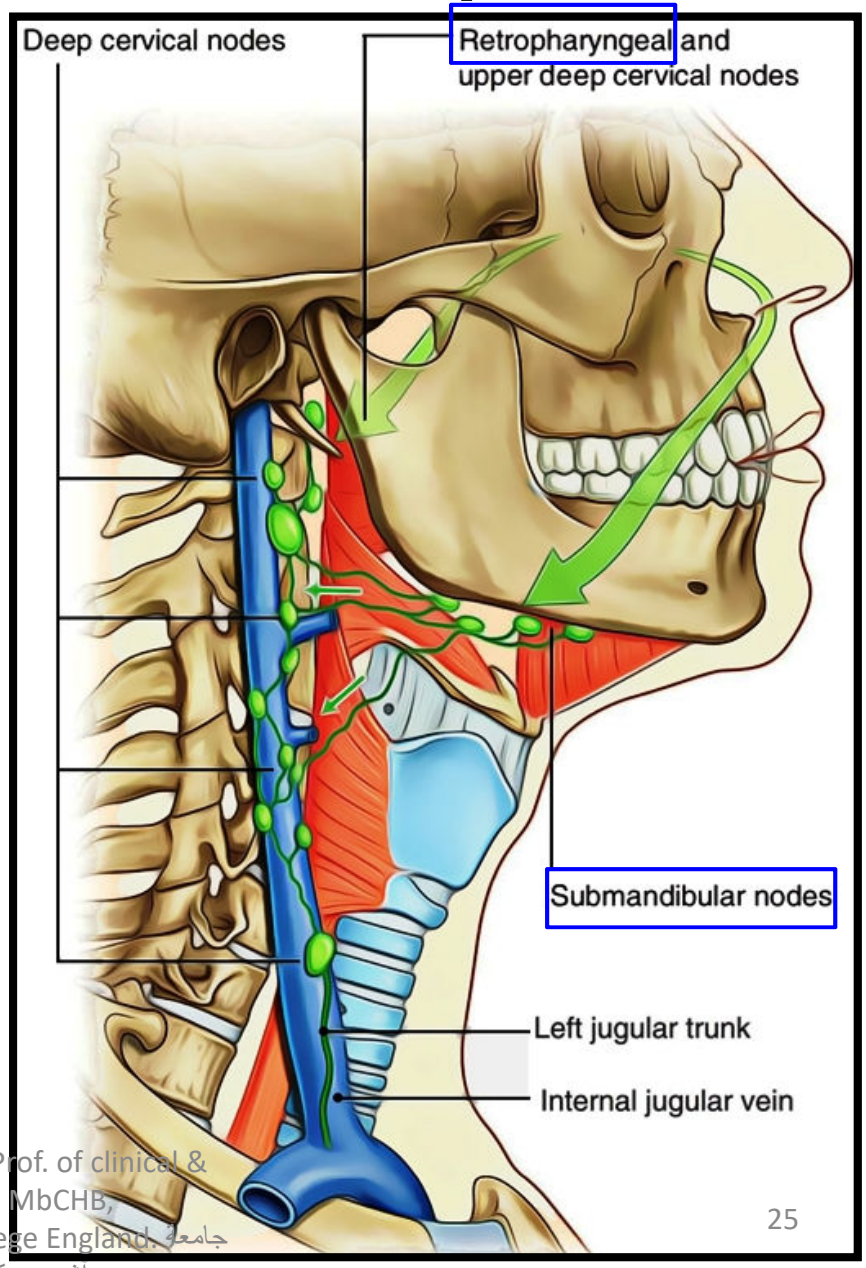

Applied Aspects

- Nasal Septum is seldom exactly in median plane.
- Usually it bulges to right or left side, more frequently to the right.

DNS [Deviated Nasal Septum]-

- An important cause of nasal obstruction.

Sex Predilection-

- Male>Female.

Etiology-

- Trauma.
- Developmental error.

Clinical Features-

- Mechanical nasal obstruction.
- Sinusitis.
- Headache etc.

Treatment-

Surgical correction-

- SMR (Submucosal resection).
- Septoplasty.

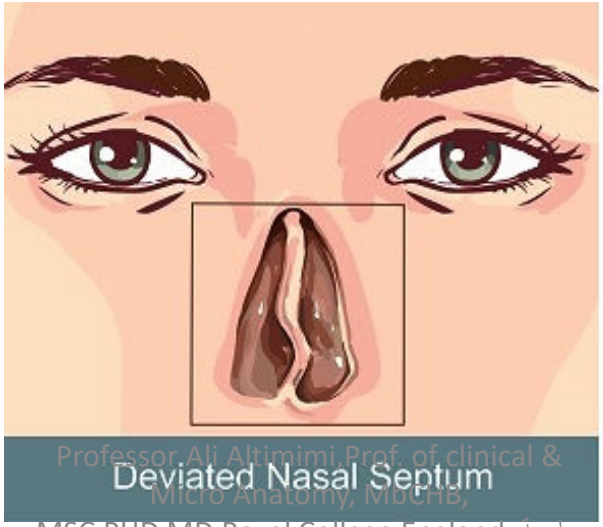

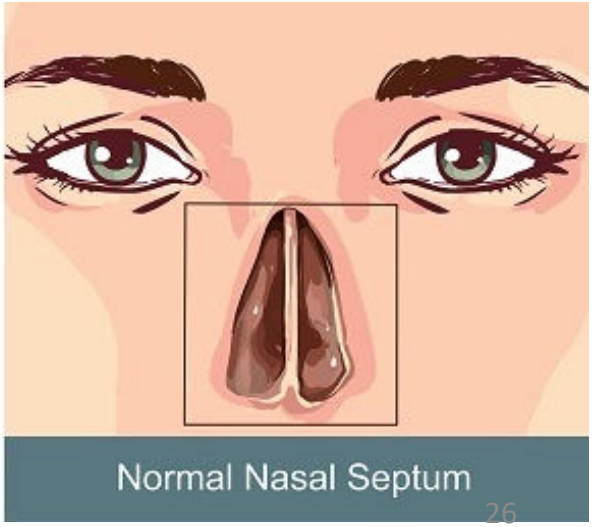

Professor Ali Altimimi,Prof. of clinical & Micro Anatomy, MbChB, MSC,PHD,MD.Royal College England. جامعة آشور ، كلية الطب البشري

Applied Aspects contd…

Supratip depression of External Nose-

- Septal cartilage provides support to dorsum of anterior 2/3rd of nose.
- Excessive removal of septal cartilage during submucosal resection can lead to Supratip depression of External Nose.
- Destruction of septal cartilage due to disease may result into this deformity.

