Pharynx, posterior view:

1 IJV

2 ICA

3 X n

4 Pharyngeal branch X

5Superior laryngeal br X

6 Recurrent laryngeal br X

7 Ascending pharyngeal a

8 Superior constrictor

9 Middle constrictor

10 Inferior constrictor

11 Pharyngeal raphe

12 Cricopharyngeus

13 Esophagus

14 Pharyngeal plexus

15Thyroid gland

16 Sympathetic trunk

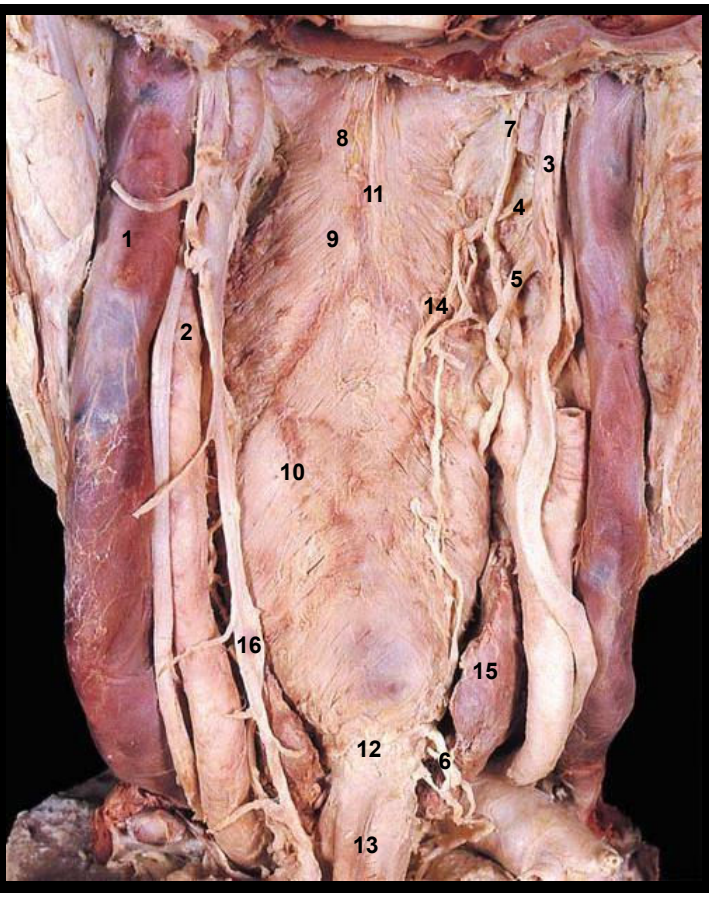

Larynx ANATOMY

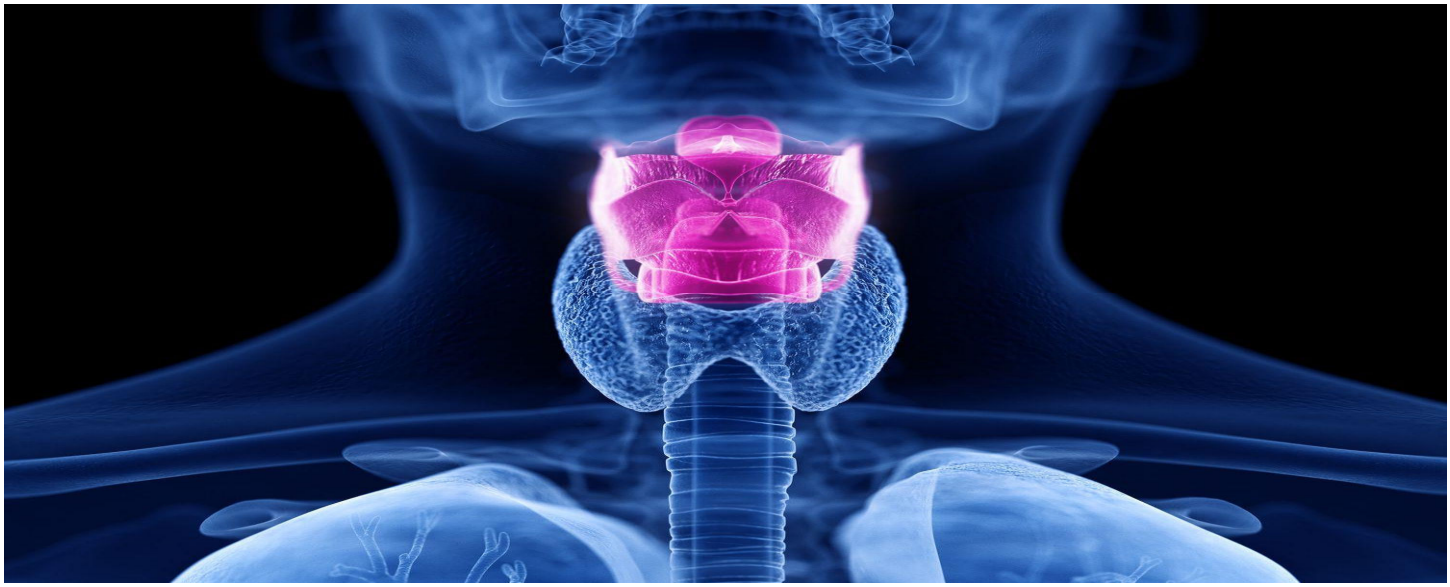

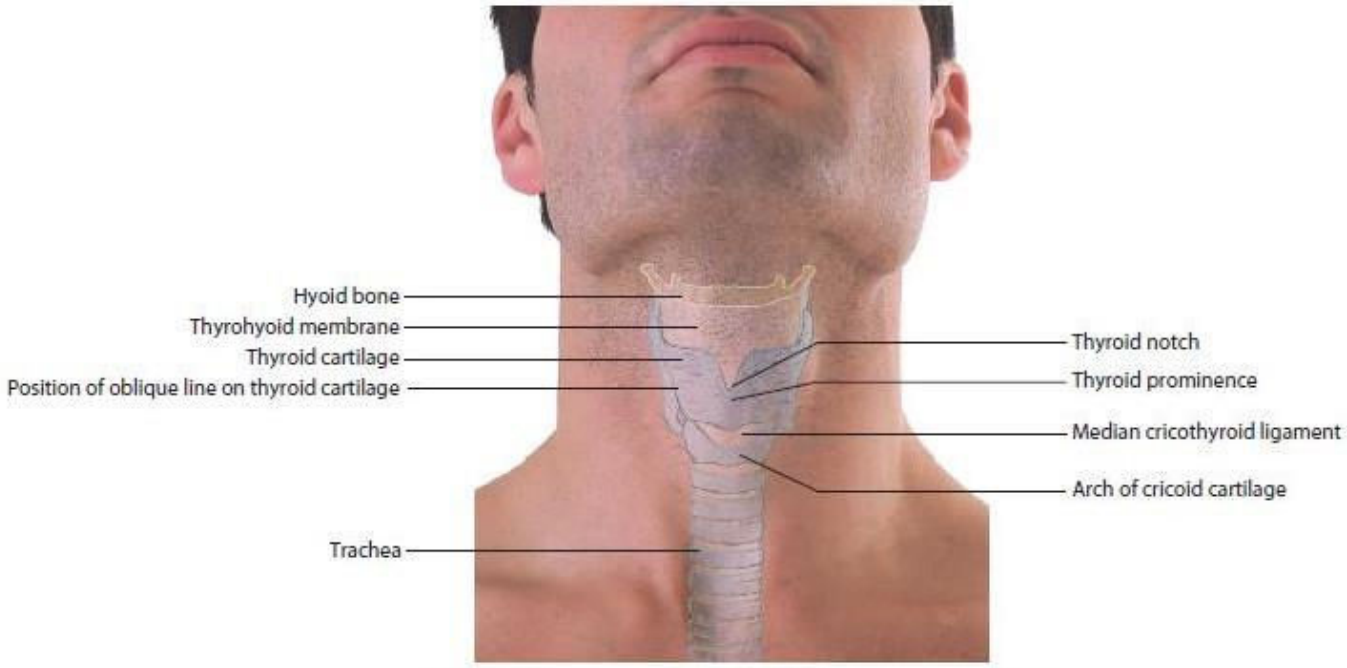

Position of larynx in the neck as it relates to the surface

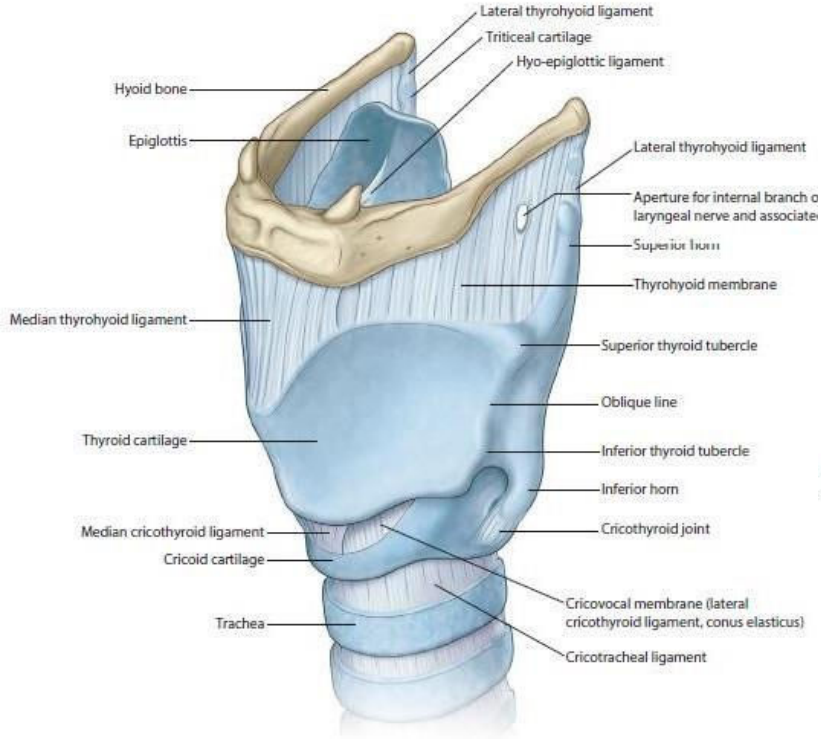
Lateral thyrohyoid ligament
Triticeal cartilage
Hyo-epiglottic ligament
Hyoid bone
Epiglottis
Lateral thyrohyoid ligament
Aperture for internal branch o
laryngeal nerve and associate
Superior horn
Thyrohyoid membrane
Median thyrohyoid ligament
Superior thyroid tubercle
Oblique line
Thyroid cartilage
Inferior thyroid tubercle
Inferior horn
Median cricothyroid ligament
Cricothyroid joint
Cricoid cartilage
Cricovocal membrane (lateral
cricothyroid ligament, conus elasticus)
Trachea
Cricotracheal ligament

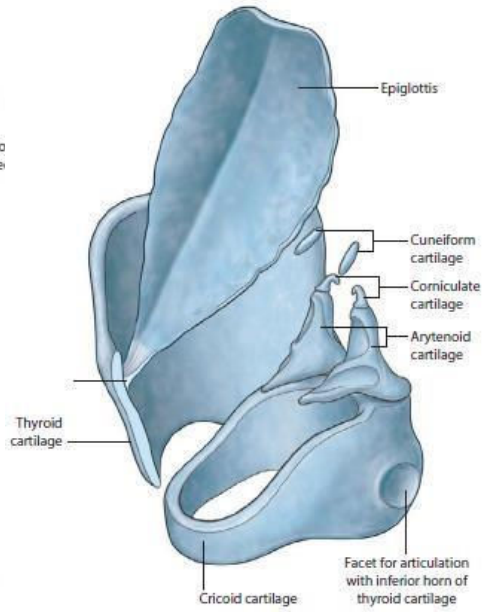
Epiglottis
Cuneiform
cartilage
Corniculate
cartilage
Arytenoid
cartilage
Thyroid
cartilage
Cricoid cartilage
Facet for articulation
with inferior horn of
thyroid cartilage



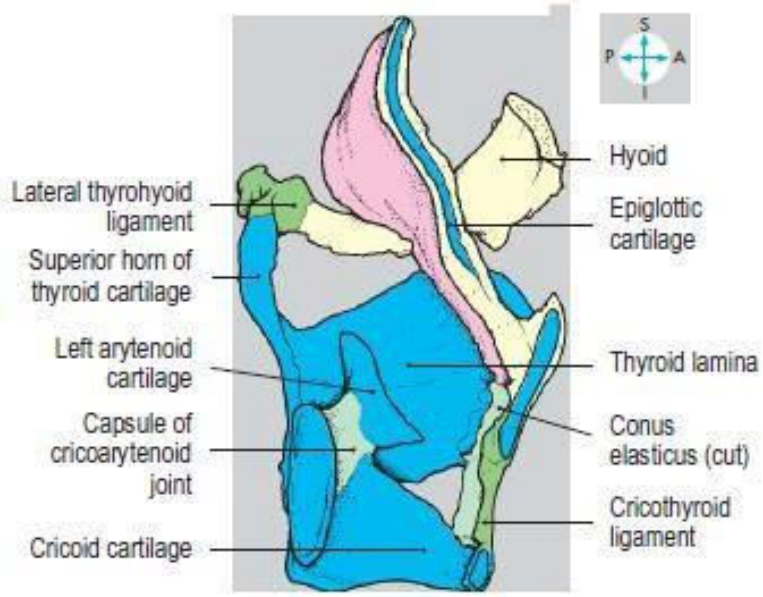
S
P
A
Hyoid
Epiglottic cartilage
Lateral thyrohyoid ligament
Superior horn of thyroid cartilage
Left arytenoid cartilage
Thyroid lamina
Capsule of cricoarytenoid joint
Conus elasticus (cut)
Cricothyroid ligament
Cricoid cartilage

Larynx, skeleton:

1 Hyoid bone

2 Epiglottis

3 Thyroid cartilage

4 Arytenoid c

5 Cricoid arch

6 Cricoid lamina

7 Conus elasticus

8 Cricothyroid ligament

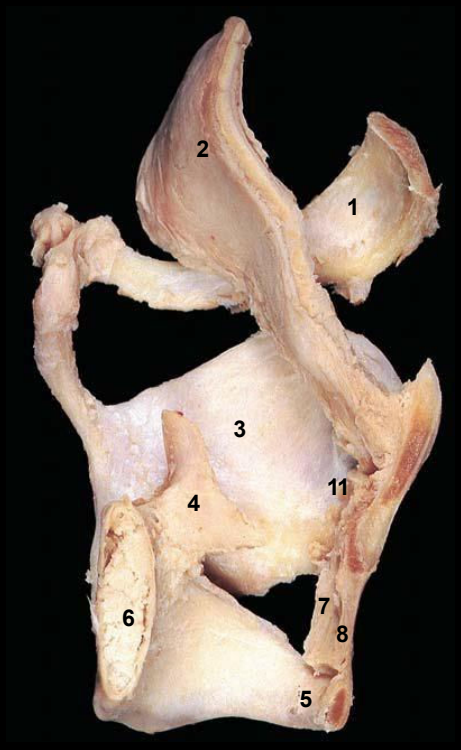

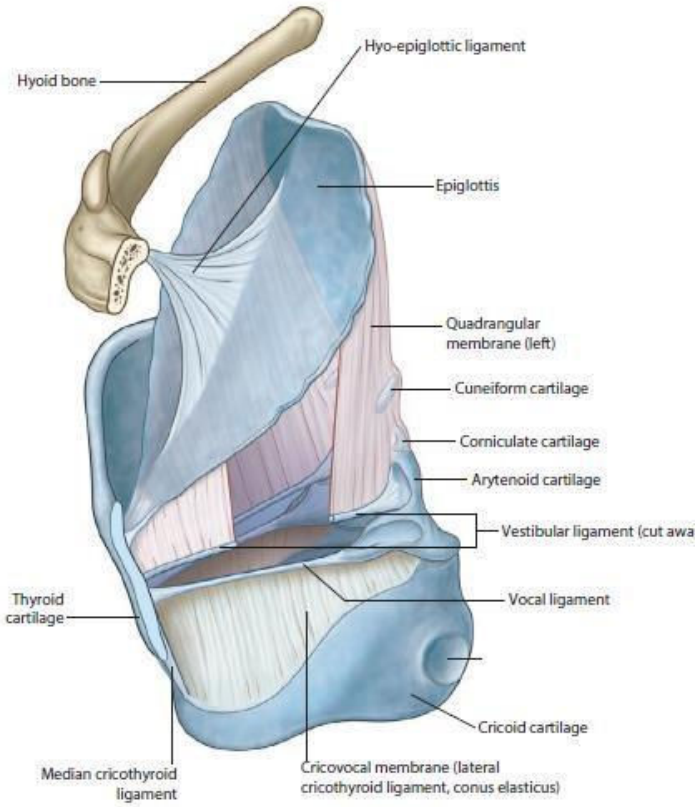
Hyo-epiglottic ligament
Hyoid bone
Epiglottis
Quadrangular membrane (left)
Cuneiform cartilage
Corniculate cartilage
Arytenoid cartilage
Vestibular ligament (cut awa
Vocal ligament
Thyroid cartilage
Cricoid cartilage
Median cricothyroid ligament
Cricovocal membrane (lateral cricothyroid ligament, conus elasticus)

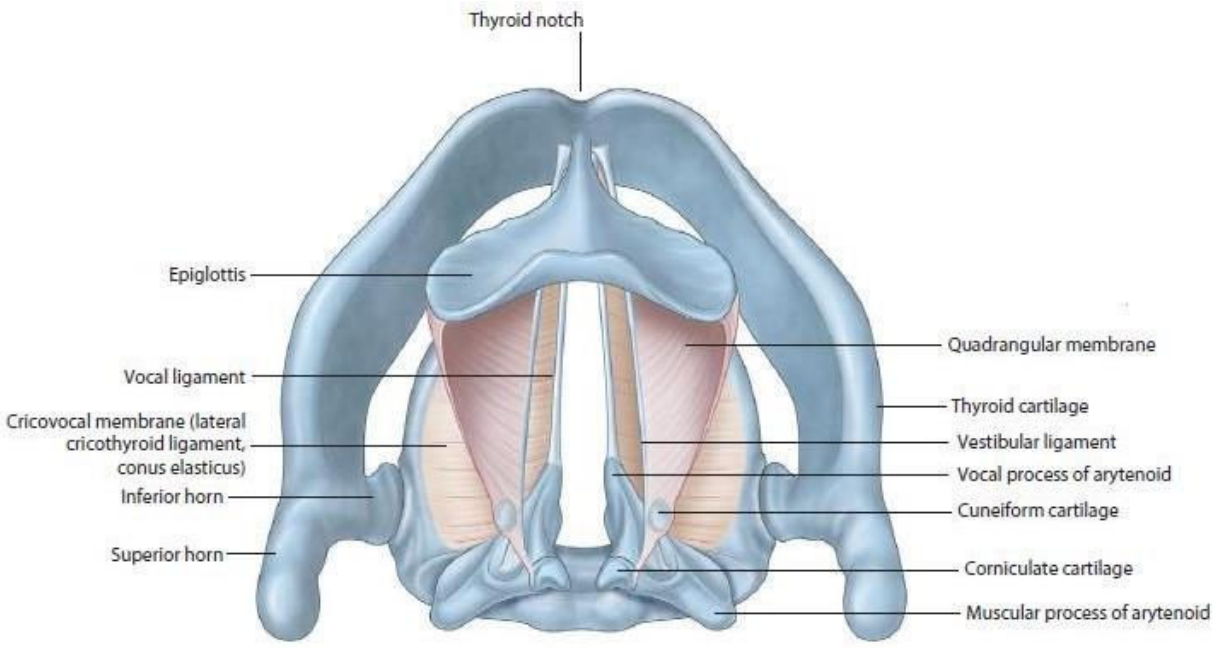

Fibro-elastic membrane of the larynx (superior view)

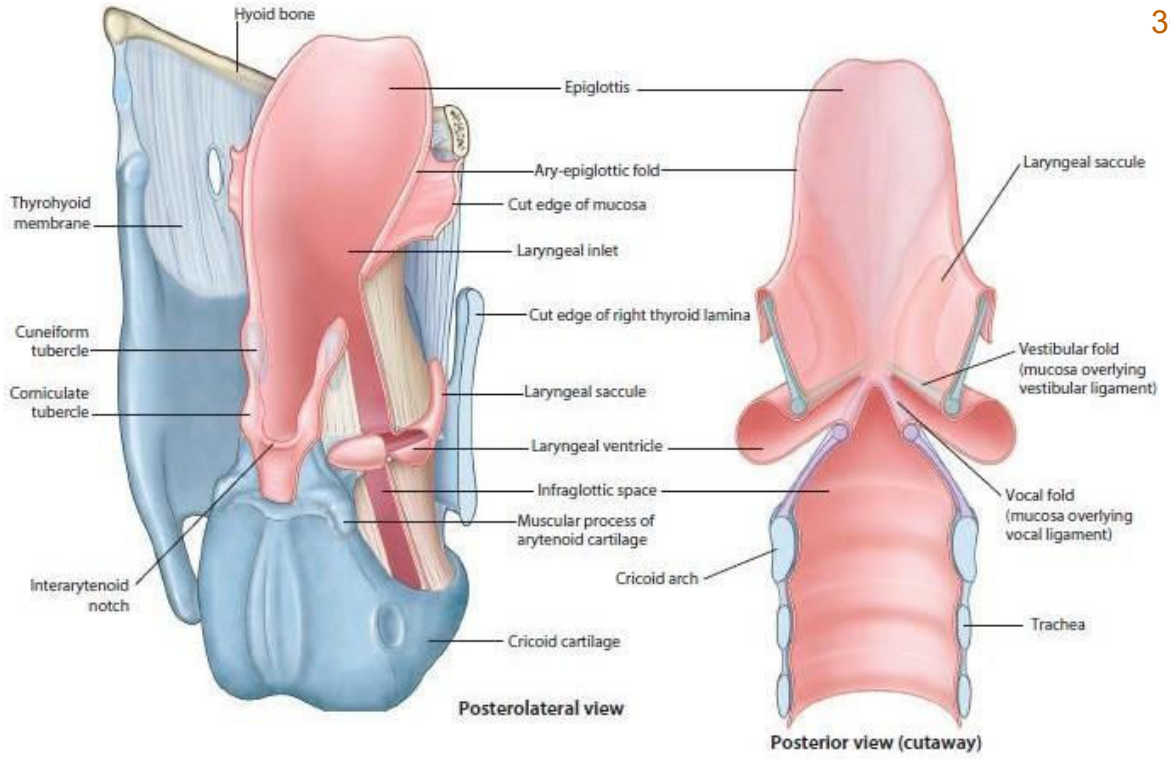
Hyoid bone
Epiglottis
Ary-epiglottic fold
Cut edge of mucosa
Thyrohyoid membrane
Laryngeal inlet
Cut edge of right thyroid lamina
Cuneiform tubercle
Corniculate tubercle
Laryngeal saccule
Laryngeal ventricle
Infraglottic space
Muscular process of arytenoid cartilage
Interarytenoid notch
Cricoid cartilage
Posterolateral view
Laryngeal saccule
Vestibular fold (mucosa overlying vestibular ligament)
Vocal fold (mucosa overlying vocal ligament)
Cricoid arch
Trachea
Posterior view (cutaway)

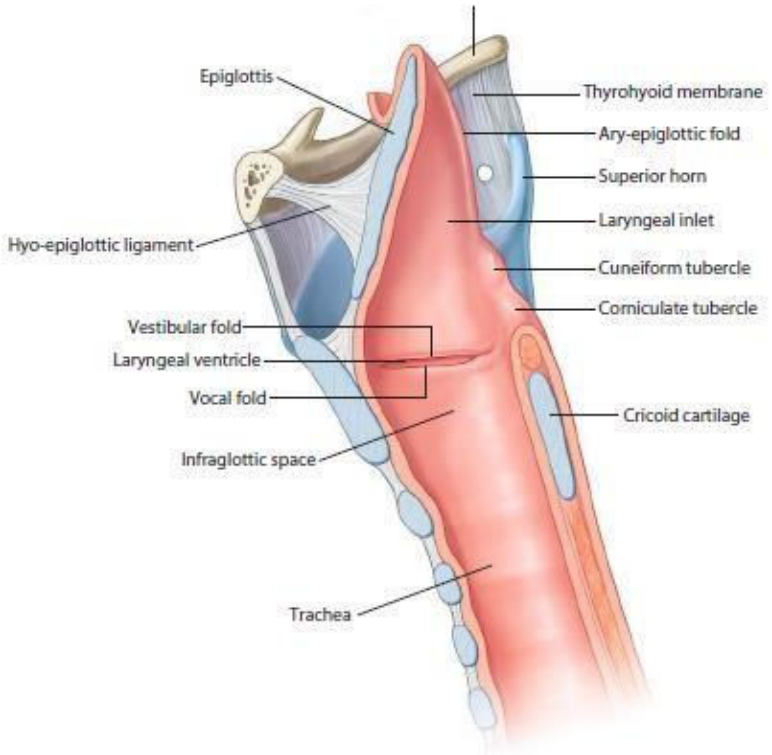
Epiglottis
Thyrohyoid membrane
Ary-epiglottic fold
Superior horn
Laryngeal inlet
Hyo-epiglottic ligament
Cuneiform tubercle
Corniculate tubercle
Vestibular fold
Laryngeal ventricle
Vocal fold
Cricoid cartilage
Infraglottic space
Trachea



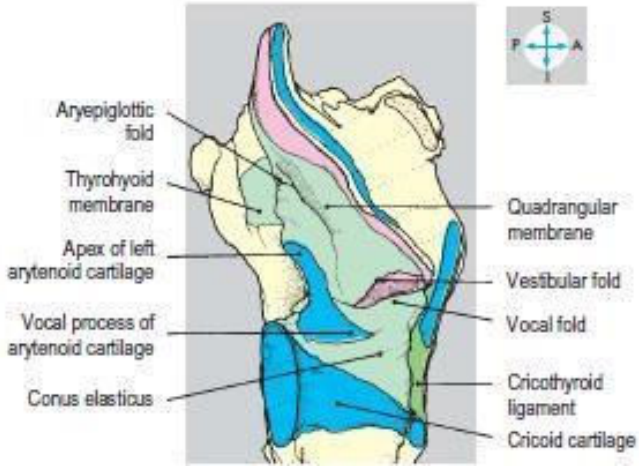
S
P
A
I
Aryepiglottic fold
Thyrohyoid membrane
Apex of left arytenoid cartilage
Vocal process of arytenoid cartilage
Conus elasticus
Quadrangular membrane
Vestibular fold
Vocal fold
Cricothyroid ligament
Cricoid cartilage

Larynx, lateral view, membranes:

1 Hyoid bone

2 Epiglottis

3 Thyroid cartilage

4 Arytenoid c

5 Quadrate membrane

6 Vestibular fold

7 Vocal cord

8 Ventricle

9 Cricoid arch

10 Cricoid lamina

11 Conus elasticus

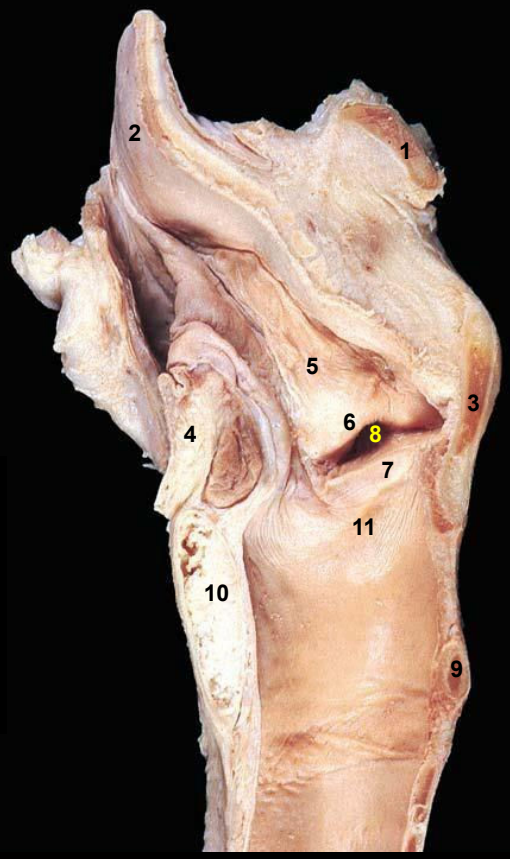



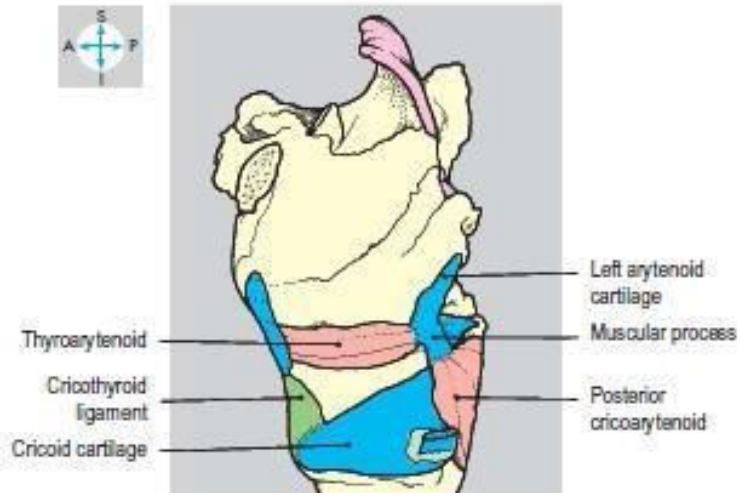
S
A
P
Left arytenoid cartilage
Muscular process
Thyroarytenoid
Cricothyroid ligament
Posterior cricoarytenoid
Cricoid cartilage



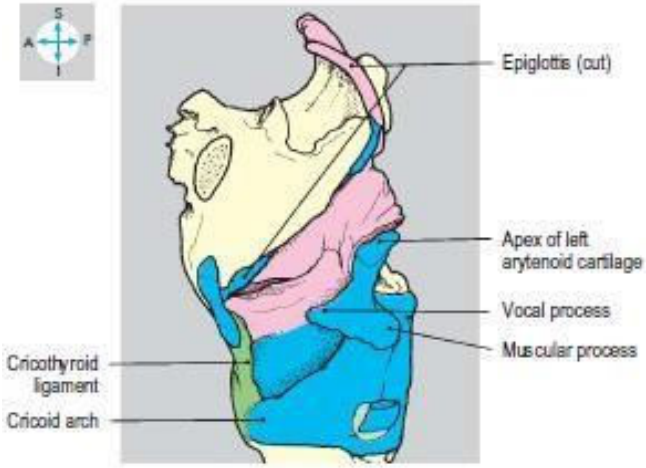
S
A
P
I
Epiglottis (cut)
Apex of left arytenoid cartilage
Vocal process
Muscular process
Cricothyroid ligament
Cricoid arch



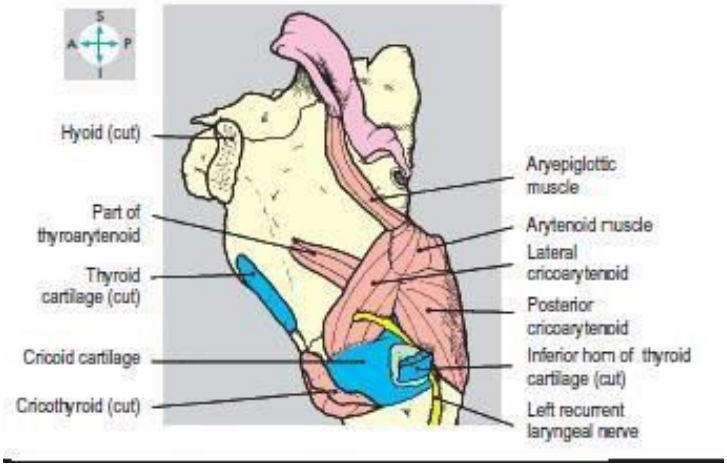
S
A
P
I
Hyoid (cut)
Part of thyroarytenoid
Thyroid cartilage (cut)
Cricoid cartilage
Cricothyroid (cut)
Aryepiglottic muscle
Arytenoid muscle
Lateral cricoarytenoid
Posterior cricoarytenoid
Inferior horn of thyroid cartilage (cut)
Left recurrent laryngeal nerve

Larynx, lateral view, muscles:

1 Aryepiglottic m

2 Thyroarytenoid

3 Lateral cricoarytenoid

4 Transverse arytenoid

5 Posterior cricoarytenoid

6 Cricothyroid



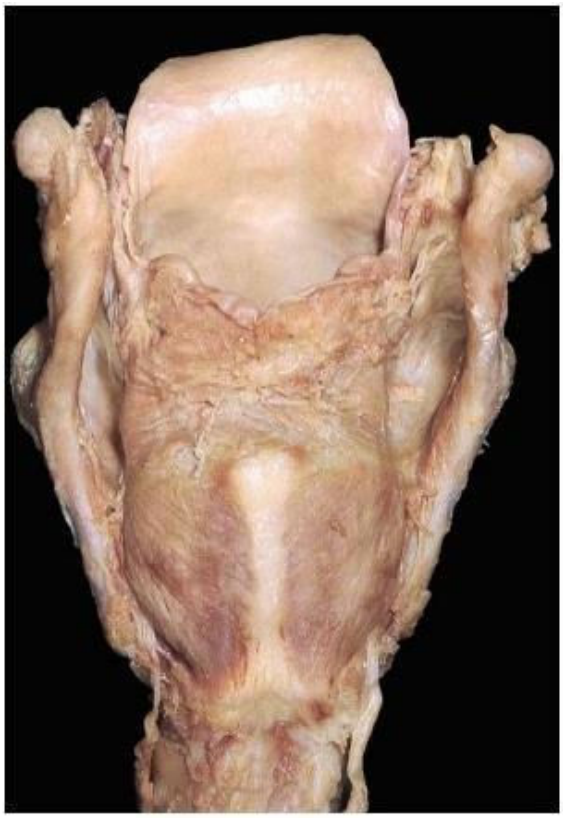

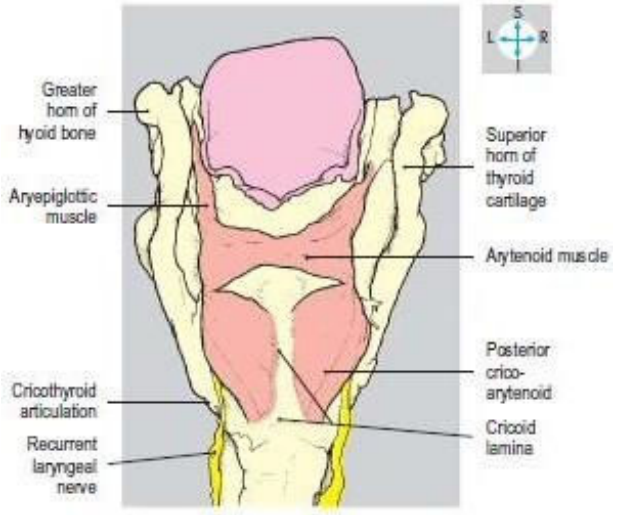
S
L
R
Greater horn of hyoid bone
Aryepiglottic muscle
Cricothyroid articulation
Recurrent laryngeal nerve
Superior horn of thyroid cartilage
Arytenoid muscle
Posterior crico-arytenoid
Cricoid lamina

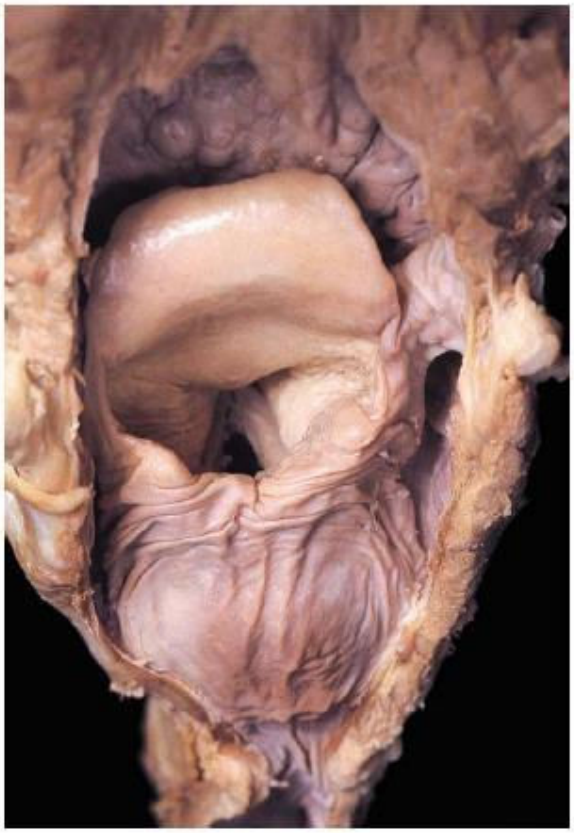

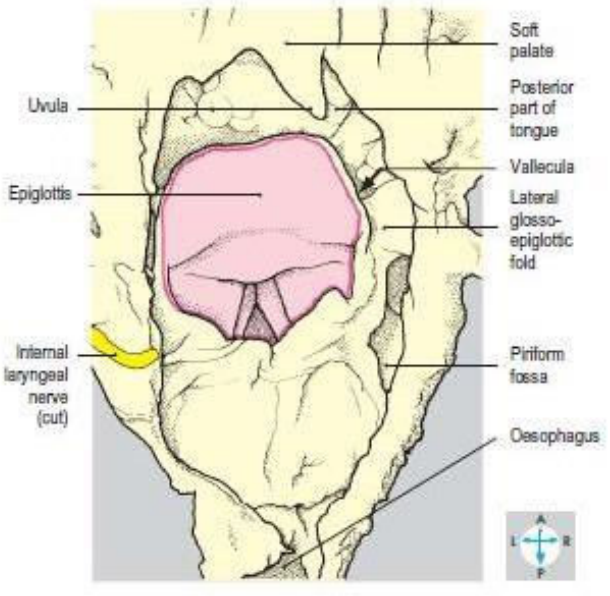
Soft palate
Uvula
Posterior part of tongue
Vallecula
Epiglottis
Lateral glosso-epiglottic fold
Internal laryngeal nerve (cut)
Piriform fossa
Oesophagus
A
L
R
P

Larynx, posterosuperior view:

1 Uvula

2 Tongue

3 Vallecula

4 Lateral glossoepiglottic fold

5 Epiglottis

6 Vestibular fold

7 Vocal cord

8 Piriform fossa

9 Internal laryngeal n

10 Esophagus

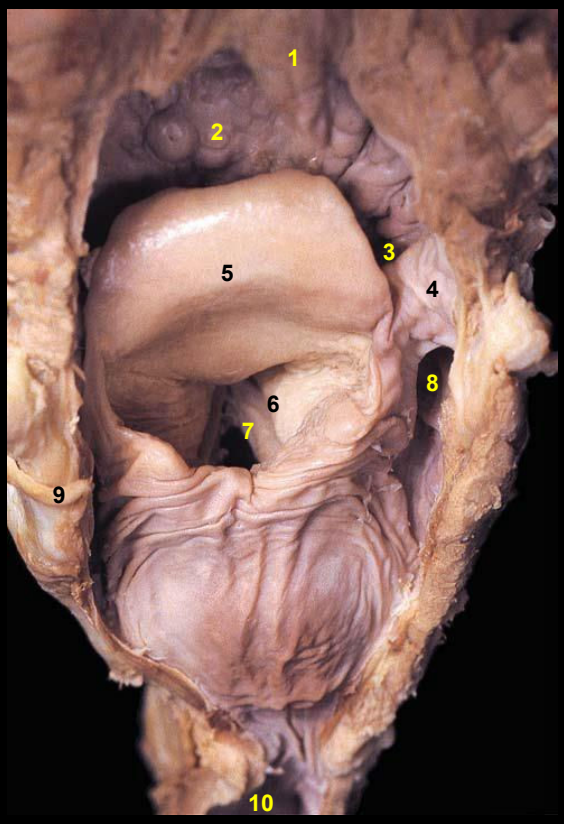

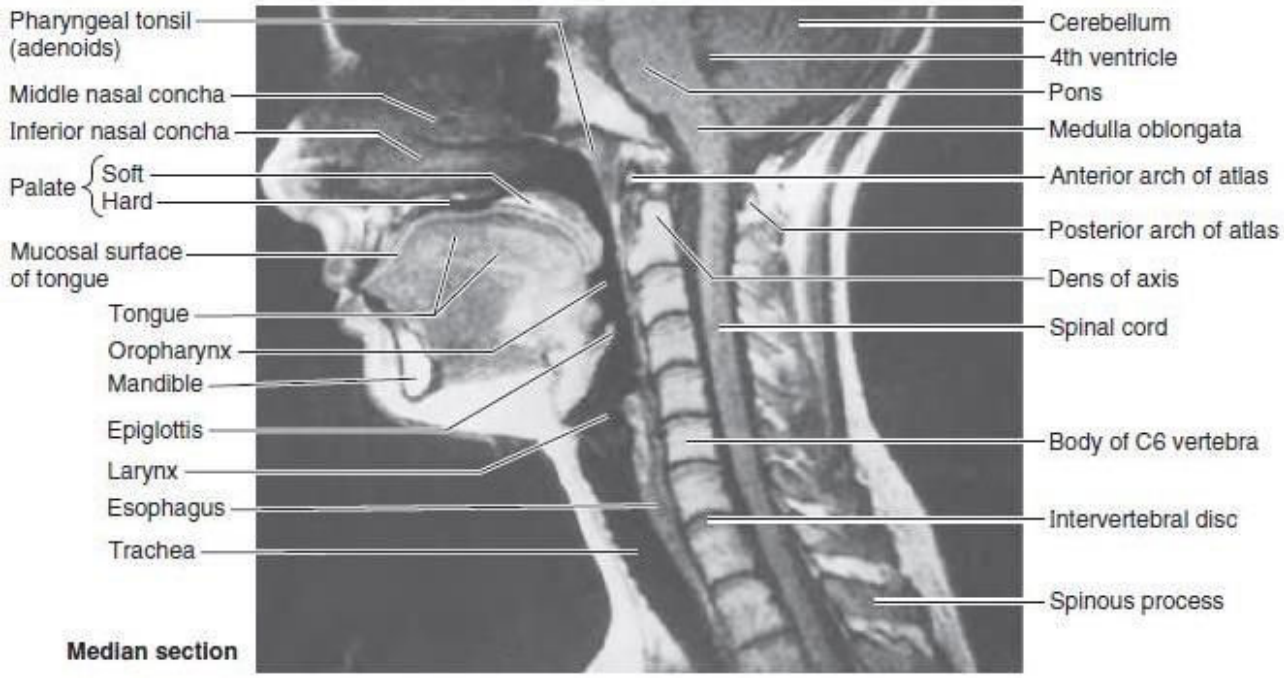
Pharyngeal tonsil (adenoids)
Middle nasal concha
Inferior nasal concha
Palate
Soft
Hard
Mucosal surface of tongue
Tongue
Oropharynx
Mandible
Epiglottis
Larynx
Esophagus
Trachea
Median section
Cerebellum
4th ventricle
Pons
Medulla oblongata
Anterior arch of atlas
Posterior arch of atlas
Dens of axis
Spinal cord
Body of C6 vertebra
Intervertebral disc
Spinous process



Clinical notes



Laryngeoscope
A- DIRECT
B-INDIRECT

A

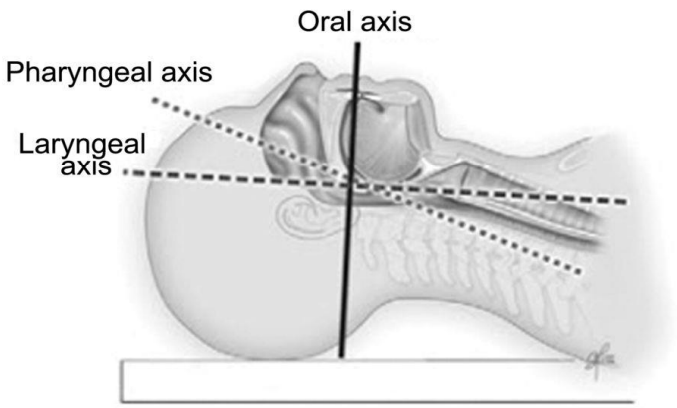

B

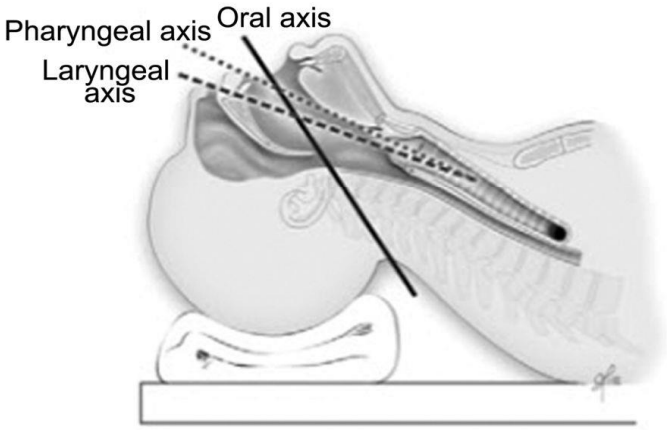

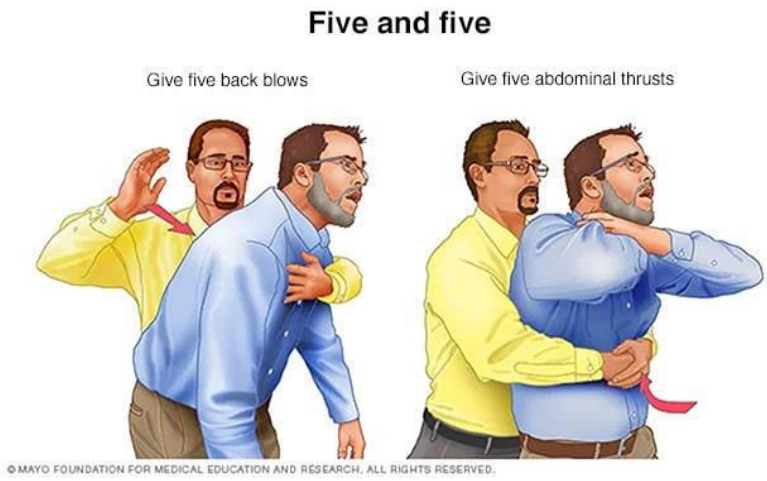
Five and five
Give five back blows
Give five abdominal thrusts
© MAYO FOUNDATION FOR MEDICAL EDUCATION AND RESEARCH. ALL RIGHTS RESERVED.






Neck Mass
Thyroglossal
Duct Cyst