Base of the Skull

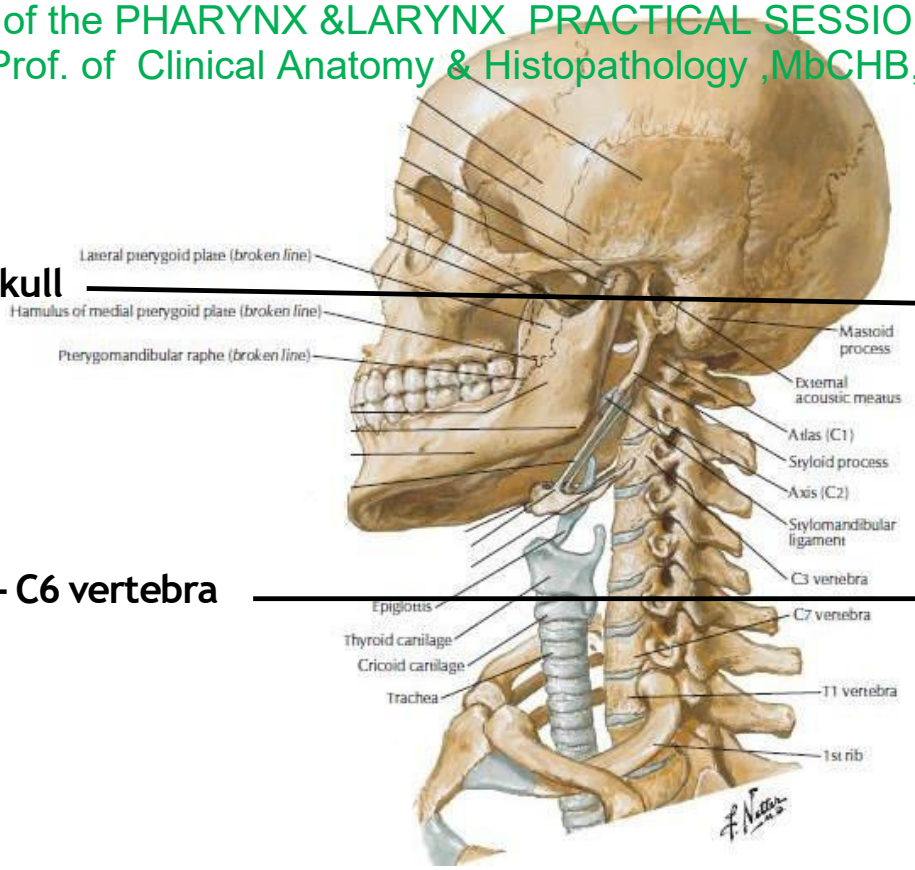

cricoid level - C6 vertebra

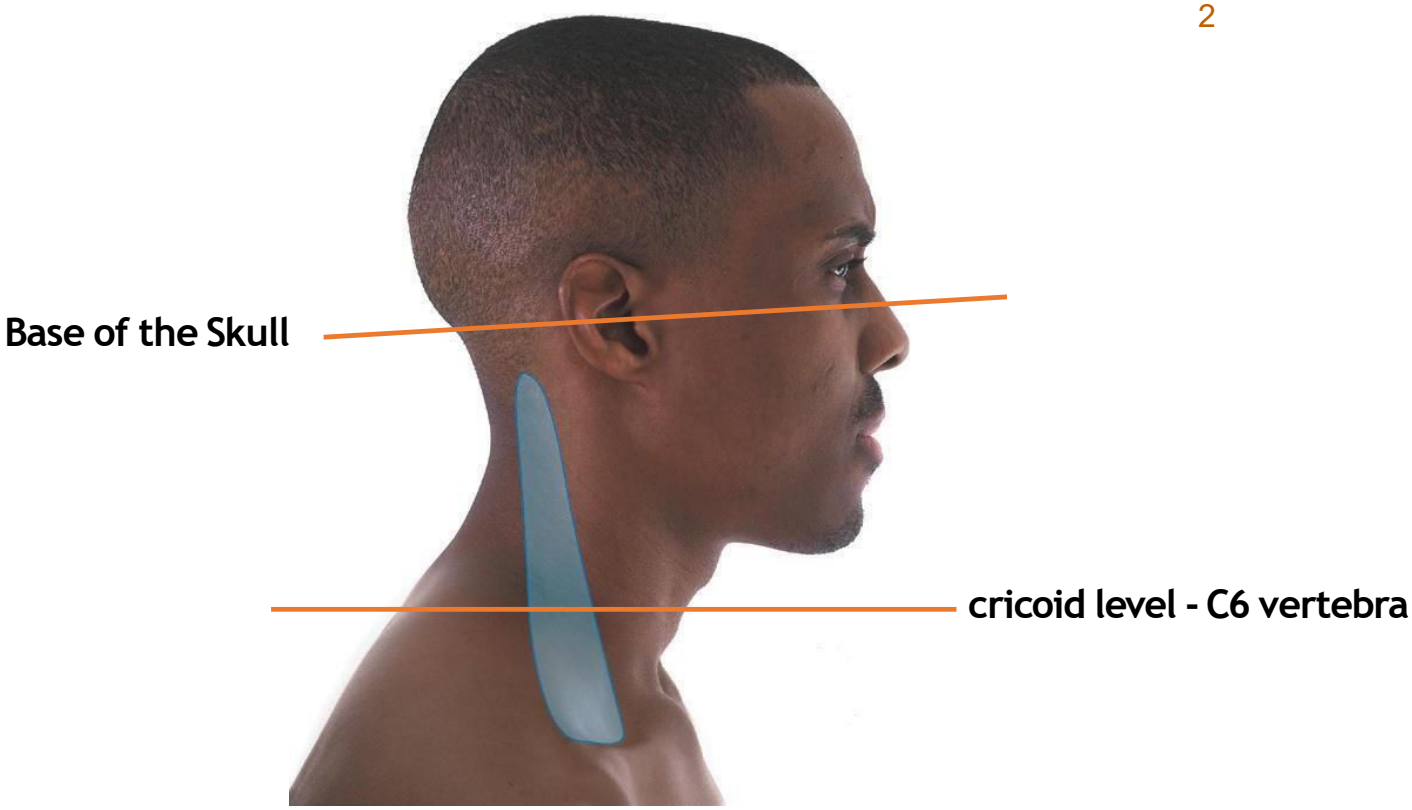
Base of the Skull
cricoid level - C6 vertebra

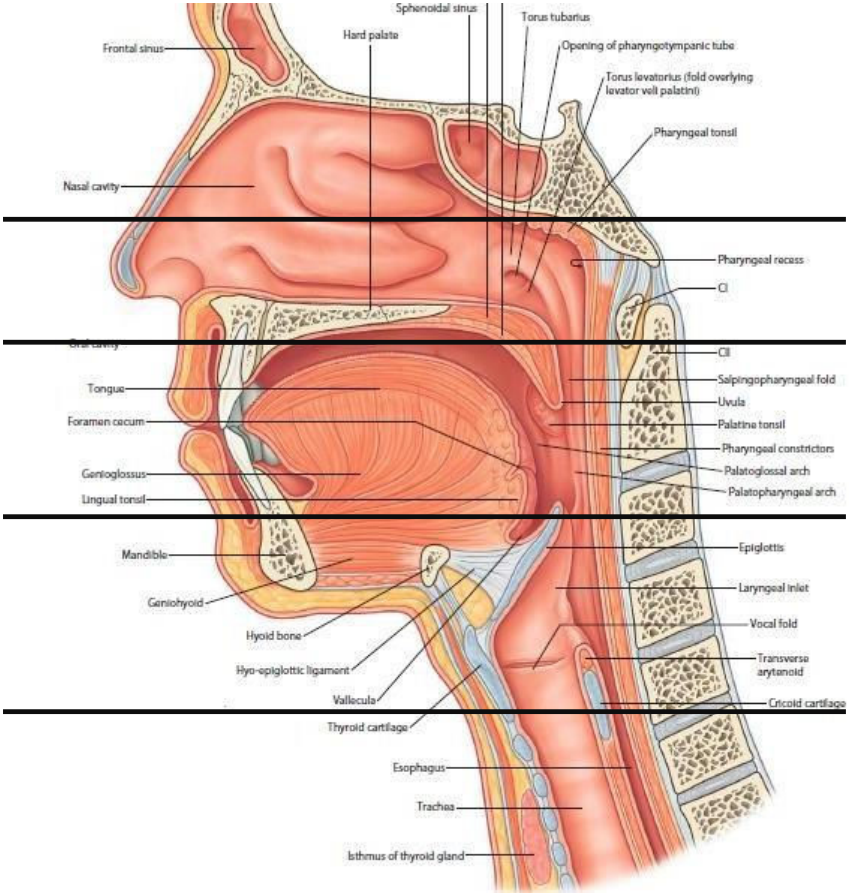
Sphenoidal sinus
Torus tubarius
Frontal sinus
Hard palate
Opening of pharyngotympanic tube
Torus levatorius (fold overlying levator veli palatini)
Pharyngeal tonsil
Nasal cavity
Pharyngeal recess
CI
CII
Tongue
Salpingopharyngeal fold
Uvula
Foramen cecum
Palatine tonsil
Pharyngeal constrictors
Genioglossus
Palatoglossal arch
Lingual tonsil
Palatopharyngeal arch
Mandible
Epiglottis
Laryngeal inlet
Geniohyoid
Vocal fold
Hyoid bone
Transverse arytanoid
Hyo-epiglottic ligament
Vallecula
Cricoid cartilage
Thyroid cartilage
Esophagus
Trachea
Isthmus of thyroid gland

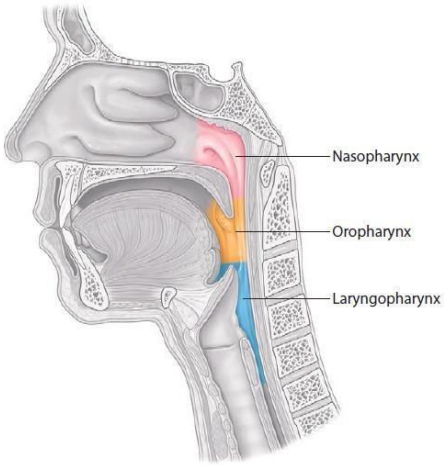
Nasopharynx
Oropharynx
Laryngopharynx

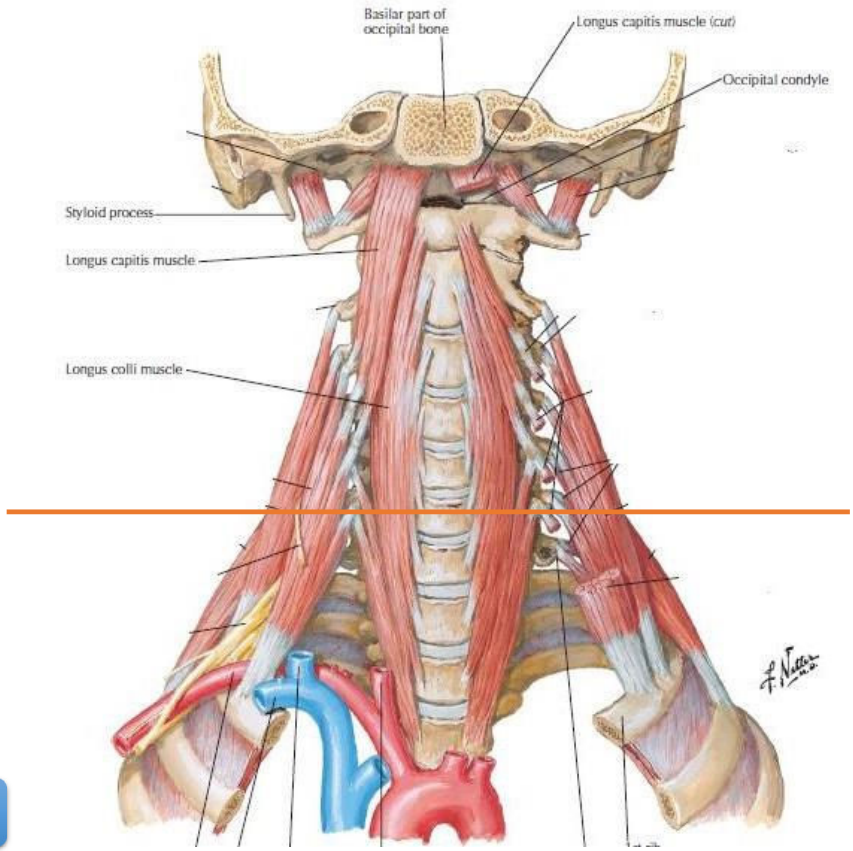

Posteriorly

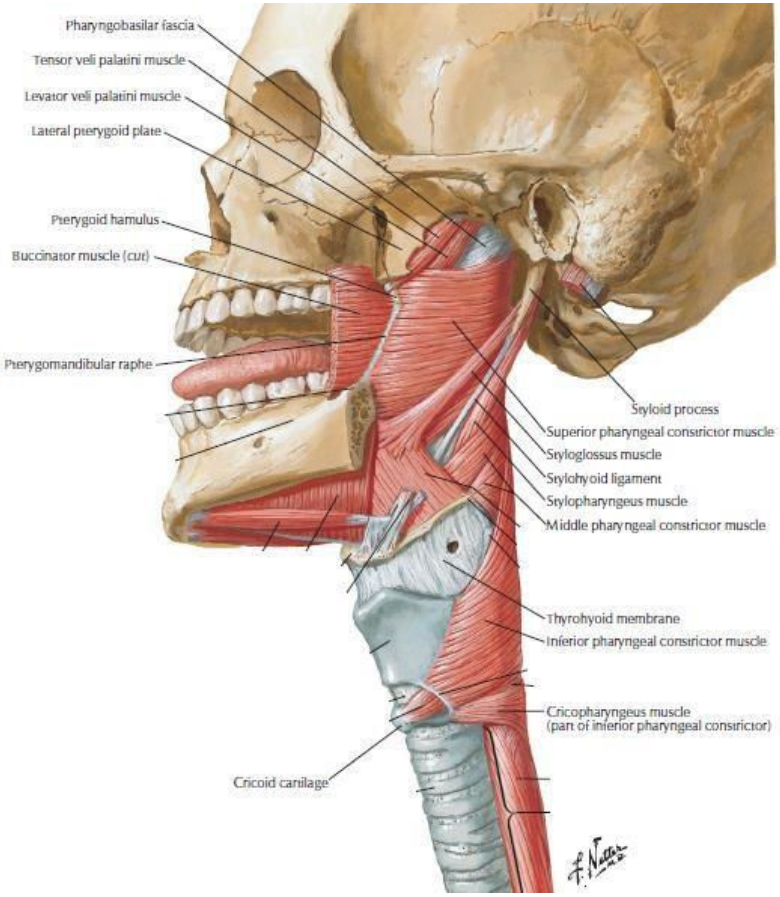
Pharyngobasilar fascia
Tensor veli palatini muscle
Levator veli palatini muscle
Lateral pterygoid plate
Pterygoid hamulus
Buccinator muscle (cut)
Pterygomandibular raphe
Styloid process
Superior pharyngeal constrictor muscle
Styloglossus muscle
Stylohyoid ligament
Stylopharyngeus muscle
Middle pharyngeal constrictor muscle
Thyrohyoid membrane
Inferior pharyngeal constrictor muscle
Cricopharyngeus muscle
(part of inferior pharyngeal constrictor)
Cricoid cartilage

Pharyngeal wall

1 Pharyngobasilar fascia

2 Superior constrictor

3 Middle constrictor

4 Inferior constrictor-thyropharyng

5 IC-cricopharyngeus

6 Stylopharyngeus

7 Salpingopharyngeus

8 Buccinator

9 Pterygomandibular raphe

10 Styloglossus

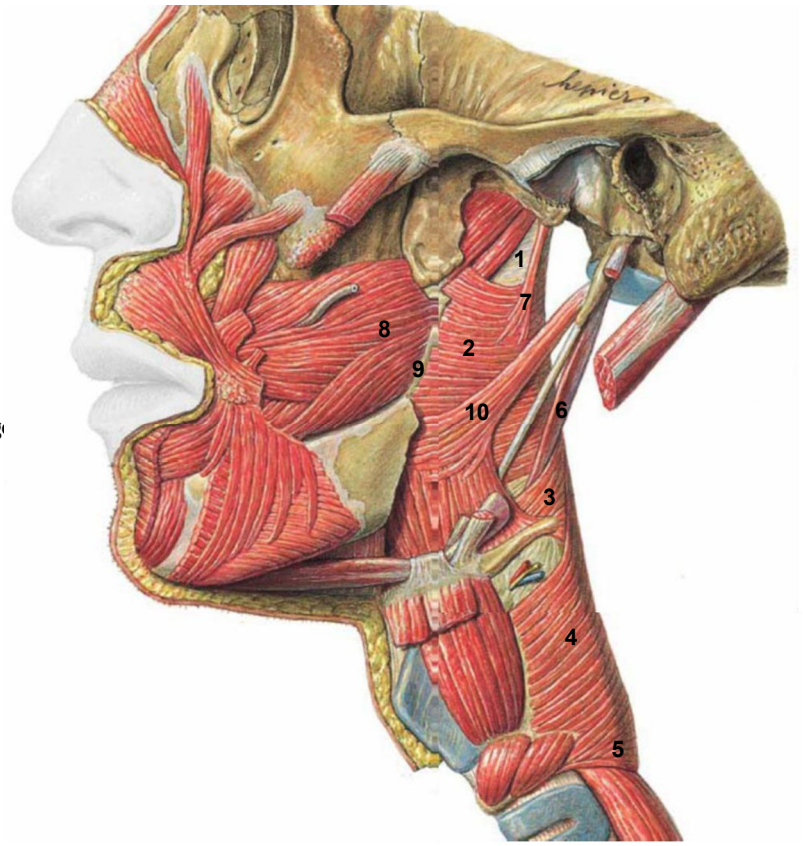

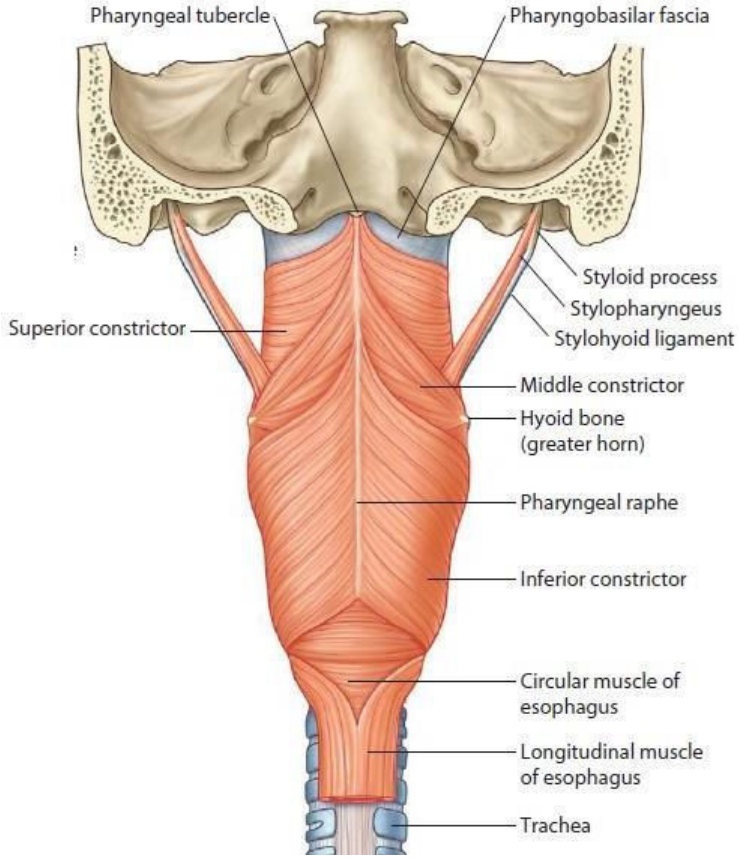
Pharyngeal tubercle
Pharyngobasilar fascia
Styloid process
Stylopharyngeus
Stylohyoid ligament
Superior constrictor
Middle constrictor
Hyoid bone
(greater horn)
Pharyngeal raphe
Inferior constrictor
Circular muscle of
esophagus
Longitudinal muscle
of esophagus
Trachea


one
two
three
3

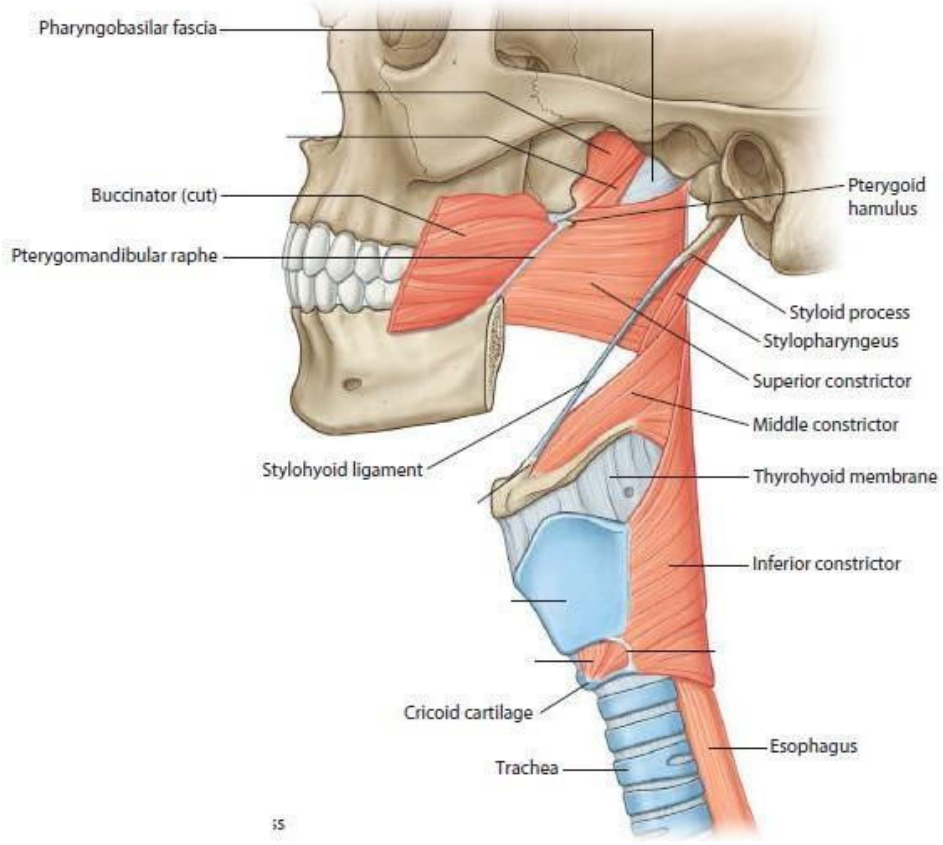
Pharyngobasilar fascia
Buccinator (cut)
Pterygomandibular raphe
Pterygoid hamulus
Styloid process
Stylopharyngeus
Superior constrictor
Middle constrictor
Stylohyoid ligament
Thyrohyoid membrane
Inferior constrictor
Cricoid cartilage
Esophagus
Trachea

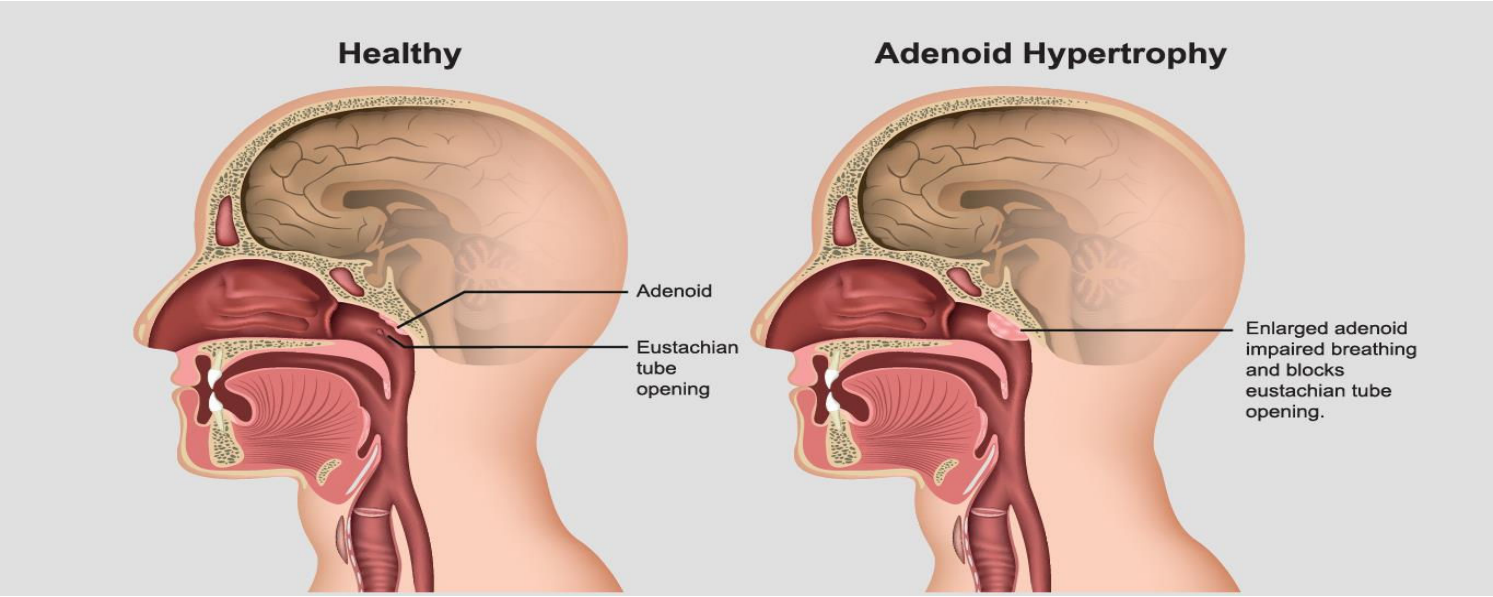
Healthy
Adenoid
Eustachian tube opening
Adenoid Hypertrophy
Enlarged adenoid impaired breathing and blocks eustachian tube opening.

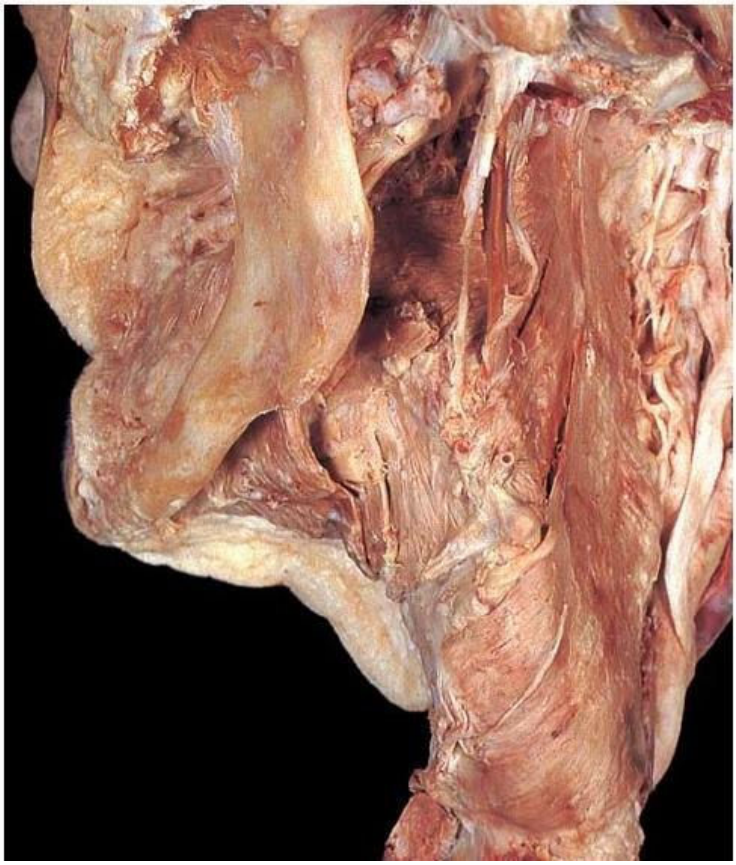

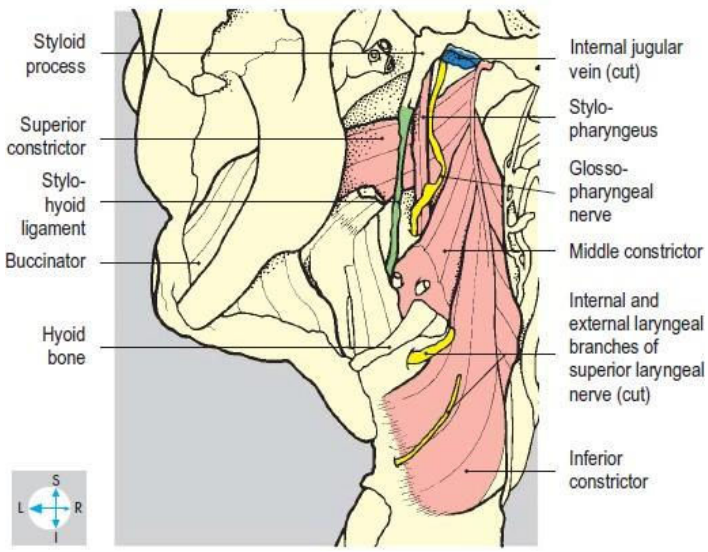
Styloid process
Superior constrictor
Stylo-hyoid ligament
Buccinator
Hyoid bone
Internal jugular vein (cut)
Stylo-pharyngeus
Glosso-pharyngeal nerve
Middle constrictor
Internal and external laryngeal branches of superior laryngeal nerve (cut)
Inferior constrictor
S
L
R
I

Pharyngeal wall

1 Pharyngobasilar fascia

2 Superior constrictor

3 Middle constrictor

4 Inferior constrictor-thyropharyngeus

5 IC-cricophryngeus

6 Stylopharyngeus

7 IX n

8 Buccinator

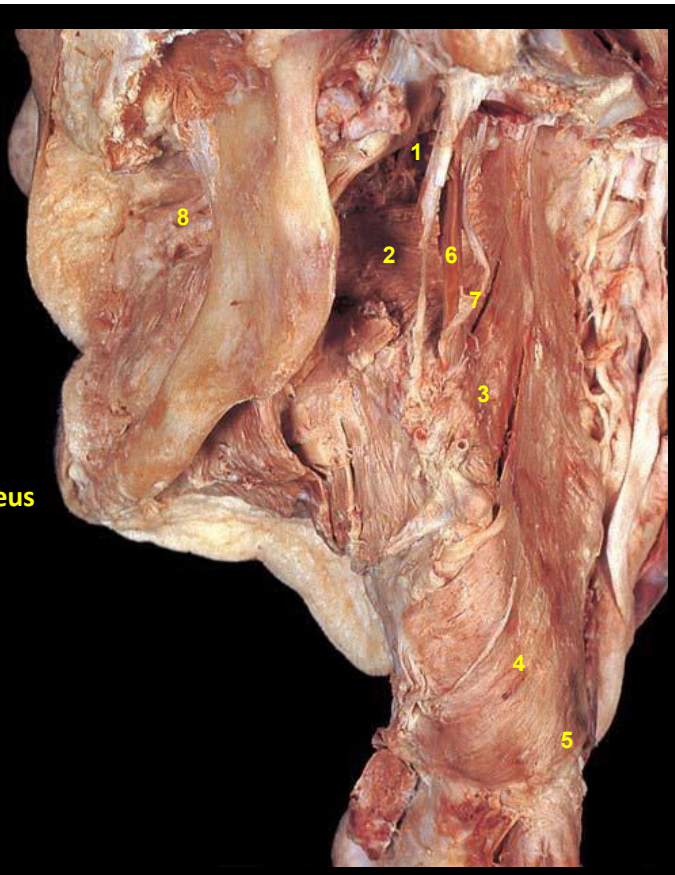

Tensor Veli Palatinin

levator veli palatini

Cartilaginous part of pharyngotympanic tube

Pharyngobasilar fascia

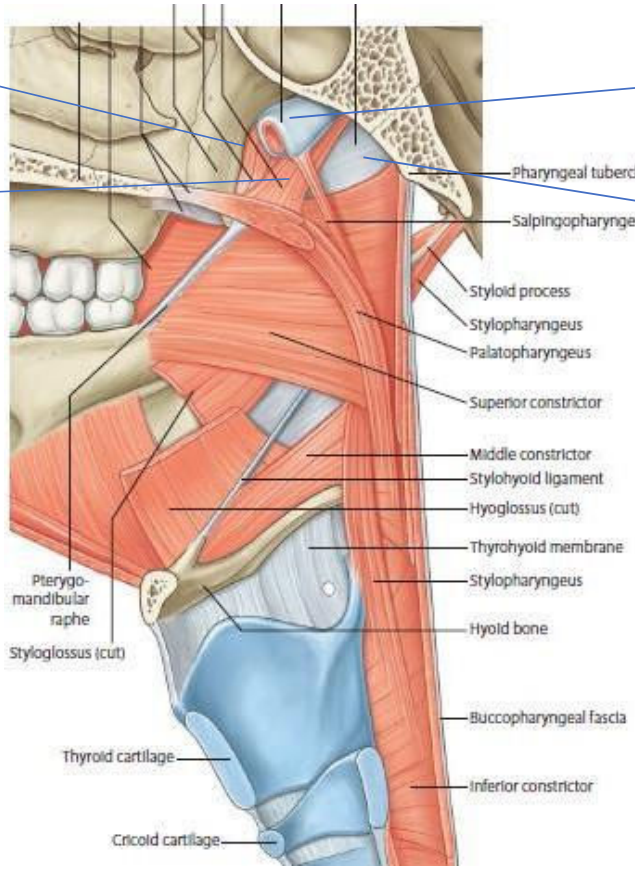

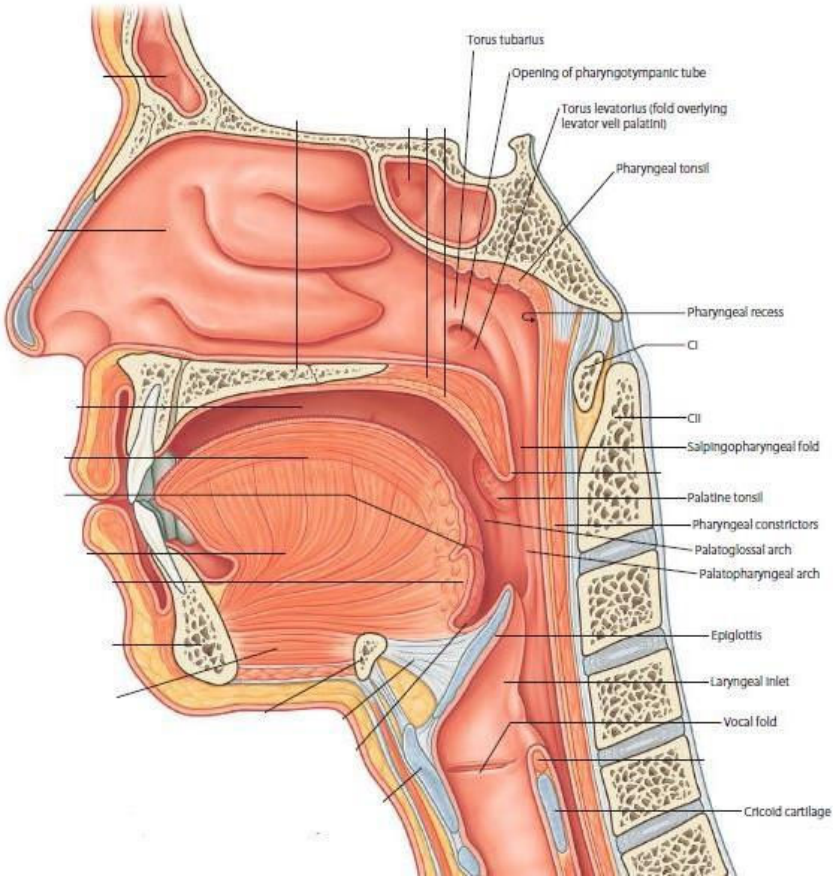
Torus tubarius
Opening of pharyngotympanic tube
Torus levatorius (fold overlying levator veli palatini)
Pharyngeal tonsil
Pharyngeal recess
CI
CII
Salpingopharyngeal fold
Palatine tonsil
Pharyngeal constrictors
Palatoglossal arch
Palatopharyngeal arch
Epiglottis
Laryngeal inlet
Vocal fold
Cricoid cartilage

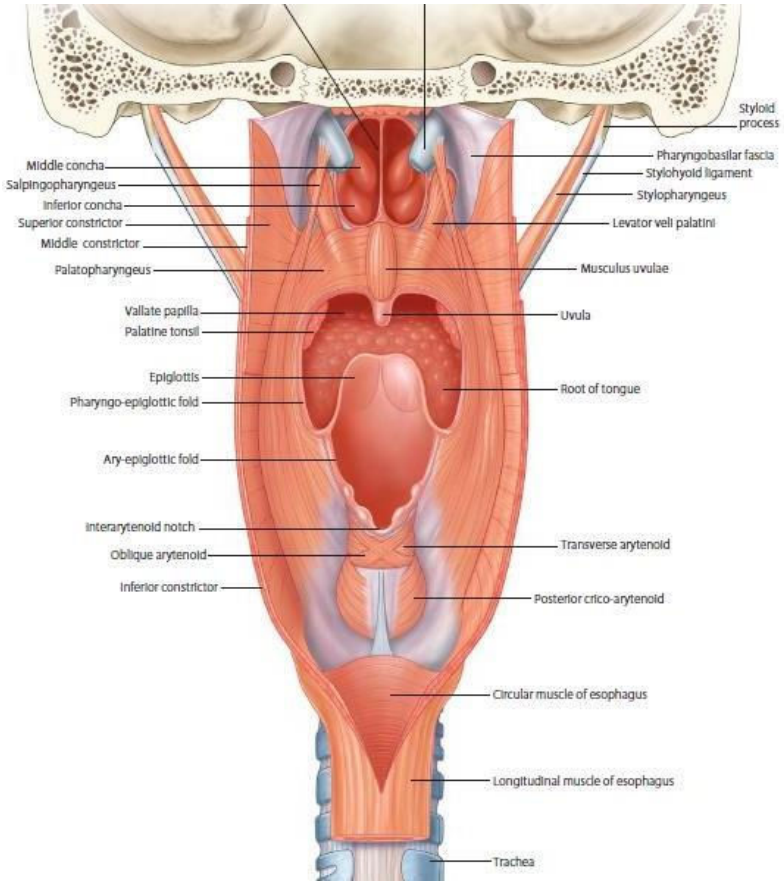
Styloid process
Middle concha
Salpingopharyngeus
Inferior concha
Superior constrictor
Middle constrictor
Palatopharyngeus
Pharyngobasilar fascia
Stylohyoid ligament
Stylopharyngeus
Levator veli palatini
Musculus uvulae
Vallate papilla
Palatine tonsil
Uvula
Epiglottis
Pharyngo-epiglottic fold
Root of tongue
Ary-epiglottic fold
Interarytenoid notch
Oblique arytenoid
Inferior constrictor
Transverse arytenoid
Posterior crico-arytenoid
Circular muscle of esophagus
Longitudinal muscle of esophagus
Trachea

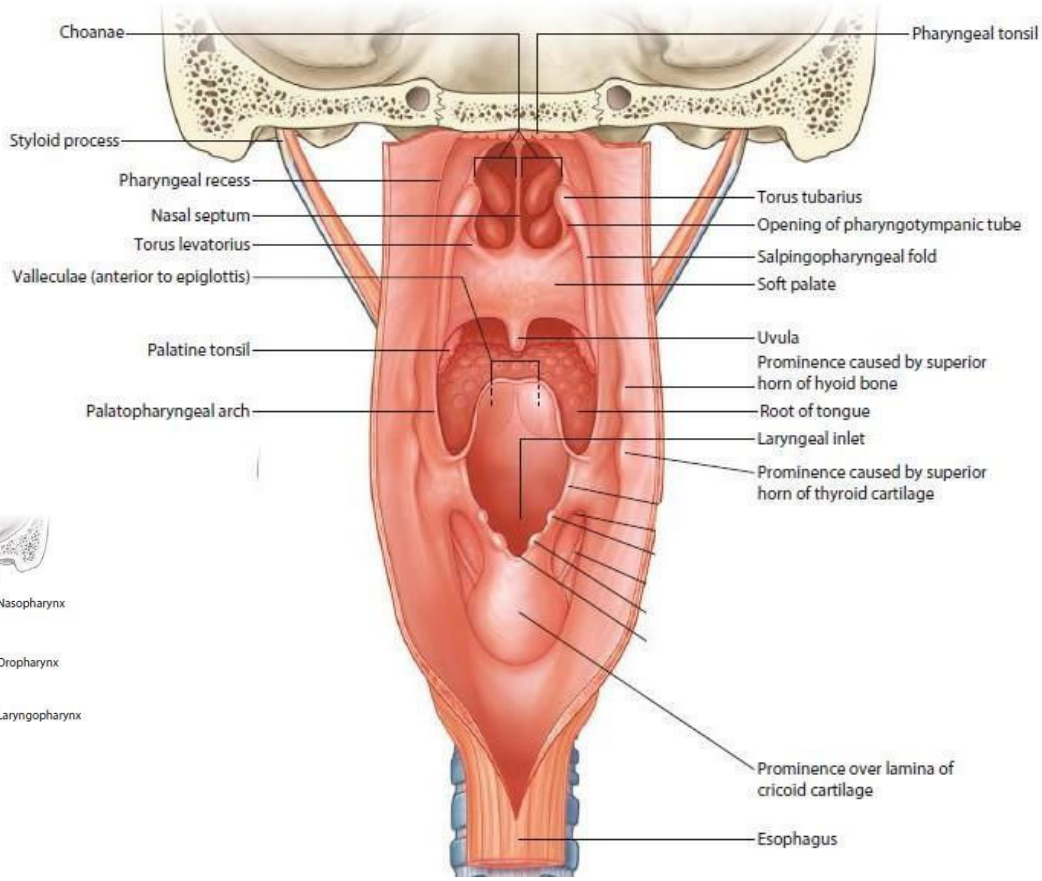
Choanae
Pharyngeal tonsil
Styloid process
Pharyngeal recess
Nasal septum
Torus levatorius
Valleculae (anterior to epiglottis)
Palatine tonsil
Palatopharyngeal arch
Torus tubarius
Opening of pharyngotympanic tube
Salpingopharyngeal fold
Soft palate
Uvula
Prominence caused by superior horn of hyoid bone
Root of tongue
Laryngeal inlet
Prominence caused by superior horn of thyroid cartilage
Prominence over lamina of cricoid cartilage
Esophagus

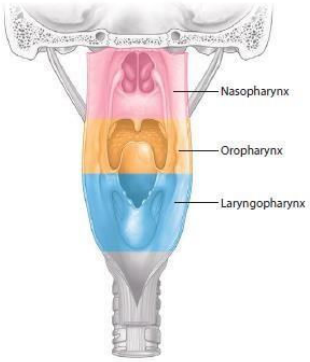
Nasopharynx
Oropharynx
Laryngopharynx

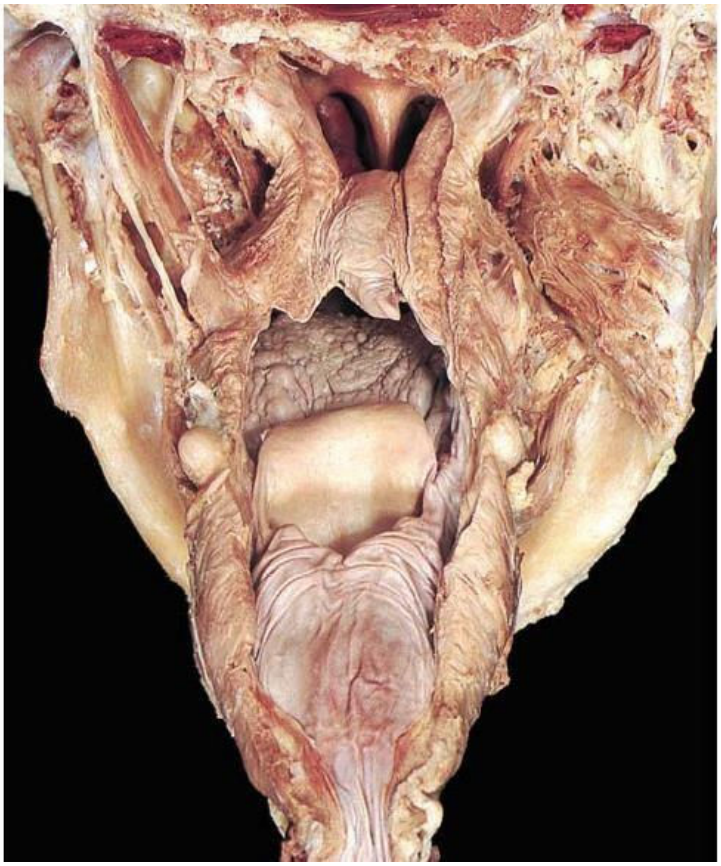

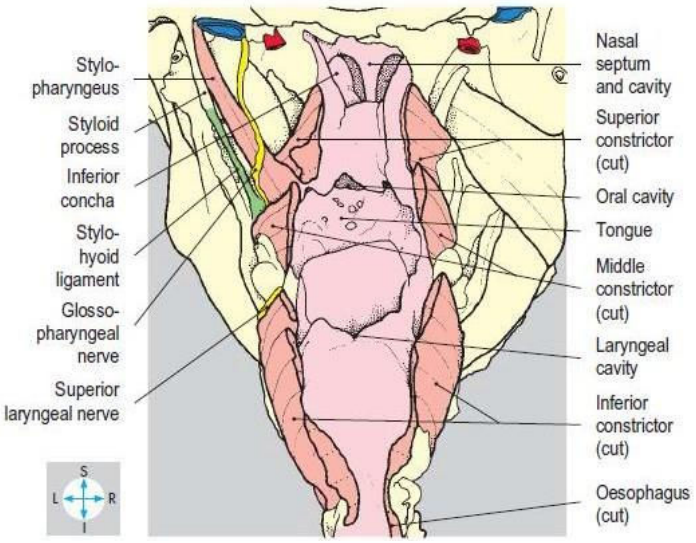
Stylo-pharyngeus
Styloid process
Inferior concha
Stylo-hyoid ligament
Glosso-pharyngeal nerve
Superior laryngeal nerve
Nasal septum and cavity
Superior constrictor (cut)
Oral cavity
Tongue
Middle constrictor (cut)
Laryngeal cavity
Inferior constrictor (cut)
Oesophagus (cut)
S
L
R
I

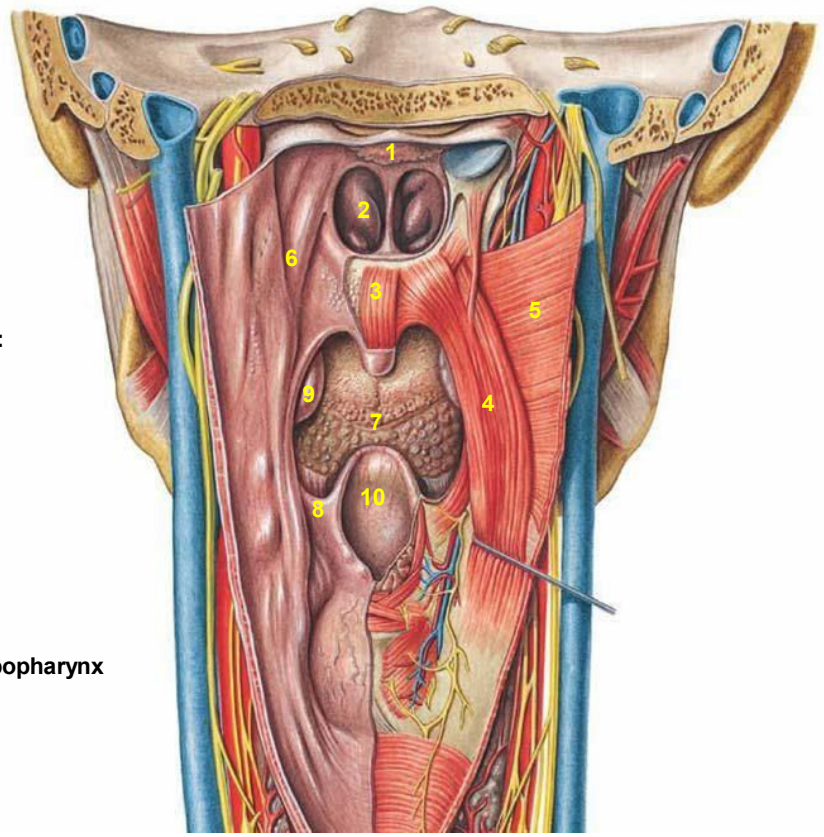

Interior of pharynx, posterior view:

1 Pharyngeal tonsil

2 Inferior concha nasal cavity

3 Uvula muscularis

4 Palatopharyngeus

5 Superior constrictor

6 Salpingopharyngeal fold

7 Tongue, oropharynx

8 Lateral glossoepiglottic fold, hypopharynx

9 Palatine tonsil

10 Epiglottis

Interior of pharynx, posterior view:

1 Pharyngeal tonsil

2 Inferior concha nasal cavity

3 Uvula muscularis

4 S constrictor

5 M constrictor

6 I constrictor

7 Tongue, oropharynx

8 IX n

9 Stylopharyngeus

10 Epiglottis

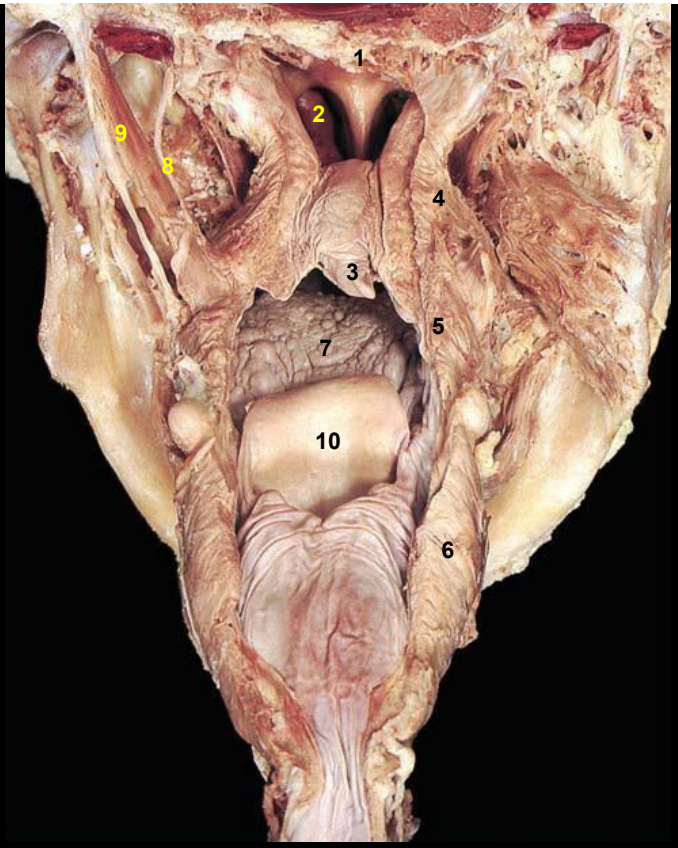

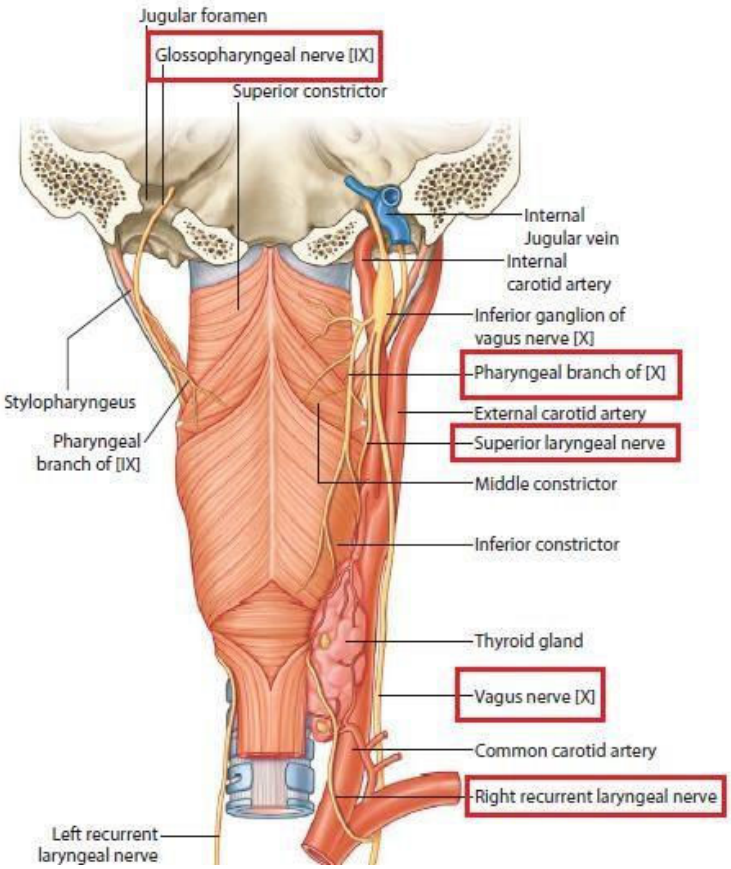
Jugular foramen
Glossopharyngeal nerve [IX]
Superior constrictor
Internal Jugular vein
Internal carotid artery
Inferior ganglion of vagus nerve [X]
Pharyngeal branch of [X]
External carotid artery
Superior laryngeal nerve
Middle constrictor
Inferior constrictor
Thyroid gland
Vagus nerve [X]
Common carotid artery
Right recurrent laryngeal nerve
Stylopharyngeus
Pharyngeal branch of [IX]
Left recurrent laryngeal nerve

Pharynx, posterior view:

1 IJV

2 ICA

3 X n

4 Pharyngeal branch X

5Superior laryngeal br X

6 Recurrent laryngeal br X

7 Ascending pharyngeal a

8 Superior constrictor

9 Middle constrictor

10 Inferior constrictor

11 Pharyngeal raphe

12 Cricopharyngeus

13 Esophagus

14 Pharyngeal plexus

15Thyroid gland

16 Sympathetic trunk

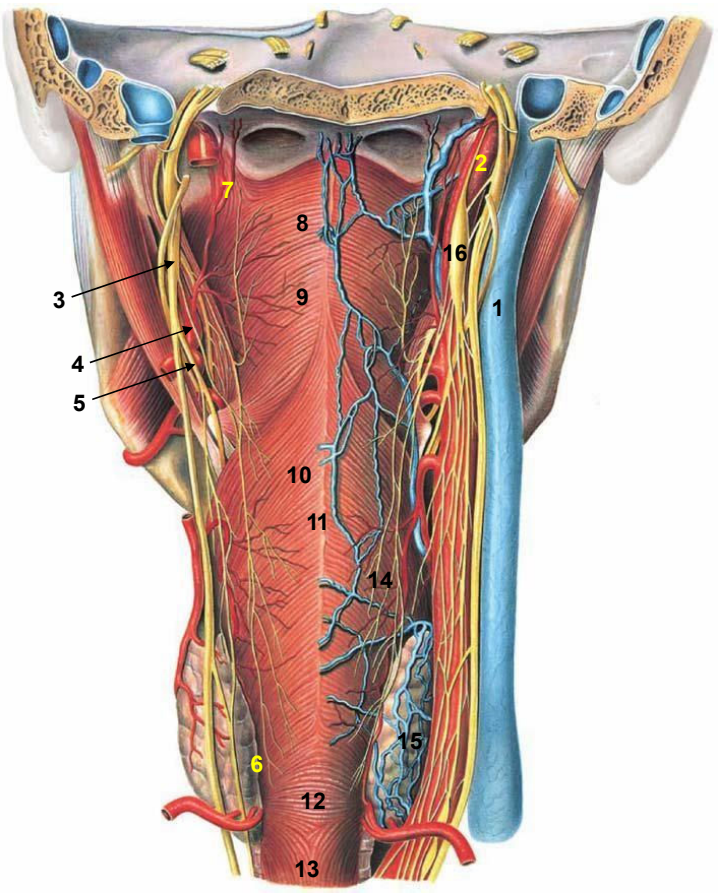

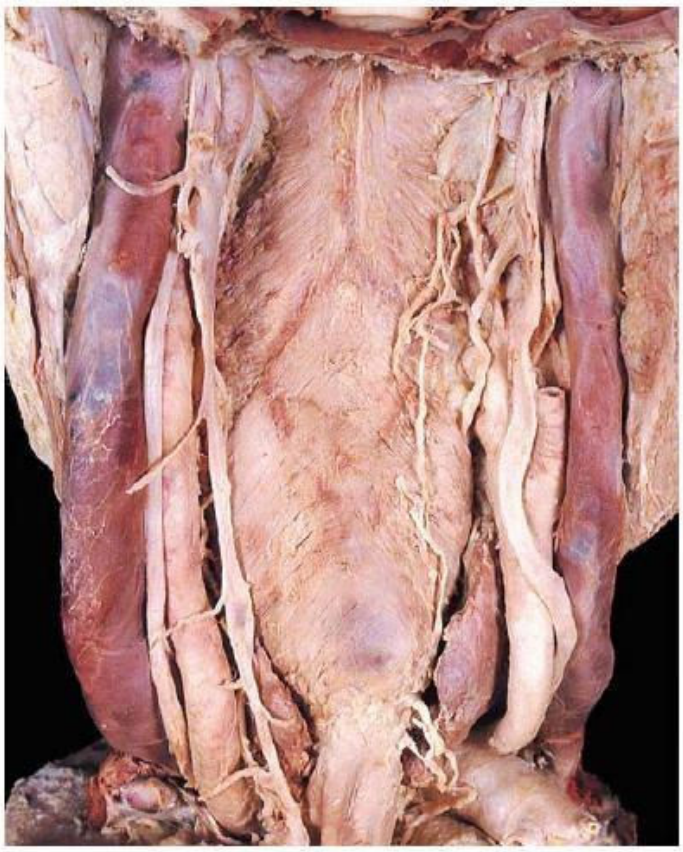

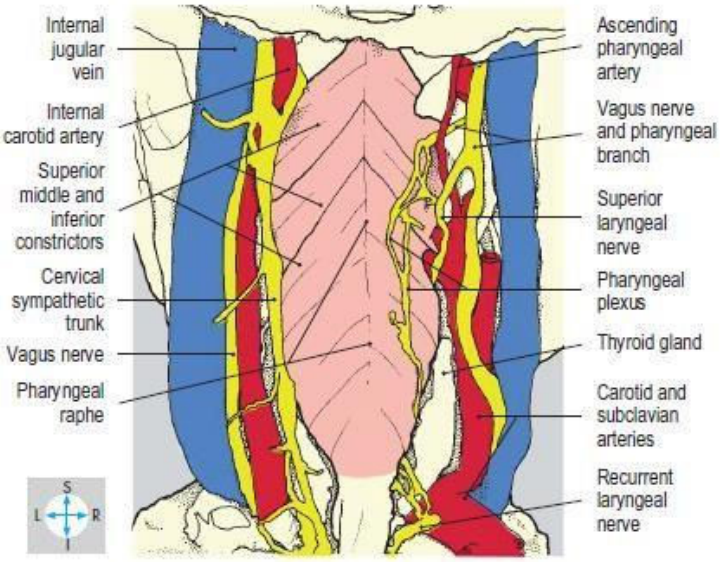
Internal jugular vein
Internal carotid artery
Superior middle and inferior constrictors
Cervical sympathetic trunk
Vagus nerve
Pharyngeal raphe
Ascending pharyngeal artery
Vagus nerve and pharyngeal branch
Superior laryngeal nerve
Pharyngeal plexus
Thyroid gland
Carotid and subclavian arteries
Recurrent laryngeal nerve
S
L
R
I

Pharynx, posterior view:

1 IJV

2 ICA

3 X n

4 Pharyngeal branch X

5Superior laryngeal br X

6 Recurrent laryngeal br X

7 Ascending pharyngeal a

8 Superior constrictor

9 Middle constrictor

10 Inferior constrictor

11 Pharyngeal raphe

12 Cricopharyngeus

13 Esophagus

14 Pharyngeal plexus

15Thyroid gland

16 Sympathetic trunk

