Anatomy of the PHARYNX Professor Ali Altimimi

Professor Ali Altimimi,Prof. of clinical Anatomy & Histopathology ,MbCHB,MSC,PHD,MD.Royal College London

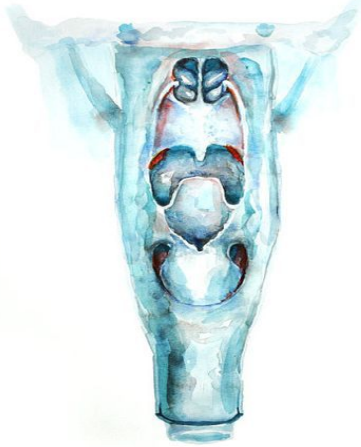

Pharynx

Lecture Objectives:

- ★ Pharynx
  - Anatomy of the pharynx and deep neck spaces (retro and parapharyngeal)
  - Physiology of pharynx (in brief).

Pharynx :

- It extend from the base of the skull to the level 6 cervical vertebra at the lower border of cricoid cartilage.
- Funnel shaped, 10 cm length

Parts of the pharynx :

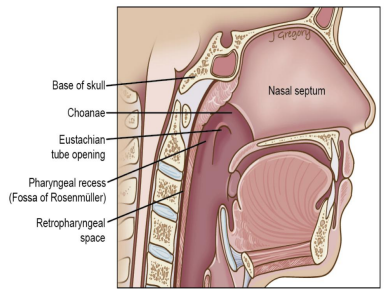

01

Nasopharynx
Open anteriorly to the nose

- **Above:** the base of skull
- **Below:** soft palate
- **Laterally** :opening of the eustachian tube, torus tuberous, Pharyngeal recess (fossa of rosenmuller common site for nasopharyngeal carcinoma*very important to examine
- Nasopharynx in smoker adult complaining of nasal obstruction + spitting blood), Adenoid, Nasopharyngeal isthmus
- In patients with a large adenoid blocking the eustachian tube, they would develop otitis media with effusion (fluid in middle ear). Adenoid is in nasopharynx. not the the nose

02

Oropharynx
Open anteriorly to the mouth

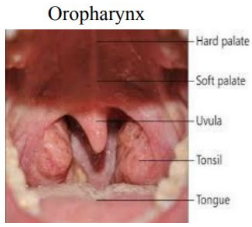

- **Above:** soft palate
- **Below:** the upper border of epiglottis
- Palatine tonsils between the ant pillars and post pillars, tonsils are located between 2 arches palatoglossal arch(1st) and palatopharyngeal arch(2nd).
- How to measure the grade of the tonsils? put imaginary line in uvula, if the tonsils are within the fossa then this is grade 1 (45%) if it extends more then 50% if more then 75% if they are touching each other this is grade 4 (kissing tonsils)

03

Laryngopharynx (hypopharynx)
Open anteriorly to the larynx

- **Above:** the upper border of the epiglottis
- **Below:** lower border of cricoid
- **Three parts :**
  - Pyriform fossa
  - Posterior cricoid area
  - Posterior pharyngeal wall

Laryngopharynx

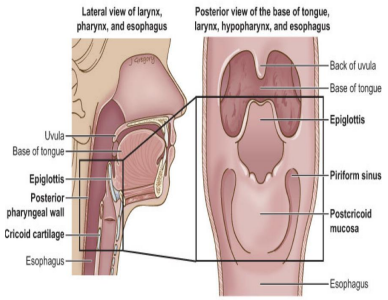



Structure of the pharynx :

- Fibromuscular tube: Four layers. From internal to external : **Mucous membrane , Pharyngeal aponeurosis , Muscle coat , and Buccopharyngeal fascia**

Mucous membrane:

- Ciliated epithelium
- Stratified squamous epithelium
- Transitional epithelium
- Subepithelial lymphoid tissue of the pharynx (waldeyer's ring) scattered in pharynx includes the (adenoid, palatine tonsils, lingual tonsils)
- Structures of Waldeyer's Ring:
  - Adenoid (no capsule) high chance of reoccurrence
  - Lingual tonsils
  - Tubal tonsils (around EU in fossa of rosenmuller)
  - Lateral pharyngeal bands
  - Discrete modules
  - Palatine tonsils

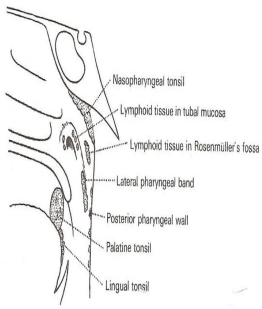

- Palatine tonsils:
- 12-15 crypt a lot of patients complain from white cheese like pieces coming out from the nose this is tonsil liths which is cause by accumulation of food in the crypts and it causes bad smell
- The deep surface is separated from the constrictor muscles of the pharynx by connective tissue' capsule'

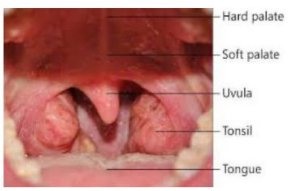

Palatine tonsils

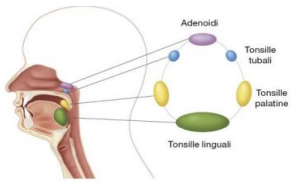

Waldeyer's ring

Pharyngeal aponeurosis

- Incomplete connective tissue coat in the lateral and posterior walls of the pharynx between the muscular layers
- Starts from the pharyngobasilar fascia
- Gives more strength to the structures

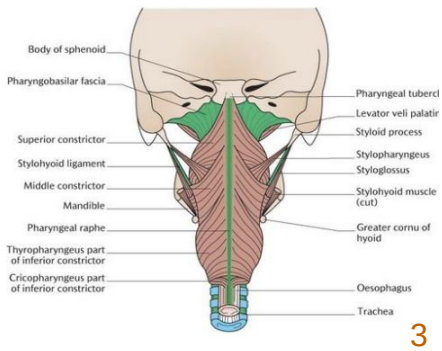

Muscular coat

External

Three constrictor muscles:

1. **Superior constrictor**: arise from pterygoid , pterygomandibular ligament post end of mylohyoid fibers
2. **Middle constrictor**: arise from the hyoid bone and stylohyoid ligament
3. **Inferior constrictor**: has insertions in thyroid and cricoid. Thyropharyngeus, Cricopharyngeus.

Killian's dehiscence: potential gap between thyropharyngeus and cricopharyngeus

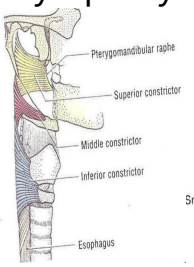

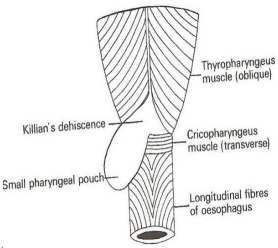

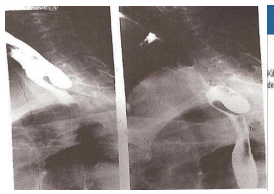

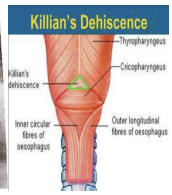

Internal

Three muscles:

1. **Stylopharyngus**
2. **Salpingopharyngus**
3. **palatopharyngus**

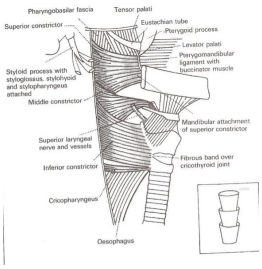

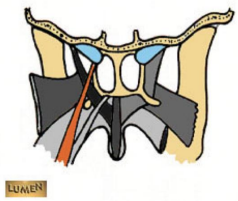

Buccopharyngeal fascia

- Thin layer covers the muscular layer of pharyngeal wall.

Relation of the pharynx :

- **Posteriorly**: prevertebral fascia (behind prevertebral fascia we have cervical spine)
- **Anteriorly**: Parapharyngeal space

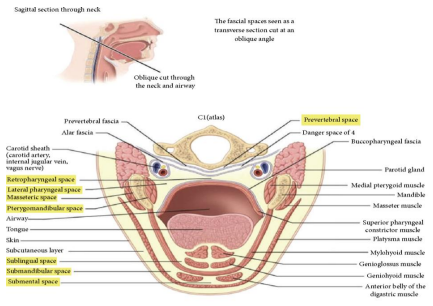

• Parapharyngeal space :

- Potential space lies outside the pharynx -
- Triangular in cross section , it extend from the base of the skull above to the sup mediastinum and apex of hyoid bone
- **Anteromedial wall**: buccopharyngeal fascia
- **Posteromedial wall**: cervical vertebrae, prevertebral muscle and fascia
- **Lateral wall**:
  - **(up)** the mandible, pterygoid muscle, parotid gland
  - **(Lower)** sternomastoid muscle
  - **Compartment :** divided by styloid process

1. **Prestyloid** is anterior: internal maxillary artery, fat, inferior alveolar, lingual, and auricultemporal nerves.
2. **Poststyloid**: neurovascular bundle (carotid artery, internal jugular vein, sympathatic chain, CN IX, X and, XI).Vital structures (infection in this space may lead to cranial nerve paralysis or carotid rupture)
   *(If a child has tonsillitis and on examination you found a bulge in the posterior wall (in front of you) you do a CT scan. It might be an abscess. an adult with a posterior bulge without acute infection, think of TB).

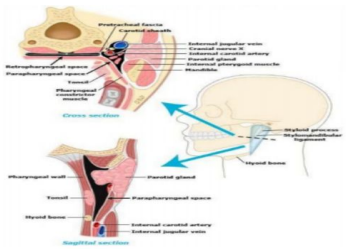

• Retropharyngeal space :

- Posterior space
- It extend from the base of skull to super mediastinum.
- Lies behind the pharynx
- **Anterior**: posterior pharyngeal wall and its covering buccopharyngeal fascia
- **Posterior**: cervical vertebrae and muscles and fascia
- **Contents**: Retropharyngeal lymph nodes
- The retropharyngeal space is actually comprised of two potential spaces, separated by the alar fascia:
  - Anterior, the 'true' retropharyngeal space
  - Posteriorly, the 'danger space'.
- The RPS communicates laterally with the parapharyngeal spaces. Clinically, the retropharyngeal space is important, **because it represents a potential pathway for metastasis of disease between the head & neck and the thorax**, specifically by means of the "danger space", which can connect the retropharyngeal space with superior mediastinum of the thorax.

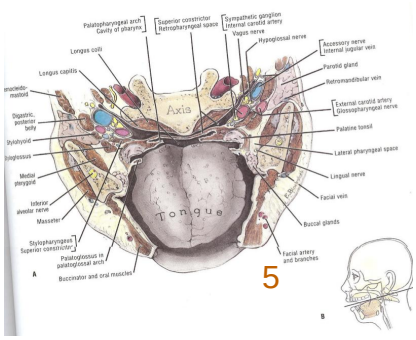

Nerve Supply

Sensory : Each of the three sections of the pharynx have a different innervation:

- The nasopharynx is innervated by the maxillary branch of the trigeminal nerve (CN V).
- **The oropharynx by the glossopharyngeal nerve (CN IX).**
- **The laryngopharynx by the vagus nerve (CN X).**

Motor: All the muscles of the pharynx are innervated by the vagus nerve (CN X), except for the stylopharyngeus which is innervated by the glossopharyngeal nerve (CN IX). Also the Sympathetic fibers of the superior cervical ganglia play a role in the innervation.

Arterial Supply from the external carotid

- Artery: *
  - **Ascending pharyngeal (Mainly)**
  - The lingual artery
  - The facial artery
  - The maxillary artery
- Venous drainage:
  - To the internal jugular
- Lymphatics:
  - Retropharyngeal nodes.
  - Deep cervical (jugular) nodes.

Physiology of the pharynx

01

Functions of the subepithelial lymphoid tissue

- Protective functions :
  - Formation of lymphocytes
  - Formation of antibodies-
  - Acquisition of immunity
  - Localization of infection
  - Salivation

02

Functions of the pharynx

- Respiration
- Speech
- Resonating cavity
- Articulation
- Taste: taste buds

03

Deglutition

- Three stages

A

Oral stage

- voluntary you can stop it
- closure of mouth
- cessation of respiration
- raising of larynx
- sudden elevation of the tongue to mixes food with saliva
- press the tongue against the palate, and pushes it backwards towards the oropharynx
- (soft palate closes against posterior pharyngeal wall to prevent food and water from coming out of the nose, in people with cleft palate or short palate everything comes out of the nose)

B

Pharyngeal stage

- Reflux
- Contraction of nasopharynx sphincter
- Larynx rises more
- Laryngeal inlet closure
- Epiglottis (closes the airway) diverts the food into cricopharyngeal sphincter (upper esophageal sphincter)
- Contraction of constrictor muscles
- Relaxed cricopharyngeal sphincter (cricopharyngeal spasm causes choking)
- Cessation of respiration

C

Esophageal Stage