Anatomy of the larynx

Professor Ali Altimimi,Prof. of Clinical Anatomy& Histopathology
MbCHB,MSC,PHD,MD.Royal College London

Objectives:

- Describe the Extent, structure and functions of the larynx.
- Describe **The larynx relation to major critical structures in the neck.**
- Describe the Membranes & Ligaments
- Describe the **Laryngeal muscles**

The larynx is related to major critical structures in the neck.

Larynx

part of the respiratory tract which contains the **vocal cords**.

- In adult it is 2-inch-long tube.
- It opens above into the laryngeal part of the pharynx.
- Below, it is continuous with the trachea

functions	➢ Respiration (breathing). ➢ Phonation (voice production). ➢ Deglutition (swallowing).
Q? **Relations**	The larynx is related to major critical structures in the neck. ➢ Arteries: Carotid arteries: 3 (common, external and internal), ➢ Thyroid arteries: 3 (superior & inferior thyroid arteries and thyroidema artery. ➢ Veins: Jugular veins, (external & internal) ➢ Nerves: Laryngeal nerves:(Superior laryngeal & recurrent laryngeal), vagus nerve.

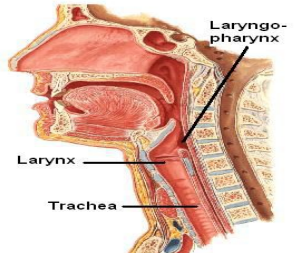

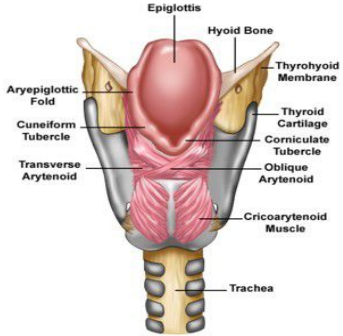

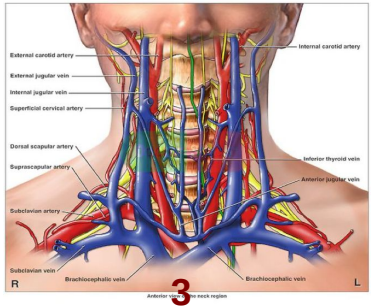

Structure:

The larynx consists of four basic components:

1) Cartilaginous skeleton.
2) Membranes and ligaments.
3) Muscles (Intrinsic & extrinsic muscles).
4) Mucosal lining.

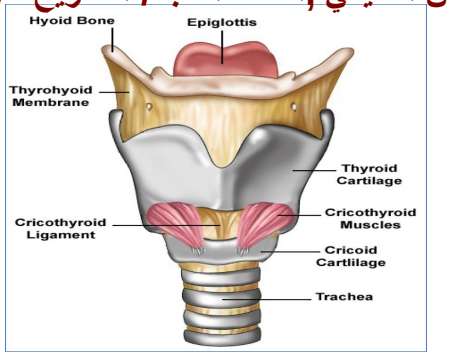

★ All the cartilages, are hyaline except the epiglottis which is Elastic cartilage.

The cartilages are: Connected by joints,ligaments, lined by membranes, and moved by muscles.

The cartilages

3 Singles:
1. Thyroid
2. Cricoid
3. Epiglottis

3 Paired:
4. Arytenoid
5. Corniculate
6. Cuneiform

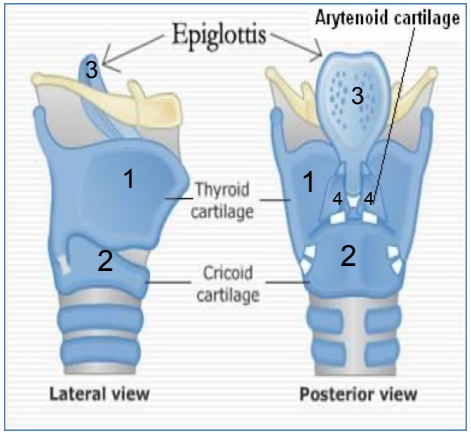

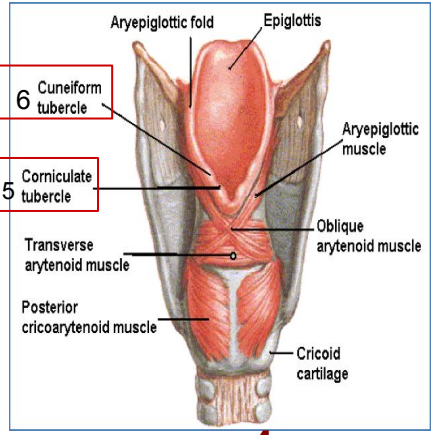

Q?

Membranes & Ligaments

1

Thyrohyoid membrane:
The thyrohyoid membrane is thickened in the median plane to form median thyrohyoid ligament and on both sides to form lateral thyrohyoid ligaments.

2

Quadrangular membrane:
(Aryepiglottic membrane),It extends between the arytenoid and epiglottis.
Its lower free margin forms the vestibular ligament which forms the vestibular fold (false vocal cord).

3

***Cricothyroid membrane**:
(conus elasticus) Its lower margin is attached to the upper border of cricoid cartilage.
Upper free margin forms Vocal ligament which forms the (true vocal cord).

4

Cricotracheal membrane

Ligaments:
Hyoepiglottic ligament.
Thyroepiglottic ligament

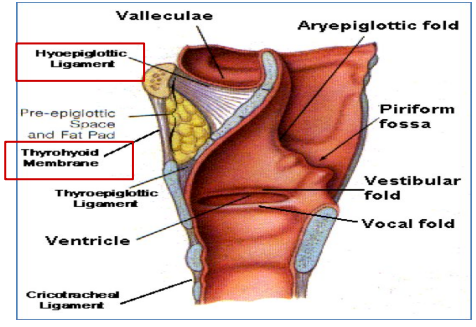

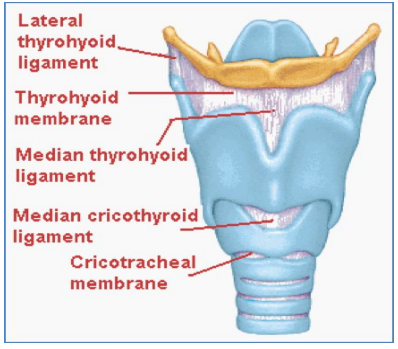

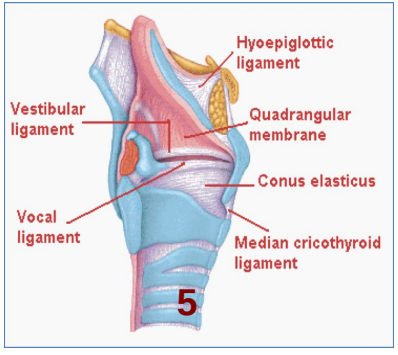

Larynx

Laryngeal Inlet

It is the upper opening of the larynx.
It faces upward and backward and opens into the laryngeal part of the pharynx, (laryngopharynx).

Bounded by:

- *Anteriorly*: by the upper margin of epiglottis (E)
- *Posteriorly & below*: by arytenoid cartilages (A)
- *Laterally*: by the Aryepiglottic folds (AEF)

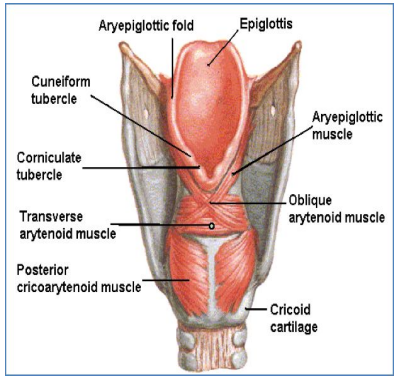

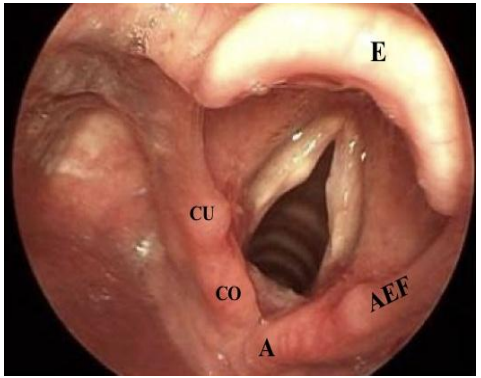

Laryngeal Cavity

Extends from laryngeal inlet to lower border of the cricoid cartilage.

- Narrow in the region of the vestibular folds (rima vestibuli)
- Narrowest in the region of the vocal folds (rima glottidis)

Divided into three parts:

1. *Supraglottic* part or vestibule: it is the part above the vestibular folds.(A)
2. *Ventricle*: it is the part between the vestibular folds & the vocal folds.(B)
3. *Infraglottic* part, the part below the vocal folds.(C)

*The ventricle has an upward invagination called saccule which is rich in goblet cells.

(Pictures are in the next slide)

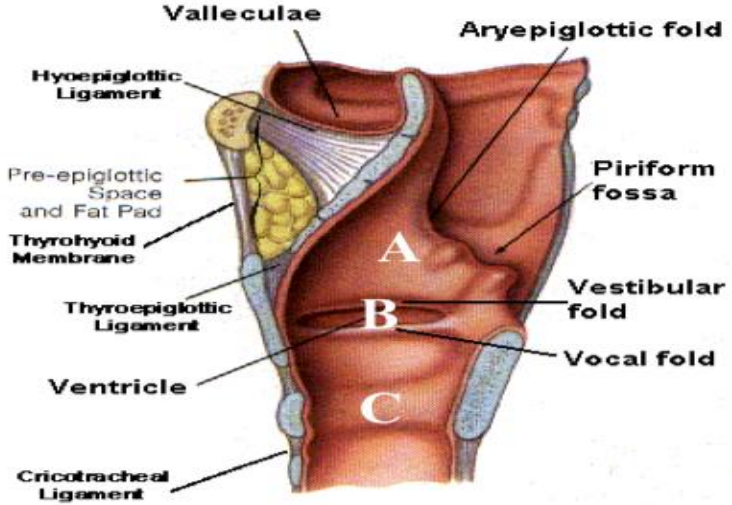

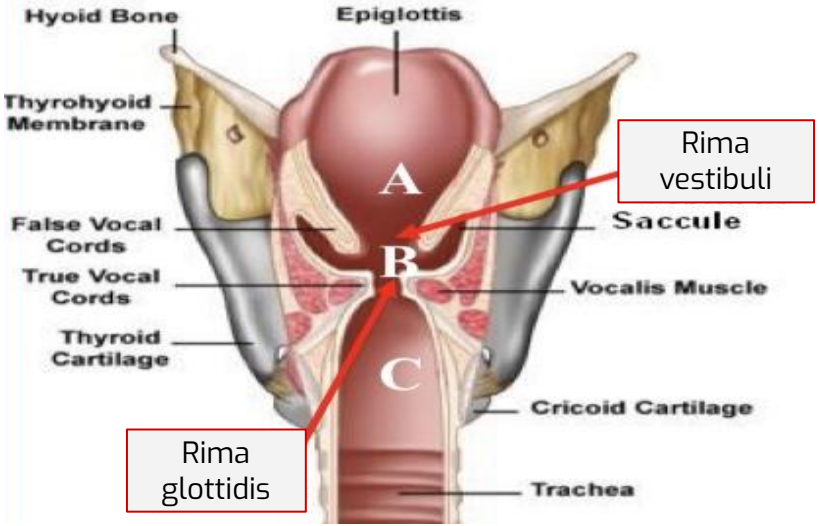

Mucous Membrane

Mucous Membrane

The cavity is lined with ciliated columnar epithelium **except** the surface of the vocal cords.
The surface of vocal folds, is covered with stratified squamous epithelium because of exposure to continuous trauma during phonation.
It contains many mucous glands, more numerous in the region of the saccule (for lubrication of vocal folds).

Laryngeal muscles

Laryngeal muscles are divided into two main groups:

- **Extrinsic muscles:**

subdivided into two groups:

1- Elevators of the larynx.

2- Depressors of the larynx.

- **Intrinsic muscles:**

subdivided into two groups:

1- Muscles controlling the laryngeal inlet.

2- Muscles controlling the movements of the vocal cords.

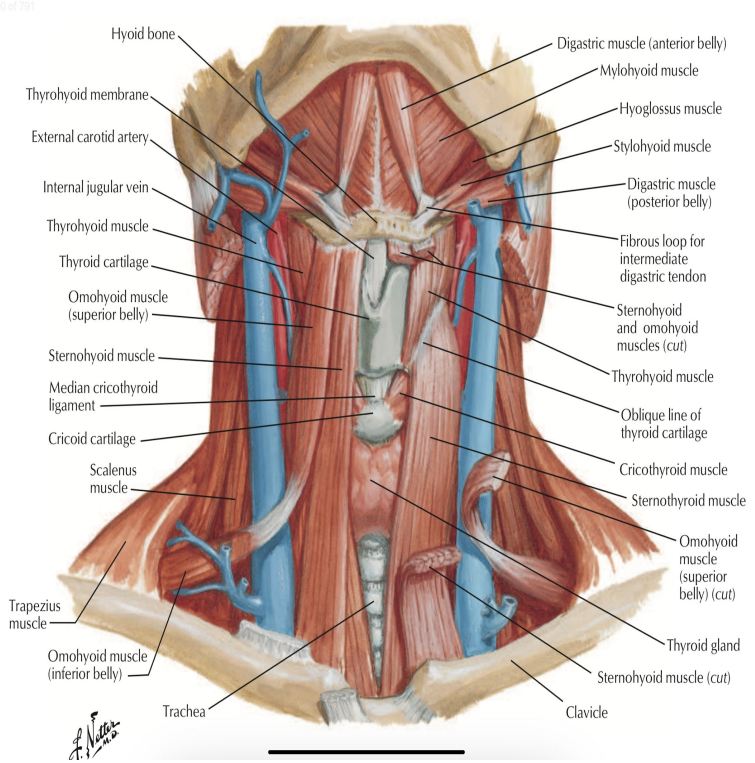

Extrinsic muscles

note:
all Extrinsic muscles ends with "hyoid" except digastric, sternothyroid and the longitudinal muscles

Elevators of the larynx:

A-The Suprahyoid(MSGD):

- ➔ Mylohyoid.
- ➔ Stylohyoid.
- ➔ Geniohyoid.
- ➔ Digastric

B-The longitudinal muscles of pharynx:

- ➔ Stylopharyngeus.
- ➔ Salpingopharyngeus.
- ➔ Palatopharyngeus.

Depressors of the larynx:

-The Infrahyoid Muscles:

- ➔ Sternohyoid.
- ➔ Sternothyroid.
- ➔ Omohyoid.

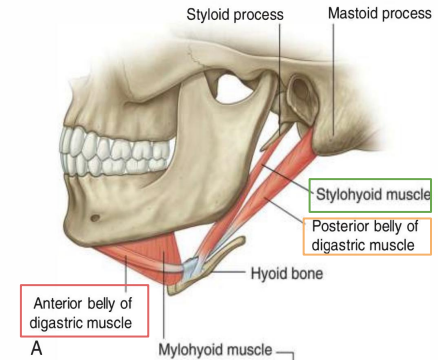

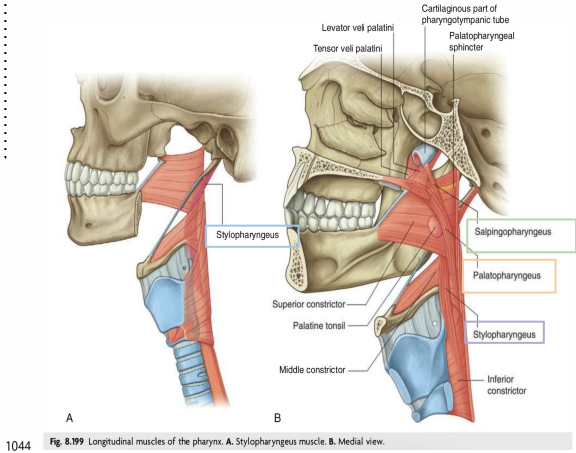

1044 Fig. 8.199 Longitudinal muscles of the pharynx. A. Stylopharyngeus muscle. B. Medial view.

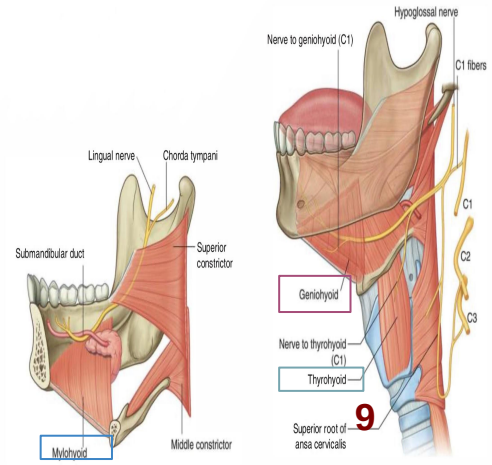

Intrinsic muscles

Muscles Controlling the Laryngeal Inlet:

- ➔ Oblique arytenoid.
- ➔ Aryepiglottic muscle.

Muscles controlling the vocal cords:

-**Muscle decreasing the Length & Tension of Vocal Cords (relax vocal cords) :**

- ➔ Thyroarytenoid (vocalis).

-**Muscle increasing the Length & Tension of Vocal Cords**.

- ➔ Cricothyroid. the only intrinsic muscle which found outside the larynx.

-**Adductors (close rima glottis):**

- ➔ Lateral crico**arytenoid**.
- ➔ Transverse **arytenoid**.

-**Abductor (open rima glottis):**

- ➔ *Posterior crico**arytenoid**.

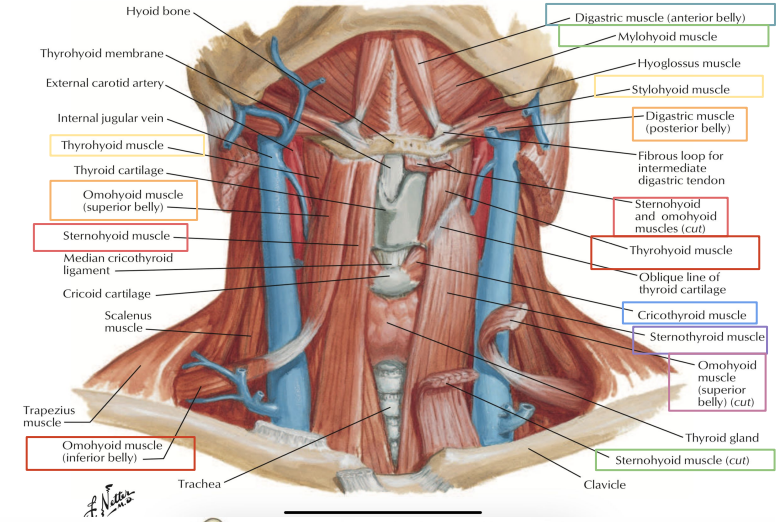

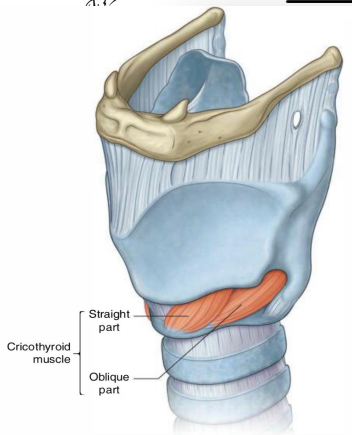

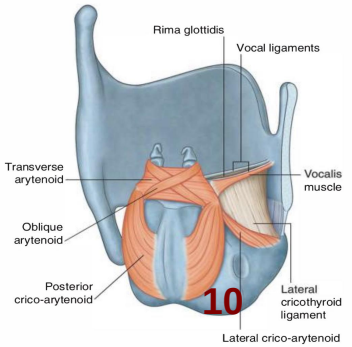

Blood supply

Arteries
upper half:
superior laryngeal artery,
branch of
superior thyroid artery.
lower half:
inferior laryngeal artery
branch of
inferior thyroid artery.

Veins :

Accompany the corresponding arteries,

Lymphatics :

the lymph vessels drain into the deep cervical lymph nodes

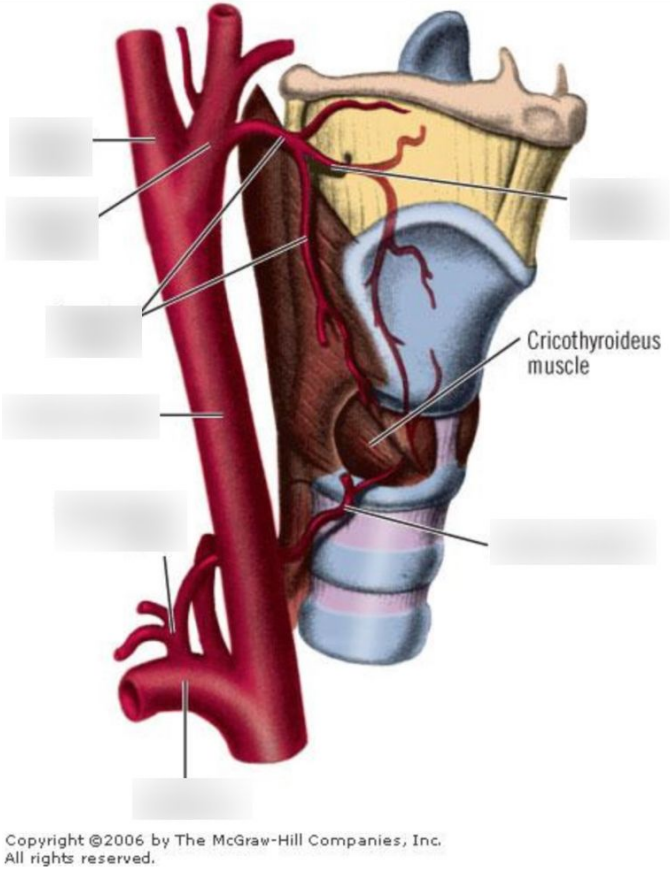

Copyright ©2006 by The McGraw-Hill Companies, Inc.
All rights reserved.

Nerve supply and semon's law

Motor:
All intrinsic muscles are supplied by recurrent laryngeal nerve of vagus nerve EXCEPT cricothyroid which is supplied by external laryngeal nerve of superior laryngeal of vagus

Sensory:
above the vocal cords = internal laryngeal nerve branch of the superior laryngeal of the vagus nerve
below the vocal cords = recurrent laryngeal nerve of the vagus nerve

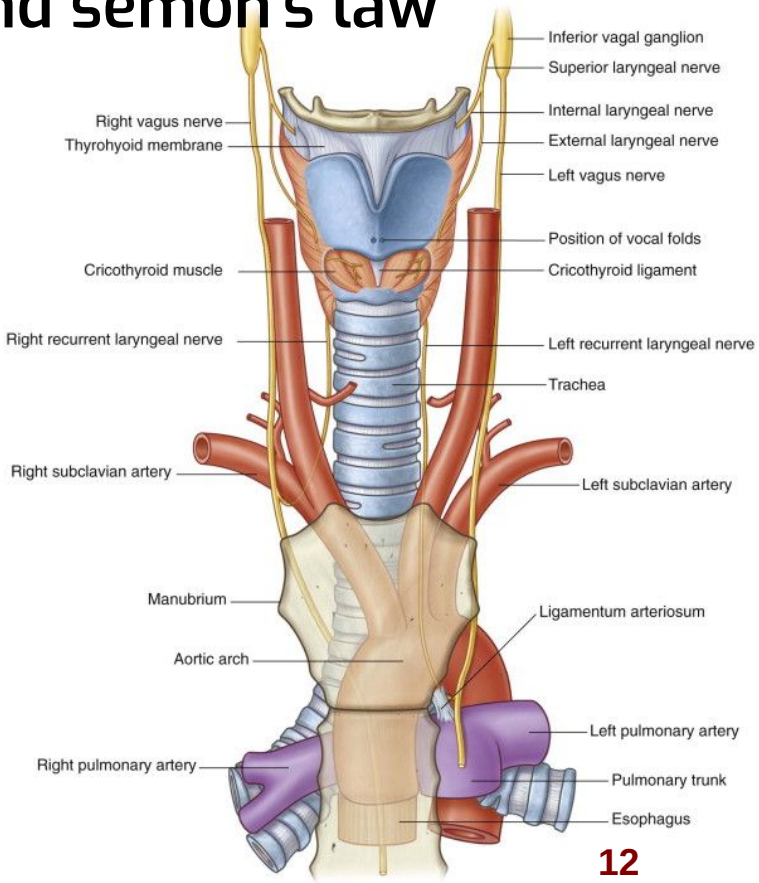

Semon's law :

Semon's law : (damage of recurrent laryngeal nerve)
indicates the different effect between damage (surgical trauma) and transection of the recurrent laryngeal nerve due to surgery in region of the neck (e.g thyroidectomy or parathyroidectomy).

Transected: complete paralysis,cannot speak,cannot cough, cords half abducted/adducted , can breath

Trauma without transected: partial paralysis,adducted vocal cords as posterior crico-arytenoid most vulnerable and cannot breath
in non transected damage:
-Bilateral(both sides)= VERY dangerous (disaster)
-Unilateral= CAN partially compensate

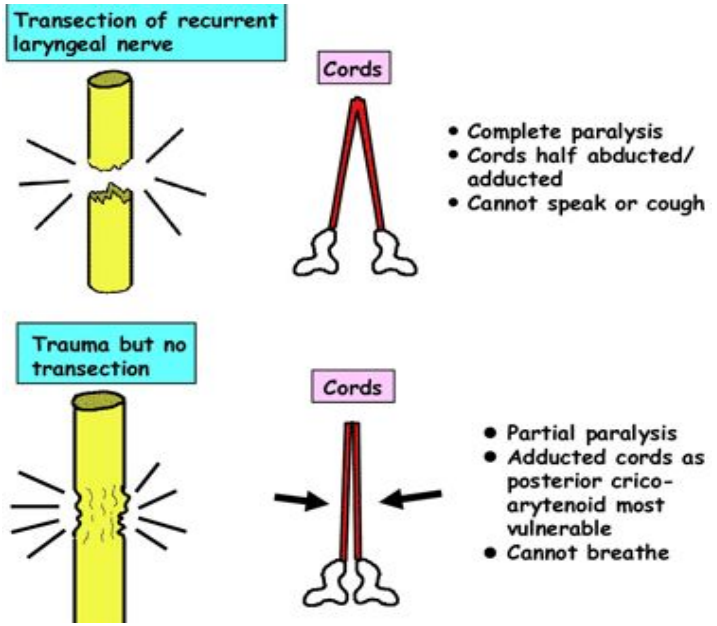

N.B : The nerve fibers supplying the abductors of the vocal folds lie in the periphery of the recurrent laryngeal nerve and any progressive lesion involves these fibers first before involving the deeper.

MCQ

Q1: the larynx has function in:

A.respiration
B.phonation
C.deglutition
D.all above

Q2: which one of these is a single cartilage?

A.Epiglottis
B.arytenoid
C.cuneiform
D.none

Q3: which one is an elastic cartilage

A.thyroid
B.cricoid
C.Epiglottis
D.arytenoid

Q4: lower margin of Cricothyroid membrane is attached to the upper border of

A.thyroid cartilage
B.cricoid cartilage
C.epiglottis
D.none

Q5: It extends between the arytenoid and epiglottis:

A.Quadrangular membrane
B.aryepiglottic membrane
C.both A and B
D.cricotracheal membrane

Q6: The cavity of larynx is lined with:

A.ciliated columnar epithelium
B.stratified squamous epithelium
C.saccules
D.none

answer key:
1:D
2:A
3:C
4:B
5:C
6:A

MCQ

Q7: Semon's law due to ?

A.damage of recurrent laryngeal nerve
B.damage of internal laryngeal nerve
C.damage of external laryngeal nerve
D.damage of accessory nerve

Q8: Trachea ends in ?

A.upper border of T4
B.lateral border of T4
C.medial border of T4
D.inferior border of T4

Q9: Which one of the following is a posterior relation to trachea

A.sternum
B.pleural
C.esophagus
D.Arch of aorta

Q10: Right bronchus is ?

A.short
B.narrow
C.vertical
D.A & C

Q11: Trachea are associated with ?

A.sneezing
B.cough
C.sweating
D.swallowing

Q12: Venous supply of trachea drain into ?

A.superior arytenoid vein
B.inferior arytenoid vein
C.superior thyroid vein
D.inferior thyroid vein

answer key:
7:A
8:D
9:C
10:D
11:B
12:D

SAQ :

1 : List the Depressors muscles of the larynx.

2 : The Laryngeal Inlet is bounded by?

3 :List three features of left Bronchus ?

SAQ Answers

1 :Sternohyoid, Sternothyroid, Omohyoid.

2 :Anteriorly: by the upper margin of epiglottis
Posteriorly & below: by arytenoid cartilages
Laterally: by the Aryepiglottic folds

3 Narrow,long,horizontal,two inch long

Students **Team leaders**

Students Team Members :