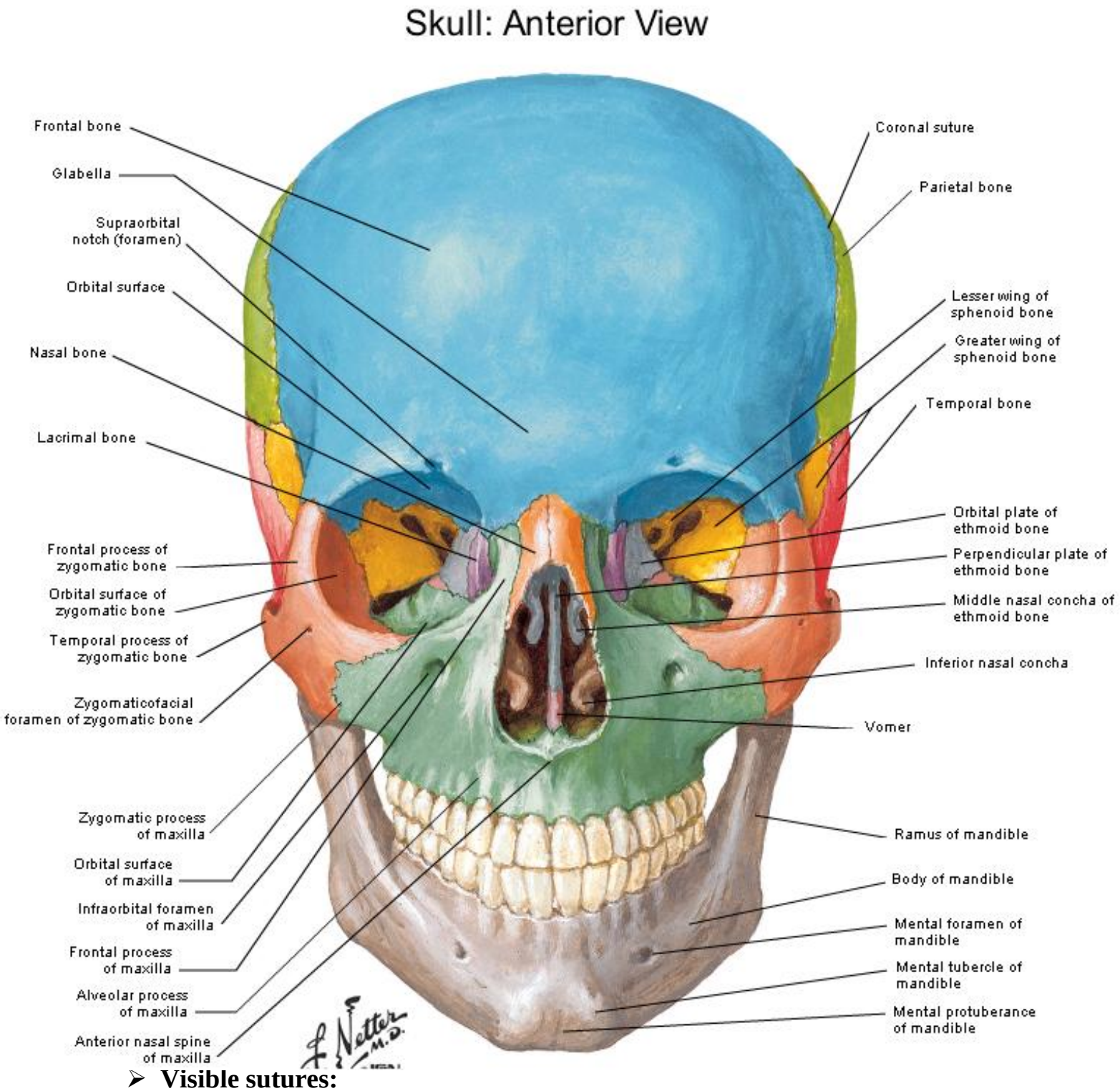

- **Visible sutures:**

1-The coronal suture: a straight suture that lies across the skull separating the frontal bone in front from the parietal bones behind.

2-The sagittal suture: a straight suture that lies in between the two parietals in the midline plane, it meets the coronal suture anteriorly & the lambdoid posteriorly.

3-The lambdoid suture: a very coarse, tortuous, inverted-V like suture whose apex meets the posterior end of the sagittal suture & its diverging two limbs descend in the direction of the mastoid process to meet the occipito-temporal suture, this suture separates the occipital from the parietal bones & frequently contains sutural bones.

The Skull Skull L#1& 2 Text Osteology

The skull is the skeleton of the head formed of two groups of bones:

1- Cranial bones: are series of flat bones united to each other by interlocking or overlapping sutures forming a cavity which accommodates the brain (cranial cavity), they consist of eight bones:

* ***Paired:*** -Parietal bones
  -Temporal bones
* ***Single:*** -Frontal bone
  -Occipital bone
  -Sphenoid bone
  -Ethmoid bone

2- Facial bones: irregular bones unite with each other & with cranial bones in a complex manner forming the bony framework of the face, they total fourteen:

* ***paired:*** -Nasal bones
  -Maxillae
  -Zygomatic bones
  -Palatine bones
  -Inferior turbinates
  -Lacrimal bones
* ***Single:*** -Vomer
  -Mandible

NORMA VERTICALIS "The skull viewed from above":

- The skull is oval in shape broadened posteriorly by the parietal eminences.
- In children the prominent frontal eminences together with the parietal give the skull a square shape.
- **Visible bones:**

1-The frontal bone anteriorly
2-The occipital bone posteriorly
3-The two parietals in between
4-The upper part of squamous temporal laterally
5-The zygomatic arch (zygomatic process of the temporal & temporal process of the zygomatic bones).

- **Visible sutures:**

1-The coronal suture: a straight suture that lies across the skull separating the frontal bone in front from the parietal bones behind.
2-The sagittal suture: a straight suture that lies in between the two parietals in the midline plane, it meets the coronal suture anteriorly & the lambdoid posteriorly.
3-The lambdoid suture: a very coarse, tortuous, inverted-V like suture whose apex meets the posterior end of the sagittal suture & its diverging two limbs descend in the direction of the mastoid process to meet the occipito-temporal suture, this suture separates the occipital from the parietal bones & frequently contains sutural bones.

4-Metopic suture: usually obliterated but may persist in 8% of adults, it is a vertical suture that separates the frontal bone into two bones.

- **Stigmata:**

1-The superciliary ridges form the anterior limit of this view.
2-The lambda "posterior fontanelle": is the meeting point between the sagittal & lambdoid sutures, it is a triangular opening in neonates & closes in the very early few months of life.
3-The bregma "anterior fontanelle": is the meeting point between the sagittal & coronal sutures, it is a star-shape opening in neonates whose closure is delayed to around 1.5 years of age.
4-The parietal foramina: two small foramina, one in each parietal bone near the sagittal suture & closer to the lambda, they transmit parietal emissary veins.

NORMA FRONTALIS "The skull viewed from the front":

- Viewed from the front, the forehead, orbit, nasal region, maxillae & mandible are the prominent features of the skull.
- **Visible bones:**

1-The frontal bone.
2-The bones of the nose (nasal, vomer, ethmoid & inferior turbinates).
3-The bones of the orbit (lacrimal, sphenoid, ethmoid & other facial bones).
4-The maxillae.
5-The zygomatic bones.
6-The mandible.

- **Visible sutures:**

1- The fronto-nasal suture, between the nasal bones & the nasal process of the frontal bone.
2- The internasal suture, between the two nasal bones.
3- The fronto-zygomatic suture: between the zygomatic process of the frontal bone & the frontal process of the zygomatic bone lateral to the orbit.
4- The zygomatico-maxillary suture: oblique suture between the zygomatic bone laterally & maxilla medially.
5- Inconstant sutures: sometimes seen as the metopic & the intermaxillary sutures.

- **Stigmata:**

1-Superciliary arches: are two blunt elevations one on each orbit medially.
2-The glabella; is the depression between the two superciliary arches.
3-The supra-orbital foramina (or notches): are located at the junction of the medial & middle thirds of each superior orbital margin & transmit the vessels & nerves of its own name.
4-The nasion: is the crosspoint between the fronto-nasal & internasal sutures.
5-The orbit: will be discussed later.
6-The anterior nasal aperture: an oval opening narrower above than below from which the cavity of the bony nose is seen.
7-The anterior nasal spine: is a sharp spine in the inferior border of the anterior nasal aperture in the midline.
8-The canine eminence: is an elevation surrounding the root of the canine tooth.

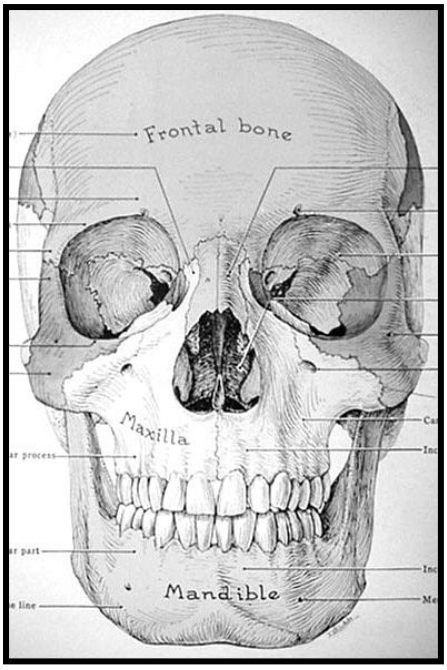

9-The incisive fossa: a light depression in the maxilla medial to the canine eminence.
10-The canine fossa: a more deep depression lateral to the eminence.
11-The infra-orbital foramina: well defined rounded foramina in the maxillae just below the inferior orbital margin, they transmit the nerves & vessels carrying its own name.
12-The symphysis menti: is a midline ridge in the body of the mandible.
13-The mental protuberance: enlarged triangular lower end of the symphysis.
14-Mental foramina: small foramina in the mandible, one below each second lower premolar tooth & transmit the mental vessels & nerves.

NORMA OCCIPITALIS "The skull viewed from the back":

- Viewed from the back, the skull is rounded in shape whose roundness is modified by the parietal eminences superolaterally & the mastoid processes inferolaterally.
- **Visible bones:**

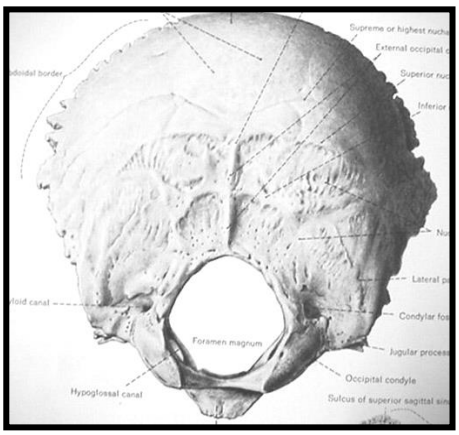

1-The occipital bone.
2-The parietal bones.
3-The temporal bones.

- **Visible sutures:**

1-The sagittal suture.
2-The lambdoidal (parieto-occipital) suture.
3-The occipito-temporal (occipito-mastoid) suture.
4-The parieto-mastoid suture.

- **Stigmata:**

1-The lambda.
2-The mastoid foramen: adjacent to the occipito-mastoid suture, transmits the mastoid emissary vein connecting the posterior auricular vein (extracranial) with the sigmoid sinus (intracranial).
3-The external occipital protuberance (EOP): a marked rounded process in the pccipital bone in the midline usually easily felt through the skin.
4-The external occipital crest: a well-defined midline ridge extending between the EOP & the foramen magnum.
5-The highest nuchal line: faint line starts from the EOP & extends laterally in an upward curve in the direction of the mastoid process.
6-The superior nuchal line: just below the highest one & more marked than it.
7-The inferior nuchal line: between the superior one & foramen magnum, it is also a well defined line.

NORMA LATERALIS "The skull viewed from the side":

- The lateral aspect of the skull is partly facial & partly cranial.
- **Visible bones:**

1-The frontal bone.
2-The parietal bone.
3-The occipital bone.
4-The temporal bone.
5-The sphenoid.
6-The zygomatic bone.
7-The nasal bone.
8-The maxilla.
9-The lacrimal bone.
10-The mandible.

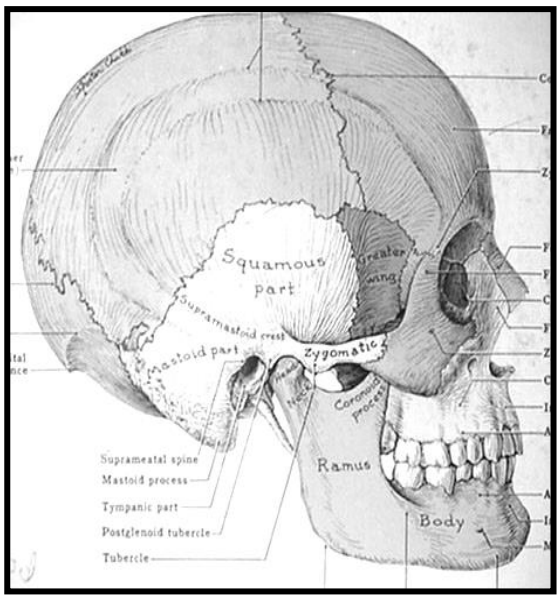

- **Visible sutures:**

1-The coronal suture.
2-The temporo-parietal (squamosal) suture.
3-The occipito-mastoid suture.
4-The temporo-zygomatic suture.
5-The zygomatico-maxillary suture.
6-The fronto-nasal suture.
7-The spheno-frontal suture.
8-The spheno-parietal suture.
9-The spheno-squamosal suture.

- **Stigmata:**

1-The temporal lines: two lines (superior & inferior) start at the root of the zygomatic process of the frontal bone & diverge as they go posteriorly curving upward, then inferiorly & then anteriorly completing the circle by joining the posterior root of the zygomatic arch.
2-The infratemporal crest: the rough lower free edge of the greater wing of the sphenoid bone usually hidden by the zygomatic arch, it separates the temporal fossa above from the infratemporal fossa below.
3-The pterygo-maxillary fissure: deep to the mandible, a vertival slit exists between the posterior border of the maxilla & the anterior border of the pterygoid plate, this fissure connects the infratemporal with the sphenopalatine fossae & transmits the posterior superior alveolar vessels & nerves.
4-The temporal fossa: is the area bounded by the superior temporal line & infratemporal crest.
5-The zygomatic arch: formed by the zygomatic process of the temporal bone (posterior ¾) & the temporal process of the zygomatic bine (anterior ¼).
6-The pterion: is the point where the coronal suture meets the spheno-parietal suture in the floor of the temporal fossa, it represents the lateral fontanelle.
7-The asterion: is the meeting point between the temporo-parietal & lambdoid sutures.

8-The temporo-mandibular joint: seen at the inferior aspect of the posterior root of the zygomatic arch with the articular tubercle of the temporal bone (eminentia articularis) lies in front of it.
9-The external acoustic meatus.
10-The suprameatal triangle: lies postero-superior to the meatus, it is an important surgical landmark in ear surgery.
11-The mastoid process: is the downward projecting mamillary process of the temporal bone lies behind the external acoustic meatus.
12-The styloid process: sometimes seen projecting down deep to the external acoustic meatus.

NORMA BASALIS "The skull viewed from below":

- **Visible bones:**

1-The alveolar & palatal processes of the maxilla.
2-The horizontal plate of the palatine bone.
3-The pterygoid processes & greater wing of sphenoid.
4-The vomer.
5-The temporal bone.
6-The zygomatic bones.
7-The occipital bones.

- **Visible sutures:**

1-The intermaxillary suture. } **Cruciate suture**
2-The palato-maxillary sutures. }
3-The zygomatico-maxillary suture.
4- The spheno-squamosal suture.
5-The squamo-tympanic suture.
6-The petro-squamous suture.
7-The petro-tympanic suture.
8-The occipito-mastoid suture.

- **Stigmata:**

1-The alveolar process of the maxilla: is the curved, teeth-carrying bone which bounds the skull anteriorly in this view.
2-The hard palate: lies in the concavity of the alveolar process, it is formed by the palatal processes of both maxillae (anterior 2/3) and the horizontal plates of the palatine bones (posterior 1/3), it represents the roof of the mouth & floor of the nasal cavity.
3-The incisive fossa: a depression in the midline of the hard palate anteriorly in which lies the incisive foramen which connects the oral to the nasal cavities & transmits the long spheno-palatine vessels & nerves (anterior palatine vessels & naso-palatine nerves).
4-The maxillary tuberosity: is the remaining part of the alveolar process behind the last molar tooth, it is separated from the lower end of the pterygoid process by a gap, this gap is filled by the pyramidal process of the palatine bone closing the lower end of the pterygo-maxillary fissure.

5-The posterior nasal spine: is the midline spine projecting from the back of the hard palate for the attachment of musculus uvulae.
6-Posterior nasal apearture: is the posterior opening of the nasal cavity, here we see the vomer dividing it into two cavities, the vomer is seen to expand as it goes superiorly to abut on the undersurface of the sphenoid body & join the roots of the pterygoid plates laterally.
7-The pharyngeal canal: lies just above the junction between the vomer & pterygoid plates,it transmits the pharyngeal branch of the spheno-palatine (pterygo-palatine) ganglia from the spheno-palatine fossae to the roof of the nasopharynx.
8-The pharyngeal tubercle: a midline tubercle on the undersurface of the occipital bone anterior to foramen magnum, from this tubercle two shallow ridges pass laterally in an anterior convexity for the attachment of the pharyngo-basilar fascia.
9-The pterygoid plates: are two downward projecting processes related to the sphenoid & lie on each side of the posterior nasal apearture, each has two plates:
a)The medial pterygoid plate; is long, narrow with a hook in its lower end called "pterygoid hamulus" which is pointed in the direction of the maxillary tuberosity, high up, the base of this plate is hollowed laterally forming the "scaphoid fossa", the posterior border of this plate is sharp & shows a spur above which lies the cartilaginous part of auditory tube as it enters the nasopharynx.
b)The lateral pterygoid plate; is broader than (a), this plate is for muscle attachment giving attachment for medial pterygoid muscle from its medial side and for lateral pterygoid muscle from its lateral side.
c)Pterygoid fossa; is the deep fossa lying between the two pterygoid plates & is almost filled by medial pterygoid muscle.
10-The pterygoid canal: situated high up in the root of the pterygoid plate (in the anterior aspect of foramen magnum), it leads from the base of the skull to the pterygo-palatine fossa & transmits the nerve of pterygoid canal.
11-The spine of sphenoid: lateral to the pterygoid plate, the greater wing of sphenoid extends laterally in a quadrangular fashion, the postero-lateral angle of it shows a sharp spine projecting inferiorly called spine of sphenoid which gives attachment to the sphenomandibular ligament.
12-The foramen ovale: an oval foramen perforates the greater wing of sphenoid near the root of the lateral pterygoid plate, it connects the infratemporal fossa with the middle cranial fossa & transmits; mandibular nerve, accessory meningeal artery, emissary vein between the cavernous sinus & pterygoid plexus and the lesser petrosal nerve.
13-Foramen spinosum: a small, rounded foramen which lies posterolateral to ovale perforating the spine of sphenoid & transmits the middle meningeal artery & the meningeal branch of mandibular nerve (this branch may pass through ovale).
14-The mandibular fossa: is a depression in the squamous temporal in which the head of mandible rests to form the TM joint, it is bounded posteriorly by the tympanic plate of the temporal bone & anteriorly by the articular eminence which is an elevation anterior to the joint providing anterior stability for it.
15-Foramen lacerum: the petrous part of temporal bone is wedged in 45° antero-medially between the temporal & sphenoid anteriorly and the occipital posteriorly.

The apex of the petrous bone ends short of the way to the occipital bone leaving a gap between its apex, the occipital bone & the root of pterygoid plate, this irregular gap is called foramen lacerum which is closed from below during life but its upper part remains patent to transmit the ICA as it emerges from the petrous bone.

16-The carotid canal: a circular opening in the undersurface of the petrous bone through which the ICA enters the bone & passes inside it to emerge from its apex in the upper part of foramen larerum. The carotid sheath is applied at its margins.

17-The tympanic plate: is a V-shape plate which is applied to the undersurface of the temporal bone forming the external auditory canal. Its lower free edge is sharp & gives attachment to the deep layer of parotid fascia. The plate is pushed slightly ateriorly in a curve, this push is produced by the position of the styloid process which lies behind the tympanic plate, at this curved part the parotid fascia is thickened from the styloid process down to the mandible forming the stylomandibular ligament.

18-The styloid process: a hook-like process projects downward & anteriorly from behind the tympanic plate, its ossification is variable & consequently its length is variable too. It gives attachment to three muscles & a ligament, the muscles are; stylopharyngeus, styloglossus & stylohyoid, the ligament is the stylohyoid ligament.

19-The stylomastoid foramen: lies behind the styloid process between it & the mastoid process. It transmits the facial nerve & stylomastoid branch of the posterior auricular artery.

20-The jugular foramen: a backward facing notch in the posterior part of the petrous bone faces the jugular notch of the occipital bone embracing between them the large jugular foramen which transmits; IJV, inferior petrosal sinus, glossopharyngeal, vagus & accessory nerves.

21-The mastoid process: discussed.

22-The digastric notch: deep to the mastoid process lies a deep elongated notch for the origin of the posterior belly of digastric muscle.

23-The occipital condyles: a pair of oval articulating surfaces, convex downward to fit the superior articular facets of C1, they are applied in an anteromedial obliquity to the anterior ½ of foramen magnum.

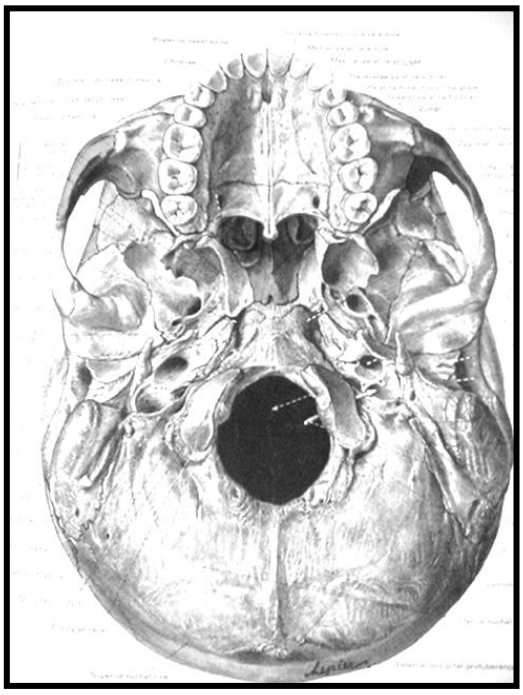

24-Anterior condylar canal: perforates the root of the occipital condyle & transmits the hypoglossal nerve.

25-Posterior condylar canal: smaller than (24) & transmits emissary veins between the suboccipital venous plexus & intracranial venous sinuses.

26-Foramen magnum: is the largest foramen in the skull, lies in the occipital bone, it is oval in antero-posterior axis & transmits; medulla & its meninges, the anterior & posterior spinal arteries, spinal accessory nerve, vertebral arteries, articular structures.

27-The mandible: bounds the anterior ½ of the

skull & shows the following landmarks:
a)The head: lies in the mandibular fossa.
b)The neck: is the thin part of the bone which lies below the head.
c)The coronoid process: is the upward projection which lies anterior to the head.
d)The mandibular notch: between the head & neck behind and the coronoid process in front.
e)The ramus: is the part of the bone which lies vertical between the bode below & the processes above.
f)The mandibular foramen:lies on the medial side of the ramus, a bony spine protects its inlet called the lingula for the attachment of the sphenomandibular ligament. It transmits the inferior alveolar vessels & nerves.
g)The body: is the anteriorly curved horizontal part of the bone which carries the alveolar process & teeth.
h)The myelohyoid line: a long line on the inner aspect of the body reaches back near the mandibular foramen, it gives attachment to myelohyoid.
i)The superior & inferior genial tubercles: anteriorly, on each side of the symphysis menti lie two shallow spines, the superior & inferior genial tubercles for the attachment of genioglossus & geniohyoid respectively.
j)The digastric fossa: a light depression in the lower border of the mandible near the chin for the attachment of the anterior bellies of digastric.

THE CRANIUM:

The calvaria:

Is the inside of the vault of the skull, it shows some landmarks:
1-The groove for superior sagittal sinus: this long depression grooves the sagittal suture from its inside & broadens as it goes backward because it collects more blood. It ends on the internal occipital protuberance.
2-The lateral blood lakes: on each side of the above sinus near the vertex lie a variable-size depression which marks the lateral blood lakes.

The anterior cranial fossa:

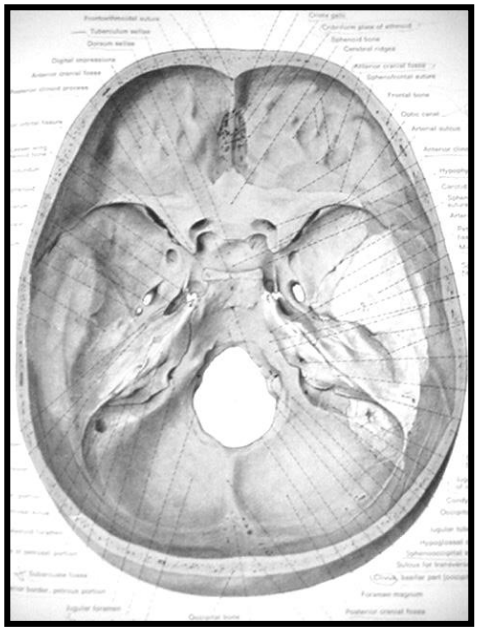

***The floor:** is formed by the orbital plate of the frontal bone (anterior 2/3) completed posteriorly by the lesser wing of sphenoid. A gap in the midline between the two orbital plates is closed by the cribriform plate of the ethmoid bone & crista galli. The floor of this fossa forms the roof of the orbit (laterally), the ethmoidal air cells (intermediate) & the nasal cavity (in the midline).

***Boundaries:** the fossa is bounded anteriorly & laterally by the frontal bone and posteriorly by the free edge of the lesser wing of sphenoid.

***Stigmata:**

1-The frontal crest: a midline sharp ridge lies between the cribriform plate & the anterior wall of the fossa, it gives attachment to the falx cerebri (a meningeal fold).

2-The crista galli: is the midline ridge which is centered on the cribriform plate, it represents the upper part of the vertical plate of the ethmoid & it gives attachment for the falx cerebri.
3-The cribriform plate: is the horizontal plate of the ethmoid which roofs the nasal cavity & is perforated by many foramina for the passage of the olfactory rootlets, the ethmoidal foramina also lie in this plate laterally.
4-The anterior clinoid process: as the posterior free border of this fossa curves medially, it will end in a sharp projection faces posteriorly called the anterior clinoid process for the attachment of the tentorium cerebelli (another meningeal fold).

The middle cranial fossa:

***The floor:** is formed anteriorly by the greater wing of sphenoid completed laterally by the squamous temporal & posteriorly by the petrous temporal. The narrow midline part of the floor which connects the two fossae is formed by the body of sphenoid. The floor of the fossa roofs the infratemporal fossa laterally & the sphenoidal air cells in the midline.

***Boundaries:** the fossa is bounded anteriorly by the sphenoidal wings separated from each other by the superior orbital fissure, laterally the greater wing of sphenoid & squamous temporal bones curves from the floor upward to form the lateral wall of the fossa & posteriorly the petrous bone closes it.

***Stigmata:**

1-The hypophyseal fossa: is the midline deep notch in the sphenoid body to lodge the pituitary gland. The fossa with its anterior wall (tuberculum sellae) & posterior wall (dorsum sellae) look like the Turkish saddle & therefore this complex is called the sella turcica.
2-The middle clinoid processes: two shallow projections anterior to the pituitary fossa & posterior to the optic sulcus.
3-The dorsum sellae: is the back of the pituitary fossa.
4-The posterior clinoid processes: are the two projections that project from each side of the dorsum sellae.
5-The optic canal: a rounded foramen medial to the anterior clinoid process leads from the MCF to the orbit & transmits the optic nerve & the ophthalmic artery.
6-The optic sulcus (groove): is the shallow sulcus which connects the the two optic canals.
7-The foramen rotundum: a rounded foramen in the anterior wall of the fossa transmits the maxillary nerve from the fossa to the spheno-palatine fossa.
8-The superior orbital fissure: is the elongated gap between the two wings of the sphenoid in the anterior wall of the fossa, it leads to the orbit & transmits the oculomotor, trochlear abducent nerves & the ophthalmic division of the trigeminal nerve and the superior orbital veins.
9-Foramina ovale, spinosum & lacerum: discussed.
10-The groove for the middle meningeal artery: a clear groove starts in the floor of the fossa from foramen spinosum & soon divides into anterior & posterior groove according to the branches of the middle meningeal artery.

11-The arcuate eminence: a laterally placed shallow eminence in the anterior wall of the petrous bone (posterior wall of the MCF), it is produced by the underlying superior semicircular canal of the internal ear.
12-The hiatus of canal for greater petrosal nerve: a slit-like opening in the anterior wall of the petrous bone infero-medial to the arcuate eminence. From this slit a shallow groove descends in the direction of foramen lacerum produced by the greater petrosal nerve.
13-The groove for the lesser petrosal nerve: not always seen, it lies antero-inferior to that of the greater petrosal nerve & leads in the direction of foramen ovale.
14-The trigeminal fossa: a depression in the anterior surface of the petrous apex carries the trigeminal ganglion.

The posterior cranial fossa:

The floor: is formed mainly by the occipital bone completed laterally by the temporal bone.

Boundaries: the PCF is bounded anteriorly by the occipital bone as it forms the dorsum sellae in the midline and petrous temporal bone lateral to it, laterally by the mastoid part of the temporal & posteriorly by the occipital bone.

Stigmata:

1-Foramina magnum, jugular & hypoglossal: discussed.
2-The internal acoustic meatus: an oval foramen located in the anterior wall of the fossa to transmit the facial, vestibulo-cochlear nerves & nervus intermedius together with the labyrinthine artery.
3-The vestibular aqueduct: a very small slit lies postero-lateral to the internal acoustic meatus & transmits the endolymphatic duct of the membranous labyrinth.
4-The internal occipital protuberance: lies opposite to the external one on the inner aspect of the occipital bone.
5-Grooves for the transverse sinuses: from the internal occipital protuberance two grooves pass one to each side of the protuberance representing the transverse sinuses.
6-Grooves for the sigmoid sinuses: at the root of the petrous bone laterally on the deep surface of the mastoid bone the transverse sinuses descend down in an S-shape deep groove on the inside of the mastoid bone to end in the jugular foramen.
7-The internal occipital crest: from the internal occipital protuberance to the foramen magnum lies in the midline a blunt crest for the attachment of the falx cerebelli (a third meningeal fold).
8-The cerebellar fossae: one on each side of the internal occipital crest to lodge the cerebellar hemispheres.

By the end of these lectures the students will demonstrate the ability to assimilate and integrate information from lectures, practical sessions, tutorial, and students activities on the anatomy of the human body regarding head and neck ,Skull. Also,student will demonstrate the ability to gain practical skills enabling him to recognize and differentiate bonesof Skull .The student can gain skill in reading and understanding radiological images of the Skull and identify through palpation the anatomical landmarks on the surface of the body regarding Skull .