Ashur University
College of Medicine

Grade 2
PHYSIOLOGY OF
GASTROINTESTINAL TRACT
(GIT)
DS - Medicine

Gastroenterology & Hepatology: Introduction



Ass. Professor Internal Medicine

Dr.Qasim Razzaq Radhi

5/2/2025

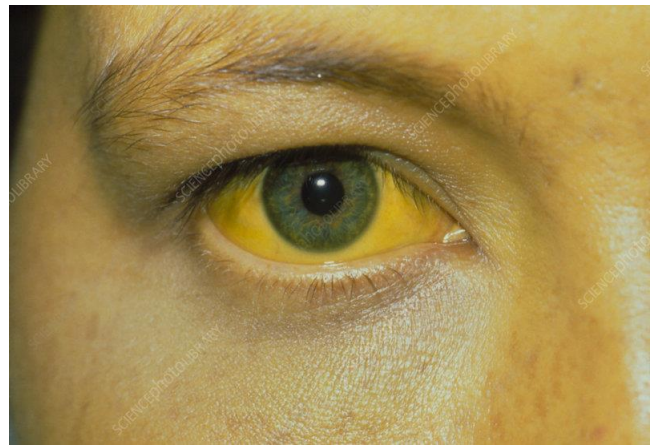

GIT anatomy :

Includes:

- **Mouth**
- **Pharynx**
- **Esophagus**
- **Stomach**
- **Small intestine**
- **Large intestine**
- **Anal canal**

Accessory organs:

- **Liver**
- **Gallbladder**
- **Pancreas**

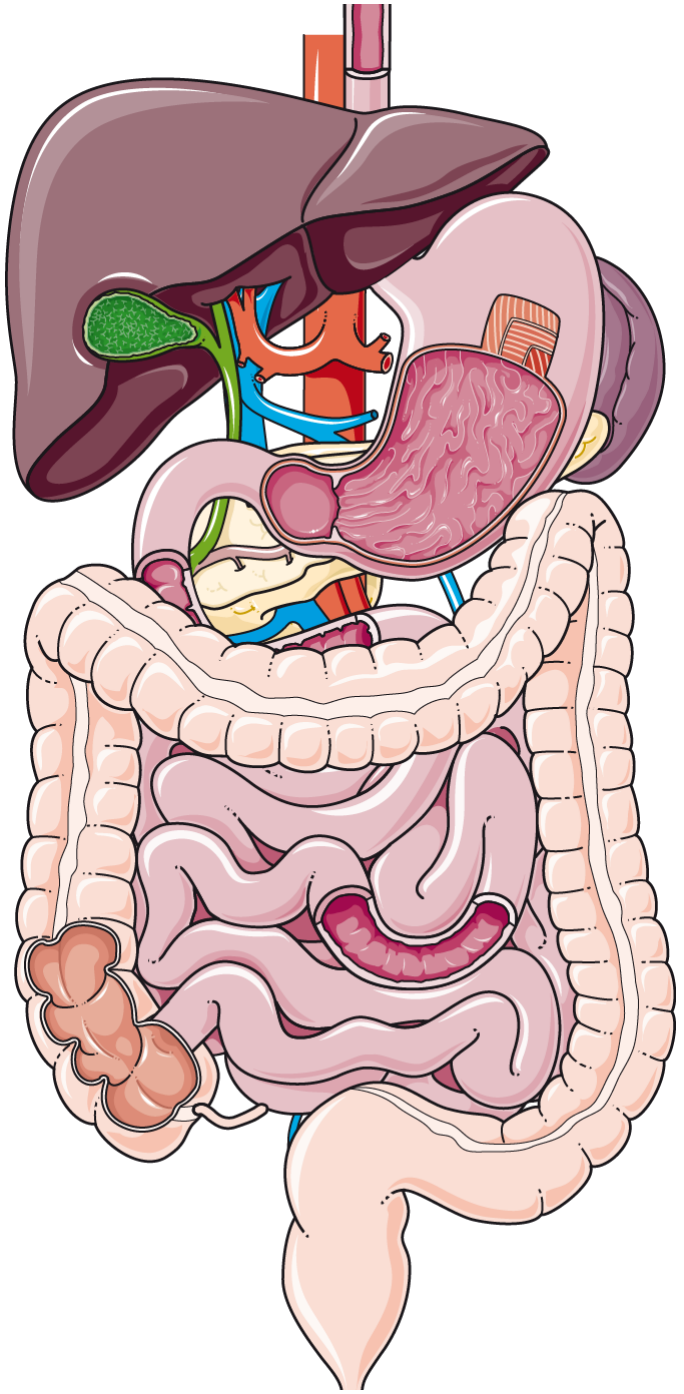

GI Symptoms - Mouth symptoms:

Bad breath (halitosis) due to gingival, dental or pharyngeal infection.

Dry mouth (xerostomia) are common mouth → symptoms

Painful mouth :

Causes of sore lips, tongue or buccal mucosa include:

Aphthous ulcers →

Deficiencies : iron, folate, vitamin B12 or Vit. C.

Inflammatory bowel disease (IBD) →

and coeliac disease, associated with mouth ulcers.



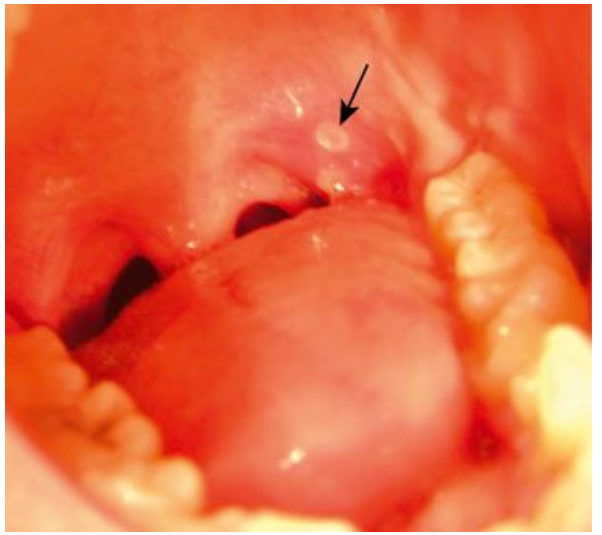



GI Symptoms

Dysphagia : difficult swallowing, food or drink sticks when person swallow.

Globus sensation : Feel a lump in the throat without organic cause .

Odynophagia : Pain during swallowing, usually from **gastro esophageal reflux** or **candidiasis** .→ →

Aphagia : mean complete esophageal obstruction

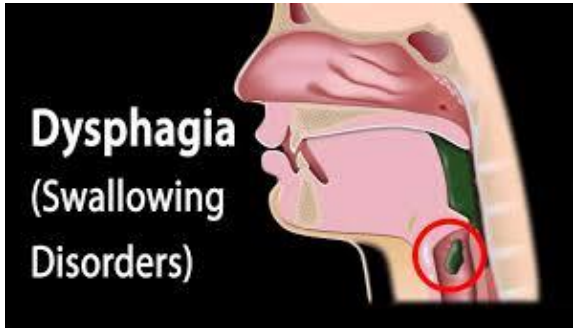

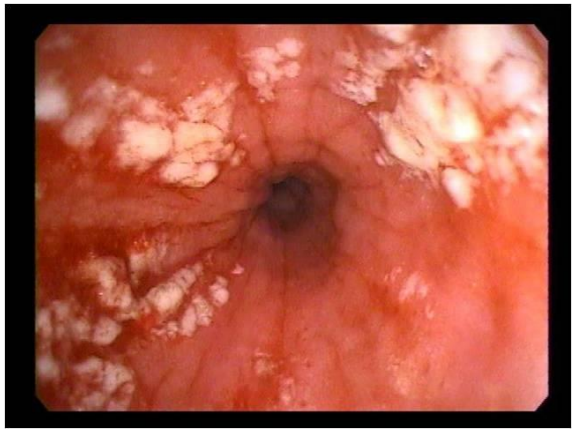

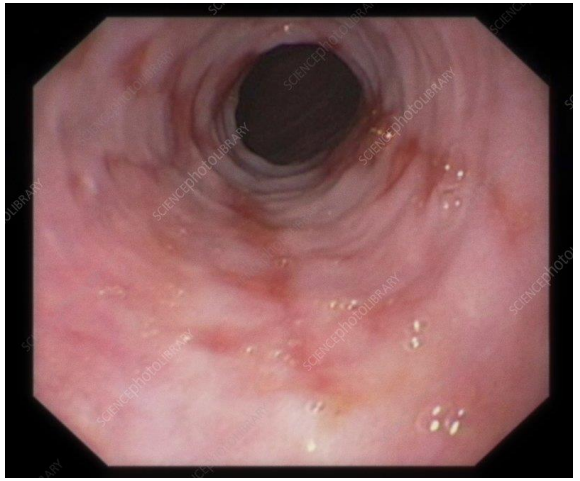

Nausea: is the subjective feeling of a need to vomit. Or a feeling of sickness in the stomach characterized by an urge to vomit. Or a sensation of discomfort in the stomach involuntary urge to vomit .

Vomiting (emesis): is the oral expulsion of gastrointestinal contents resulting from contractions of gut and thoraco-abdominal wall musculature.

Receptors on the floor of the fourth ventricle of the brain represent a **chemoreceptor trigger zone**, known as the area stimulation of which can lead to vomiting.

Regurgitation: effortless passage of gastric contents into the mouth.

Rumination: is the **repeated regurgitation of stomach contents**, which may be rechewed and reswallowed. In contrast to vomiting, these phenomena often exhibit volitional (voluntary) control and the content is not acidic.

Dyspepsia: is a nonspecific term that include a variety of complaints including nausea, vomiting, heartburn, regurgitation.

Dyspepsia is pain or discomfort centered in the upper abdomen.

In contrast, **'indigestion'** is a term commonly used by patients for ill-defined symptoms from the upper gastrointestinal tract.

Clusters of symptoms are used to classify dyspepsia:

- **Reflux-like dyspepsia** (heartburn-predominant dyspepsia)
- **Ulcer-like dyspepsia** (epigastric pain relieved by food or antacids)
- **Dysmotility-like dyspepsia** (nausea, belching, bloating and premature fullness (early satiety).

Dyspepsia that is worse with an empty stomach and eased by eating is typical of peptic ulceration.

Dyspepsia … cont.

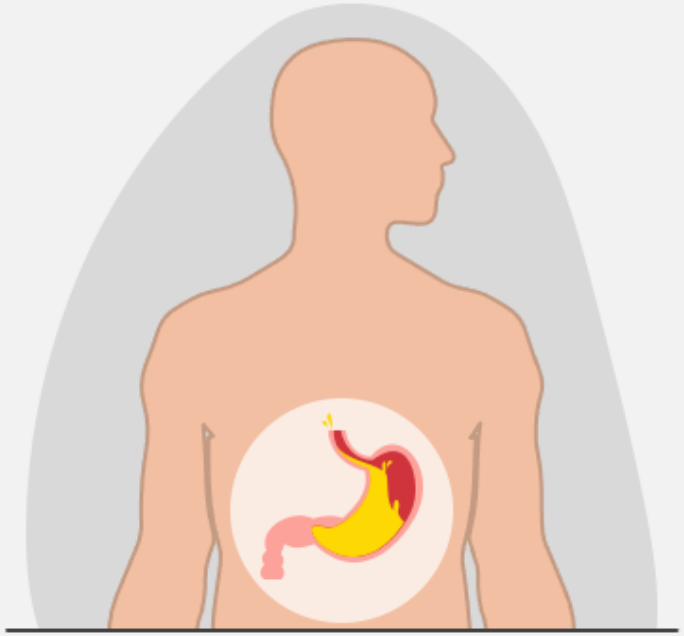

Dyspepsia or indigestion refers to a condition in which a person suffers from pain in the abdominal region accompanied by heartburn and difficulty in digestion of food.

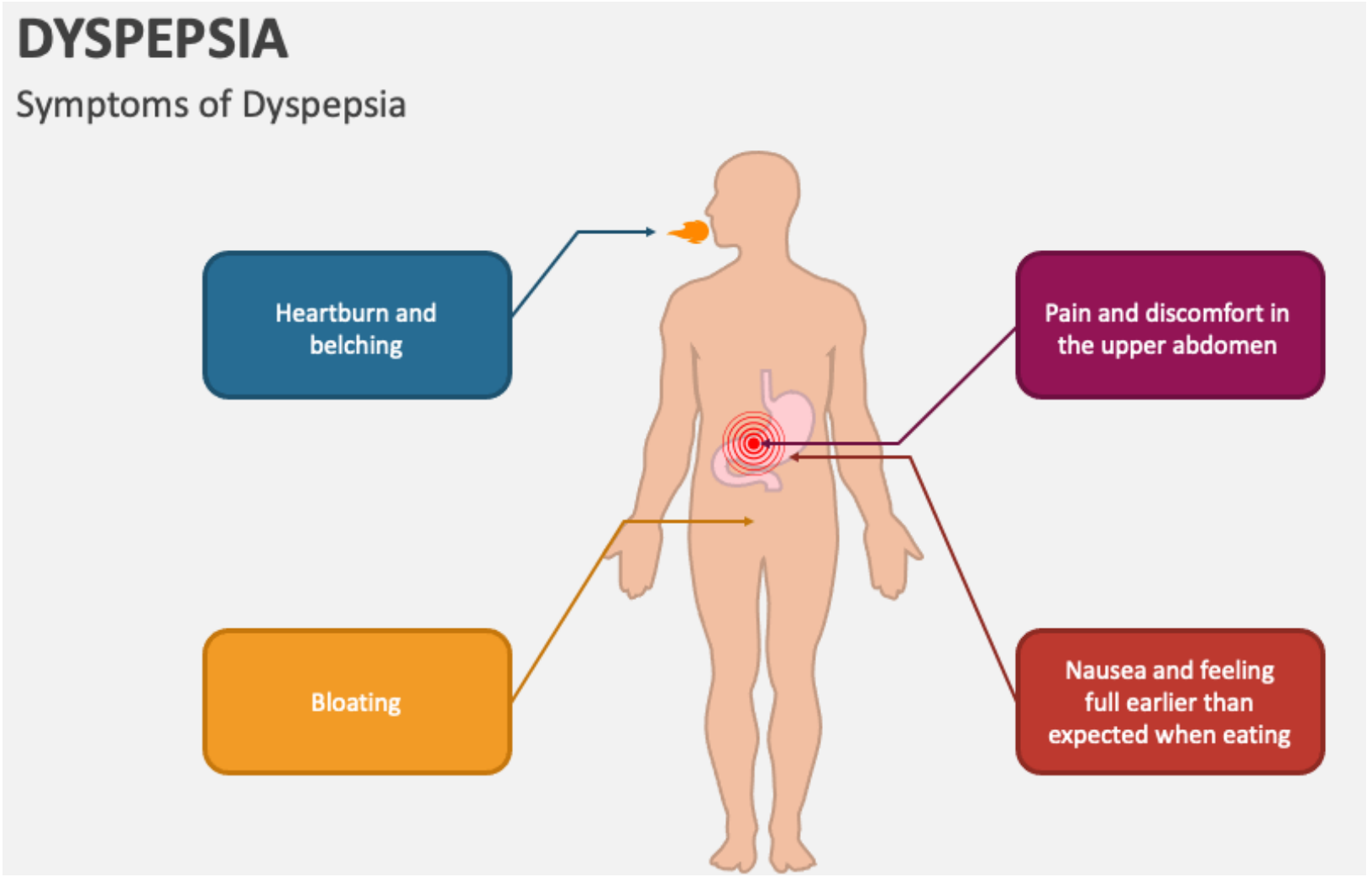

Bleeding from the gastrointestinal (GI) tract may present in five ways:

① **Hematemesis:** is the **vomiting of blood** OR **"coffee-grounds"** vomitus.



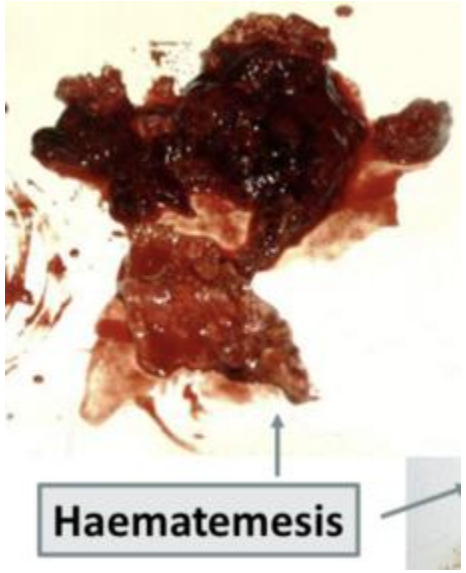

② **Melena:** is **black, tarry, foul-smelling stool**. Result from upper gastrointestinal bleeding.



Melaena



③ **Bleeding per rectum : blood is mixed with stool**, coats the surface of the otherwise normal stool.

④ **Hematochezia:** is the passage of **bright red or maroon blood** from the rectum.



⑤ **Occult GI bleeding (GIB):** may be identified in the absence of overt bleeding by a

fecal occult blood test or

the presence of iron deficiency.

Symptoms of blood loss or anemia:

such as lightheadedness, syncope,

angina, or dyspnea.



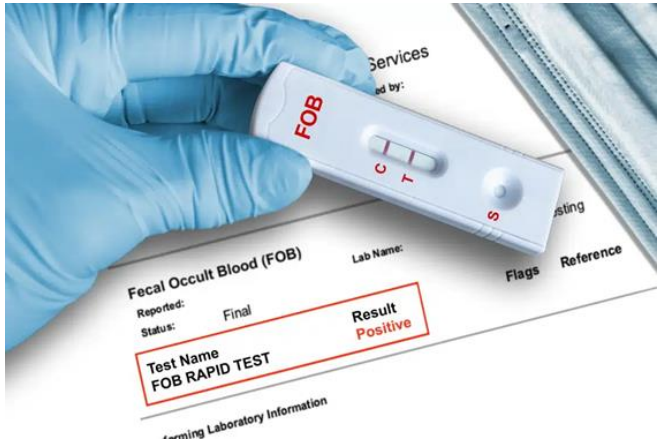

Abdominal Pain

It is important to remember that pain severity does not necessarily correlate with the severity of the underlying condition.

Some Mechanisms of Pain Originating in the Abdomen:

1- Inflammation of the Parietal Peritoneum: The pain is steady and is located directly over the inflamed area.

2- Obstruction of Hollow Viscera: The pain is classically described as intermittent, or colicky, It is not well localized as the pain of parietal peritoneal inflammation.

3- Vascular Disturbances: The pain of **embolism** or **thrombosis** of the superior mesenteric artery or that of impending rupture of an **abdominal aortic aneurysm** may be severe and diffuse .

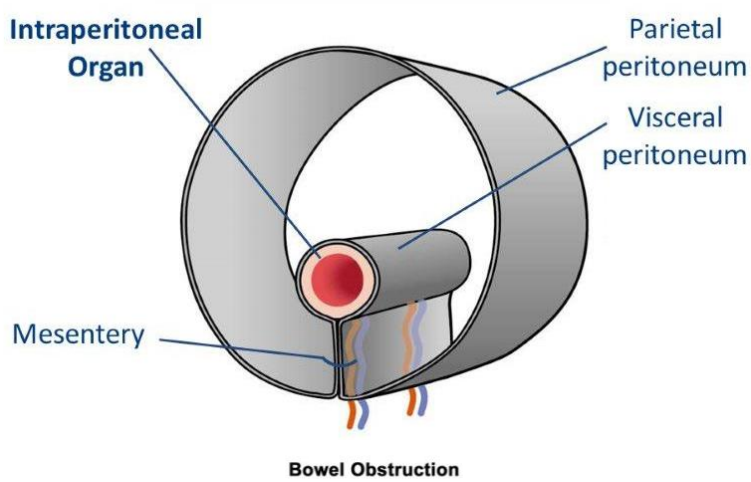

Bowel Obstruction

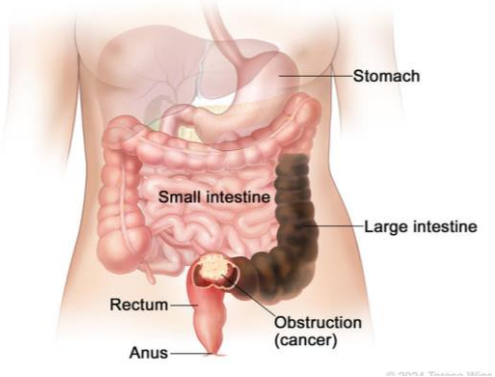

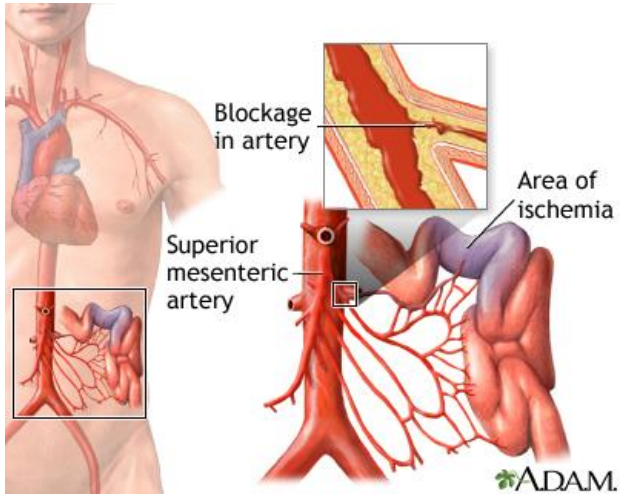

4- Abdominal Wall: Pain arising from the abdominal wall is usually constant and aching. Movement, prolonged standing increase the pain.



5- Metabolic Abdominal Crises : Pain of metabolic origin may simulate almost any other type of intraabdominal disease, such as **diabetic ketoacidosis**.



6- Neurogenic Causes: occur in diseases that injure sensory nerves. It has a burning character and is usually limited to the distribution of a given peripheral nerve. Example; **Herpes zoster**.



igure 1 A cutaneous vesicular eruption involving the area of th
8-T12 dermatomes on the right

Abdominal Pain … cont.

Site: Pain arising from foregut structures (stomach, pancreas, liver and biliary system) is localised above the umbilicus.

Onset : Sudden onset suggests a hollow viscus perforation (usually due to peptic ulceration)

Character : colicky, constant, sharp or dull, wakes patient at night. Colicky pain, It arises from hollow structures, as in small or large bowel obstruction.

Radiation : Pain radiating from the right hypochondrium to the shoulder or inter scapular region may reflect diaphragmatic irritation, as in acute cholecystitis .

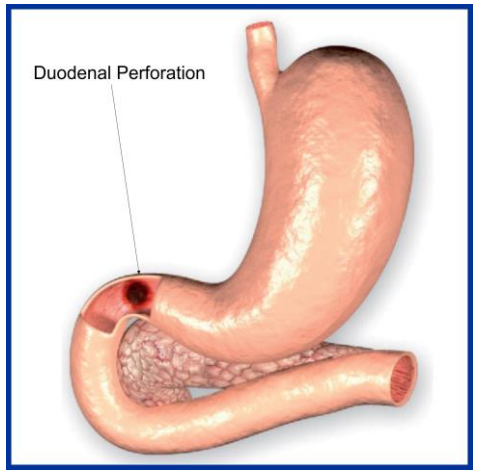



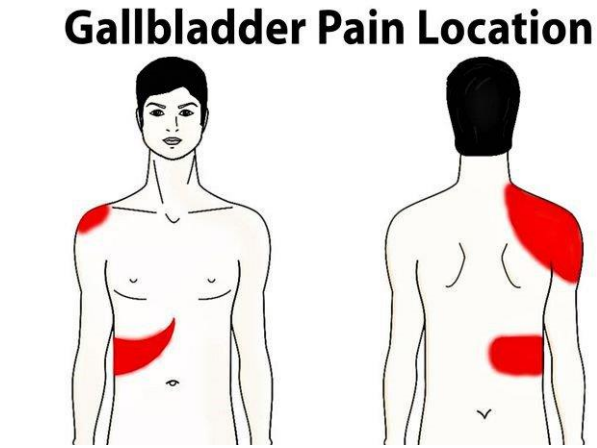

Abdominal Pain … cont.

Associated symptoms: vomiting, dyspepsia, altered bowel habit .

Timing : Frequency , Duration.



Exacerbating and relieving factors: Pain exacerbated by movement or coughing suggests inflammation.→

Severity: Excruciating (sever) pain, poorly relieved by opioid analgesia, suggests an ischaemic vascular event, such as **bowel infarction** or ruptured **Abdominal Aortic Aneurysm (AAA)** → →

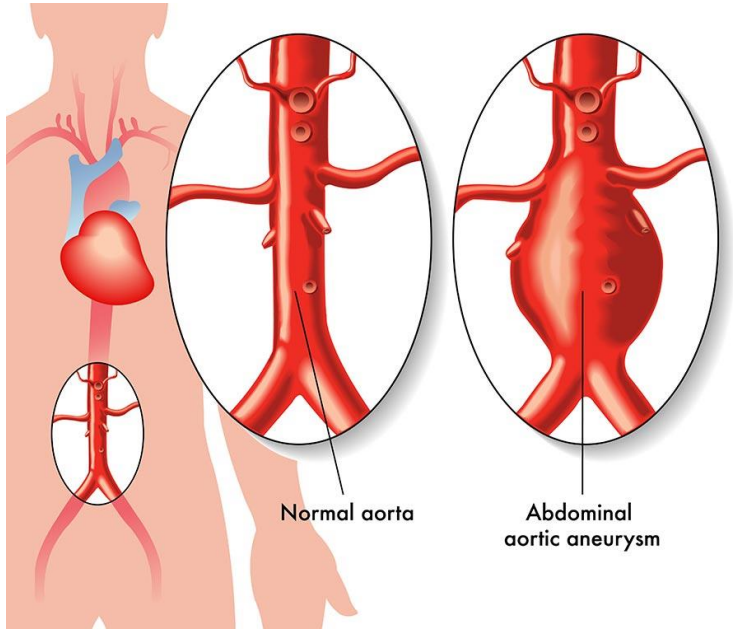

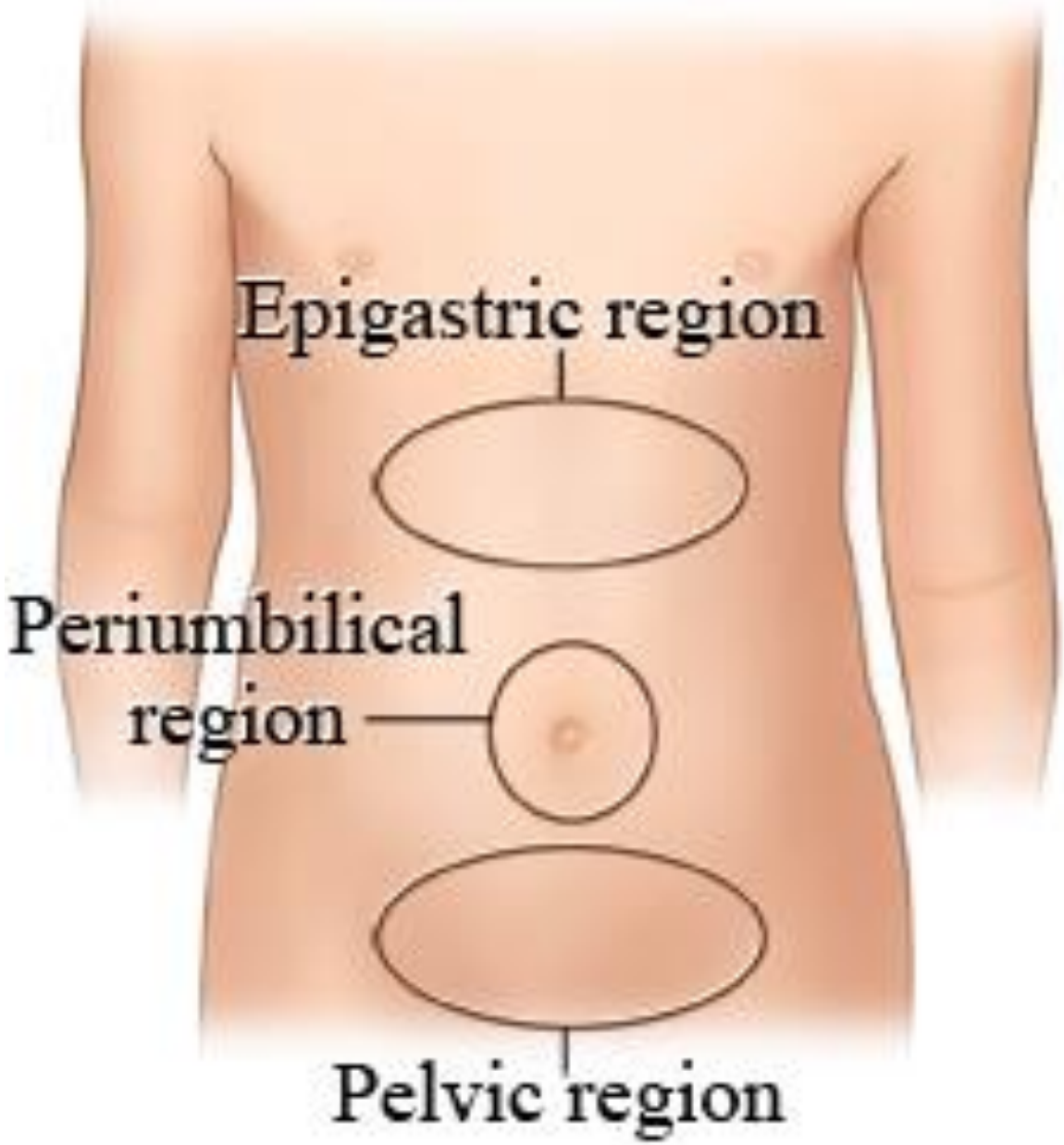
Epigastric region
Periumbilical region
Pelvic region

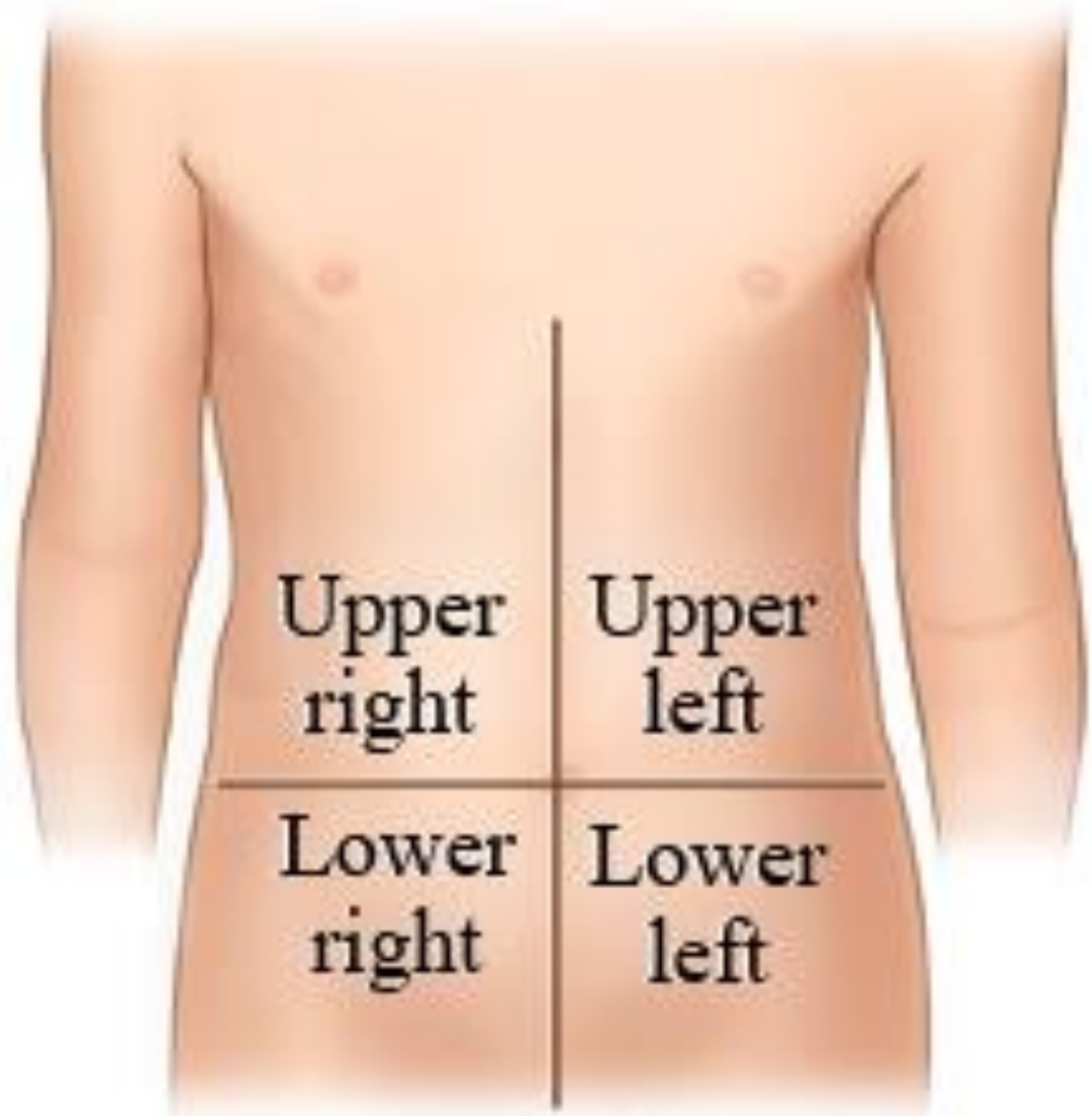
Upper right
Upper left
Lower right
Lower left

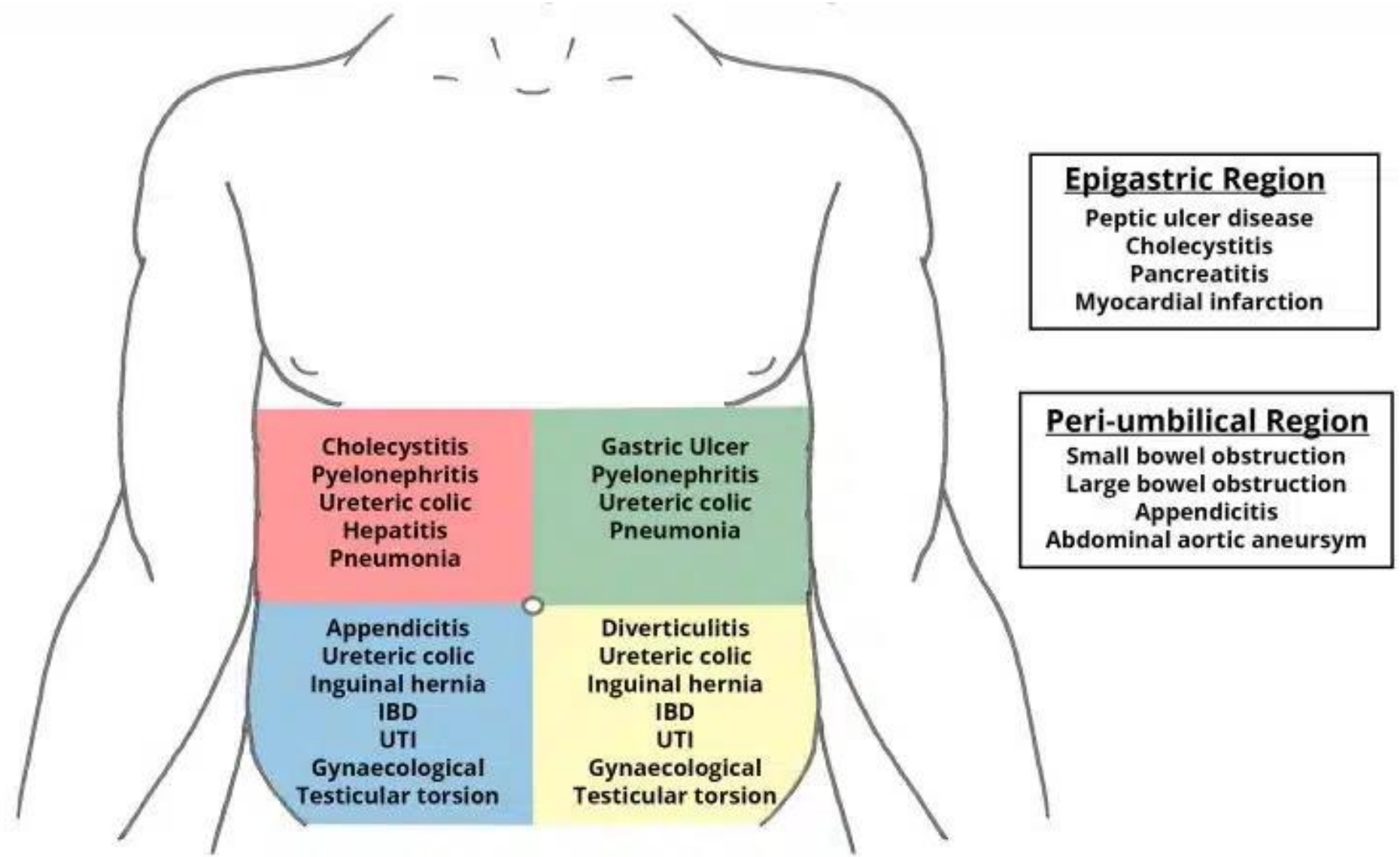

Figure : Differential diagnoses for pain felt in the different regions of the abdomen.

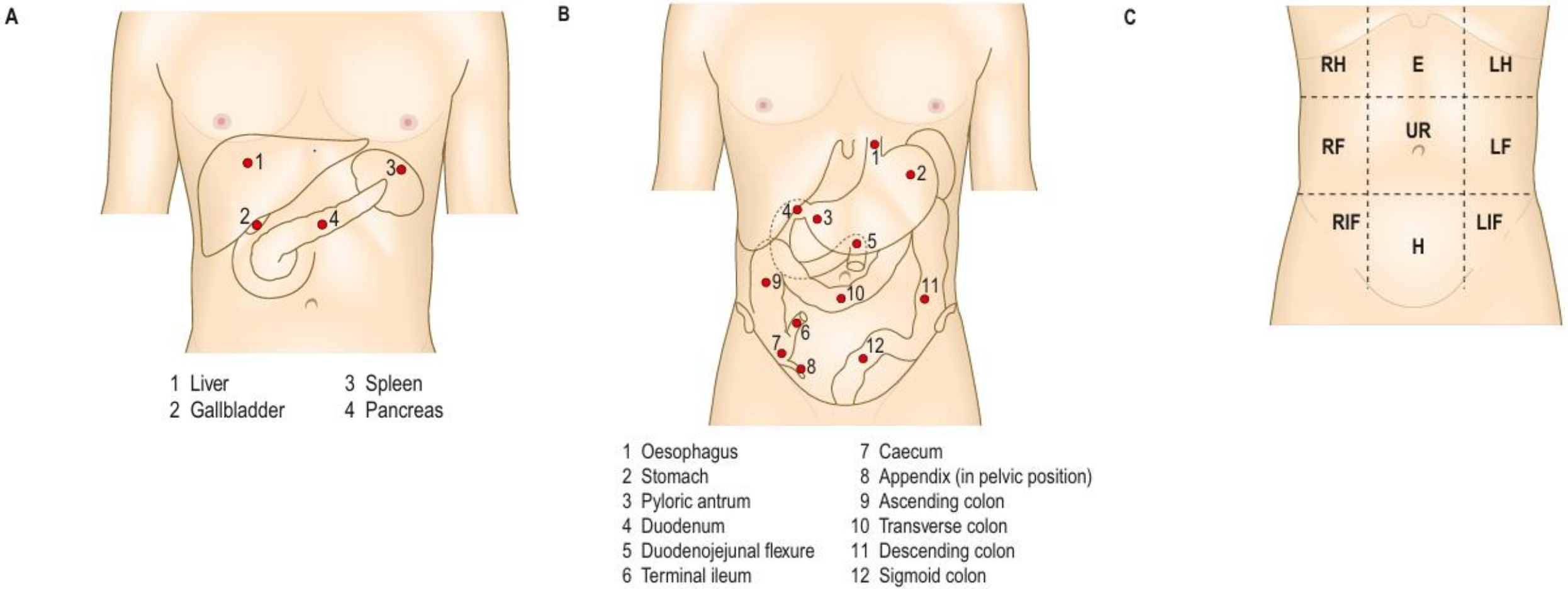

Fig. Surface anatomy. A Abdominal surface markings of non alimentary tract viscera. B Surface markings of the alimentary tract. C Regions of the abdomen. E, epigastrium; H, hypogastrium or suprapubic region; LF, left flank or lumbar region; LH, left hypochondrium; LIF, left iliac fossa; RF, right flank or lumbar region; RH, right hypochondrium; RIF, right iliac fossa; UR,umbilical region.

Abdominal Pain … cont.

Abdominal pain based on location

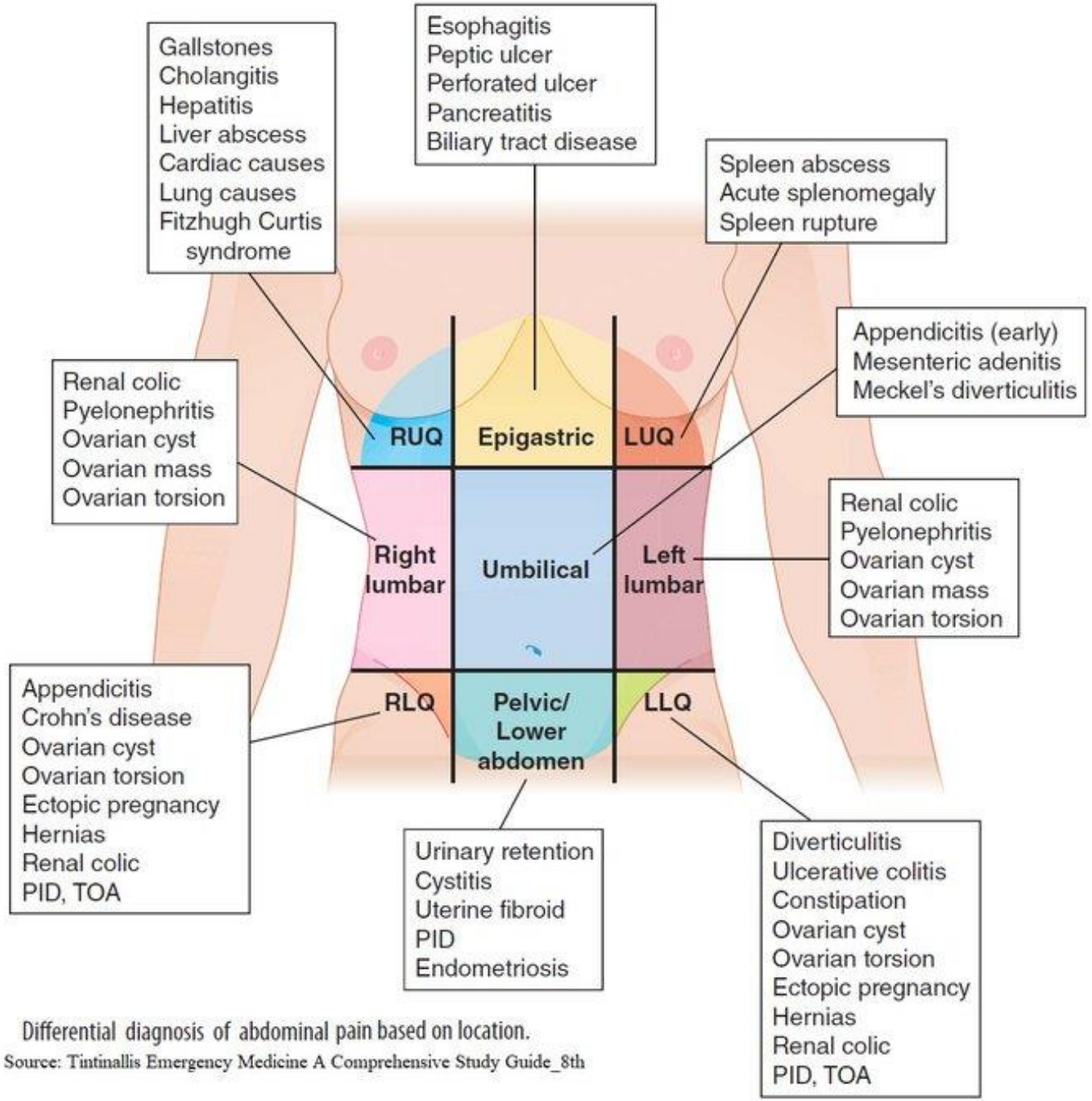

Differential diagnosis of abdominal pain based on location.
Source: Tintinallis Emergency Medicine A Comprehensive Study Guide_8th

TOA : Tubo-Ovarian Abscess

PID : Pelvic Inflammatory Disease

Abdominal Swelling or Distention

The causes of abdominal swelling can be remembered by the Six F:

1- Flatus.

2- Fat.

3- Fluid.

4- Fetus.

5- Feces.

6- Fatal growth: (often a neoplasm)



- **Weight loss** may be ‘physiological’ due to dieting, exercise, starvation, or the decreased nutritional intake which accompanies old age.

Weight loss of more than 3 kg over 6 months is significant.

- **Loss of appetite (anorexia)** mean that hunger feeling is absent—a person with anorexia has no desire to eat. In contrast, a person with an eating disorder such as:

① **Anorexia nervosa** : eating disorder have a very low body weight, an intense **fear of gaining weight** or

② **Bulimia nervosa :** person regularly eats excessive amounts of food **(binge eats)** and then attempts to eliminate **(purge)** the consequences of overeating by vomiting, taking laxatives or diuretics, fasting or exercising excessively. This is often referred to as **“binge and purge.”**

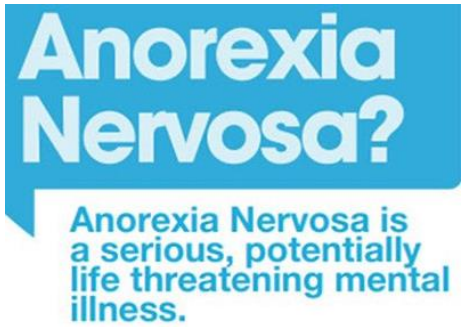



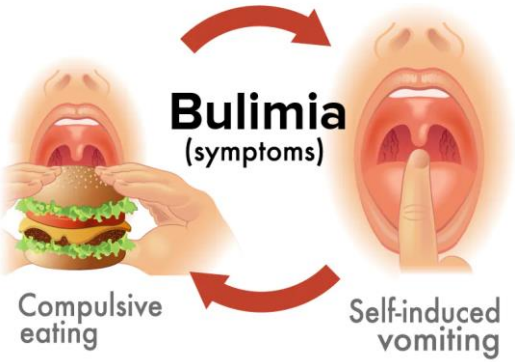

Jaundice or icterus : Jaundice is a yellowish discolouration of the skin, sclerae and mucous membranes caused by hyperbilirubinaemia. There is no absolute level at which jaundice is clinically detected but, in good day light, most clinicians will recognise jaundice when **bilirubin levels exceed 2 – 3 mg/dL**







Diarrhea: is Passage of abnormally liquid or unformed stools at an increased frequency. For adults on a typical normal diet, **stool weight >200 g/d can generally be considered diarrhea**. Diarrhea classified into :

① **Acute diarrhea** lasting les than 2 weeks.

② **Persistent diarrhea** lasting from 2- 4 weeks.

③ **Chronic diarrhea** lasting for more than 4 weeks.



Steatorrhea: increase in stool fat excretion of >6% of dietary fat intake.

Pseudodiarrhea: is the frequent passage of small volumes of stool, is often associated with rectal urgency and accompanies **Irritable bowel syndrome (IBS)** or proctitis.

Fecal incontinence: is the **involuntary discharge of rectal contents** and is most often caused by neuromuscular disorders or structural anorectal problems.

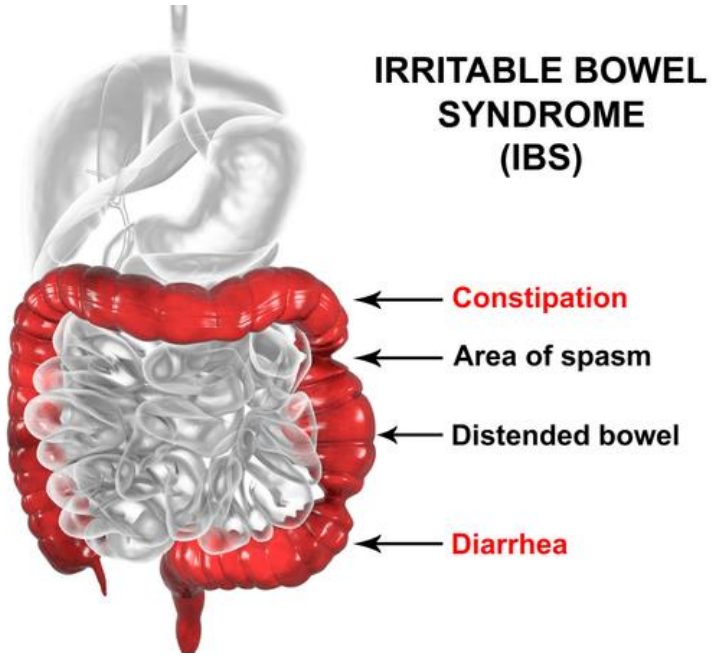

Constipation:

Constipation is the infrequent passage of hard stools.

Constipation refer to persistent, difficult, infrequent.

People have "normal" frequency of from

” three bowel movements(BM) a day

to one every three days”

3 BM in 1 Day – 1 BM in 3 Days.

Use the Bristol stool form scale to describe the stools.

Constipation may be due :

- Lack of dietary fibre, Impaired colonic motility
- Mechanical intestinal obstruction
- Anorectal dysfunction, Irritable bowel syndrome (IBS)
- Colorectal cancer , Hypothyroidism
- Drugs (opiates, iron)

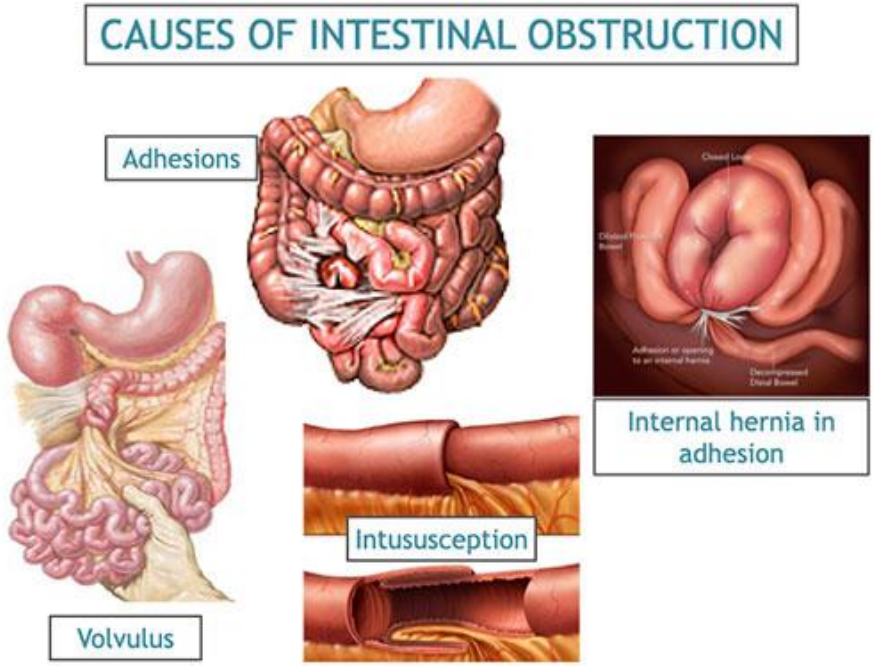



Constipation: . . .cont.



Fig. Bristol stool form scale. Reproduced with kind permission of Dr KW Heaton, formerly Reader in Medicine at the University of Bristol.

Clinical exam of the GIT

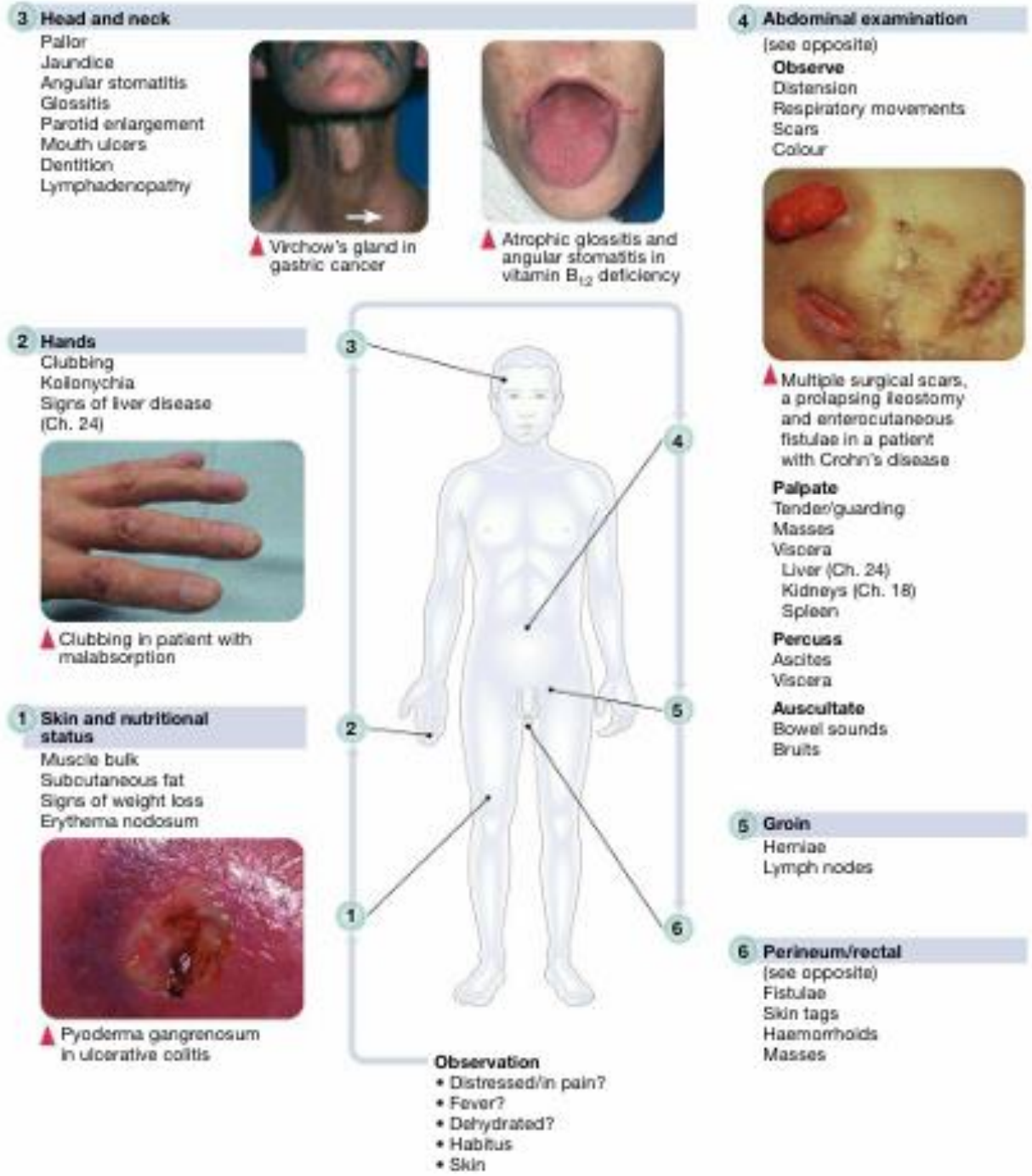



Thank You

