Ashur University
College of Medicine

Grade 2
PHYSIOLOGY OF
GASTROINTESTINAL TRACT
(GIT)
Lec. 3

Lower esophageal sphincter , Movements in the Stomach & Emptying of the Stomach



Ass. Professor Internal Medicine

Dr.Qasim Razzaq Radhi

21/1/2025



Objectives:

- Describe the lower esophageal sphincter.
- Describe the term Achalasia.
- Explain Stomach movements.
- Describe the role of the pylorus in stomach emptying.
- Outline the factors affecting gastric emptying.

Stomach Anatomy & Physiology

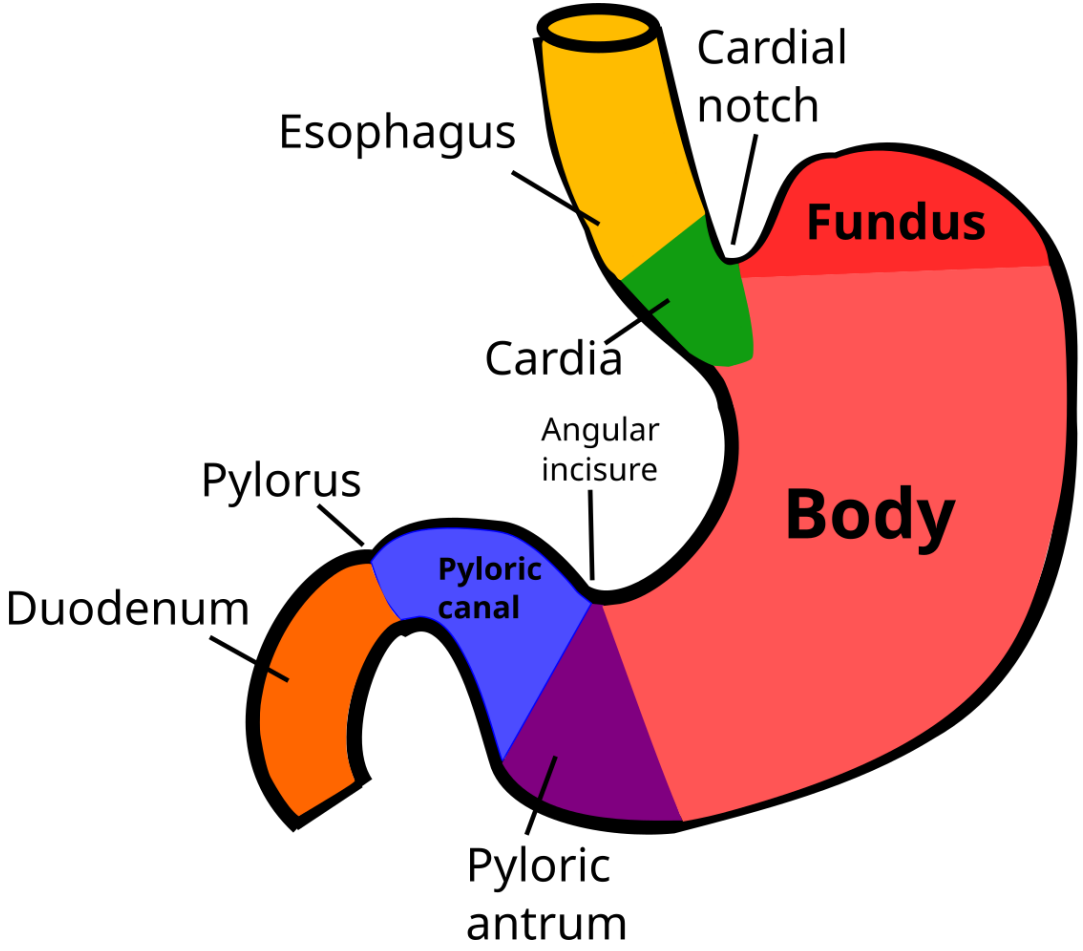

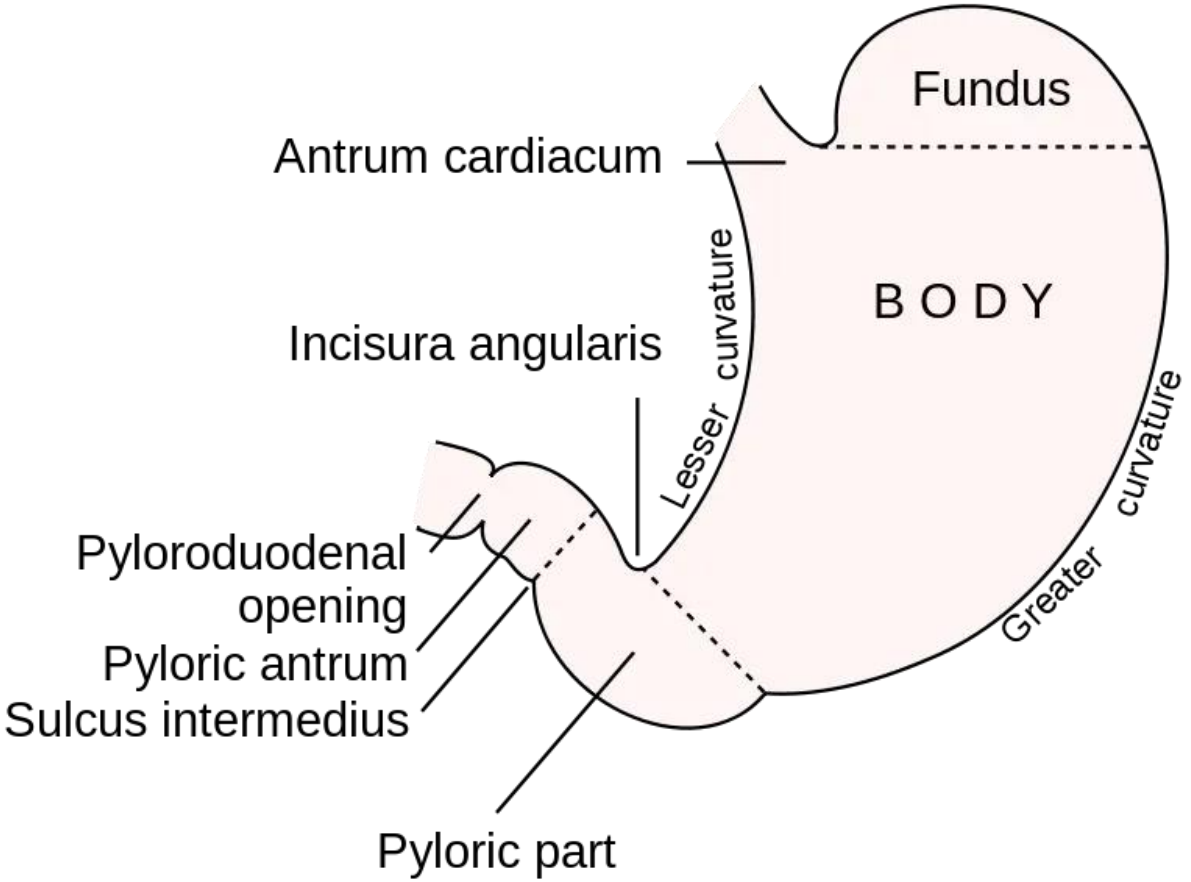

LOWER OESOPHAGEAL SPHINCTER (LOS)

LOWER ESOPHAGEAL SPHINCTER (LES)

- **The lower Oesophageal sphincter (LOS) is a physiological sphincter rather than an anatomical sphincter.**
- is tonically active but relaxes on swallowing.
- When there is no swallowing the sphincter is in state of tonic contraction and thus there is no reflux of food from the stomach to the oesophagus.
- During swallowing, this sphincter will relax to allow the food to enter the stomach.
- **LOS is controlled by** both **nervous** and **hormonal** mechanisms.

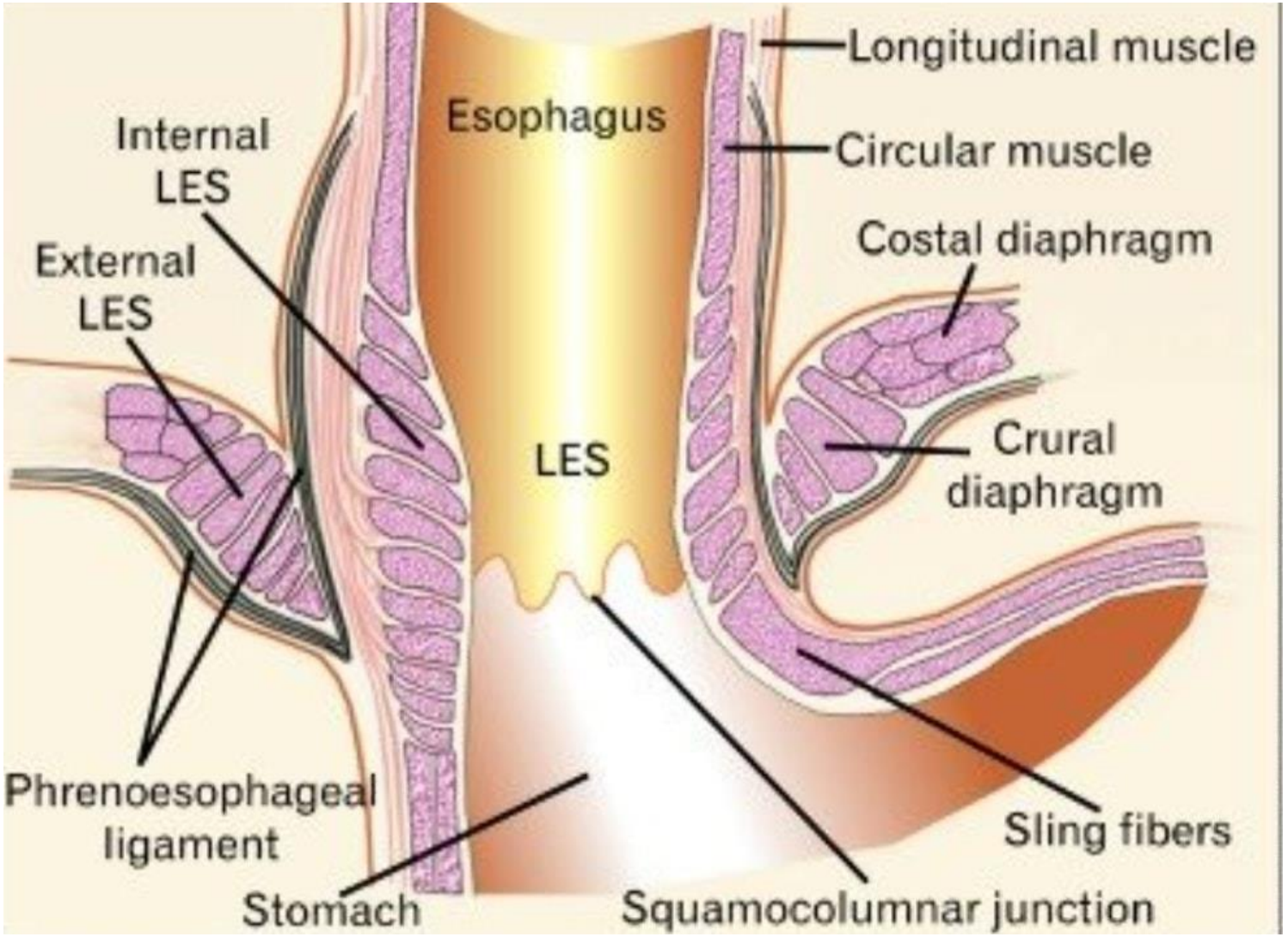

- **FIGURE** :**Esophagogastric junction. Note that the lower esophageal sphincter (intrinsic sphincter) is supplemented by the crural portion of the diaphragm (extrinsic sphincter), and that the two are anchored to each other by the phrenoesophageal ligament.**

- **Nervous control:**
- **Acetylcholine (Ach) from vagal endings cause increase in tonic contraction**.
- **Nitric oxide (NO) and Vasoactive intestinal peptide (VIP)** released from interneurons innervated by other vagal fibers causes it to **relax** (nonadrenergic non-cholinergic NANC).

Ach → intrinsic sphincter contraction

NO and VIP → intrinsic sphincter relaxation

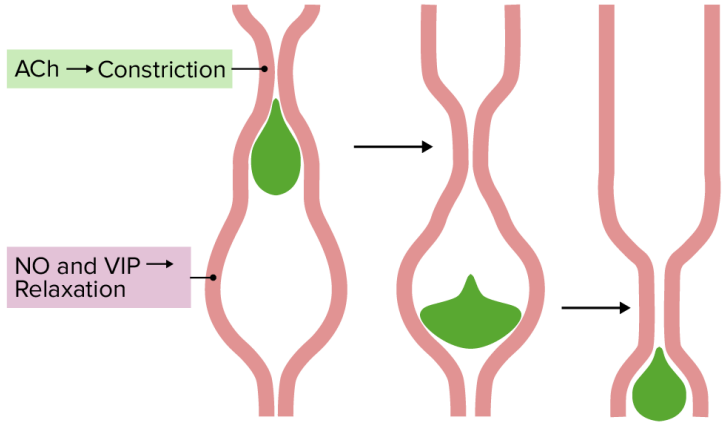

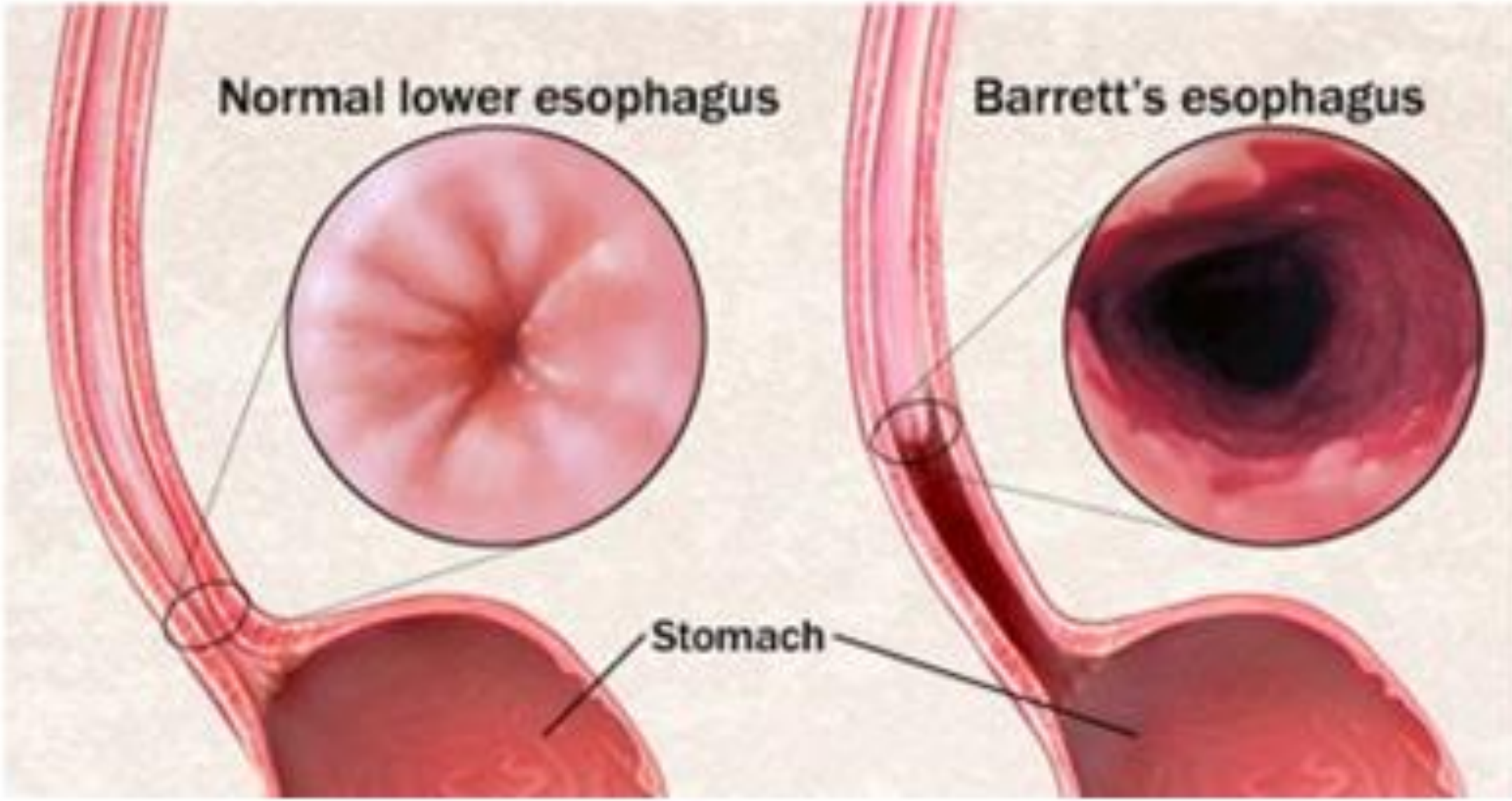
Normal lower esophagus
Barrett's esophagus
Stomach

- **Hormonal control:**

1- Gastrin, Motilin, Pancreatic polypeptide, and Bombesin

contract the LES (increase the tone)

2-Secretin, Cholecystokinin (CCK), Glucagon and Progesterone.

relax the LES (decrease the tone)

- **Estrogen and progesterone** confer their effect on the gastrointestinal tract by increasing nitric oxide synthesis, a muscle relaxant which **decreases smooth muscle tone of the lower esophageal sphincter predisposing patients to gastroesophageal reflux** thus reflux is well documented in the 3rd trimester of pregnancy, and in women taking birth control pills (Contraceptive pills) containing progesterone.
- **Heartburn is a common symptom during pregnancy**.Heartburn is more common in the third trimester, when the uterus is the largest and increase abdominal pressure with pressure on stomach.

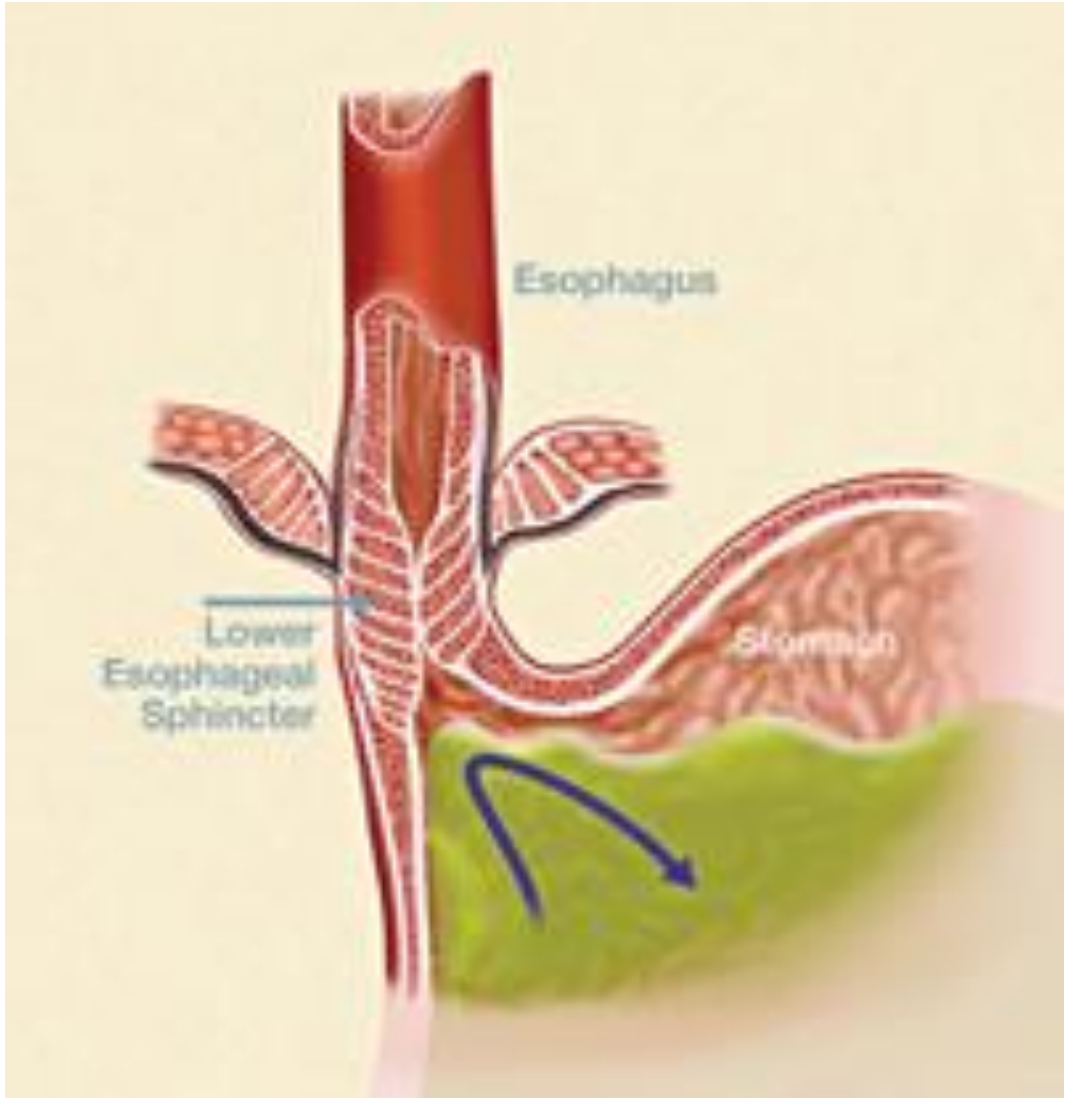

Normal

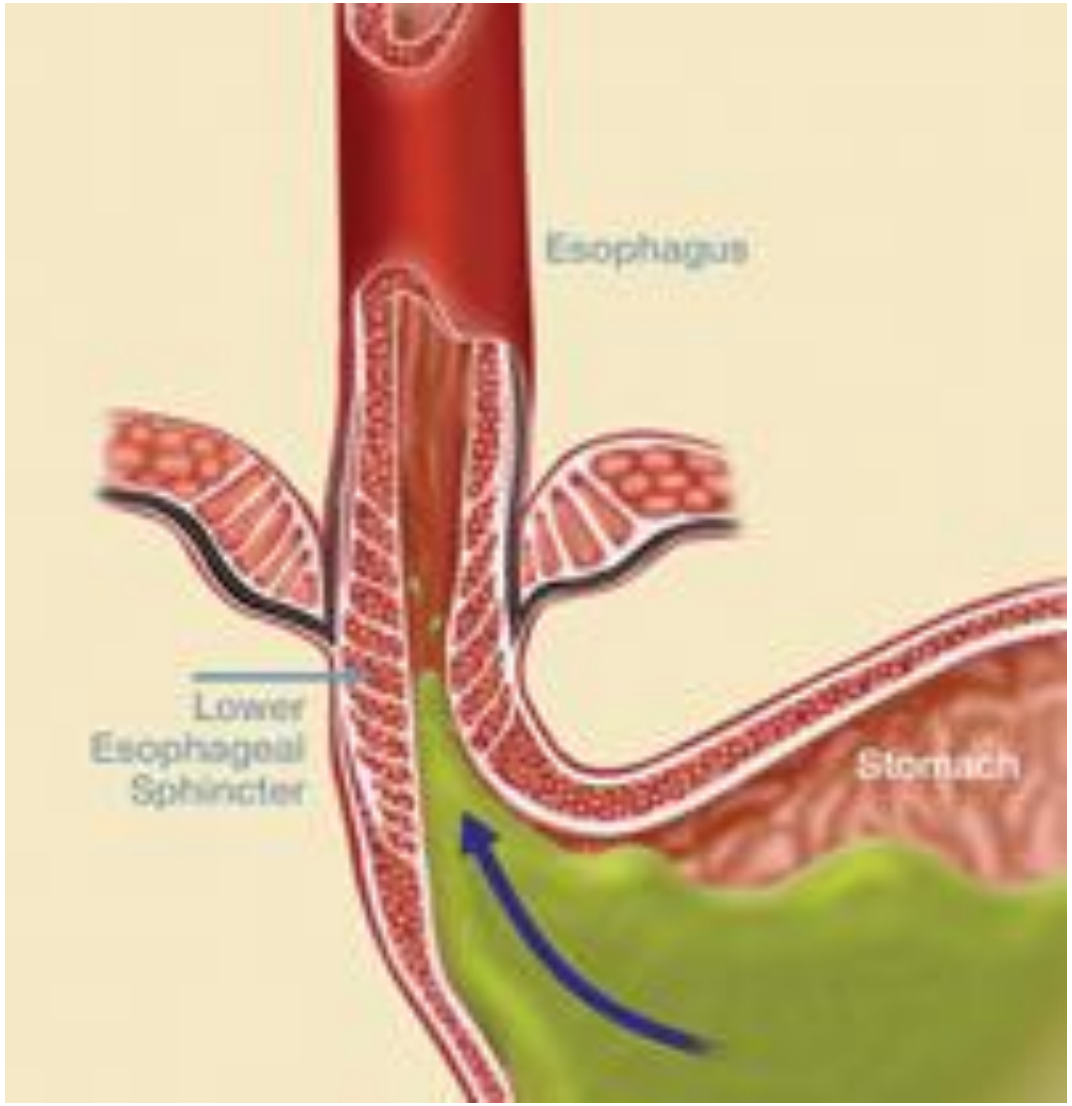

GastroEsophageal Reflux Disease (GERD)

What mechanisms normally prevent reflux of food and fluid from the stomach into the lower oesophagus ?

1-The LES is clearly the most important component.

2- The intraabdominal position of LES just below the diaphragm so that it is reinforced by intraabdominal pressure.

3- The angle of His, also known as the esophagogastric angle, is the **acute angle** , helps to prevent acid reflux of stomach acid into the esophagus.

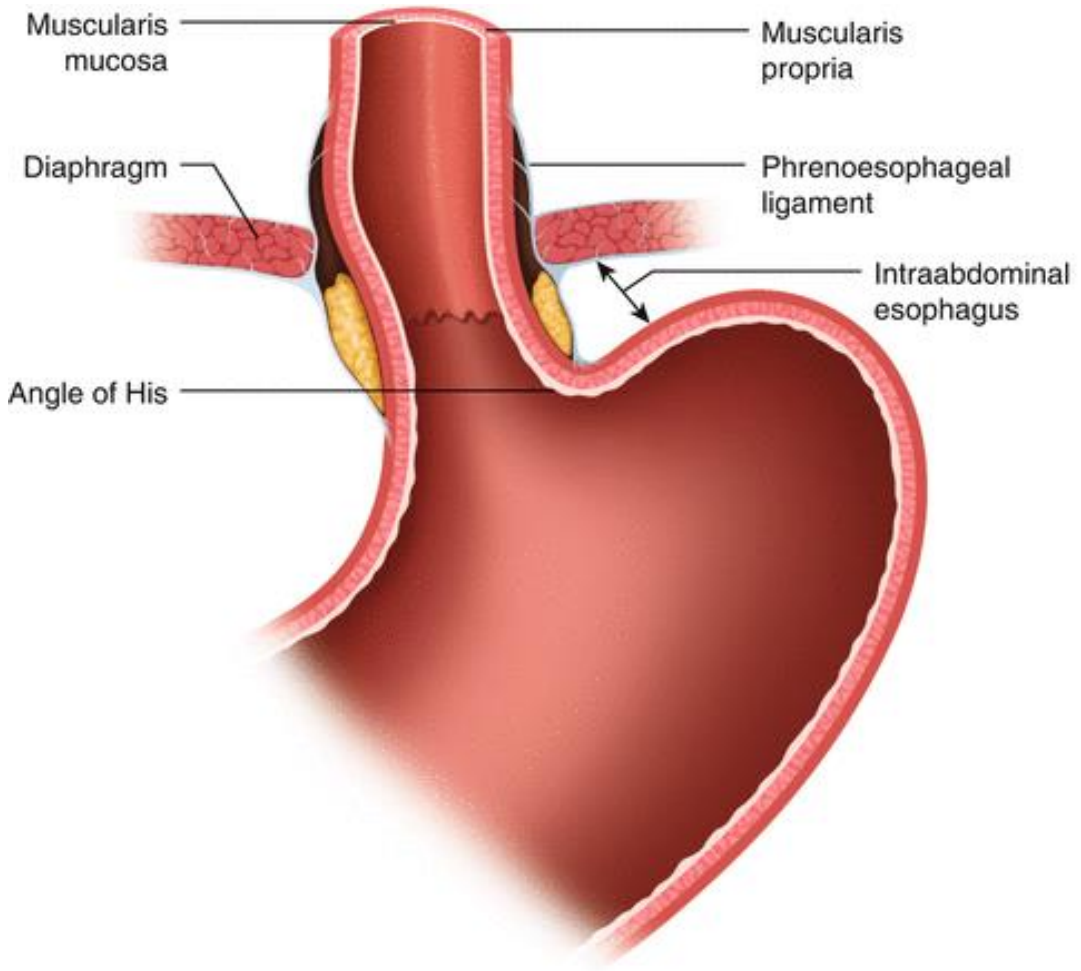

- **Proximal displacement of gastroesophageal junction allow reflux**.
- In a **hiatal hernia**, part of the stomach and/or the section where the stomach joins the esophagus (called the gastroesophageal junction) slips through the hiatus into the chest. **There are two types of hiatal hernias**:
- **Type I Sliding** -A part of the stomach and the gastroesophageal junction slip into the chest. **(Fig.A) →**
- **Type II, Rolling Hernia**

(or para-oesophageal) – an upward movement of the gastric fundus occurs to lie alongside a normally positioned GOJ, which creates a 'bubble' of stomach in the thorax. **(Fig.B) →**

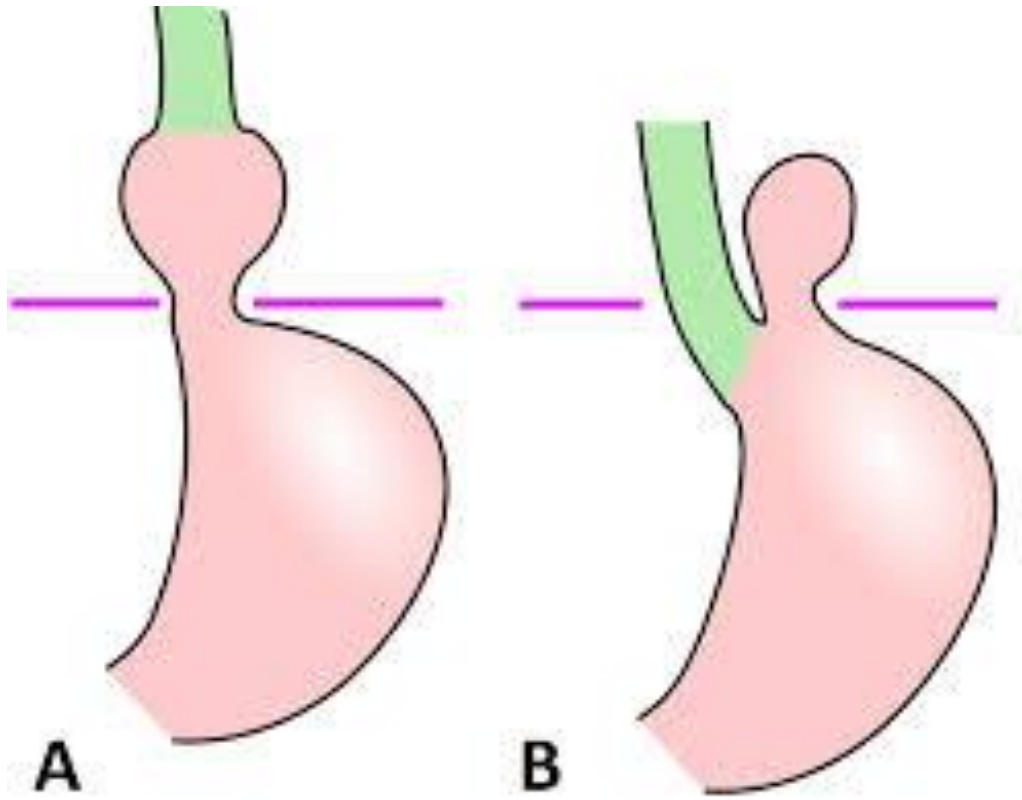

CLINICAL APPLICATION

Generally, GERD and achalasia are thought to be at opposite ends of the spectrum of LES dysfunction.

1- GgastroEsophageal Reflux Disease (GERD):

LES incompetence, which permits reflux of acid gastric contents into the esophagus. This can cause inflammation and heartburn.

2- Achalasia (literally, failure to relax) is a condition in which food accumulates in the esophagus and the organ can become massively dilated. It is due to **increased resting LES tone and incomplete relaxation on swallowing**. **The myenteric plexus of the esophagus is deficient at the LES** and the release of NO and VIP is defective.

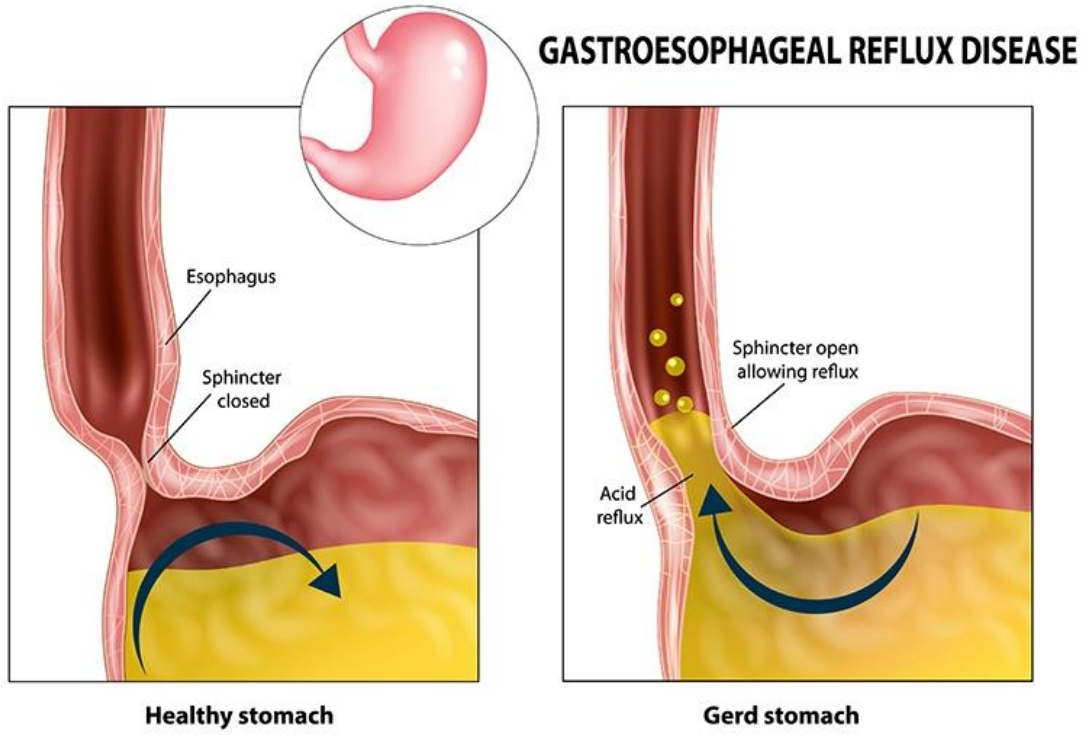

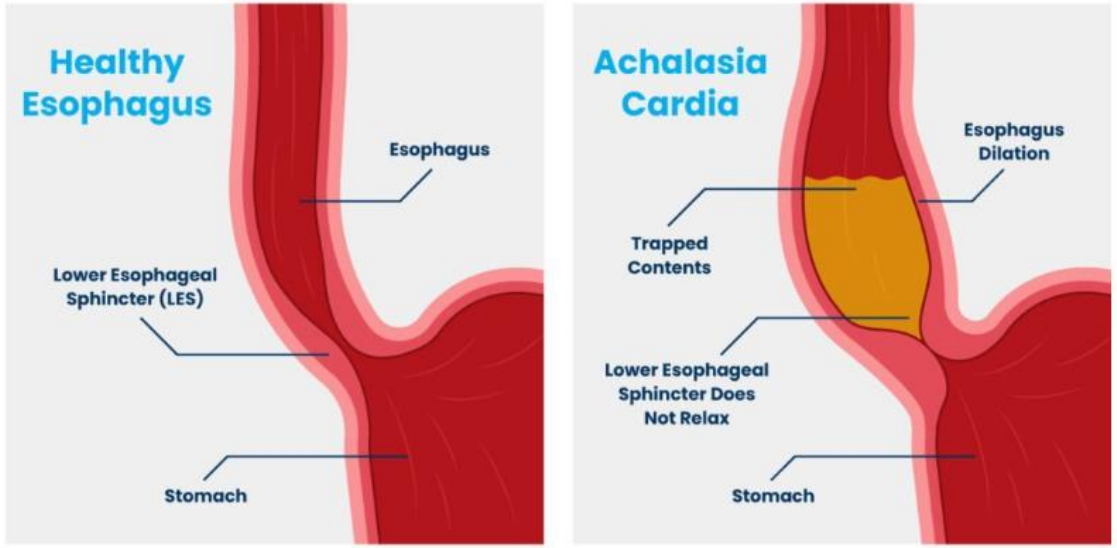

Lower Esophageal sphincter incompetence

It is opposite to Achalasia

Allows reflux of gastric contents into the esophagus, causing **burning pain**.
Prolonged reflux may lead to ,

esophagitis,

ulceration ,

scarring,

stricture,

rarely metaplasia or cancer.

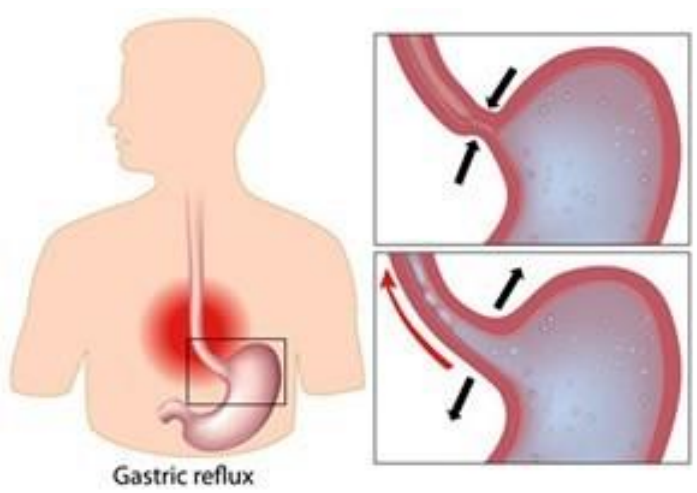

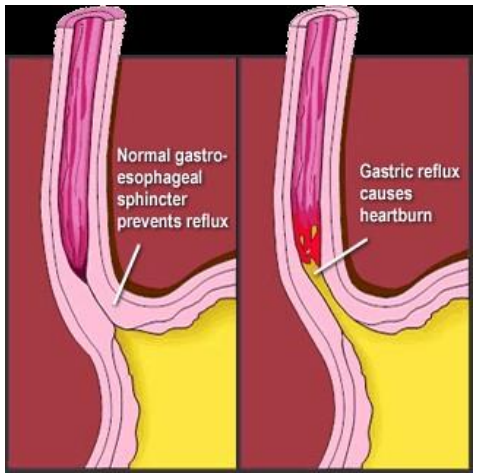

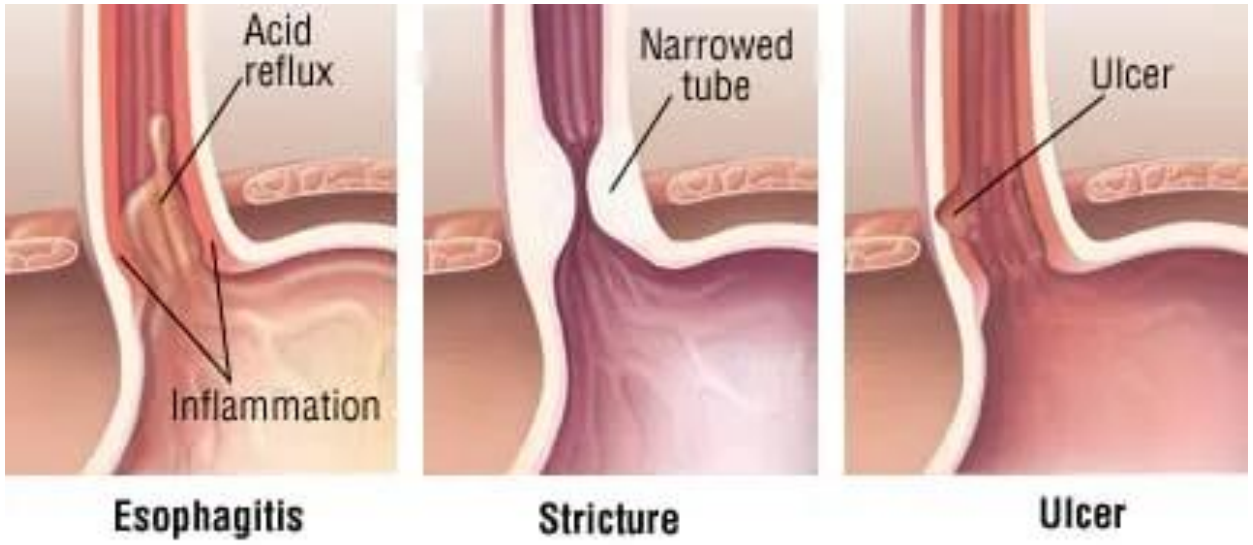

ACHALASIA

- It is due to **increased resting LES tone and incomplete relaxation on swallowing**. The myenteric plexus of the esophagus is deficient at the LES.

Radiology , Barium Swallow show :

Rat-tail sign or Bird-beak sign



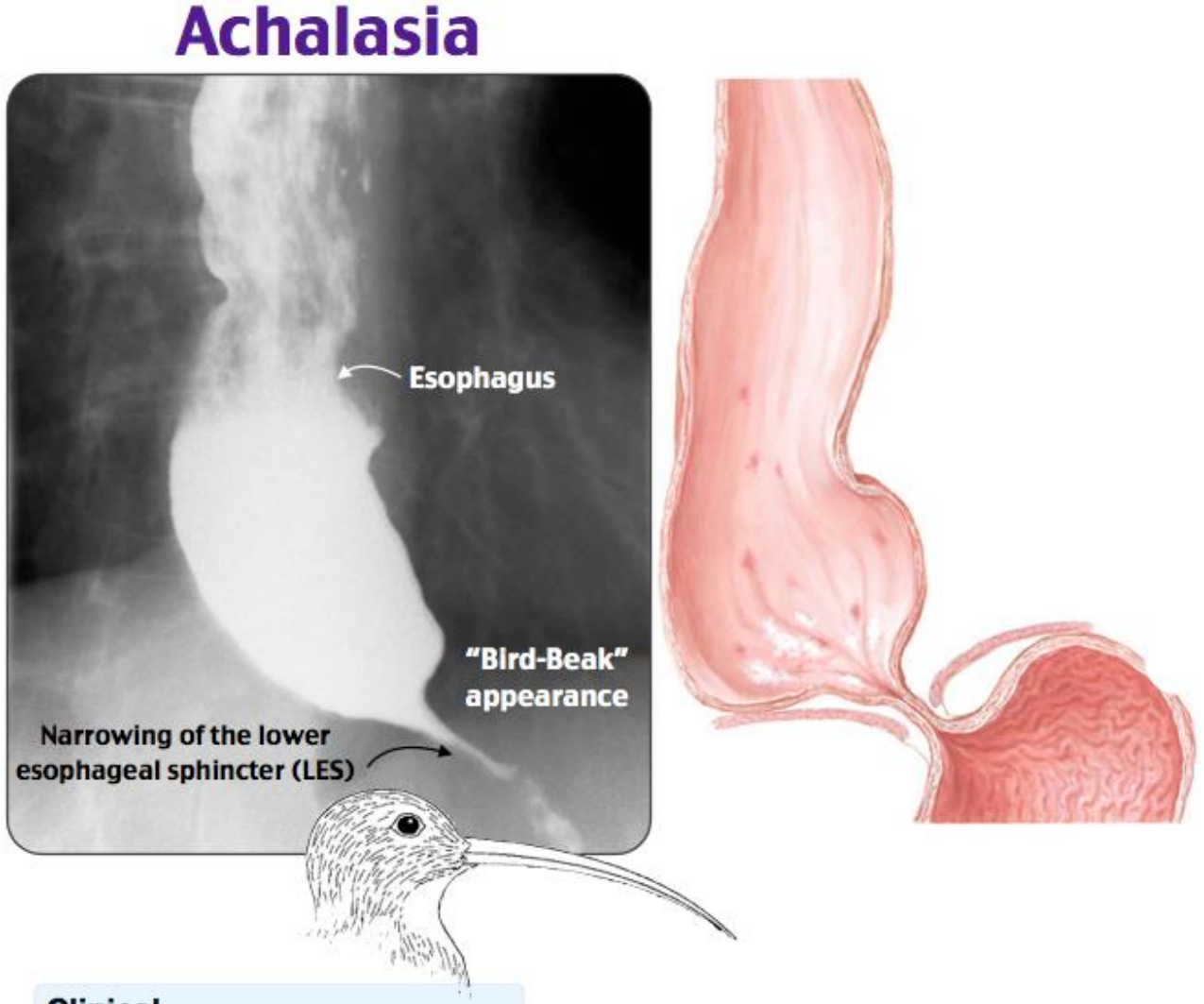

Clinical

- Dysphagia
- Odynophagia
- Regurgitation of undigested food

CLINICAL APPLICATION

Gastroesophageal reflux disease (GERD) OR (GORD)

- **GERD** is a common condition, where acid from the stomach leaks up into the oesophagus (gullet).
- **Symptoms :**
- Heartburn, acid reflux (where stomach acid comes back up into the mouth)
- laryngitis and cough
- bad breath
- bloating and belching.

(Bloating refers to a sense of fullness in the upper abdomen. Belching (or burping) is usually caused by swallowing too much air)

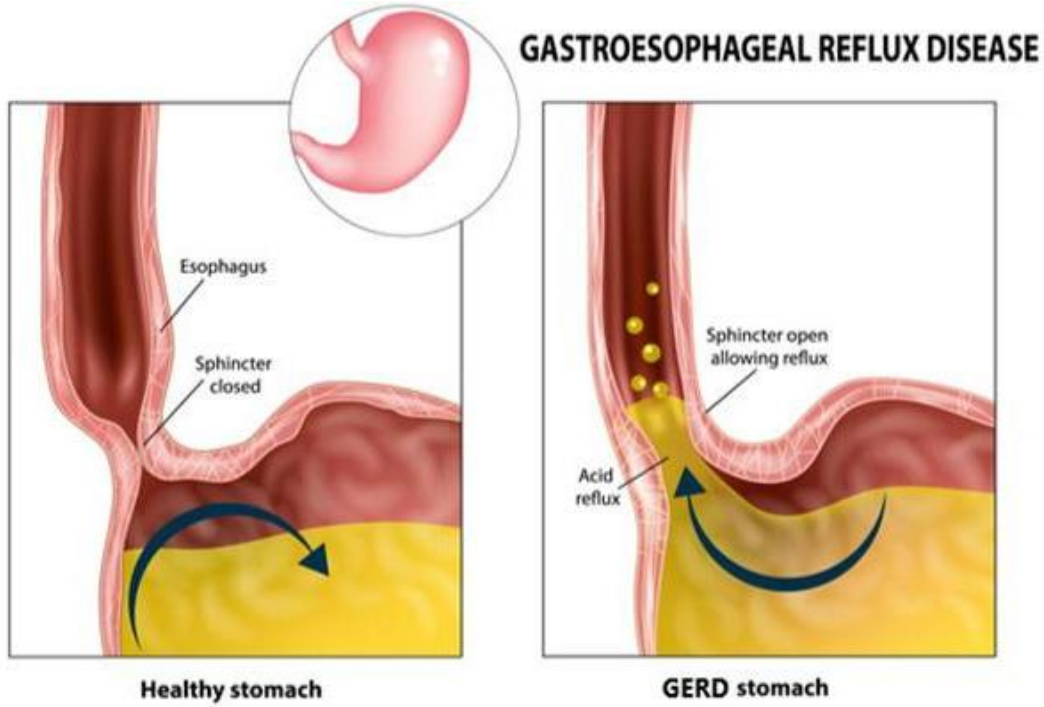

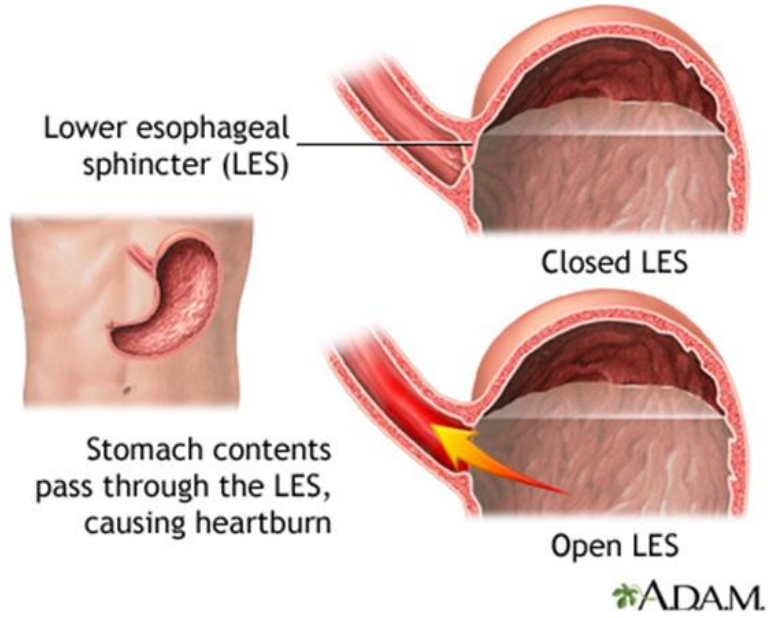

GERD

Complications :

Ulceration

Stricture

Barrett's oesophagus

(columnar cells in place of the squamous epithelium)

Adenocarcinoma

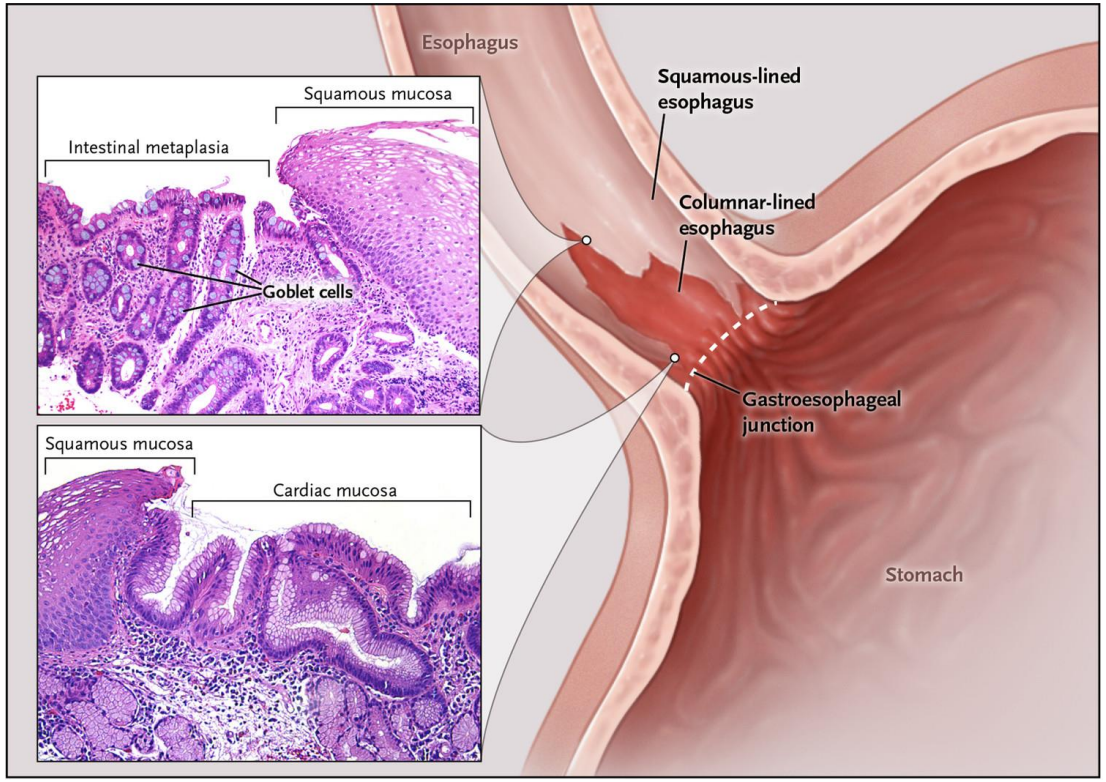

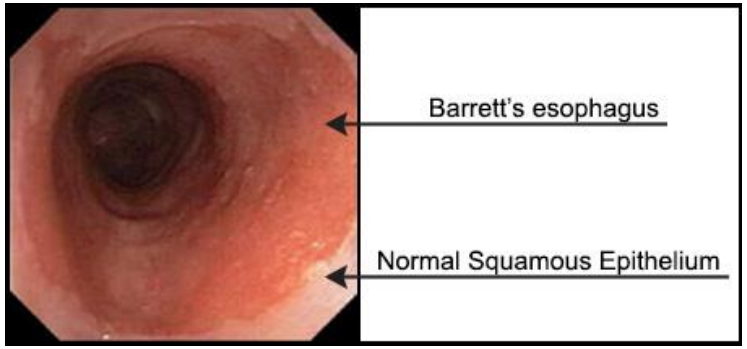

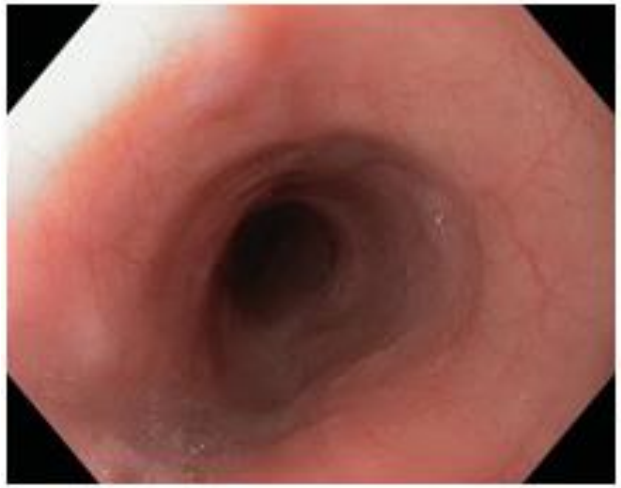

Images: Normal oesophagus

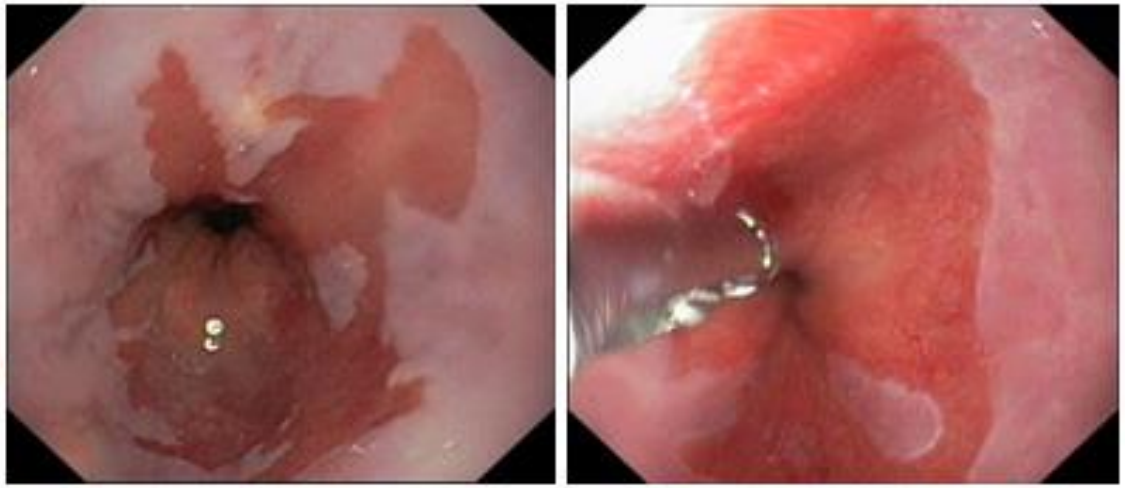

Examples of Barrett's oesophagus

RECEPTIVE RELAXATION OF THE STOMACH:

- When food enters the stomach, the fundus and upper portion of the body relax and accommodate the food with little if any increase in pressure **(receptive relaxation)**. Peristalsis then begins in the lower portion of the body.
- **The proximal third of the stomach (fundus plus oral corpus) relaxes during swallowing so that it can hold large amounts of food with limited increases in intraluminal pressure**. This mechanism has been called **"receptive relaxation".** This allows the stomach to accommodate greater quantities of **food up to 1-1.5 liter.**
- Receptive relaxation is, in part, vagally mediated and triggered by movement of the pharynx and esophagus.
- **The stomach secretions are highly acidic** and contain many proteolytic enzymes (proteases) (enzymes that break down protein).

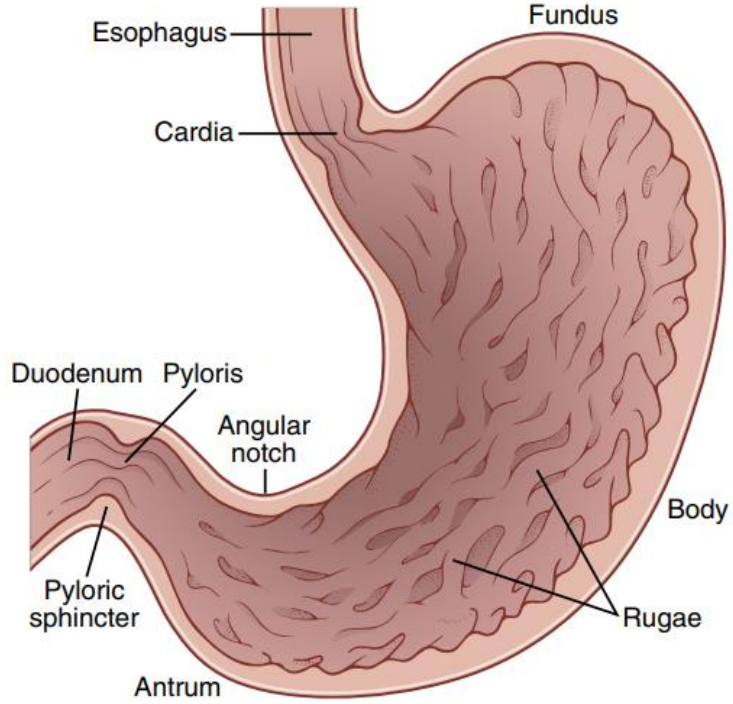

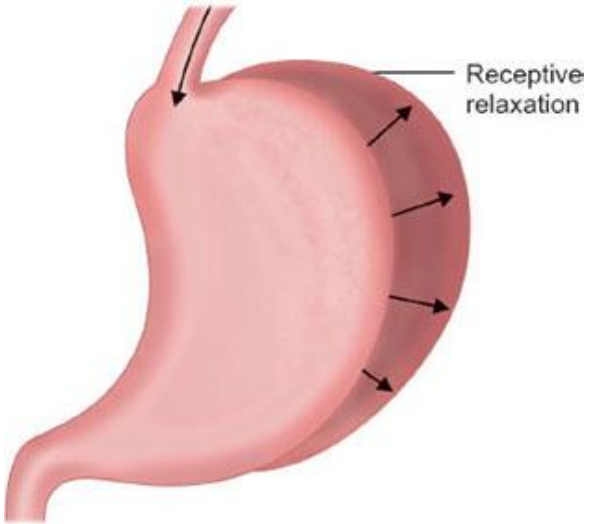

BASIC ELECTRICAL RHYTHM (BER) OR GASTRIC SLOW WAVE:

- As long as food is in the stomach, weak peristaltic constrictor waves, called **mixing waves, begin in the mid to upper portions of the stomach wall and move toward the antrum about once every 15 to 20 seconds.**
- These waves are initiated by the gut wall basic electrical rhythm, consisting of electrical **“slow waves”** that occur spontaneously in the stomach wall.
- **BER a pacemaker** for the mixing and peristaltic movement of the stomach.
- Thickness is more in antrum than fundus **→ Contraction is strongest at antrum**.

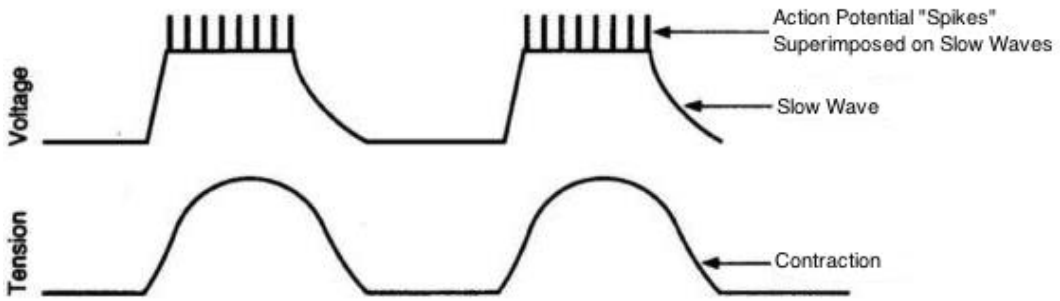

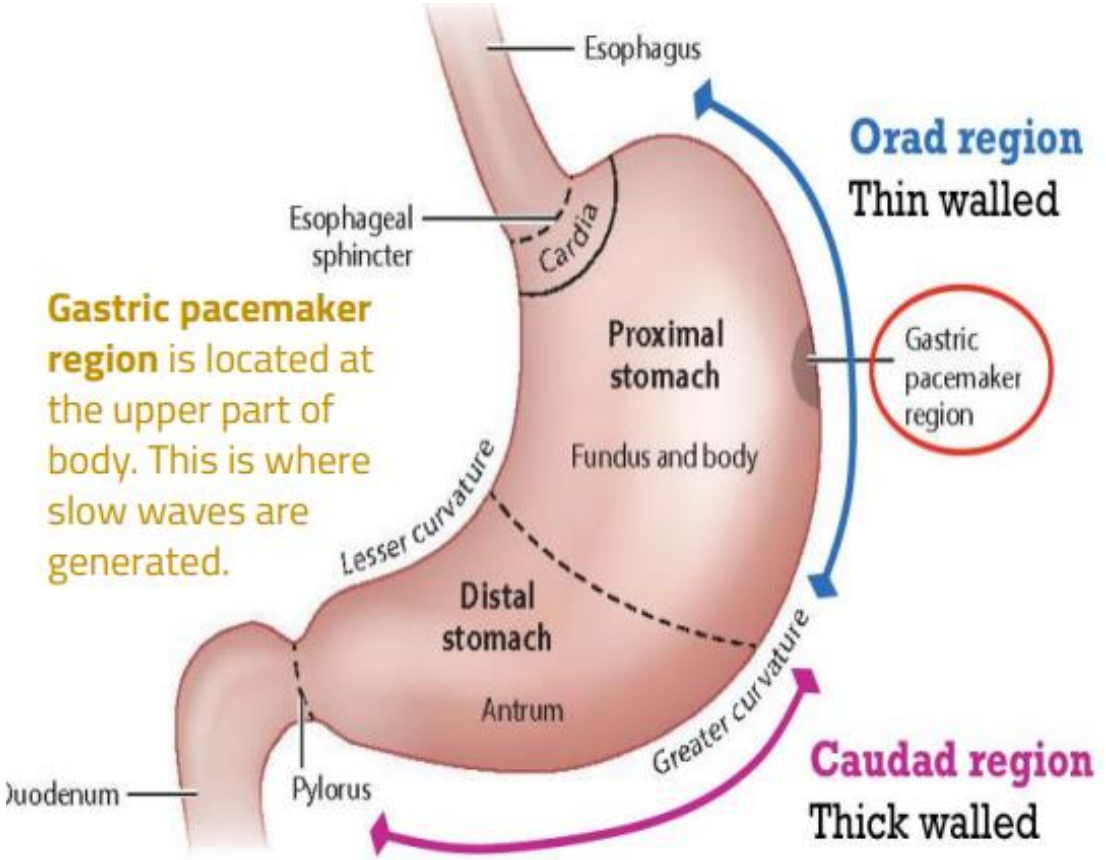

MOVEMENTS IN THE STOMACH

- **1-MIXING movement:**
- begin in the mid to upper portions of the stomach wall and move toward the antrum.
- **weak constrictor waves at a rate of 3-4/min.**
- As the constrictor waves progress from the body of the stomach into the antrum, they become more intense, some becoming extremely intense.

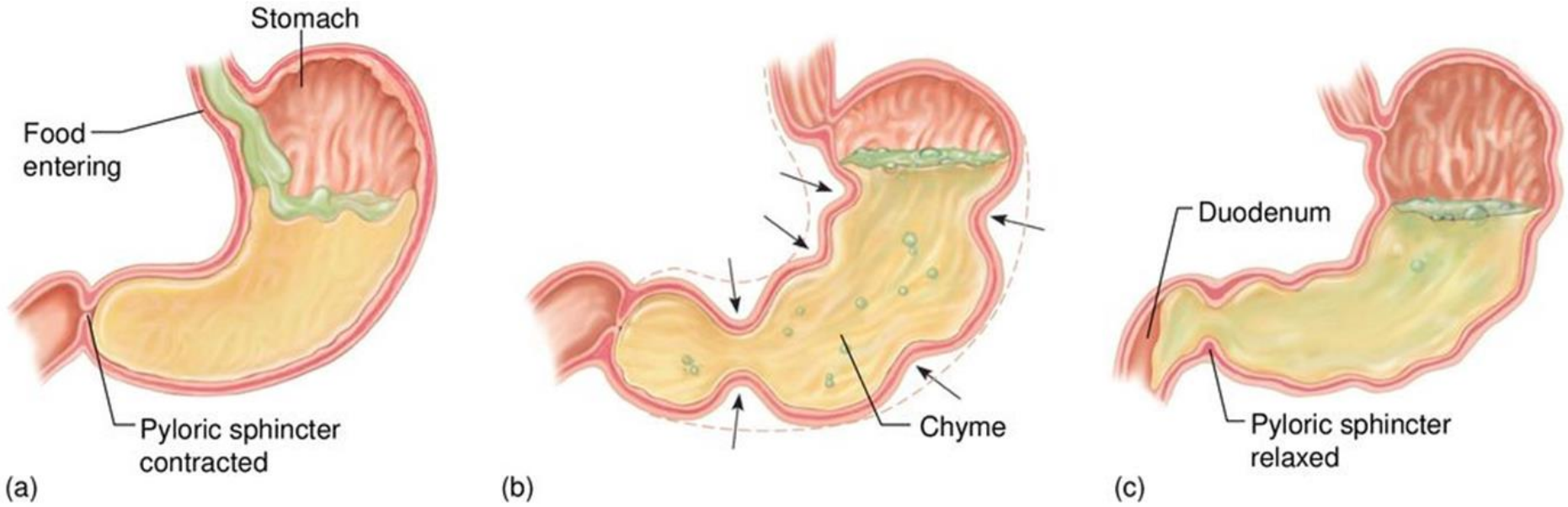

2-PROPULSIVE OR PERISTALTIC waves:

Each time a peristaltic wave passes down the antral wall toward the pylorus, it digs deeply into the food contents in the antrum.

Strong peristaltic waves occur in the antrum with a rate of 3-4/min.

(Waves occur 3–4 times per minute)

Contraction of the antrum is followed by sequential contraction of the pyloric region and the duodenum.

They are about 6 times

as powerful as the usual

mixing waves.

The peristaltic waves help in

propulsion and mixing of food.

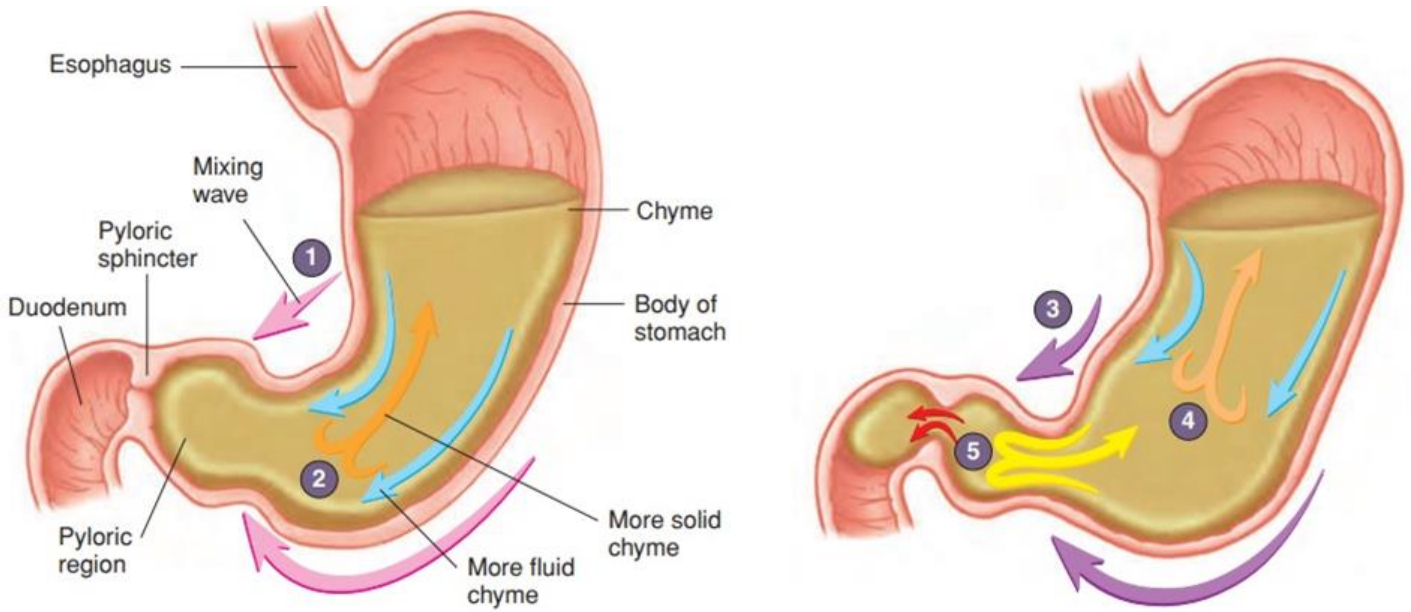

PROPULSIVE

OR

PERISTALTIC

waves

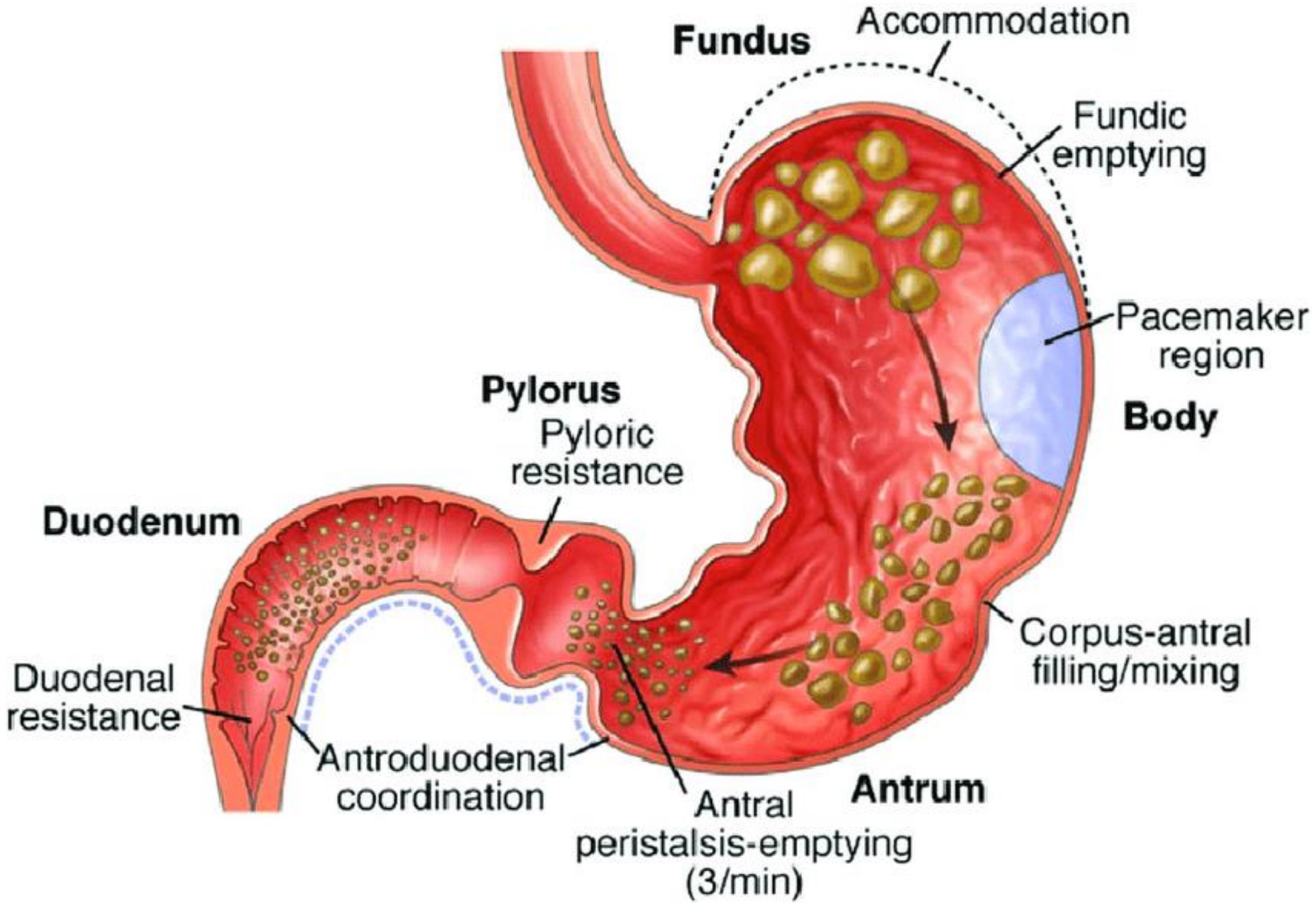

- **3-HUNGER contractions:**
- Hunger contractions, often **occurs when the stomach has been empty for several hours or more.**
- When the successive contractions become extremely strong, they often fuse to cause a continuing tetanic contraction that sometimes lasts for 2 to 3 minutes.
- Hunger contractions are **most intense in young, healthy people** who have high degrees of gastrointestinal tonus; they are also greatly increased by the person's **having lower than normal levels of blood sugar.**
- When **hunger contractions** occur in the stomach, the person sometimes experiences mild pain in the pit of the stomach, called **hunger pangs**.
- **Hunger pangs usually do not begin until 12 to 24 hours after the last ingestion of food.**

EMPTYING OF THE STOMACH

- Stomach emptying is promoted by intense peristaltic contractions in the stomach antrum. At the same time, emptying is opposed by varying degrees of resistance to passage of **chyme** at the pylorus.
- **Gastric emptying** is the process by which the contents of the stomach are moved into the duodenum. This is accomplished by three mechanisms:

(1) Peristaltic waves.

(2) Intense peristaltic contractions of the antrum.

(3) Reduction in size of the stomach.

- **After eating, food typically spends 2 to 4 hours in the stomach.**
- **Liquids usually leave stomach quickly**, while solid foods typically take longer.

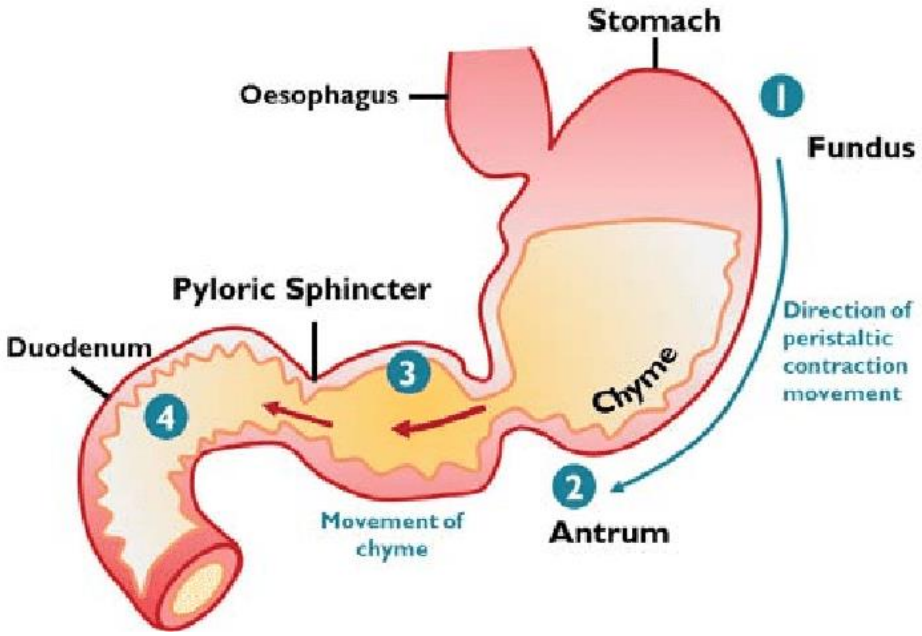

ROLE OF THE PYLORUS IN THE STOMACH EMPTYING:

- The distal opening of the stomach is the pylorus.
- **Pylorus remains slightly tonically contracted almost all the time**.
- Despite normal tonic contraction of the pyloric sphincter, the pylorus usually is open enough for water and other fluids to empty from the stomach into the duodenum with ease.
- **The degree of constriction of the pylorus**

is increased or decreased under the

influence of nervous and hormonal

signals from both the

stomach and the duodenum.

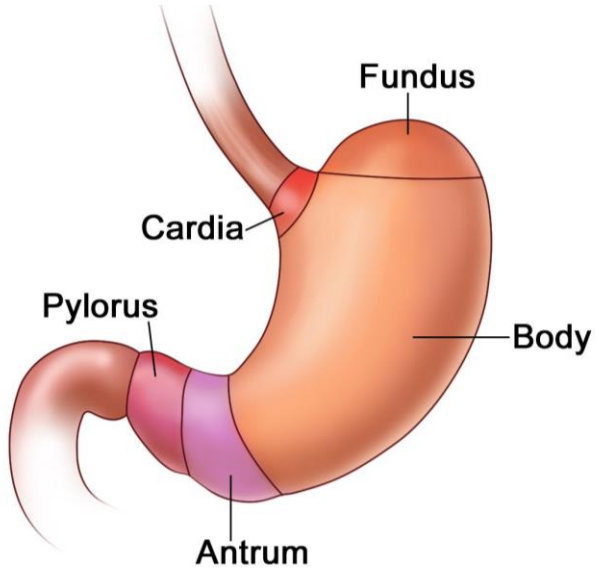

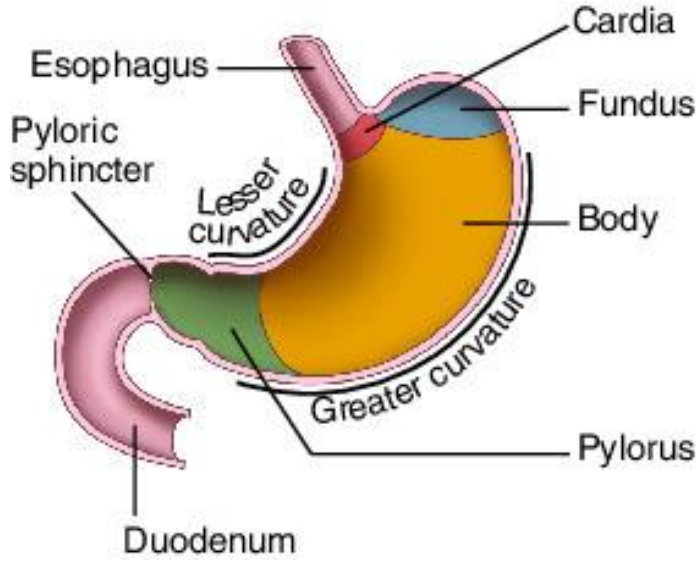

ROLE OF THE PYLORUS IN THE STOMACH EMPTYING …. Cont.

- **The Hormone Gastrin** Promotes Stomach Emptying. Most important, it seems to enhance the activity of the pyloric pump. Thus, **gastrin likely promotes stomach emptying.**
- **Duodenum Enterogastric Nervous Reflexes Inhibit Stomach Emptying**.
- **Hormonal Feedback From the Duodenum Inhibits Gastric Emptying—Role of Fats and the Hormone Cholecystokinin** :

Hormones released from the upper intestine also inhibit stomach emptying. The most potent of these hormones appears to be **cholecystokinin (CCK).** Other possible inhibitors of stomach emptying are the hormones secretin and glucose-dependent insulinotropic peptide, also called **gastric inhibitory peptide (GIP).**

FACTORS AFFECTING GASTRIC EMPTYING

- The rate at which food leaves the stomach is determined by various factors:-

1. Total volume of gastric contents.

2. Consistency.

3. Chemical composition.

4. Osmolar concentration.

5. PH

1-The total food volume (Volume of Meal)

Increased food volume in the stomach promotes increased emptying from the stomach.

Larger meal , longer emptying time.

2- Consistency: (Physical state/Viscosity of Meal)

liquid more than solids. Solids are not evacuated until they are reduced to a fluid or semi-fluid consistency.

Liquids > Solids.

3- Chemical composition of meal:

Carbohydrates (CHO) leave more rapidly followed by protein and lastly fat.

Carbohydrates > Proteins > Fats

4- Osmolar concentration of the gastric contents :

Isotonic, water show rapid while high electrolyte concentration slows gastric emptying.

5- PH :

Slow at low pH, higher at alkaline

Other factors :

Temperature of Meal:

High or low temp of food slows gastric emptying.

Body posture:

Standing, lying on right side promotes.

Emotional state:

Stress/anxiety promotes gastric motility while depression slows movement.

REGULATION OF GASTRIC MOTILITY AND EMPTYING

- **NERVOUS:**

➢ Local reflexes through myenteric plexus.

➢ Vagal nerve.

➢ Enterogastric reflex → inhibits activity.

- **Hormonal:**

➢ **Gastric : Gastrin** in the stomach and small intestine **increase** emptying.

➢ **Intestinal**: **Enterogastrone**, **Gastric inhibitory peptide (GIP)** , **vasoactive intestinal peptide(VIP)** , **Secretin**, **cholecystokinin (CCK)** , **Peptide YY(PYY)** ..etc .. **inhibit** gastric motility and emptying.

THANK YOU !



Question 1

A patient is referred to a gastroenterologist because of persistent difficulties with swallowing. Endoscopic examination reveals that the lower esophageal sphincter fails to fully open as the bolus reaches it, and a diagnosis of achalasia is made. During the examination, or in biopsies taken from the sphincter region, a decrease would be expected in which of the following?

A. Esophageal peristalsis

B. Expression of neuronal NO synthase

C. Acetylcholine receptors

D. Substance P release

E. Contraction of the crural diaphragm

Answer B

Question 2

A patient is referred to a gastroenterologist because of persistent difficulties with swallowing. Endoscopic examination reveals that the lower esophageal sphincter fails to fully open as the bolus reaches it, and a diagnosis of achalasia is made. During the examination, or in biopsies taken from the sphincter region, a decrease would be expected in which of the following?

A. Esophageal peristalsis

B. Expression of neuronal NO synthase

C. Acetylcholine receptors

D. Substance P release

E. Contraction of the crural diaphragm

Answer B

Question 3

Gastric pressures seldom rise above the levels that breach the lower esophageal sphincter, even when the stomach is filled with a meal, due to which of the following processes?

A. Peristalsis

B. Gastroileal reflex

C. Segmentation

D. Stimulation of the vomiting center

E. Receptive relaxation

Answer E

Reference : Ganong’s Review of Medical Physiology 26 th Edition.