Adhesive bridge (Resin bonded bridge, acid etched bridge)

Fixed dental prosthesis that is luted to the unprepared or minimum preparation surface of abutment teeth permanently by acid etching of enamel with some type of resin bonding agent.

1. It is alternative for the conventional bridge.
2. It is involve attaching the pontic via a metal plate to the unprepared lingual surface of the abutment teeth.
3. The attachment to the abutment is made by composite resin material after acid etch of the enamel.
4. It is the most conservative methods.
5. It is used when the abutment teeth have sufficient intact enamel, & usually used in younger patient.



Indications:

- Adolescents with single missing teeth (traumatic or congenital).
- Caries- free abutment teeth and good oral hygiene.
- Maxillary incisor replacements (most favorable prognosis) and Mandibular incisor replacements.
- Periodontal splints.
- Post orthodontic fixed retention
- Short span edentulous areas (Single posterior tooth replacements).

Contra Indications:

- Small sized abutments – Peg Laterals
- Extensive caries.
- Heavily restored abutments.
- Deep vertical overbite.
- Mal-aligned abutments
- Parafunctional habits
- Long span edentulous area
- Allergy to base metal alloys

Advantages:

- Conservative.
- Saving clinical chairs time.
- Not expensive.
- Lab procedure is easy & short.
- It can be re-cemented if failure occurs.
- Good appearance.

Disadvantages

- Not strong as conventional bridge.
- Limited use because abutment teeth should have sufficient enamel for etching.
- Tendency to de-bond.
- Increase thickness of tooth surface by the metal plate.

Types:

1- Direct:

This type is made by using the crown of patient own tooth as a pontic, for example rapid replacement of a tooth that lost by traumatic injury. In order to increase the strength of the bridge (attachment) we add metal mesh or wire (temporary replacement).



2- Indirect adhesive bridge:

According to the mean or way of retention of the metal frame work to the abutment teeth we have different types:

a) Macro mechanical retention (Rochette).
b) Medium mechanical retention (Virginia).
c) Micro mechanical retentive (Maryland).
d) Chemically retention (Panavia).

a-Macro mechanical retention (Rochette):

In this type there is multiple funnels shaped undercut perforations in the cast metal frame of the retainer is used for retention & through which composite flow during cementation and make mechanical interlocking after setting



b-Medium mechanical retention (Virginia):

Retentive feature cast as a part of the metal frame work (not undercut lumps, mesh, on the fit surface of the retainer). The size of the retentive feature is intermediate between macro mechanical & micro mechanical retentive system

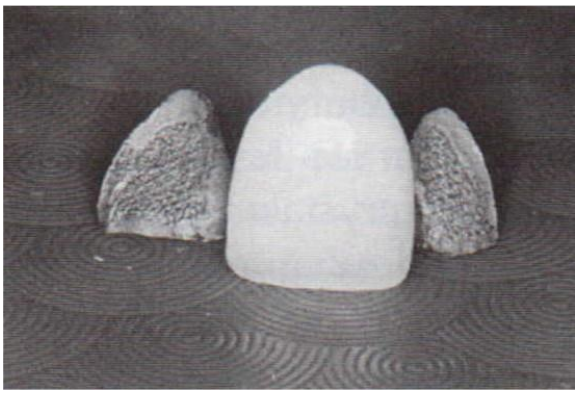

c-Micro mechanical retentive (Maryland):

In state of perforations, the tooth side of the frame work is electrolytically etched, with hydrofluoric acid, which produce a microscopic undercut, the bridge attached with a resin luting agent that lock into the microscopic undercut of both the etched retainer & etched enamel.



d-Chemically retention (Panavia):

The resin adheres chemically to recently sand-blasted metal surface and is retained on the tooth by conventional acid etching of the enamel.



DIAGNOSIS AND TREATMENT PLANNING IN FIXED PROSTHODONTICS

Successful management of cases begin with a thorough assessment of the patient's physical and psychological condition and determining a treatment that will satisfy the realistic expectations of the patient

Diagnosis

- The determination of the nature of a disease.

Treatment plan

- The sequence of procedures planned for the treatment of a patient after diagnosis

What is an Ideal Treatment plan?

Treatment plan that achieves the best possible long-term outcomes for the patient, while addressing all patient concerns and active problems, with the minimum necessary intervention.

Treatment Plan by Phases

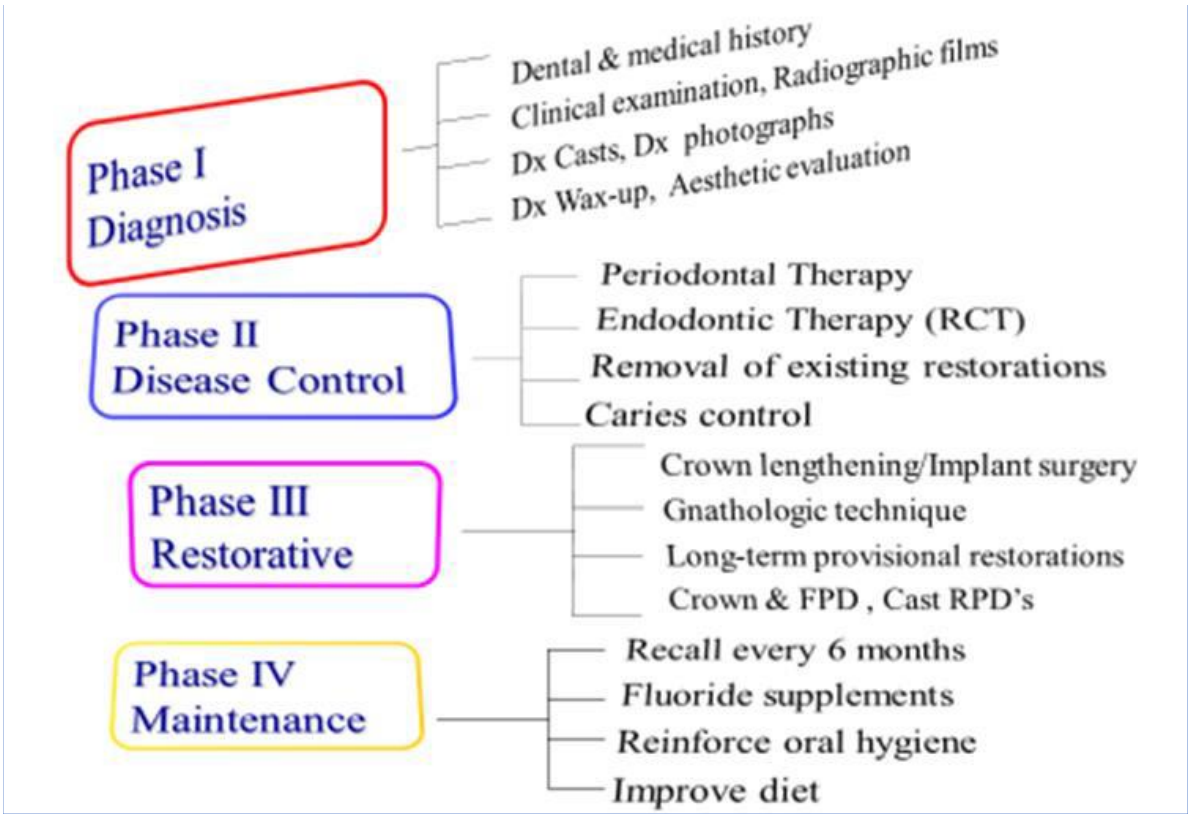

Phase I: Diagnosis

1- History
2- Clinical examination
   - TMJ & extraoral examination
   - intraoral examination
3- Diagnostic cast
4- Radiographic examination
5- Dx photographs, Dx Wax-up, Aesthetic evaluation

History (data collection)

All pertinent information concerning the reasons seeking treatment, along with any personal information, including relevant previous medical and dental experiences. The chief complaint should be recorded preferably in patient's own words.

1) Personal information: Name, Sex, AGE, Address, Telephone No, Family history, Socio-economic status, Physician Telephone No.
2) Dental History
3) Medical History

Chief complaint

The accuracy and significance of the patient's primary reason or reasons for seeking treatment should be analyzed first

Four categories of chief complaint

• **COMFORT** (pain, sensitivity, swelling)
• **FUNCTION** (Difficulty in mastication or speech)
• **SOCIAL** (Bad taste or odor)
• **APPEAREANCE** (Fractured or unattractive teeth or restorations, discoloration)

Clinical examination consists of the clinician's use of sight, touch, and hearing to detect conditions outside the normal range. Clinical examination involves the following:

General appearance:

- Gait and weight are assessed.
- Color: Anemia or jaundice.
- Vital signs: Respiration, pulse, temperature and blood pressure are measured and recorded.

Extraoral examination:

- Facial asymmetry
- Cervical lymph nodes
- TMJ
- Muscles of mastication (palpated)

Intraoral Examination

Diagnostic aids

- Radiograph
- Vitality test
- Diagnostic cast
- Periodontal probe

Pulpal health must be measured before restorative treatment to percussion, thermal stimulation and vitality tests

Radiographic examination

The radiograph should be examined carefully for caries, presence of periapical lesion, the quality of the previous endodontic treatment, alveolar bone level, crown-root ratio, root configuration, direction of root, number of root, also the presence of retained root in edentulous areas should be recorded.

Clinical information provides by radiographic examination, during this diagnosis phase are:

- Extent of bone support
- Root morphology
- Peri apical pathology

Panoramic radiographs for:

- Presence or absence of teeth
- Assessing third molars impactions,
- Evaluating the bone before implant placement.
- Screening edentulous arches for buried root tips**.**

Diagnostic Casts Examination

They should be mounted on a semi adjustable articulator

Advantages:

1. Allow an un obstructed view of the edentulous space
2. Allow accurate assessment of the span length and the curvature of the ridge or arch in the edentulous region
3. The shape and length of the abutment teeth can be measured to determine which preparation design will provide adequate retention and resistance.
4. Evaluate path of insertion (axial inclination of abutment) to determine the need for any modification.
5. No., size and location of wear can be evaluated.
6. Over erupted teeth can be easily spotted and the amount of correction needed can be determine.
7. Evaluate occlusion and Interocclusal space necessary to re-establish a proper occlusal plane.
8. Evaluate the need for any occlusal correction.
9. Used for diagnostic wax-up.
10. Construction of special try and provisional restoration.

Diagnostic photographs

There is much diagnostic information to be gained by including photography to comprehensive treatment planning. It allows the practitioner to show the patient a photograph(s) concerning his complain or problem immediately, thereby helping the

patient to co-diagnose, understand their needs and complications much better when they can see a picture of their own pathology work with the patient chairside while showing his problem and discus the treatment.

Phase II: Disease control

Mouth preparation

Mouth preparation refers to the dental procedure that need to be accomplished before fixed prosthodontics can be properly undertaken. As a general plan, the following sequence of treatment procedures in advance of fixed prosthodontic should be adhered to:

- Relief of symptoms (chief complaint)
- Removal of etiological factors (e.g.; excavation of caries removal of deposits)
- Repair of damage.
- Maintenance of dental health.

The following list describes the sequence in the treatment of a patient with extensive dental disease including missing teeth, retained roots, caries and defective restorations.

- Preliminary assessment
- Emergency treatment of presenting symptoms
- Oral surgery
- Caries control and replacement of existing restorations
- Definitive periodontal treatment
- Orthodontic treatment
- Definitive occlusal treatment
- Fixed prosthodontics
- Removable prosthodontics
- Follow up care

Selection the type of prosthesis

Factors considered

- BIOMECHANICAL
- PERIODONTAL
- ESTHETIC
- FINANCIAL and PATIENTS WISHES.

1- Conventional tooth supported fixed partial denture

- Abutment teeth are periodontally sound.
- Edentulous span is short and straight.
- Expected to provide a long life of function for the patient.
- No gross soft tissue defect in the edentulous ridge.
- Reserved for patients who are both highly motivated and able to afford

2- Resin bonded tooth supported fixed partial denture

- Defect free abutments where single missing tooth.
- A single molar (muscles are not well developed).
- Mesial and distal abutment are present.
- Moderate resorption and no gross soft tissue defects on edentulous ridges.
- Younger patients whose immature teeth with large pulps are poor risks for endodontic free abutment preparation.
- Tilted tooth can be accommodated only if there enough tooth structure to allow a change in the normal alignment of axial reduction.
- Periodontal splints

3- Implant supported fixed partial denture

- Insufficient number of abutments.
- Partial attitude and or a combination of intra oral factors make a removable partial denture or FPD a poor choice.
- No distal abutment.
- Alveolar bone with satisfactory density and thickness in a broad, flat ridges.
- Configuration that permits implant placement.
- Single tooth was defect free adjacent teeth.
- A span length of two or six teeth can be replaced by multiple implants.
- Pier in an edentulous span (three or more teeth long).

It is not uncommon to combine two types in the same arch. In cases where the choice between a fixed partial denture and a removable partial denture is not clear cut, two or more treatment options should be presented to the patients along with their advantages and disadvantages. The prosthodontist is the best person to evaluate the physical and biological factors present, while the patients' feelings should carry considerable weight on matters of esthetics & finances.

4- No prosthetic treatment

- Long standing edentulous space into which there has been little or no drifting or elongation of the adjacent teeth.
- If the patients perceive no functional, occlusal or esthetic impairment.