FLUID CONTROL & SOFT TISSUE MANAGEMENT

Moisture control

FLUID SOURCES OF THE ORAL CAVITY

- Saliva (pair of parotid &submandibular and sublingual glands). Saliva flow rate 0.26 +/- 0.16 ml/min and that of saliva while chewing different foods was 3.6 +/- 0.8 ml/min.
- Inflamed gingival tissues/ Iatrogenic soft tissue damage (Gingival bleeding during tooth preparation)
- Water / dental materials (Rotary instruments, triplex syringe, etchants, irrigant solutions). Average a high speed rotatory cutting instrument is 30 mL per minute.
- Gingival crevicular fluid (sulcular fluid). Gingival crevicular fluid 0.05 to 0.20 µL per minute.

WHY SHOULD ISOLATE THE OPERATIVE SITE?

- To obtain a dry clean operating field
- For easy access and visibility
- To improve the properties of dental materials
- To protect the patient and the operator
- To improve the operating efficiency

How is moisture control important?

1. **Patient related factors**
   - Provides comfort.
   - Protects from swallowing or aspirating foreign bodies.
2. **Task/technique being performed**
   - Dental materials are moisture sensitive, success of adhesion and physical properties relies on a dry field.
3. **Operator related factors**

   Infection control to minimize aerosol production
   Increased accessibility to operative site
   - Improves visibility of the working field
   - Less fogging of the dental mirror.
   - Prevents contamination.

Depending on the location of the preparations in the dental arch, a number of techniques can create fluid control & the necessary dry field of operation.

1) Mechanical method

a) Rubber dam

When all margins are supra-gingival, moisture control with a rubber dam is probably the most effective method. In most instances, however, a rubber dam cannot be used, so a Multiple Isolation Techniques should be performed to achieve optimal saliva control. Advantages of rubber dam are Isolation of 1 or more teeth, eliminates saliva from the operating field and retracts the soft tissues.

b) Cotton roll

Absorbent cotton rolls must be placed at the source of the saliva, the muco-buccal fold or in the sublingual area, In the maxillary arch, placing a single cotton roll in the vestibule immediately buccal. If a maxillary roll does not stay in position but slips down, it can be retained with a finger or the mouth mirror. When a mandibular impression is made, placement of additional cotton rolls to block off the sublingual and submandibular salivary ducts is usually necessary. A horseshoe shape cotton in the maxillary and mandibular muco-buccal folds may be also effective.

c) Cotton roll holder

Holds cotton rolls in place, have two advantages over cotton roll alone,

Cheek and tongue are slightly retracted and Enhances visibility.

d) Absorbing cards

Another method for controlling saliva flow. These cards are pressed-paper wafers that may be covered with a reflective foil on one side. The paper side is placed against the dried buccal tissue and adheres to it. In addition, two cotton rolls should be placed in the maxillary and mandibular vestibules to control saliva and displace the cheek laterally. The tongue can cause problems when work is being done in the mandibular arch. Saliva evacuators may help eliminate excess flow.



e) Saliva evacuators

If lingually placed cotton rolls repeatedly become dislodged (or in conjunction with a conventional saliva evacuator, fail to control moisture adequately), a flange-type evacuator (e.g., the Svedopter [E. C. Moore Company] or the Speejector [Pulpdent Corporation]) should be considered. To avoid the risk of soft tissue trauma, this device must be placed carefully. A cotton roll placed between the blade and the mylohyoid ridge of the alveolar process minimizes intraoral discomfort for the patient and avoids potential injury of the soft tissues A disposable saliva ejector designed to displace the tongue may also be effective





2) Chemical method

a) Local anesthesia

In addition to the pain control normally needed during tissue displacement, local anesthesia may help considerably with saliva control during impression making. Nerve impulses from the periodontal ligament form part of the mechanism that regulates saliva flow; when these are blocked by the anesthetic, saliva production is considerably reduced.

b) Medications

When saliva control is difficult a medication with anti-sialagogic action (drugs that inhibit parasympathetic innervation, this will inhibit action of myo-epithelial cells of salivary gland thereby reduce secretions) may be considered. Dry mouth is a side effect of certain anticholinergics. This group of drugs **includes atropine1 tablet of 0.4mg per day, Methantheline bromide (banthine):50 mg 1 hour before procedure dicyclomine, and Propantheline bromide (pro-banthine): 15 mg 1 hour before procedure.** Anticholinergics should be prescribed with **caution** in older adults and should not be administered to any patient with **heart disease**. They are also **contraindicated** in individuals with **glaucoma** because they can cause permanent blindness **Clonidine hydrochloride: 0.2 mg 1 hour before procedure, an antihypertensive drug**, has successfully **reduced salivary output**. It is **considered safer than anticholinergics** and has no specified contraindications. However, it should be used cautiously in hypertensive patients. Clonidine hydrochloride (antihypertensive)

Gingival Retraction

A procedure by which the finishing line is temporarily exposed by enlarging the gingival sulcus to create a space both laterally and vertically between the gingival margin and the gingival termination so that the printing material penetrates in sufficient quantity to obtain good impression which involves the details of the end margin of the preparation that is located subgingivally (the exact copy of the preparation).

Gingival Sulcus (Crevice)

A shallow groove around the tooth bounded on one side by the surface of the tooth and on the other by the epithelial lining of the free margin of the gingiva. It is “V” shaped with its base at the most coronal level of the epithelial attachment to the tooth root.

Biological Width

Biologic width is defined as **the dimension of the soft tissue, which is attached to the portion of the tooth coronal to the crest of alveolar bone.** There is a definite proportion between the sulcus depth, the epithelial attachment, the connective tissue attachment and the alveolar crest. The **total width of junctional epithelium** (range between **0.71 to 1.35mm, mean 0.97mm)** and **supraalveolar connective tissue attachment** (rang **1.06 - 1.08mm**, **mean 1.07mm**) forms the **biologic width** is 0.97 + 1.07 = **2.04 mm**. They established the mean sulcular depth as 0.69.

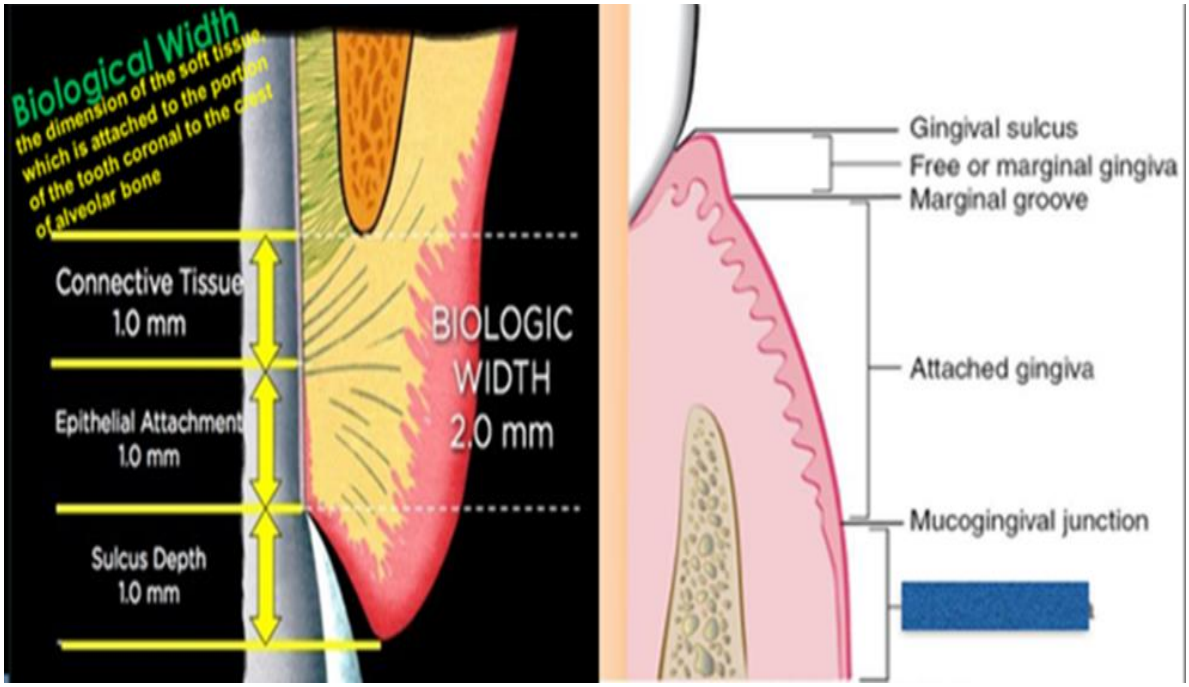

What is its function? (Its importance in restorative dentistry)

The significance of biologic width is that**, it acts as a barrier and prevents penetration of microorganisms into the periodontium.** Maintenance of biologic width is essential to preserve the periodontal health and to remove any irritation that may damage the periodontium. It is said that a minimum of 3mm space between the restoration margin and the alveolar bone is required to permit adequate healing and to maintain a healthy periodontium. This 3 mm consists of 1mm of supraalveolar connective tissue, 1mm of junctional epithelium and 1mm of sulcular depth. This allows for adequate biologic width (2.04mm) even when the margins are placed 0.5mm within the sulcus.

How to preserve?

The location, fit and finish of restorative margins are critical factors in the maintenance of periodontal health. So, a huge consideration and care should have performed during isolation and retraction (even with digital impression techniques) besides tooth preparation to the biological width to ensure the healthy standards and maintenance the normal values of the periodontium.

Objectives of gingival retraction

1. Create an access for the impression material to the area of the preparation that is located subgingivally.
2. To provide enough thickness of the impression material at the area of the finishing line to prevent distortion of the impression.
3. Providing the best possible condition for the impression material, fluid control.
4. Reduce fluid a mount in the sulcus that might cause void in the impression.

Gingival retraction techniques

1- Mechanical (plain retraction cord, retraction crown, copper band or tube , anatomic compression caps, Matrices and wedges, Rubber dam)

2- Chemo mechanical (combination of mechanical and chemical)

a) Impregnated retraction cord, with one of the following:
   - aluminum sulfate
   - epinephrine
   - ferric sulfate
   - zinc chloride
   - aluminum chloride

b) Displacement polymer & paste (cordless technique)

3) Radical or surgical means or technique (electro surgery, Laser).

1) Mechanical

It might be done by either of the followings:

Retraction cord
Retraction Crown
Copper band or tube
Anatomic compression caps
Matrices and wedges
Rubber dam

Generally, in this technique, we apply pressure on the gingiva through gingival sulcus. This mechanical pressure, after certain period of time, physically push the gingiva away from the finishing line. It might be done by the construction of temporary crown with slightly long margin leaving it for 24 hours, or by using rubber clamp, or by using plan retraction cord(free of medicament)….etc. **The most common way by using retraction cord.**

Retraction cord is a special cord made of cotton comes either with or without medicament (vasoconstrictor). Cord without a vasoconstrictor is used to obtain a mechanical gingival retraction.it come in different size

Classification of retraction cords

1. **According to chemical treatment**
   - Plain cord without any medicament.
   - Impregnated cord (impregnated with hemostatic agent).
2. **According to configuration**
   - Twisted
   - Knitted
   - Braided

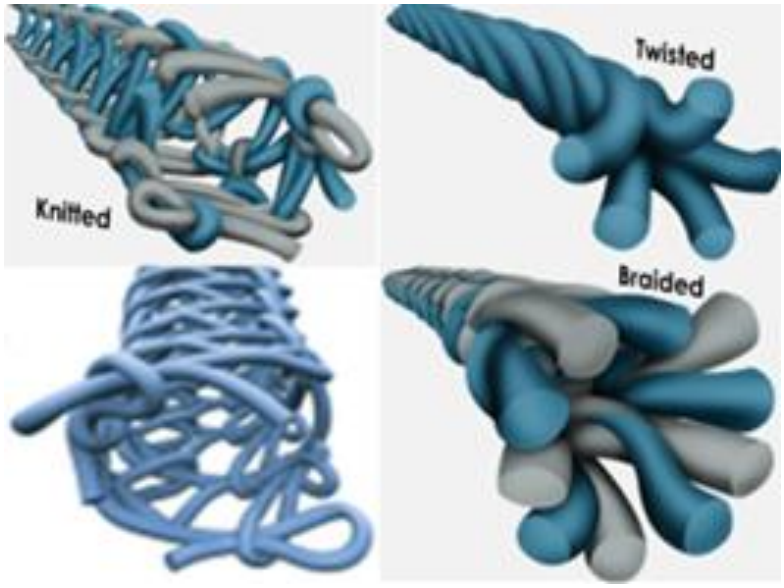

Twisted and braided cords can't offer ease of packability and tissue displacement like knitted ones.

Advantages of knitted cord over other types

1) Afford greater inter-thread space than braided cord.
2) Form an interlocking chain of thousands of tiny loops, making it
   - Easy to pack below the gingival margin
   - Stays put when packed into place.
3) Compresses upon packing, then expands for tissue displacement.

3. According to thickness (diameter)

According to its size, we have different thickness of retraction cord (color-coded thickness):

- **Black - 000**
- **Yellow – 00**

  Both are recommended for anterior teeth with minimal crevicular space.
  Also can be used as a primary cord for the double cord technique.
- **Purple - 0**
- **Blue – 1**

  Both are recommended for bicuspids. Also #0 is used as the primary cord for the double cord technique, while #1 cord is recommended to be used as the secondary cord
- **Green - 2**
- **Red – 3**

  Both sizes are used for molars where tissue friability permits.



Some textbook divide retraction cord into three main size:

- **SMALL-** involve (#000 &# 00) to be used in anterior teeth, where thin firmly tissue is present
- **MEDIUM-** involve (#0, #1 & #2) to be used where greater bulk is encountered e.g. posterior teeth
- **LARGE-** involve size (#3) should be used with caution as can produce soft tissue trauma.

Cord packing instruments

Cord packers are dental instruments used to pack gingival retraction cord into the sulcus. Most cord packing instruments have a slightly rounded tip with serration to hold the cord while it is positioned intra-sulcularly.

Fischer packer is a cord packing instrument. Furthermore, plastic instrument (Ash No. 6) can be used for cord packing.

The cord packers with round, non-serrated working ends are used for atraumatic cord placement; serrated cord packers should only be used with braided cord.




Fischer packing instrument

These specially designed packers ease the packing of Ultrapak® knitted cord. Their thin edges and fine serrations sink into the cord, preventing it from slipping off and reducing the risk of cutting the gingival attachment. It available in two form

- **45° to handle:** with heads at 45° to the handle with three packing sides. Circular packing of the prep can be completed without the need to flip the instrument end to end. Use the small packer on lower anterior and upper lateral incisors.
- **90° and parallel to handle:** Same size and three-sided heads as the 45º to handle packer, except one of the heads is in line with the shank and the other is at a right angle to the shank.

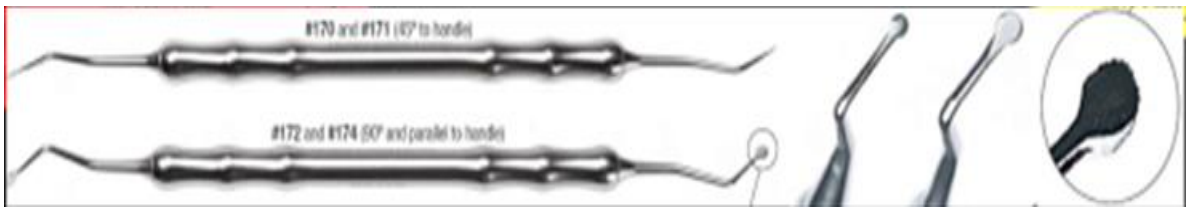

2) Chemo mechanical

Usually in this technique, we use retraction cord that contain a vasoconstrictor (adrenaline or AL.sulfat). Cords are soaked in the Hemostatic solution before placement or Some cords are already impregnated with hemostatic solution eliminating this step (adrenaline 8%, aluminium sulfate, or Aluminium chloride 5-10%).

Whether plain or impregnated cord, the cord pack into the gingival sulcus between the tooth and the gingival tissue, using a plastic instrument (fischer packing instrument or Ash no.6) , the cord will physically push the gingiva away from the finishing line and the combination of the chemical action and pressure packing will cause transit gingival ischemia, this will lead to shrinkage of gingival tissue and control fluid seepage from gingival sulcus, we put the retraction cord inside the gingival sulcus all around the tooth for 10 minutes , the area of our work should be kept dry during this period ,then, the cord can be removed leaving the gingival tissue in an expanding state and this, will provide space to inject the impression material around the tooth at the area of finishing line by the use of impression syringe.

Step-by-Step Procedure

1- Isolate the prepared teeth with cotton rolls, place saliva evacuators and any other aids as required, and dry the field with air. Do not excessively desiccate the tooth because this may lead to postoperative sensitivity.
2- Cut a length of cord sufficient to encircle the tooth.
3- Dip the cord in astringent solution and squeeze out the excess with a gauze square. An impregnated cord can be placed dry but should be slightly moistened in situ immediately before removal from the sulcus, to prevent the thin sulcular epithelium from sticking to it and tearing when it is removed. A convenient way to limit the amount of moisture added is to apply water held between the tips of a dental forceps by opening it.
4- Twist non-braided cords tightly for easier placement.

5- Loop the cord around the tooth, and gently push it into the sulcus with a suitable instrument.

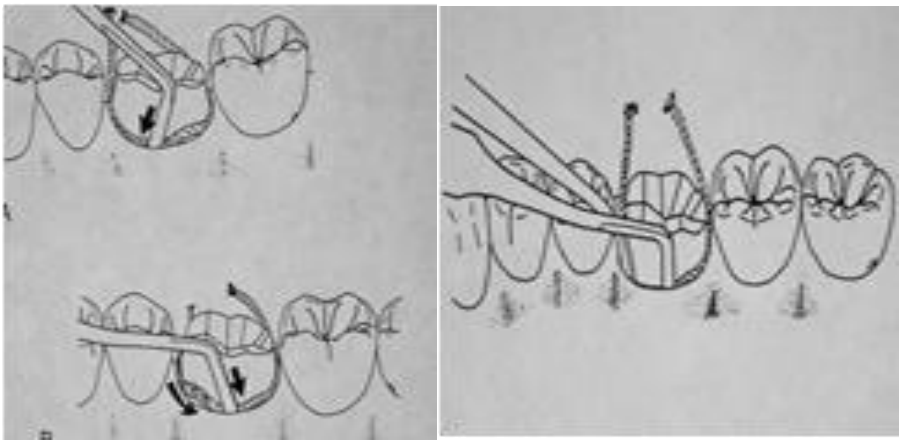

These notes should be considered during cord placement procedure

1- Starting point: It is easiest to start inter-proximally, because more sulcular depth available than facial or lingual.

2- Instrument angulation: The instrument should be angled slightly toward the tooth so that the cord is pushed directly into the sulcus, also be angled slightly toward any cord previously packed; otherwise, it might be displaced. A second instrument holding the cord may aid in subsequent placement.

3- Placement and pressure: Gentle and Firm Pressure applied to the cord, it should place apical to the margins of preparation.

4- Over packing and repeated use of displacement cord should be Avoided it could cause tearing of the gingival attachment, which leads to irreversible recession.

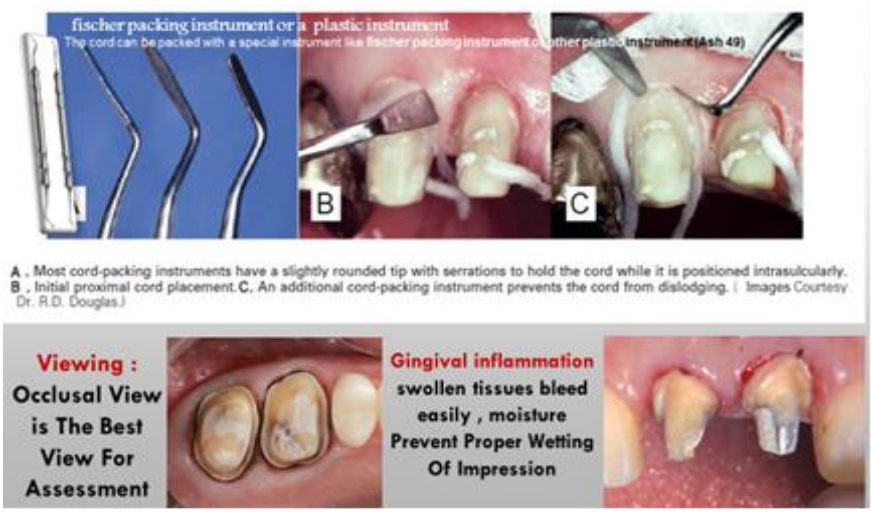

Double (dual) Cord Technique

With a deeper subgingival preparation, after removing the cord, the sulcus 'closes' not allowing the ingress of the impression material in the subgingival area, so in such a case you might need to use 2 or double cords.

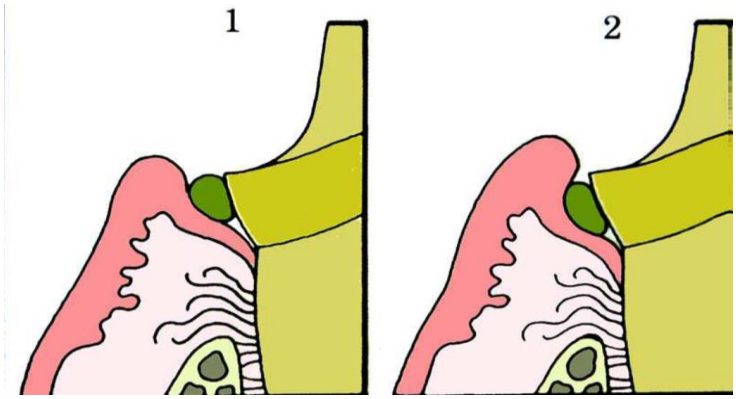

When 2 cords are need, it requires that about 1 mm of intact tooth structure remains between the top of the initial cord and the preparation margin. The first cord is thin, left during impression taking, while the second cord is thick. In this technique, a thin cord is placed without overlap at the bottom of the gingival crevice. A second cord is placed on top to achieve lateral tissue displacement. The latter is removed immediately before impression making, whereas the initial cord is left in place to help minimize seepage during Impression, be careful not to exert excessive pressure on the tissues, which can damage the epithelial attachment (Biological Width).

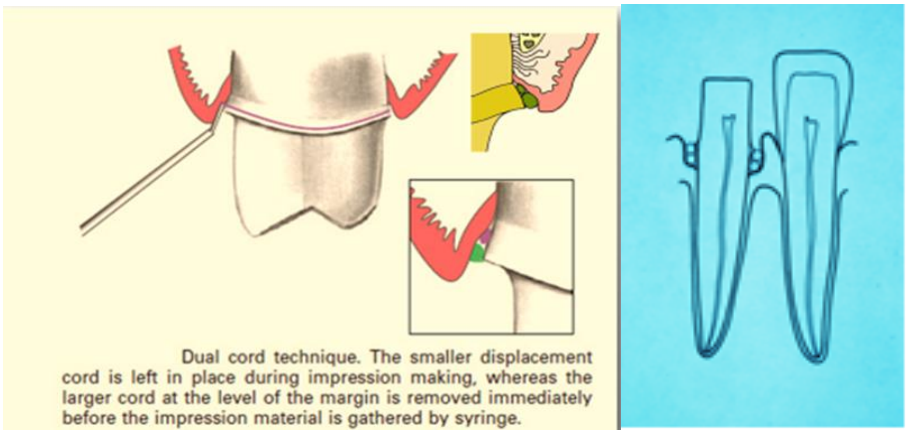

Dual cord technique. The smaller displacement cord is left in place during impression making, whereas the larger cord at the level of the margin is removed immediately before the impression material is gathered by syringe.

This technique is indicated when we have:

1. Impression of multiple prepared teeth
2. Impression for compromised tissue health
3. Excess gingival fluid exudates.

Advantages

1) The first cord remains in place within the sulcus thus reducing the tendency of the gingival cuff to recoil and displace partially set impression material.
2) Helps to control gingival hemorrhage and exudate.
3) Overcomes the problem of the impression tearing because of inadequate bulk, an especially important consideration with hydrocolloids, which have low tear strength.

Remember: Never pack a dry cord

- Dry cord adheres to the cervicular epithelium and may tear the epithelium upon its removal and may elicit a wound healing reaction.
- Dry cord is harder to pack into the sulcus, leads to more bleeding upon cord removal and an unacceptable impression, and makes it more likely that a less than ideal gingival response will follow.

Gingival retraction pastes (Cordless technique)

In most cases, gingival retraction cord is the most effective method for retracting tissue to the depth of the sulcus. Unfortunately, gingival retraction cord may injure the gingival sulcular epithelium and the gingival bleeding is difficult to control when packing a cord into the sulcus making impression difficult or impossible. Using a retraction cord requires proper tissue manipulation and is technique sensitive. For this reason, a new class of gingival retraction materials has been introduced in the form of retraction paste like Expasyl (Aluminum chloride 15%) and Magic Foam Cord (Polyvinylsiloxane, addition type silicone elastomer).

Expasyl retraction paste

It is an AlCl3-containing paste (Aluminum chloride 15%) is injected into the dried sulcus with a special delivery gun. Advantages of this system include good hemostasis with less discomfort than with traditional cord. However, less tissue displacement is achieved than with cord. Improved displacement may be achieved if the paste is directed into the sulcus by applying pressure with a hollow cotton roll.

Magic Foam Cord (Coltène/Whaledent)

Magic foam is a polydimethylsiloxane with a tin catalyst. The resulting release of gas resulted in a fourfold(x4) volumetric expansion. When the paste was applied into the sulcus, reaction between base and catalyst take place with gas release that resulted in volumetric expansion of the material that cause an apically directed flow that enlarged the gingival sulcus and allowed impression making, a hollow cotton roll is used to apply pressure to the expanding foam to directed expansion apically.

Other cordless retraction materials, e.g**., Racegel** (Septodont) **Traxodent** (Premier); **GingiTrac** (Centrix) provide for excellent hemostasis and some gingival retraction.

Whatever is the material, after isolation of the area, the material is injected inside the gingival sulcus starting from the deepest area at interproximal area, leave the material for 5 to 10 minutes then clean the area and inspect the result.

The advantage of cordless retraction technique is providing a non-traumatic, non-invasive tissue management and excellent hemostasis in the gingival sulcus for fixed prosthodontic impressions.

3) Surgical technique (radical or surgical means)

Some methods that use the surgical approaches to improve the visualization of the preparation margins of the tooth are not true retraction techniques. This is because they actually remove some part or all of the overlying gingival tissue in order to expose the finish line of the preparation and/or control hemorrhage. These techniques are more invasive and should only be used in cases where there is adequate amounts of attached gingiva. These methods include the following:

▶ ROTARY GINGIVAL CURETTAGE (GINGETTAGE)

It is a toughing technique involves preparation of the tooth sub-gingivally while simultaneously curetting the inner lining of the gingival sulcus (a portion of the epithelium within the sulcus is removed to expose the finish line). It should be done only on the healthy gingival tissue

CRIETERIA TO BE FULLFILLED FOR GINGETTAGE

- There should be no bleeding on probing

  The depth of the sulcus should be minimum of 3 mm

DISADVANTAGES OF GINGETTAGE

- Instrument has poor tactile sense so this technique is very sensitive

  It can potentially damage the periodontium

TECHNIQUE OF GINGETTAGE

- It is usually done simultaneously along with finish line preparation.
- Portion of sulcular epithelium is removed using a torpedo diamond bur.
- To improve tactile sense hand piece is run very slowly.
- Abundant water should be sprayed during the procedure.
- A retraction cord is impregnated with $AlCl_3$ can be used to control bleeding

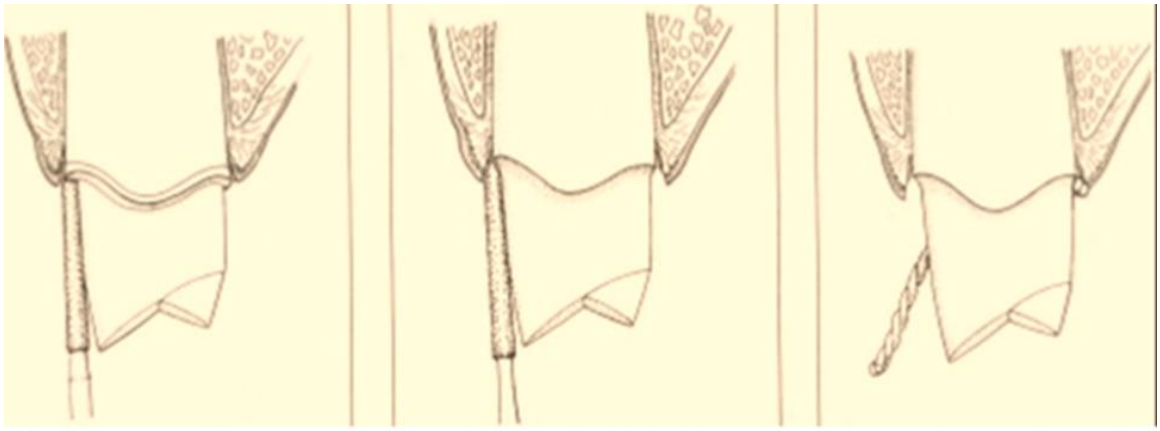

Prior to rotary curettage a shoulder F.L. is formed to the level of the gingival crest

A torpedo diamond point simultaneously form a chamfer F.L. and removes the epithelial lining of the sulcus

A cord is placed in the troughed sulcus for heamostasis

▶ Electro-surgical method

In this technique, an electro-surgical unit could be used to remove the gingival tissue from the area of the finishing line with the advantage of controlling the post-surgical hemorrhage. However, electrosurgery is contraindicated when there is gingival inflammation or periodontal disease. In this case, gingivectomy could be performed. There is the potential for gingival tissue recession after treatment.

Indications:

- ❑ For minor tissue removal before taking impression, toughing the inner epithelium lining of gingival sulcus, improving access for the subgingival margin.
- ❑ Control post-surgical hemorrhage.

Contra-indications:

- ☐ Thin attached gingivae (lower anterior, upper canines)
- ☐ Electronic medical devices Cardiac Piece Makers
- ☐ Metallic restoration & Instruments

▶ Soft issue Laser

Soft tissue lasers have been introduced into dentistry and can provide an excellent adjunct for tissue management before impression making for gingival retraction, Nd- YAG lasers are used.

Advantages of Laser:

1. Certain laser dentistry procedures do not require anesthesia.
2. Laser procedures minimize bleeding because the high-energy light beam aids in the clotting (coagulation) of exposed blood vessels, thus inhibiting blood loss.
3. Precise recontouring of gingiva.
4. No gingival recession and no discomfort to the patient.
5. Bacterial infections are minimized because the high-energy beam sterilizes the area being worked on.
6. Damage to surrounding tissue is minimized.
7. Wounds heal faster and tissues can be regenerated.