Fixed Prosthodontics

Lecture 4 **Fifth Stage**

Biomechanical Considerations of Fixed Partial Denture

Management of the destructive forces

- The design of the bridge must handle the occlusal & dislodging forces such as torque, flexure and tension.
- Occlusion must be designed to optimize the distribution of occlusal forces evenly throughout the envelope of motion over the entire mouth.

The biomechanical considerations include the role of span dimension, pontics' characteristics, the connecters or joints of the prosthesis, abutment tooth & acting forces (masticatory) on the success of the constructed bridge.

Span length

The distance between abutments that affects the feasibility of placing FPDs.

- One missing tooth is ideal for replacements.
- 2-3 adjacent teeth requires careful evaluation of other factors (crown-root ratio, root length & form, periodontal health, mobility, occlusal force & biomechanical factor).

The dimensions of the span (MD length and OG height) affect the number of the selected abutments, type of retainers & materials that are used for bridges' construction. In addition to the increased load placed on the periodontal ligament by long span FPDs, longer spans are less rigid. All FPDs flex slightly when subjected to a load, the longer the span the greater the flexing. Bending or deflection varies directly with the cube of the length & inversely with the cube of the occlusogingival thickness of the pontic.

Length of the span (Law of beam)

It is an engineering principle states that as the length of the span increases, the flexure of a system will be the increase in length to the power of three (cubed)

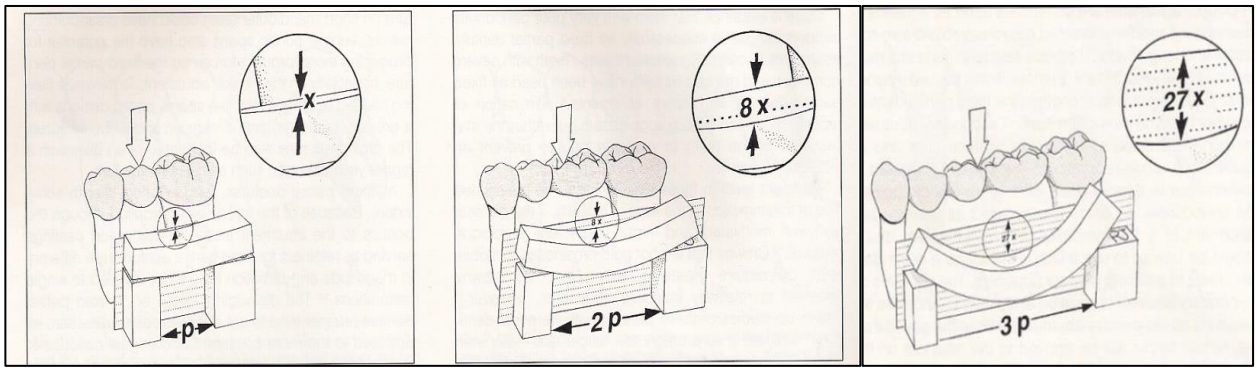

Compared with a FPD having a single-tooth pontic span, a two-tooth pontic span will bend 8 times as much. A three-tooth pontic span will bend 27 times as much as a single pontic.

This mean replacing three missing posterior teeth with FPDs rarely has favourable prognosis, especially in the mandibular arch (Treatment with RPDs or implant supported prosthesis).

Height of the connector (Law of beam)

As the height of the span decreases, the flexure of a system will be the increase in length to the power of three (cubed). Therefore, halving the connector height would yield 8 times the flexure.

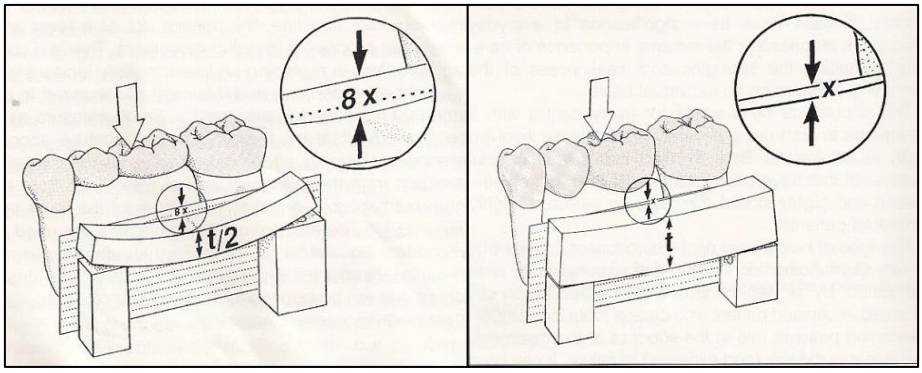

A pontic with a given occluso-gingival dimension will bend 8 times as much if the pontic thickness is halved.

Therefore, a long span FPD on short mandibular teeth can have disappointing results. Excessive flexing under occlusal loads may lead to failure of the long span FPDs (fracture of the porcelain veneer, connector breakage, retainer loosening and caries, or unfavourable tooth or tissue response).

To minimise flexing:

- Select pontic design with greater occlusogingival dimension
- Pontics & connectors should be made as bulk as possible to ensure optimum rigidity without jeopardizing gingival health.
- Long span or unfavourable crown/root ratio then used double abutments to enhance the retention & support the long span FPD.

Double abutment

It refers to the use of two adjacent abutment teeth at one or both ends of a FPD

Indications

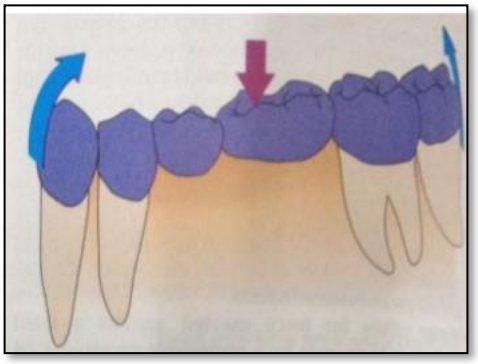

- To increase the retention of the restoration
- To increase area of supporting periodontal ligament and bone.
- Un favourable crown-root ratio
- Long span FPDs
- Splint & stabilise periodontally compromised teeth.

Criteria for double abutment

- Secondary abutments must have as much root surface area & a favourable crown root ratio as the primary abutment.
- The retainers on secondary abutment must be at least as retentive as on primary abutments because when the pontic flexes, tensile forces will be applied on the retainers of the secondary abutments.

Arch curvature:

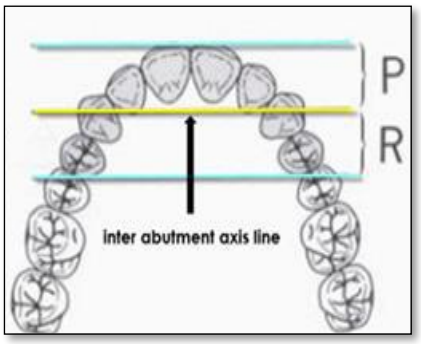

When pontics lie outside the interabutment line, they act as a lever arm, which can produce a torqueing movement.

- This is a common problem in replacing all four maxillary incisors with a FPD.
- It is more pronounced in pointed taper arch anteriorly. The more the taper of the arch, the longer will be the lever arm, the more stress or torqueing force, while the more circular arch curvature reduces such a problem.

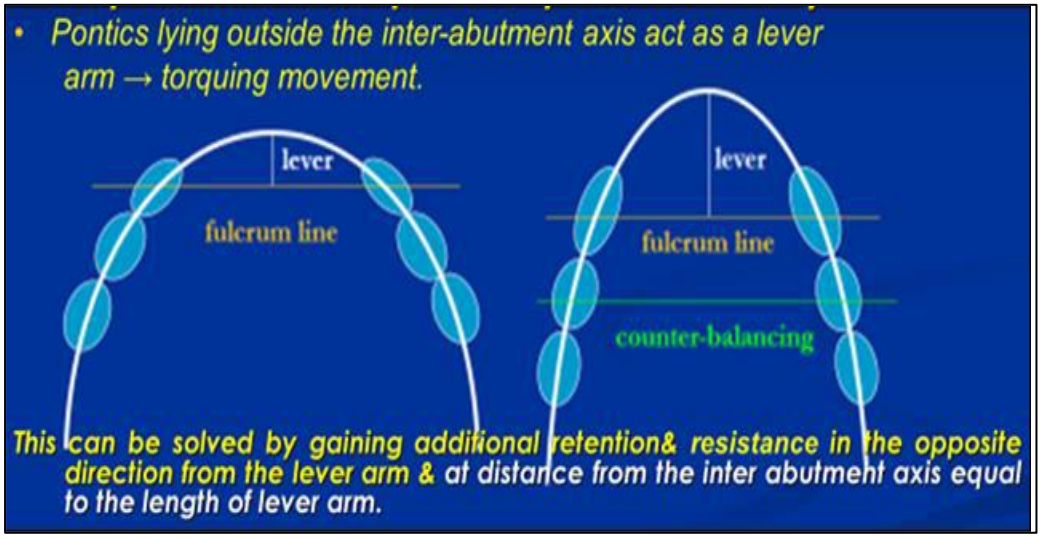

To solve such problem and offset the torque, additional retention is obtained in the opposite direction from the lever arm & at distance from the inter abutment axis equal to the length of lever arm, this mean, that **two abutment teeth at each end of long span anterior FPD** must be used in order to resist this tipping forces. This mean first premolars are used as secondary abutments for a maxillary four pontic canine-to-canine FPD.

Pier (intermediate) abutment:



It is a natural tooth located between terminal abutments that serve to support fixed or removable prosthesis. Because it lies in the middle of the span, it creates huge stresses on the terminal abutments and acts as a fulcrum causing failure of the weaker retainer. These forces loosen the retainer or the casting, or may lead to leakage around the margin leading to extensive caries.

To overcome such complication, you can select one of the following approaches:

1) The use of extremely retentive retainers.
2) When periodontal support is adequate, a much simpler approach would be to cantilever one segment of the bridge on one side of pier abutment.

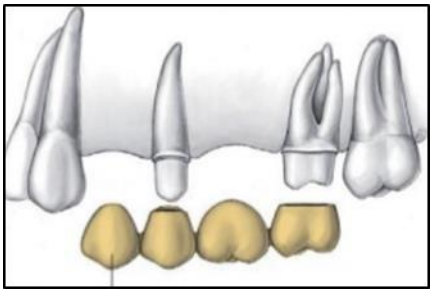

3) Use of non-rigid connector.

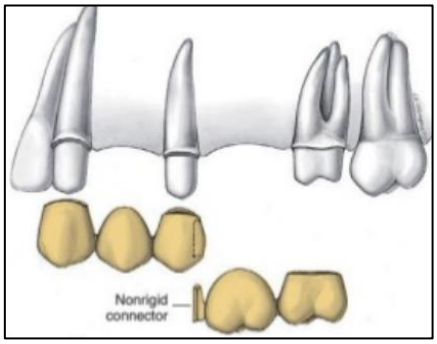

- It is a broken stress mechanical union of retainer (dovetail keyway) & pontic (T- shaped way)
- It transfers shear stress to supporting bone rather than the connectors.
- It appears to minimize mesiodistal torquing of the abutment, while permitting them to move independently.
- The most commonly used non-rigid design T- shaped key that is attached to the pontic & a dovetail keyway placed in the retainer

Location of the key & key way:

- Keyway should be placed within the distal contours of pier abutment.
- Key should be placed on the mesial side of the distal pontic.

Why keyway should be placed on the distal not on mesial of pier abutment?

Long axes of posterior teeth usually lean slightly in a mesial direction and tilt more mesially when subjected to occlusal forces. Therefore, if keyway is placed on the distal of pier abutment, then the mesial movement seats the key into the keyway more solidly. If placement of the keyway is on the mesial side then it causes the key to be unseated during the mesial movement which in time can cause a pathologic mobility in the canine or failure of the canine retainer.

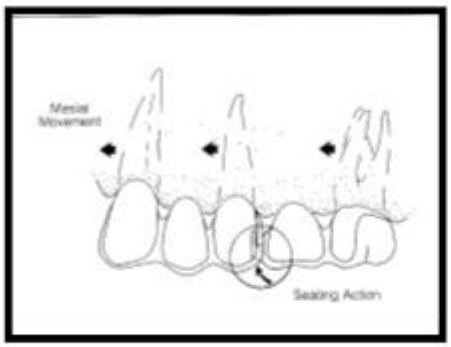

Nonrigid connector on distal side of pier abutment.

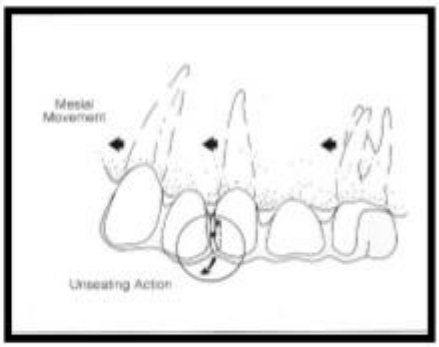

Nonrigid connector on mesial side of pier abutment.

Tilted molar abutment: Mesially tilted second molars

The early loss of mandibular 1st molar due caries is still relatively common. If this space is ignored, the 2nd molar will tilt mesially with the eruption of 3rd molar which inturn might be drifted & tilted with the 2nd molar. Then it becomes difficult to make a satisfactory FPD, due to the positional relationship no longer allows for parallel path of insertion without interferences from adjacent teeth, added to the excessive preparation that is needed.

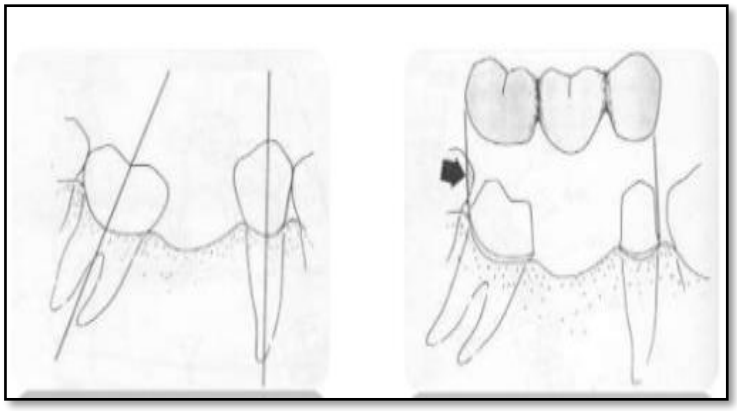

To solve this problem:

1- Ortho treatment (Uprighting the tilted tooth)

If the tilting is severe, uprighting of the molar is indicated by orthodontic treatment. This helps in distributing the occlusal forces & eliminating the bony defects along the mesial surface of the root. In such case the 3rd molars, if present, are better to be extracted to facilitate movement of 2nd molar (Average treatment time 3 months).



2- Using proximal hall partial crown as a retainer on tilted molar abutment

Proximal half-crowns can be used as a retainer on distal abutment. This is simply a three-quarter crown that has been rotated 90 degrees so that the distal surface is uncovered. It is possible only if:

- The distal surface is caries free.
- The distal surface is not decalcified.
- There is a very low incidence of proximal caries throughout the mouth.
- The patient is able to keep the area exceptionally clean.
- If there is a Severe Marginal Ridge Height Discrepancy between the distal of the 2nd molar & the mesial of the 3rd molar the proximal-half crown is contraindicated

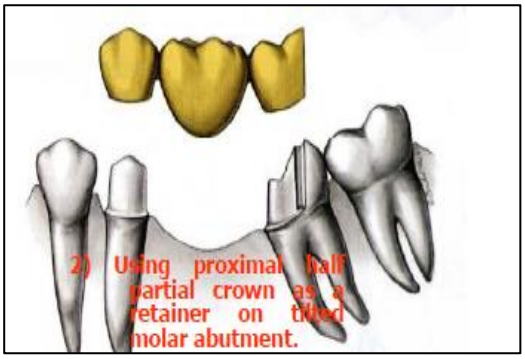

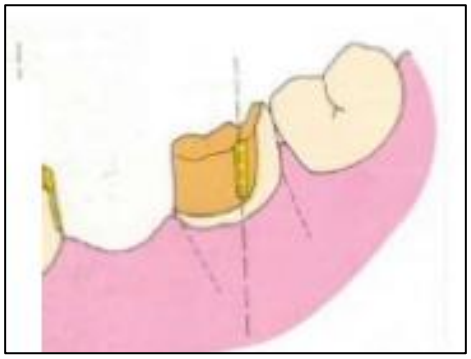

3- Using telescope crown & copping as retainer.

A telescope crown & coping can be used as a retainer on the distal abutment

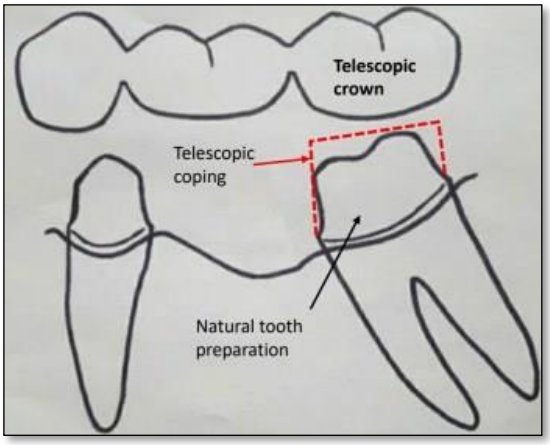

i.e. Full crown preparation with heavy reduction is made to follow the long axis of tilted molar. An inner coping is made to fit the tooth preparation and a proximal half-crown that will serve as a retainer for the FPD is fitted over the coping.

Advantages: it allows total coverage of the clinical crown while compensating for the discrepancy between the path of insertion of the abutments.

4- Non rigid connector is another solution to the problem.

The connection of fixed bridges in some manner that will allow the various components of the prothesis to be seated separately

A full preparation is done on the molar with its path of insertion parallel with the long axis of the tilted tooth. A box form is placed on the distal surface of the premolar to accommodate a keyway in the distal aspect of the premolar. Reasons for NOT placing the non-rigid connector on the mesial aspect of the tipped molar is that it can lead to greater tipping of the tooth.

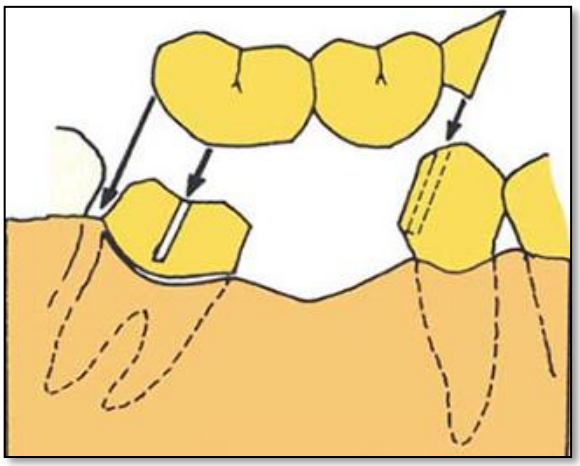

It is indicated when the molar exhibits marked lingual as well as mesial inclination because the routine FPD in such cases will lead to drastically overtapered preparation with no retention.

Because telescope crowns and non-rigid connectors both require tooth preparations that are more destructive than normal, the selection of one of these would be influenced by the nature of previous destruction of the prospective abutment tooth for ex. the presence of a dowel core or a DO amalgam on the premolar would favour placement of a non-rigid connector, while extensive facial and / or lingual restorations on the tilted molar would call for the use of a telescope crown.

Canine replacement fixed partial denture

FPDs replacing canines can be difficult because the canine often lies outside the interabutment axis.

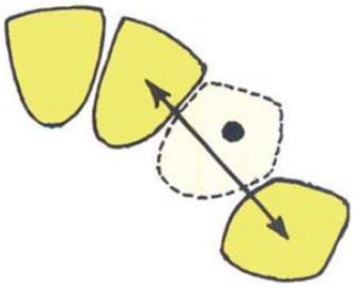

The prospective abutments are the lateral incisor usually the weakest tooth in the entire arch, & the 1st premolar, the weakest posterior tooth.

A FPD replacing maxillary canine is subjected to more stress than that replacing a mandibular canine since forces are transmitted outward (labially) on the maxillary arch, against the inside of the curve (its weakest point) & the pontic lies farther outside the inter-abutment line axis.

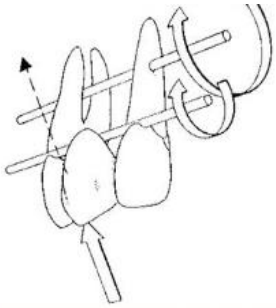

While, in mandibular canine, the forces are directed inward (lingually), against the outside of the curve (its strongest point), & the pontic is closer to the inter-abutment axis.

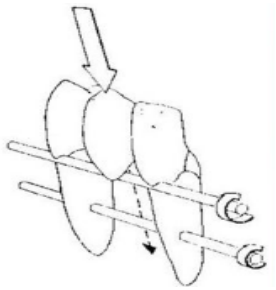

So in cases of canine replacement FPD, you should consider the following points:

- Any canine replacement FPD must be considered a complex
- No FPD replacing a canine should replace more than one additional tooth (the support from secondary abutments will have to be considered).
- An edentulous space created by the loss of a canine and any two contiguous teeth is best restored with Implants or a RPD.

Evaluation of the path of insertion

- Path of insertion should be check before imprint.
- Parallelometer-mirror can easily spot the positional relationship of the prepared abutments, especially in difficult case or inexperience dentist.

