Fixed Prosthodontics

Lecture 3 **fifth stage**

Evaluation of Abutment tooth

Abutment in fixed prosthodontic terminology is a tooth or portion of a tooth that supports and/or retains a fixed bridge or part of the bridge, to which the retainer is connected (cemented).

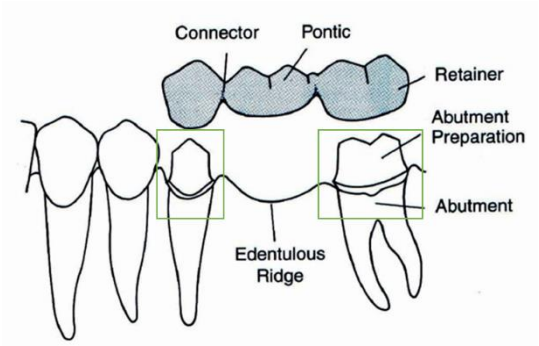

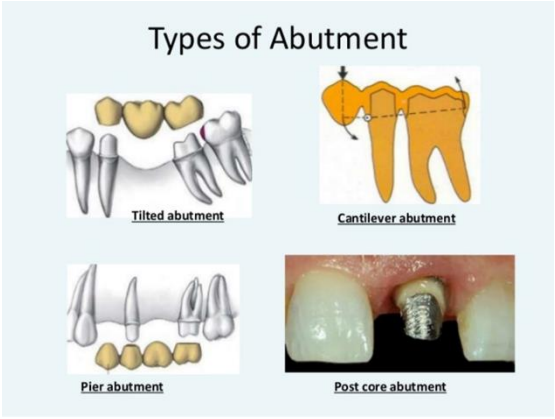

All forces that are absorbed by the missing tooth are transmitted, through the pontic, connectors, & retainers to the abutment teeth. Abutment teeth must withstand forces that are normally directed to the missing teeth, in addition to those usually applied to the abutments, therefore, the choice of abutment is important because it has to withstand the forces that acting on it and on the pontic.

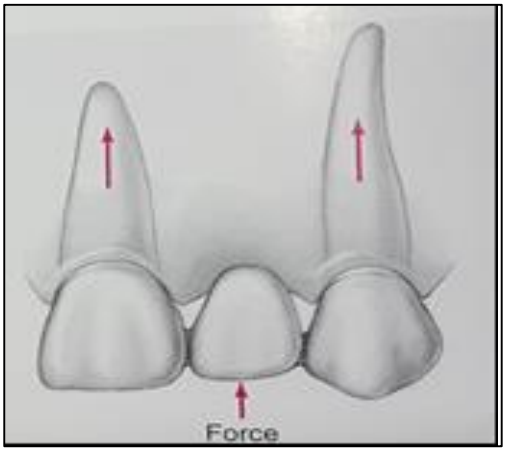

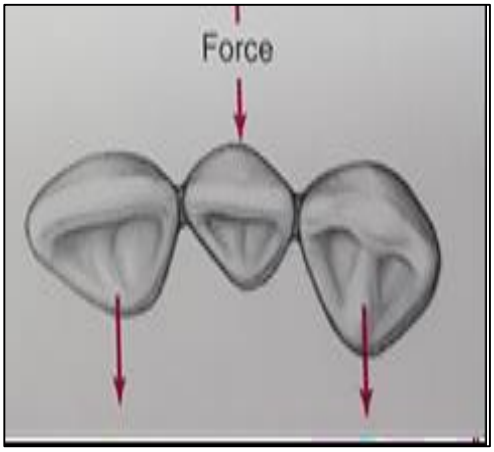

So the clinician have to evaluate the abutment teeth carefully

Considerable time & expense are spared by thoroughly investigating each abutment tooth before proceeding the preparation. Radiographs are made & the pulpal health is assessed by evaluating the response to thermal & electrical stimulation.

Evaluation Aids:

They include; clinical examination using examination tools, vitality test, radiographs, diagnostic casts, & periodontal probe.

Requirements:

1- The abutment must withstand forces normally directed to the missing teeth, whenever possible the abutment should be vital tooth.

2- A symptomatic endodontically treated teeth with a radiographic evidence of good seal & complete obturation of the canal can serve as abutment (post & core for retention & strength).

3) The supporting tissue surrounding the abutment teeth must be healthy & free of inflammation.

4) Abutment teeth must not exhibit any mobility, since they will be carrying an extra load. Sever uncorrectable periodontal disease is contraindicated for FPDs.

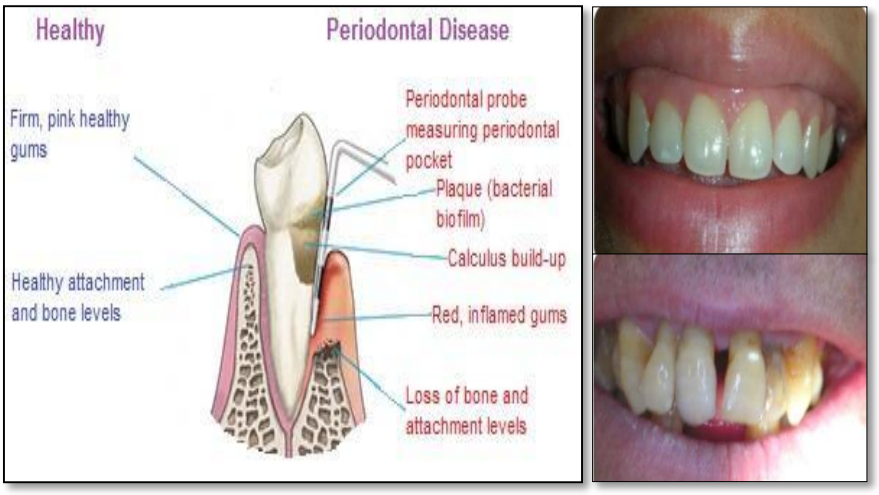

Abutment evaluation (selection):

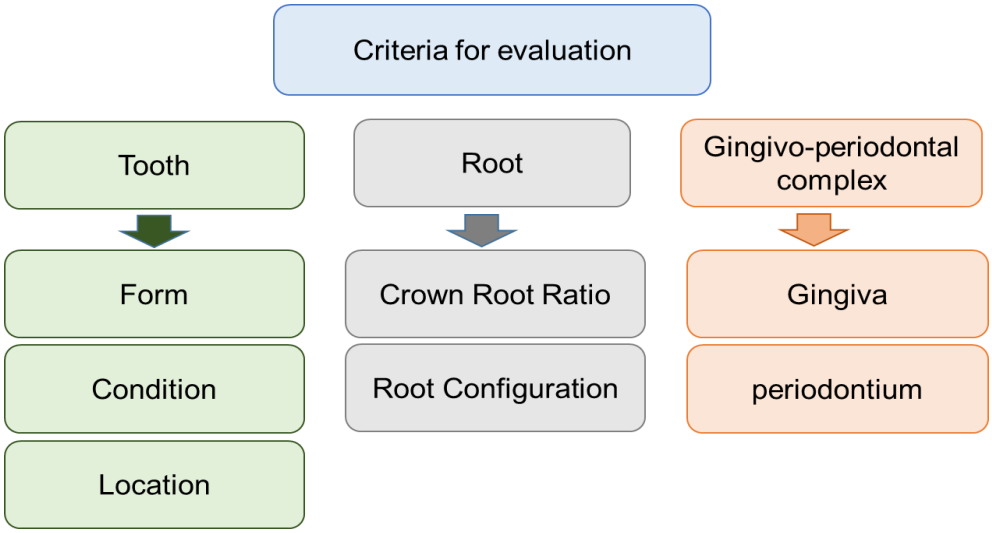

Factors related to tooth (abutment)

1. Shape:

Some teeth have conical, peg, bulbous or tapered crown form that interfere with the preparation parallelism, necessitating full coverage crowns to improve aesthetics and retention. Examples; Peg laterals, anterior teeth with poorly developed cingula and short proximal walls, mandibular premolars with poorly developed lingual cusps & short proximal surface, and thin incisors.

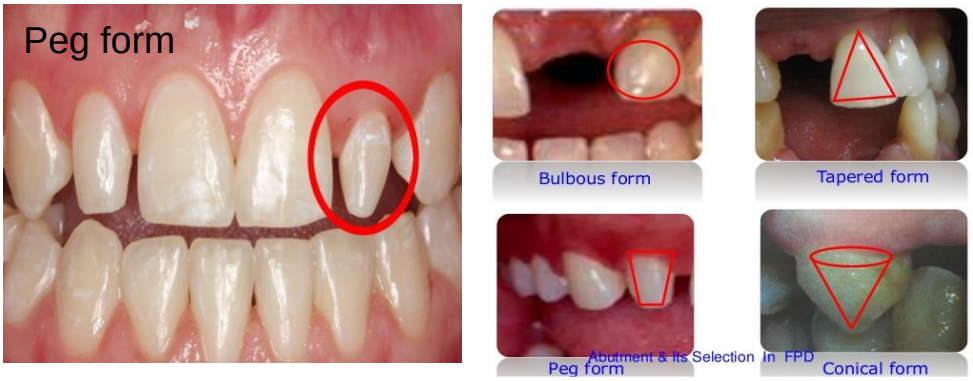

2. Crown length

- Abutment teeth must have adequate occlusocervical crown length to achieve sufficient retention. Full coverage restorations & crown lengthening are considered with short clinical crowns to ensure adequate retention.

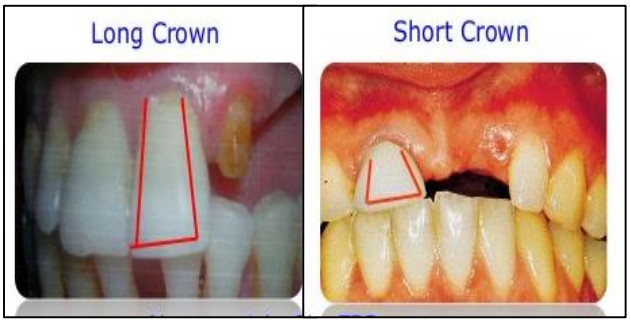



3. Size of the crown:

It determines the type of retainer to be used. For example: short, thin, conical, tapered teeth are poor indication for partial veneer crown.

4. Health of abutment (caries or pulpal):

- A sound abutment tooth permits ideal type of preparation. Carious tooth may be used as abutment if the caries is removed with pulp protection (lining) and then restored to its original form by suitable filling material.

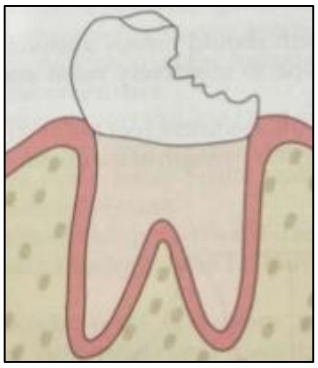

- Degree of mutilation of the crown: The size, number & location of the carious lesion or restorations in a tooth will influence the type of the retainer on the abutment. If the caries is small and far away from the margin, the retainer design will extend beyond the caries area. If the mutilation/fracture is severe, removal of the tooth might be indicated.

-Vital teeth are preferred, however, pulpless teeth can be used only after endodontic treatment. Pulp capped teeth should be avoided because they are under risk of requiring RCT.

- Modifications like dowel core and pin retained restorations may be needed to restore crown morphology in grossly destructed teeth.

5. Axial relationship:

a) Rotation, tilting, over lapping, malposition might lead to a decision of excluding such a tooth to be used as abutment (because rotation or torque can damage the supporting structure or cause retainer to become loose).

b) It may indicate the use of specific retainer (over reduction lead to weaken the tooth & endanger pulp health).

c) Rotation lead to either increase or decrease of space available for pontic (size of pontic planned).

Factors related to root

1. Root configuration (root shape, angulation & length)

- The shape of the roots determine the ability of the roots to handle the occlusal forces. Root that is wider labiolingually than mesiodistally with elliptic cross-section offers better support than a tooth with similar root surface area but has a circular cross-section.

- Parallel-sided roots with developmental depressions are better to resist occlusal forces than smooth-sided conical roots which can be used for short span bridge, if the other factors are optimal.

- A single-rooted tooth with irregular configuration or with some curvature at the apical third of the root is preferable than tooth that has a nearly perfect taper.

- Multi-rooted teeth with separated roots provide greater stability than single-rooted teeth or teeth with conjoined roots.

- Teeth with longer root are stronger abutment than shorter one, since root length is directly proportional to the stability & strength of the prosthesis.

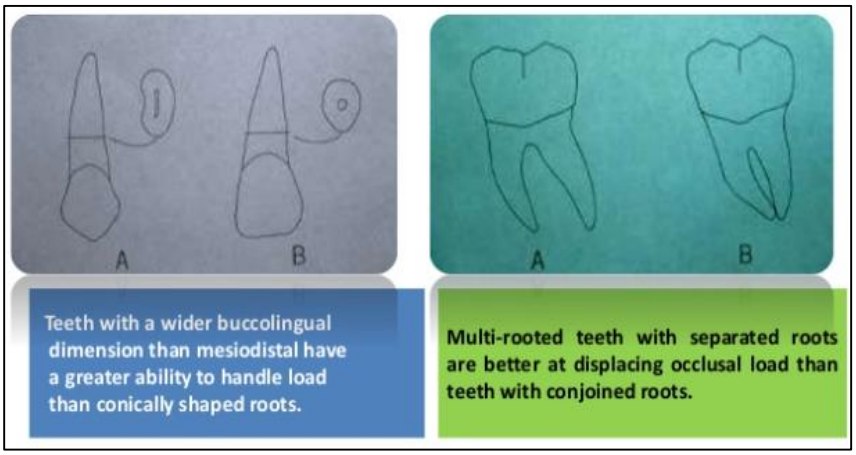

2. Crown - root ratio: It is a linear measurement of the length of the tooth occlusal to the crest of alveolar bone (crown) compared to the length of the tooth that is embedded in the bone (root).

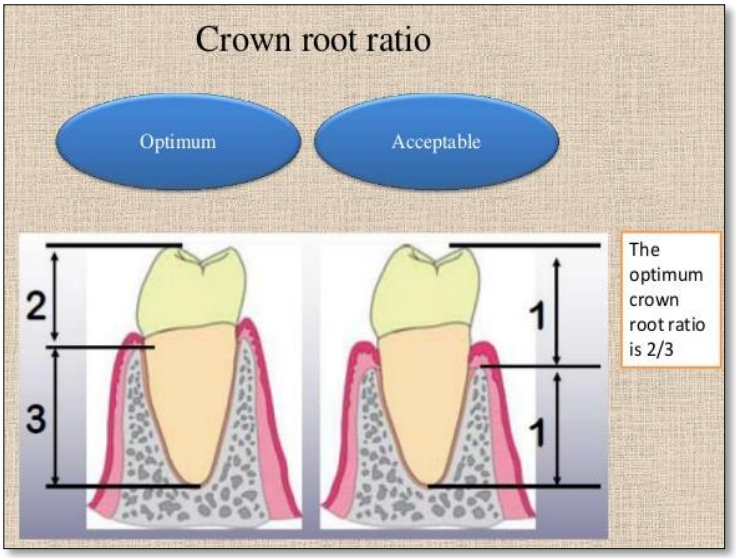

- 2:3 Crown/Root ratio is the optimum for a tooth to be used as abutment.

- 1:1 Crown/Root ratio is the minimum acceptable ratio. It might be considered adequate if the opposing occlusion is mobile or periodontally involved, or it composed of artificial teeth, which reduce occlusal forces that acting on the abutment which means less stress on the abutments.

Factors related to Gingivo-Periodontal complex

- Abutment teeth must be free from periodontal disease, periodontal pockets, osseous defect, and gingival inflammation with adequate zone of attached gingiva.

- The supporting tissue surrounding the abutment teeth must be healthy & free of inflammation. The abutment teeth should not exhibit any mobility, since they will be carrying an extra load. Intra oral radiograph should be used to evaluate bone architecture.

- The alveolar bone support is one of most important factors that aid to evaluate an abutment which must be healthy, have good trabecular architecture with no sign of bone defect or bone loss.

3. Root surface area (Periodontal ligament area):

- The periodontal ligament area can be used as a scale or measurement to determine the potency of an abutment for FPDs.

- Tylman stated that "Two abutment teeth could support two pontics".

- Johnston et al improvised Tylman's statement and proposed the famous ANTE's Law

Periodontal surface area "Ante's law":

- The root surface area of abutment teeth (embedded in bone) (pericemental area) must be equal or greater than root surface area of teeth to be replaced.
- If the periodontal surface area seems inadequate, the use of multiple teeth for abutments may be indicated depending on other biomechanical factors.

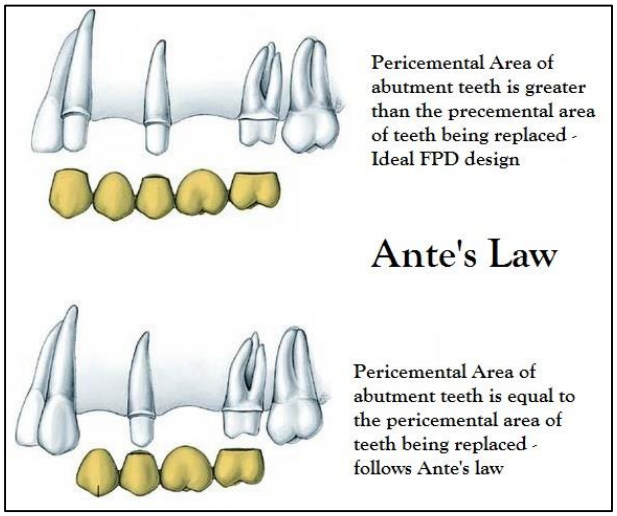

Example: Missing 1st molar alone or with 2nd premolar, the root surface areas of both are equal to the root surface area of abutments (second molar & first premolar).

According to this premise:

- One missing tooth can be successfully replaced if abutment teeth are healthy. In selected case and in order to increase the capability of the bridge to withstand the loading force 1st premolar can be used as a secondary abutment.
- If two teeth are missing, a FPD can probably replace the missing teeth but the limit is being approached.
- If three missing posterior teeth (1st molar & two premolars) or when the root surface area of the teeth to be replaced by pontics are greater than that of the abutment teeth, then a high risk or an unacceptable situation for FPD is exists.

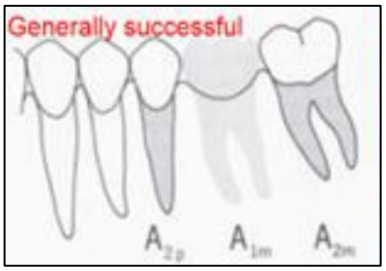





- Jespen (1963) reported average measurements of root surface areas that can be used to calculate the abutment to pontic ratio

Abutment Evaluation

- Periodontal Surface Area (Ante's Law)



Order of Abutments concerning Periodontal Surface Area:

- First Molar
- Second Molar
- Canine
- First Premolar
- Second Premolar
- Central Incisor
- Lateral Incisor

Abutment Evaluation

- Periodontal Surface Area (Ante's Law)

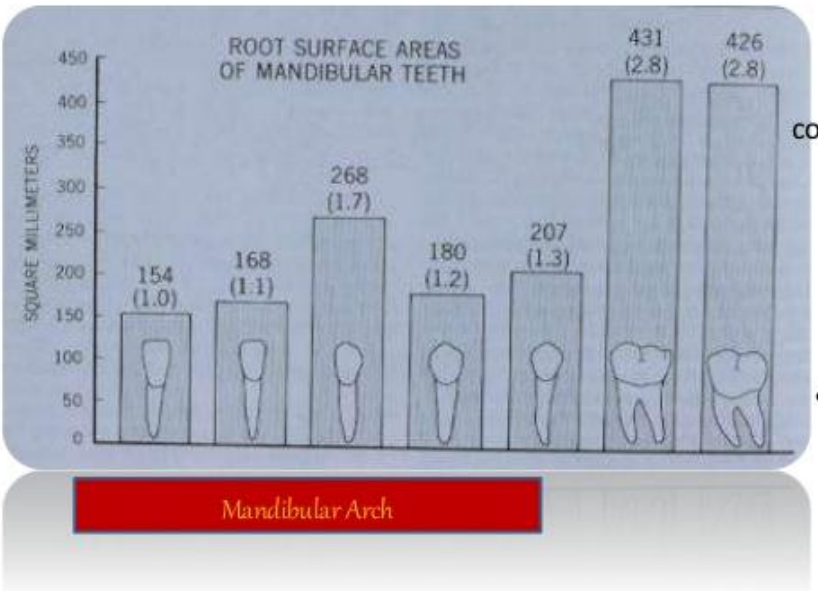

Order of Abutments concerning Periodontal Surface Area:

- First Molar
- Second Molar
- Canine
- Second Premolar
- First Premolar
- Lateral Incisor
- Central Incisor