Fixed Prosthodontics

Lecture 1 **Fifth Stage**

Prosthodontics (prosthetic dentistry or prosthodontia)

The dental speciality that concerned with restoring & maintaining oral functions, comfort, appearance & health of the patients by making artificial replacements for missing parts of the mouth and jaw.

Branches of Prosthodontics

1. Fixed Prosthodontics FPDs
2. Removable Prosthodontics
    a) Complete Denture
    b) Removable Partial Denture RPDs
3. Implant Prosthodontics
4. Maxillofacial Prosthodontics

Fixed prosthodontics (Crown & Bridge Prosthodontics):

It's a branch of dental science that deals with restoring damaged teeth with artificial crown & replacing the missing natural teeth by a dental prosthesis permanently cemented in place (Fixed partial denture).

Types of Fixed Prostheses

1) Extracoronal: It involves all restorations that seat over the tooth such as all types of crown restorations (Full metal crown, partial crown, PFM, all ceramic crown) & direct or indirect veneer restoration.

2) Intracoronal: It involves all restorations that seat inside the tooth such as inlay, onlays, pinlage.



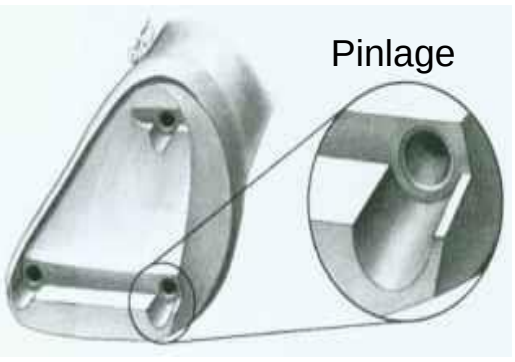

The Crown: It's a fixed extracoronal artificial restoration for the coronal portion of a natural tooth. It must restore morphology, function & the contour of the damaged portion of a tooth and must protect the remaining tooth structure from further damage.

Types of crowns: (Classifications)

A) According to the coverage area

1. **Complete crown:** It covers the coronal portion of the tooth, such as full metal crown, All- ceramic crown (made of ceramic material).

2. **Partial Crown:** It is covers part of the coronal portion of the tooth such as 3/4 Crown, 7/8 Crown.

3. **Complete replacement:** it involves those which replace the natural crown entirely while retains itself by means of a metal extended inside the root canal space of the tooth such as a post crown.

According to materials used in the construction of C&B restorations

1. **Metal Crowns:** Gold alloy and its alternatives

2. **Non-Metal crowns:** Acrylic resin, Zirconium or Porcelain as in jacket crown.

3. **A combination:** of metal and plastic materials as in PFM crown restorations.

Fixed Partial Denture (Bridge)

It is a fixed dental prosthesis (appliance) which replaces and restores function and aesthetic of one or more missing natural teeth. It cannot be removed from the mouth by the patient and primarily supported by natural teeth or root.

Components of the bridge:

1. **Retainer:** It's the part that seat over (on or in) the abutment tooth connecting the pontic to the abutment. It is either major or minor retainer, or it could be crown, inlay, post & core.

2. **Pontic:** It is the suspended member of fixed partial denture that replaces the missing tooth or teeth, usually it occupies the position of the missing natural tooth.

3. **Connector:** It's the part that join the individual components of the bridge together (retainer& pontics), which could be fixed (rigid) or movable (flexible) connector. When the retainer is attached to a fixed connector it's called a major retainer, but when it is attached to a flexible (movable) connector it is called a minor retainer.

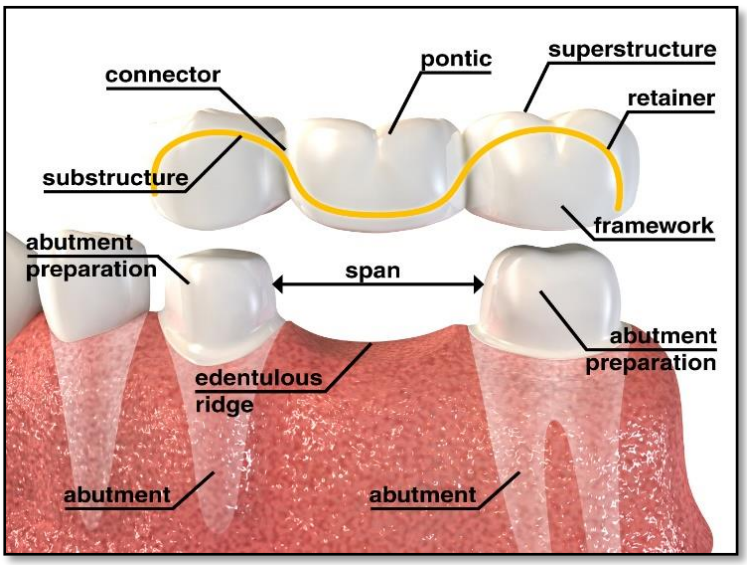

Definitions (terminology)

Abutment: a tooth to which a bridge is attached.

Span: is the space between natural teeth that is to be filled by pontics.

Saddle: is an area of the edentulous ridge over which the pontic lies.

Pier: is an abutment standing between two abutments & supporting two pontics, each pontic being attached to further abutment.

Unit: when applied to bridgework, means either a retainer or a pontic, thus a bridge that replaces a premolar using two abutments is referred as three Unit Bridge.

Path of insertion: An imaginary line along which the restoration can be inserted and removed without any interferences or causing lateral force on the abutment.

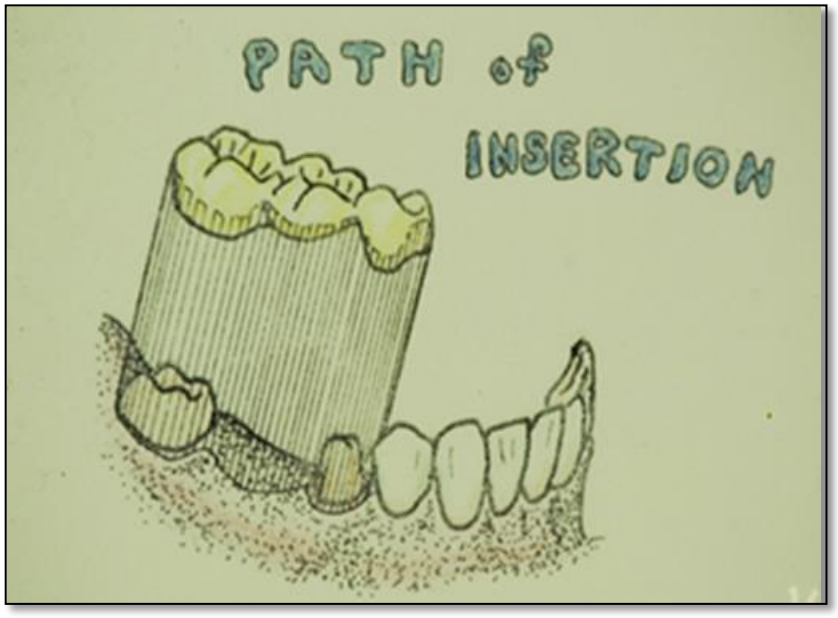

Why do a Fixed Partial Denture?

The stability of an individual tooth depends on a balance of the forces exerted on that tooth by the adjacent, opposing teeth, supporting tissue & by the soft tissue of the cheek, lips & tongue

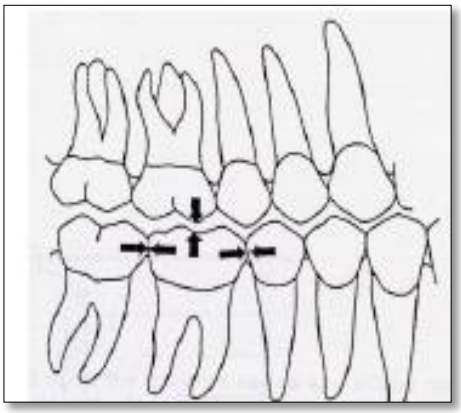



When a single tooth is not replaced (after loss), this balance is upset, & the consequence may by:

1. Super eruption of the opposing tooth or teeth:

a) Gingival recession

b) Traumatic occlusion or lacking of bite

c) Loss of bony support for that tooth.

d) Loss of the proximal contact

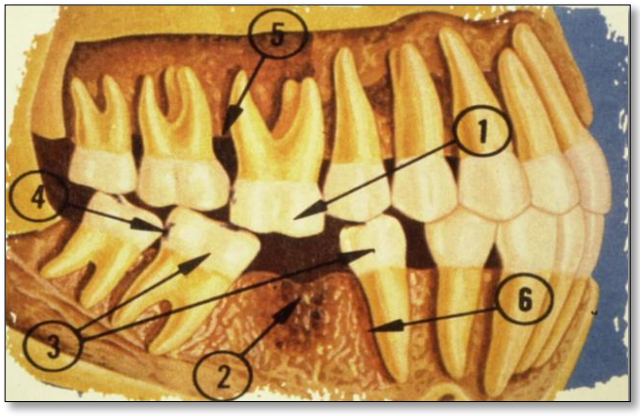

2. Loss of function on the affected side:

a) Diffuse atrophy.

b) Heavy deposition of plaque & this lead to gingivitis & periodontal disease.

c) Trauma to the soft tissue during function.

d) Loss of tissue (contraction of both soft tissue & alveolar bone).

3. Tilting (drifting) of the adjacent teeth.

4. Loss of the proximal contact to:

a) Food stagnation & pocketing

c) Sub-gingival caries

5. Periodontal problem & mobility

Posterior Bite Collapse:

The posterior teeth support the vertical height of the face. If they are lost, the face tends to lose height and close down; this is called “posterior bite collapse”



Figure 1: The back teeth and front teeth work in harmony. The back teeth support facial height & chew food while the front teeth cut food, protect the back teeth in lateral jaw movements and provide your smile



Figure 2: The loss of the back teeth place excessive pressure on the front teeth causing shifting of teeth and slight loss of facial height.



Figure 3: Without replacement of the back teeth, the teeth start to shift and excessive pressure causes the front teeth to spread forward. Loss of facial height occurs

The general effects of tooth loss:

1) Generalized collapse of lower & upper dental arches.

2) Premature contact causing deviation in the normal movement of the mandible which might lead to TMJ dysfunction & muscle spasm that cause pain.

3) Tooth loss may lead to unilateral mastication on the opposite side of the dental arch which results in periodontal problems, caries on the affected side due to deficient mechanical cleaning afforded by the act of mastication.

4) Posterior bite collapse these changes also put pressure on the front teeth which tend to move or splay forward.

Treatment at this stage prevents further disruption, it may be insufficient to ration back to full health, it need extended treatment plans including, ortho. Treatment, additional cast restoration to correct the disturbed occlusal plane.

Reasons for treating tooth loss

1) Aesthetic.

2) Function (ability to eat).

3) Pain due to TMJ dysfunction & muscle spasm

4) Maintenance of dental arch (occlusal stabilization & prevent tilting)

5) Speech (particularly lower incisors).

Methods of treating tooth loss

- Orthodontic.
- Removable partial denture.
- Fixed partial denture (tooth supported partial denture).
- Implant (Osseo-integrated implant).
- Combination.

In some case the decision might be no prosthetic treatment

1) Long standing edentulous space (long span) into which there has been little or no drifting or elongation of the adjacent teeth.
2) Lack of distal abutment.
3) If the patients perceives no functional, occlusal or aesthetic impairment.

