CARDIOVASCULAR MODULE PHYSIOLOGY

SYNCOPE PART 2

GRADE: FIRST YEAR – ASHUR MEDICAL COLLEGE

2023/2024

MODULE: SYSTEMIC (PHYSIOLOGY)

DR TAREEF FADHIL : ASSISTANT PROFESSOR & CONSULTANT PEDIATRICIAN

22 / 5/2024

MAY 22, 2024

3. CARDIOGENIC SYNCOPE



Pathophysiology : reduced cardiac output or reduced venous pooling

A- Structural

1. Myocardial infarction with pump failure.

2. Valve diseases (aortic stenosis, mitral stenosis).

3. Effort syncope: common in patients having aortic or pulmonary valve

4.Congestive heart failure.

5. Advanced cardiomyopathy

B- Arrhythmias : 1.**heart block**

2.severe tachycardia eg SVT .

3.prolonged QT interval.

ECG IN CARDIOGENIC SYNCOPE

HEART BLOCK

First Degree AV Block

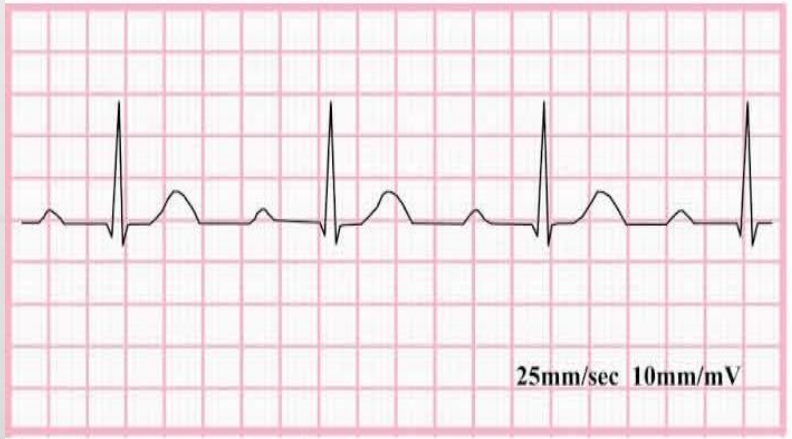

Rhythm:	Regular
PR interval:	Prolonged >0.20 sec
P Wave:	Normal
QRS:	<0.11 sec

Second Degree AV Block - Type 1 (aka Mobitz 1, Wenckebach):

P-R INTERVALS BECOME PROGRESSIVELY LONGER UNTIL ONE P WAVE IS BLOCKED, AND A QRS IS DROPPED.

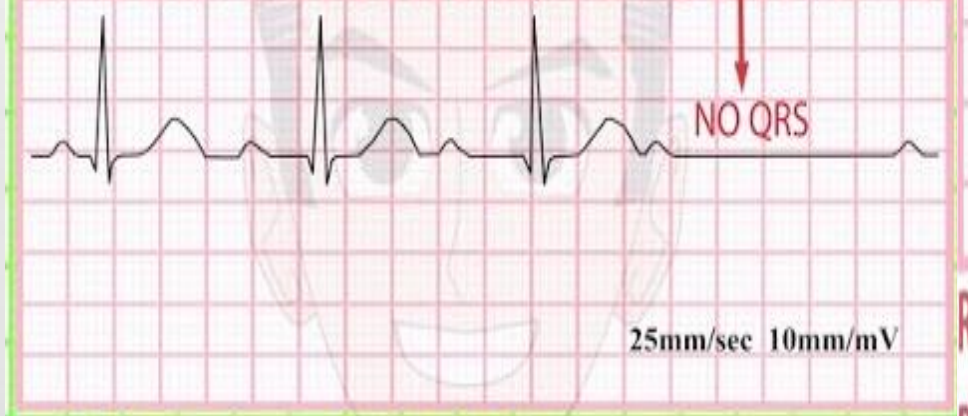

Rhythm:	Irregular
PR interval:	Increasingly Prolonged
P Wave:	Normal
QRS:	<0.12

Second Degree AV Block - Mobitz Type 2

Common ratio 2:1, 3:1, or 4:1



Rhythm:	Irregular
PR interval:	Normal (more P waves then QRS)
P Wave:	Normal
QRS:	Usually wide >0.10

3rd Degree AV Block

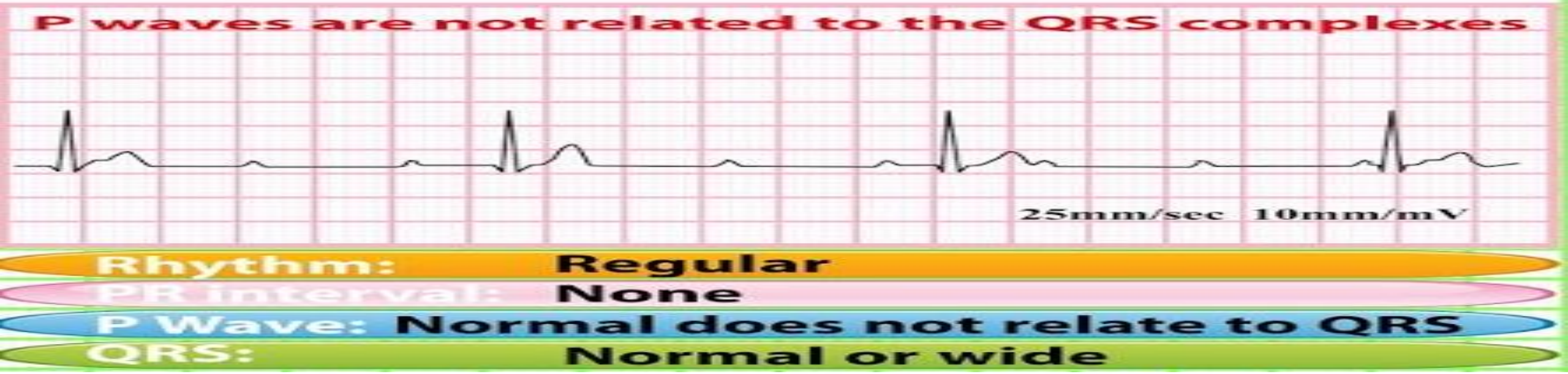

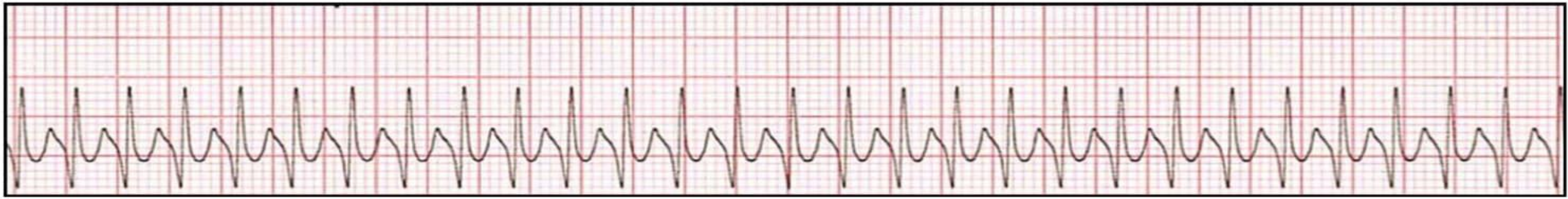

Supraventricular Tachycardia

Rhythm: Regular
Rate: 280 bpm (SVT is defined as >100bpm. Typically under 150bpm has no symptoms.)
P Waves: Present but difficult to see on the end of the T wave because of rapid rate
P-R Interval: 0.12 sec (normal range= 0.12-0.20), one P wave for each QRS, again difficult to see
QRS: 0.04 sec (normal range= 0.04-0.12)

MYOCARDIAL INFARCTION

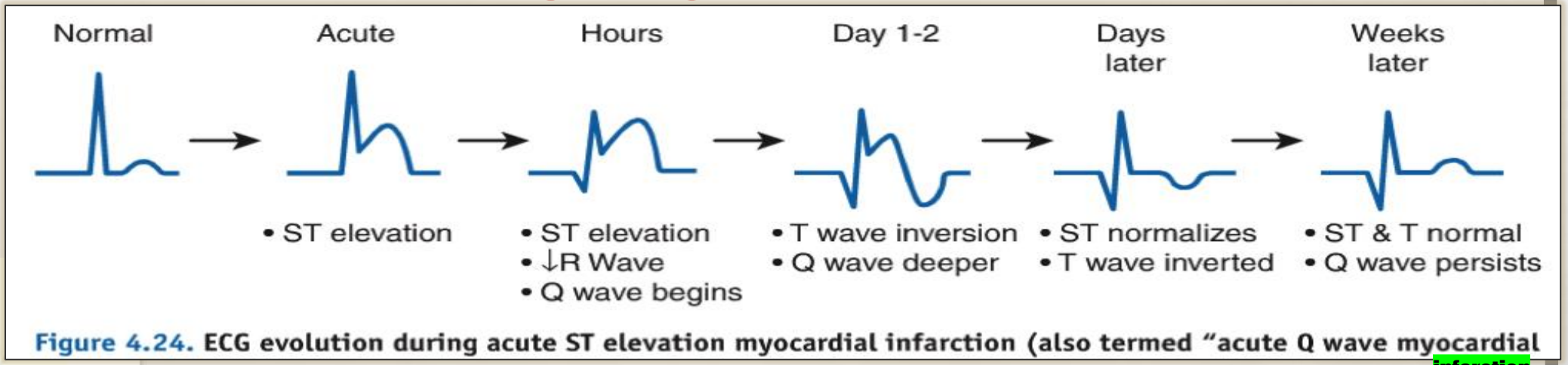

Figure 4.24. ECG evolution during acute ST elevation myocardial infarction (also termed "acute Q wave myocardial infarction

NSTEMI

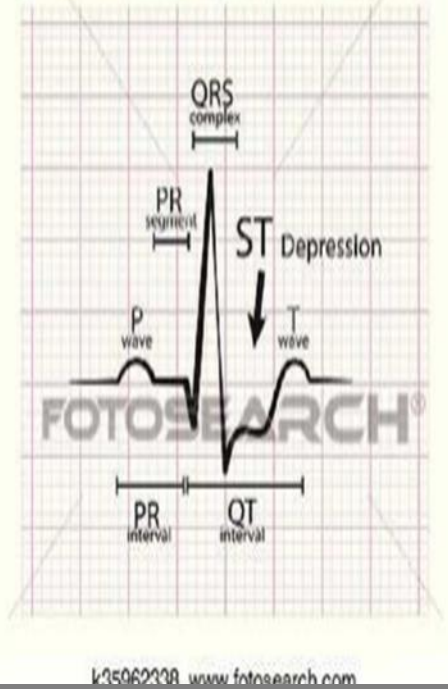

It's generally true that in many cases of ST-segment myocardial ischemia, ECG changes can occur early and precede the detectable rise in cardiac markers.

Both ECG changes and cardiac markers are used in the diagnosis of NSTEMI, cardiac markers, particularly troponin, are generally more sensitive for detecting myocardial injury in NSTEMI compared to ECG changes.

CLINICAL

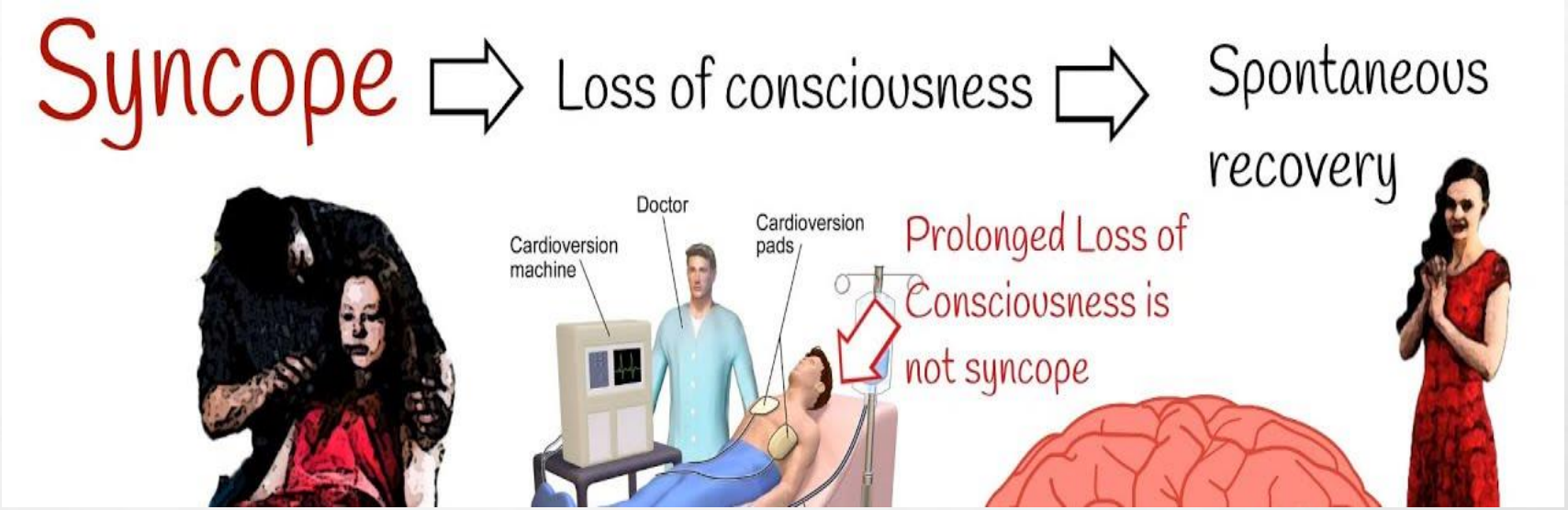

Absence of postural tone leading to collapse, followed by complete and usually rapid spontaneous recovery. Last only a few minutes.
A person who has fainted typically exhibits shallow breathing, a weak pulse, and low blood pressure.



Symptoms may overlap between different types of syncope, certain features may help distinguish one type from another. 1.*Reflex Syncope:1.1. Vasovagal:*

A- Often preceded by trigger and prodromal symptoms • Lasts about 2 minutes such as dizziness , nausea, sweating, and pallor.

B- May be triggered by specific situations or stimuli, such as emotional stress, pain, or sight of blood.

C- Usually lasts 5-20 seconds .

D-Occurs in sitting or standing positions.

E-Typically occurs in younger individuals and may have a strong familial predisposition.

1.2.Situtional:

1.3. Carotid sinus:

2. Orthostatic Syncope:

1. **Occurs upon standing up from a sitting or lying position.**
2. **Symptoms may include lightheadedness, dizziness, blurred vision, weakness, and palpitations.**
3. **Often associated with conditions that affect blood volume or autonomic nervous system function, such as dehydration, blood loss, or autonomic neuropathy.**
4. **Recovery may occur quickly once the individual sits or lies down, allowing blood flow to the brain to normalize.**

3. Cardiac Syncope:

1. Can occur suddenly and without warning.
2. Often associated with underlying heart conditions, such as arrhythmias (abnormal heart rhythms), structural heart disease, or coronary artery disease.
3. May be preceded by symptoms such as palpitations, chest pain, shortness of breath, or fatigue.
4. Recovery may be slower, and the individual may remain unconscious for a longer duration compared to vasovagal syncope

Neurally Mediated Reflex Syncope --what happens?

- Stress causes an abnormal autonomic reflex
- Normal increased sympathetic tone replaced by increased vagal tone
- Variable contribution of vasodilation and bradycardia.
- Examples include syncope from:
  - Pain and/or fear
  - Carotid sinus hypersensitivity
  - "situational" (cough, micturition, defecation syncope)

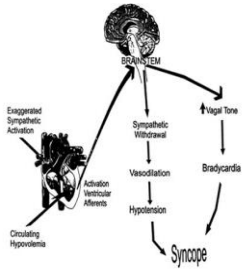

Medical Center

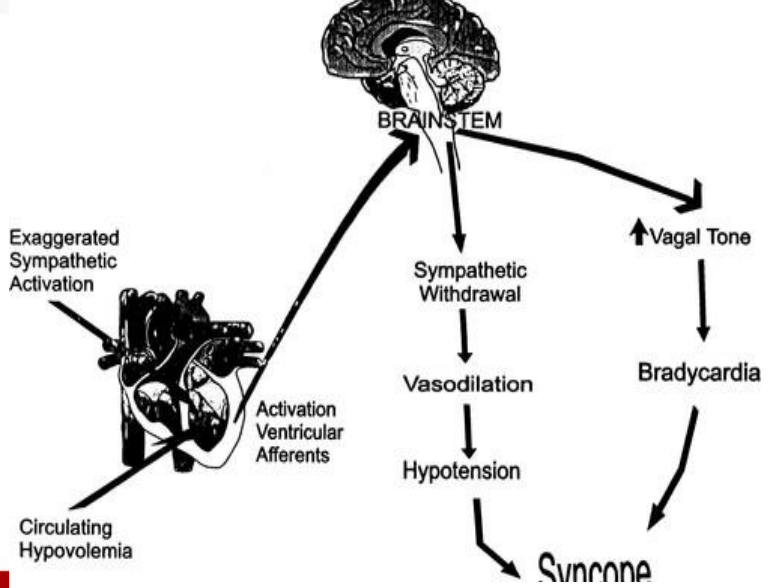

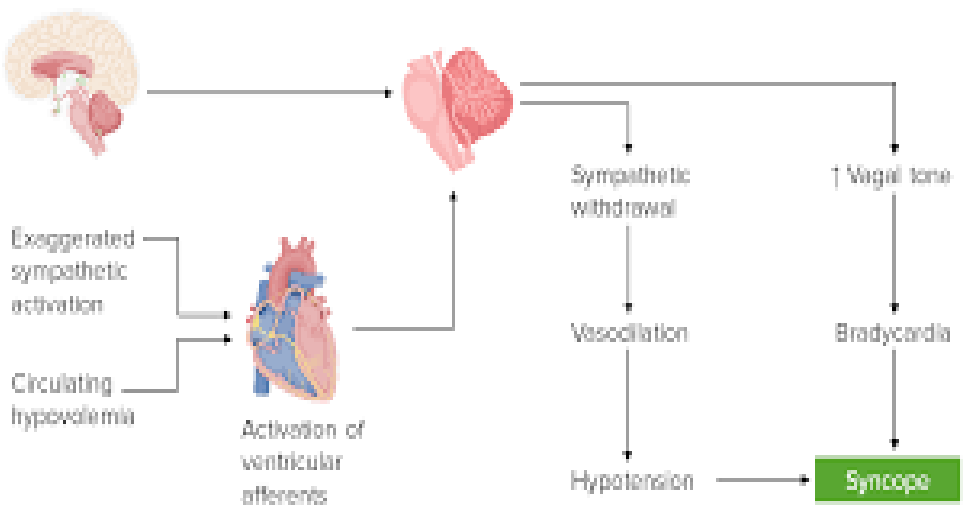

1. REFLEX SYNCOPE (NEURALLY MEDIATED)

PATHOPHYSIOLOGY

1-

– Increased Parasympathetic activity
• Cardioinhibitory effect
Chronotropic (heart rate) effect

2-

– Decreased Sympathetic activity
• Vasodilation
– Pooling of blood in the periphery, decreased venous return
- Drop in blood pressure during the fainting episode
- Negative Ionotropic (heart contraction)

3 – These contribute to » Decreased Cardiac Output the subsequent fainting (syncope).

Enhancement of parasympathetic nervous system (vagal) tone and withdrawal of sympathetic nervous system tone. It occurs when there is a sudden drop in blood pressure and heart rate due to a reflex response of the autonomic nervous system.

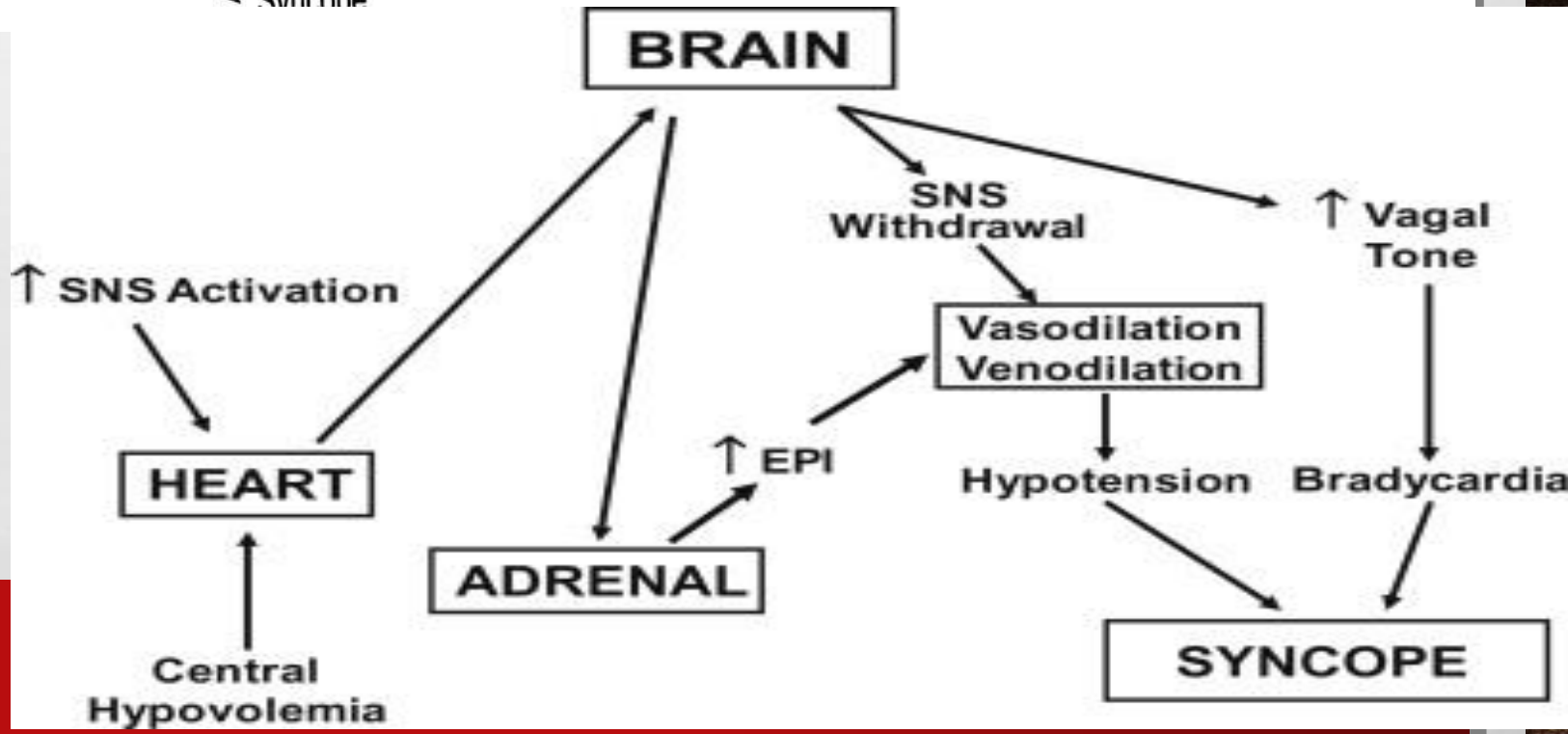

CONCLUSIONS

Syncope is a transient, self-limited loss of consciousness with an inability to maintain a postural tone which can happen as:

1- An exaggeration of normal physiological response e.g. postural syncope(orthostatic).

2- Inapproperiate signal response by triggering baroreceptors by cough, lough, carotid sinus, Valsalva maneuver, and vasovagal.

Pain-Induced Vasovagal Syncope: Triggered by intense pain, emotional stress, or the sight of blood, this type of syncope results from an abnormal reflex. This inappropriate autonomic response is the body's overreaction to certain stimuli, causing a temporary loss of consciousness.

3-Paradoxical (parasympathomimetic response secondary to initial sympathomimetic response eg pain (vasovagal).

•Trigger (e.g., pain) → Initial Sympathomimetic Response (↑ Heart Rate, ↑ Blood Pressure). Secondary Parasympathomimetic Response (↓ Heart Rate, ↓ Blood Pressure) → Vasovagal Syncope (Loss of Consciousness). Prolonged periods of upright posture

4- Protective when hypovolemia and hypoperfusion can affect the brain.

Homework: Compare between sympathetic and parasympathetic effects on Heart and Blood vessels.