

Prosthodontics

Diagnosis and treatment planning for Cr/Co RPD

Lec. 3

Dr. Saja Kareem



- **Indications for RPD**

There are several specific indications for the use of removable partial denture-:

1) The most common situations are partial edentulous space Cl I and Cl II which have an edentulous space on the opposite side of the arch is often conveniently present to aid in the required retention and stabilization of the partial denture.

2) The replacement of teeth recent extraction cannot be accomplished satisfactory with fixed restoration.

3) Along span may be totally tooth supported if the abutments and the means of transferring the support to the denture are adequate and if the denture framework is rigid.

4) Need for bilateral stabilization

5) The removable partial denture may act as a periodontal splint through its effective cross arch stabilization of teeth weakened by periodontal disease.

6) Excessive loss of residual bone

7) Economic considerations





Description of each patient uniqueness occurs through patient interview and clinical examination. These include four distinct processes:-





1. Understanding the patient desire or chief concern complain
2. Ascertaining the patient dental need through a diagnostic clinical examination.
3. Developing treatment plane that reflects the best management of desire and need.
4. Executing appropriately sequenced treatment with planed follow up.



Patient interview

- The interview, an opportunity to develop connection with the patient, involves listening to and understanding the patient's chief complaint or concern about his or her oral health.

- **The chief complaint is referred to the illness as described by the patient word.**





- This can include clinical symptoms of pain, difficulty with function, concern about appearance, problems with an existing prosthesis, or any combination of symptoms related to the teeth, periodontium, jaws, or previous dental treatment. It is important to listen carefully to what the patient has stated is the reason for presenting for evaluation; this is because all subsequent information gathered will be used to discuss these concerns and to relate whether the proposed treatment will affect the patient in any way.





Failure to do so leads to the chance that the patient will be unhappy with the treatment result, as it might not see the correction for its chief complain.



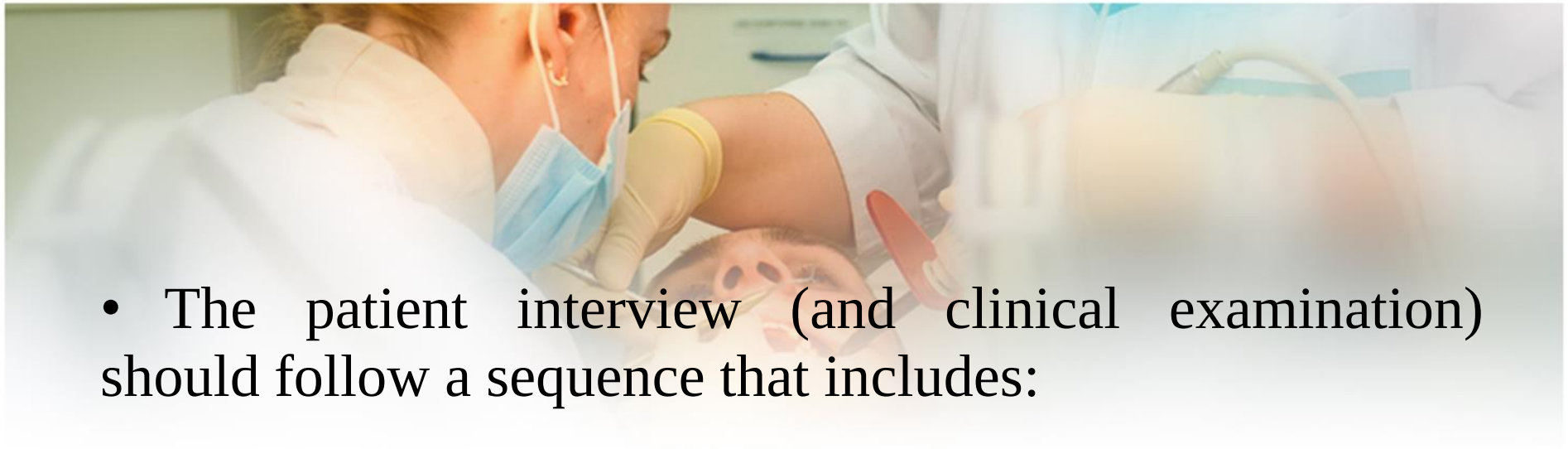

• The patient interview (and clinical examination) should follow a sequence that includes:

1. Chief complaint and its history

2. Medical history review

3. Dental history review, especially related to previous prosthetic experience(s)

4. Patient expectations



The objectives of prosthodontic treatment

1. The best method of restoring the lost function within the limits of tissue tolerance of the patient .
2. Maintain or improve on the appearance of the mouth. As the first objective is satisfied, so the 2nd requirement is comfort in an esthetically pleasing manner. (esthetically pleasing restoration)
3. The preservation and maintenance of the health of the remaining teeth and oral tissues (which will enhance the removable partial denture design).





Oral Examination

- Visual
- Digital



Sequence of oral examination

1) Reliefs of pain discomfort and caries lesion by placements of temporary fillings, preliminary examination to determine the need for management of acute needs and whether prophylaxis is required to conduct a thorough oral examination.

2) A thorough and complete oral prophylaxis .best doing prophylaxis to obtain:-

- Teeth free from accumulation of calculus and debris.
- Accurate diagnostic cast of dental arch can be done

3) Complete intraoral radiograph

4) Impression for making accurate diagnostic cast to be mounted for occlusal examination, mounting preferably on semiadjastable articulator.

5) Examination of teeth and residual ridge by instrument and visual





objectives of a radiographic examination

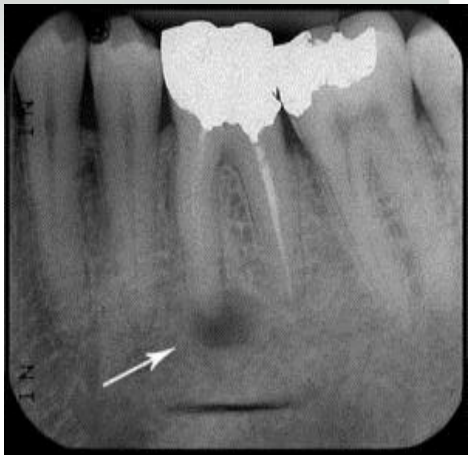

- To locate areas of infection and other pathosis.
- The presence of root fragments, foreign objects, bone spicules, and irregular ridge formations.
- presence and extent of caries and the relation of carious lesions to the pulp and periodontal attachment.
- evaluation of existing restorations as to evidence of recurrent caries, marginal leakage.
- presence of root canal fillings and to permit their evaluation.
- evaluation of periodontal conditions.
- to evaluate the alveolar support of abutment teeth, their number, the supporting length and morphology of their roots.





Visual examination will reveal many of the:-

- signs of dental disease consideration of caries susceptibility.
- examination of periodontal disease, gingival inflammation.
- The number of teeth remaining, the location of the edentulous areas, and the quality of the residual ridge.
- Tissue contours may appear to present a well-formed edentulous residual ridge.
- The presence of tori or other bony exostoses.
- During the examination, not only each arch but also its occlusal relationship with the opposing arch must be considered separately.
- Determination of height of the floor of the mouth to locate inferior borders of lingual mandibular major connectors.



- **Diagnostic cast:**
- Diagnostic casts are used to supplement the oral examination
- used to permit a topographic survey of the dental arch that is to be restored by means of a removable partial denture.
- used to permit a logical and comprehensive presentation to the patient of present and future restorative needs, as well as of the hazards of future neglect.
- Can be used in the fabrication of individual trays.
- Diagnostic casts may be used as a constant reference as the work progresses.
- Unaltered diagnostic cast should become a permanent part of the patients record.





Interpretation of Examination Data

1) **Roentgenographic interpretation:**

- Many of the reasons for roentgenographic interpretation during oral examination are outlined and are considered in greater detail in other texts.
- The quality of the alveolar support of an abutment tooth is of primary importance because the tooth will have to withstand greater stress loads when supporting a dental prosthesis.



2) Value of interpreting bone density:

- Its importance to the dentist when evaluating the quality and quantity of the alveolar bone are the height and the quality of the remaining bone structure.

- Roentgenographic evaluation of bone quality is often necessary. Optimum bone qualities are ordinarily expressed by normal sized interdental trabecular spaces.

- The normal interproximal crest is ordinarily shown by a relatively thin white line crossing from the lamina dura of one tooth to the lamina dura of the adjacent tooth.



Root morphology

- The morphologic characteristics of the roots determine to a great extent the ability of prospective abutment teeth to resist successfully additional rotational forces that may be placed on them. Teeth with multiple and divergent roots will resist stresses better than teeth with fused and conical roots, because the resultant forces are distributed through a greater number of periodontal fibers to a larger amount of supporting bone





Periodontal considerations

- An assessment of the periodontium in general and abutment teeth in particular must be made before prosthetic restoration.
- One must evaluate the condition of the gingiva, looking for adequate zones of attached gingiva and the presence or absence of pockets.
- The condition of the supporting bone must be evaluated and mobility patterns recorded
- If mucogingival involvements, osseous defects, or mobility patterns are recorded, the causes and potential treatment must be determined.
- Qral hygiene habits of the patient must be determined, and efforts made to educate the patient relative to plaque control.
- In addition, the patient must be advised of the importance of regular maintenance appointments after treatment.











Need for extraction:

- Need for extraction of teeth for the following reasons

1. If the tooth cannot restore to a state of health, extraction may be unavoidable.
2. A tooth may be removed if its absence will permit amore serviceable and less complicated partial denture design.
3. A tooth may be extracted if it is so anesthetically located as to justify its removal to improve appearance.







- **The Recommended Infection Control Practices for Dental Treatment**

1. Gloves should be worn in treating all patients.
2. Masks should be worn to protect oral and nasal mucosa from splatter of blood and saliva.
3. Eyes should be protected with some type of covering to protect from splatter of blood and saliva
4. Sterilization methods known to kill all life forms should be used on dental instruments. Sterilization equipment includes steam autoclave, dry heat oven, chemical vapor sterilizers, and chemical sterilants.
5. Attention should be given to cleanup of instruments and surfaces in the operatory. This includes scrubbing with detergent solutions and wiping down surfaces with iodine or chlorine (diluted household bleach solutions).
6. Contaminated disposable materials should be handled carefully and discarded in plastic bags to minimize human contact. Sharp items, such as needles and scalpel blades, should be contained in puncture-resistant containers before disposal in the plastic bags.





Thank you

