Oral Bacteriology

Lecture

Cariogenic Bacteria

Dr Mayyadah Hameed Rasheed
BDS, MSc, PhD
Oral Medicine

Ashur University, Dental Technologies Department

Dental caries

Dental caries is a biofilm-mediated, sugar-driven, multifactorial, and dynamic disease affecting the dental hard tissues (enamel, dentin, and cementum). It can occur throughout life and affects both primary and permanent dentitions.

The disease develops as a result of acids produced by oral microorganisms within dental plaque. When these bacteria metabolize fermentable carbohydrates—particularly sucrose—they generate organic acids that initiate repeated cycles of demineralization and remineralization at the tooth surface.

If the balance shifts in favor of demineralization over remineralization, cumulative mineral loss occurs. This process leads to the formation of carious lesions, which may progress from early enamel changes (clinically observed as a non-cavitated white spot lesion) to cavitation and eventual structural destruction of the tooth.

The primary cariogenic microorganisms include:

- Streptococcus mutans
- Lactobacillus

The Demineralization–Remineralization Cycle

Dental caries is characterized by a dynamic and potentially reversible balance between:

- Demineralization → Mineral loss
- Remineralization → Mineral gain

This cycle is influenced primarily by dietary habits and salivary function.

Demineralization Phase: Following the intake of fermentable carbohydrates, especially sucrose, cariogenic bacteria metabolize these sugars and produce organic acids, predominantly lactic acid. The accumulation of acid results in a reduction of plaque pH from its normal level (approximately 7.0) to the critical pH of about 5.5 for enamel. At this critical level, hydroxyapatite crystals begin to dissolve, leading to subsurface mineral loss.

In the early stage:

- The enamel surface remains intact.
- A white spot lesion appears as the first clinical sign.

Remineralization Phase: Remineralization occurs when salivary mechanisms restore the oral environment. Saliva contributes by:

- Clearing sugars from the oral cavity
- Providing bicarbonate ions, which act as buffering agents and raise the pH above the critical level
- Supplying calcium (Ca^{2+}), phosphate (PO_4^{3-}), and fluoride (when available)

Dental caries

Dental caries is:

- ✓ **biofilm**-mediated
- ✓ **sugar-**driven
- ✓ **multifactorial**
- ✓ **dynamic** disease
- ✓ affecting the dental **hard tissues** (enamel, dentin, and cementum)
- ✓ It can occur **throughout life**
- ✓ and affects both **primary and permanent** dentitions.

Demineralization – Remineralization Cycle

fermentable carbohydrates (sucrose)

Metabolize by:
- Streptococcus mutans
- Lactobacillus

lactic acids (PH= 5.5)

hydroxyapatite crystals

saliva

- Clearing sugars
- bicarbonate buffering
- Ca^{2+}, PO_4^{3-}, F

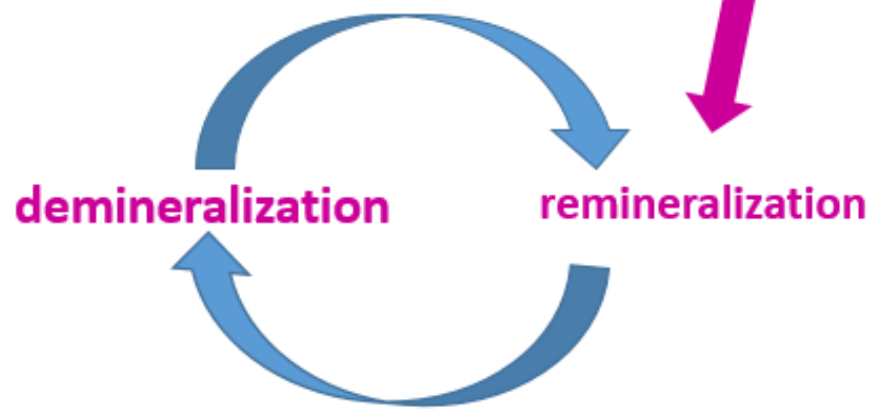

Dental caries

Demineralization Vs Remineralization

This cycle is influenced primarily by:

- ✓ dietary habits
- ✓ salivary function.

In the early stage:

- The **enamel surface** remains intact.
- A **white spot without cavitation**
- Reversible ??????

Dental caries

These components facilitate the redeposition of minerals (hydroxyapatite) into the enamel structure.
In the presence of fluoride, hydroxyapatite may convert into fluorapatite, which is more resistant to acid dissolution.
The outcomes of successful remineralization include:

- Mineral redeposition on the tooth surface
- Rehardening of early enamel lesions
- Possible reversal of white spot lesions

The Balance Between the Two Processes:

The progression or arrest of dental caries depends on the balance between these two opposing processes:

✓ If Demineralization > Remineralization → Cavitation occurs
✓ If Remineralization ≥ Demineralization → Arrested or reversed carious lesion

Factors That Disturb the Balance: Several factors may shift the balance toward demineralization, including:

1. Frequent snacking (increased frequency of sugar exposure)
2. Reduced salivary flow due to systemic disease or medication
3. Poor oral hygiene and increased plaque accumulation

Oral Bacteriology

Lecture

Gingivitis: Definition, Histology, Pathogenesis, and Stages

Dr Mayyadah Hameed Rasheed
BDS, MSc, PhD
Oral Medicine

Ashur University, Dental Technologies Department

Gingivitis; Definition

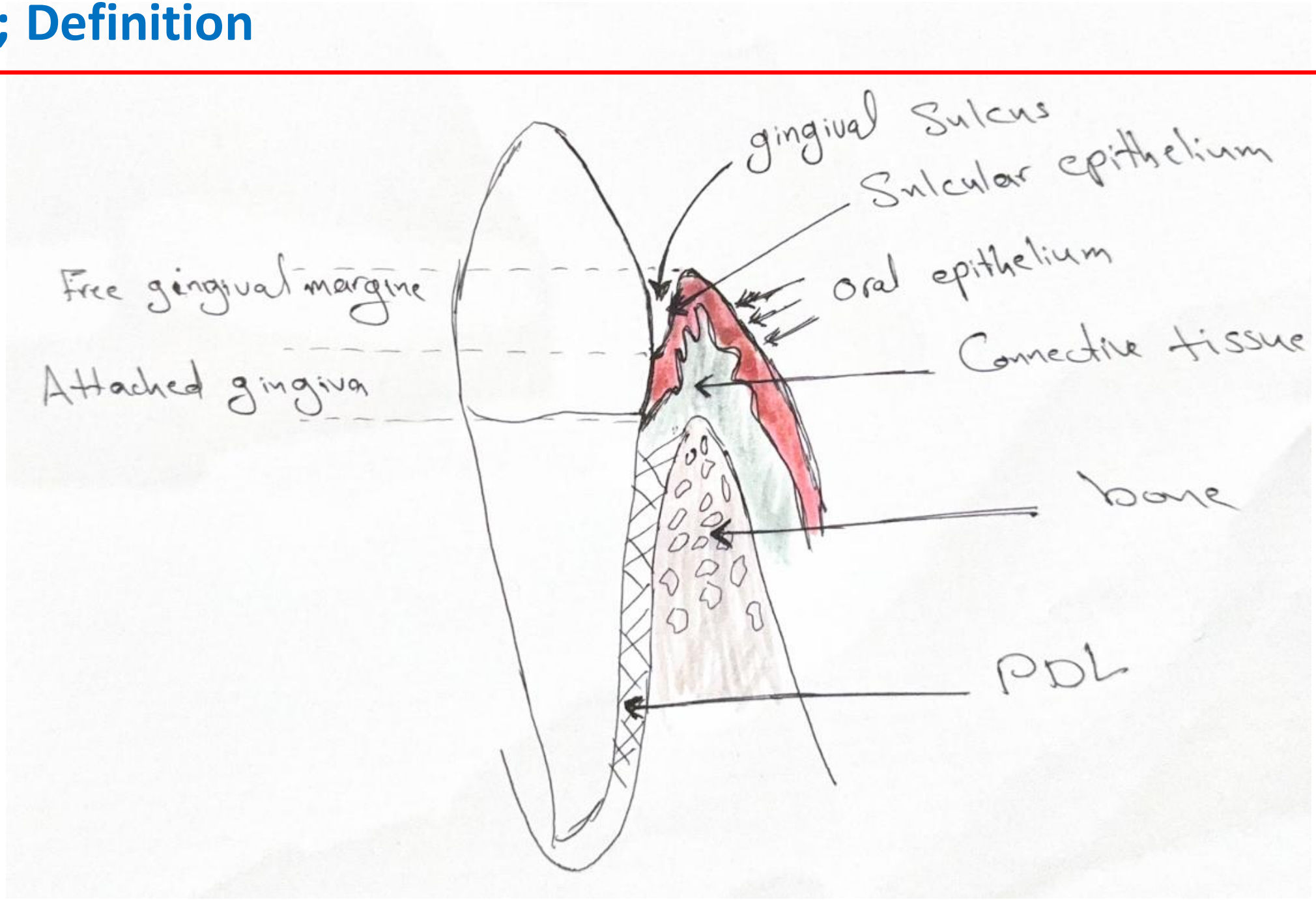

Gingivitis; Definition

Definition: Gingivitis is a biofilm-induced, reversible inflammatory condition of the gingiva characterized by clinical signs of inflammation without loss of periodontal attachment or alveolar bone.

Histo-anatomy of the Gingiva: The gingiva consists of:

1. A central connective tissue core
2. Covered by stratified squamous epithelium

Three types of epithelium are present:

a) Oral (outer) epithelium; covers the free gingival margin from outside
b) Sulcular epithelium; Lines the gingival sulcus, contains gingival crevicular fluid (GCF) which is composed mainly of Immune cells and bacterial toxins. It's permeability makes it the primary pathway for bacterial invasion into connective tissue.
c) Junctional epithelium; Attaches to the tooth surface in a collar-like manner. And plays the most critical role in the development of gingivitis.

If plaque is allowed to accumulate along the gingival margin, bacterial toxins penetrate the gingival tissues, initiating an inflammatory response. This inflammatory condition is referred to as gingivitis. Unlike dental caries (which has specific dominant pathogens such as Streptococcus mutans), gingivitis is characterized by a shift in the composition of the plaque microbiota, particularly an increase in Gram-negative anaerobic bacteria.

Risk factors for gingivitis:

a) Poor oral hygiene
b) Reduced salivary flow (xerostomia), often due to medications or mouth breathing or systemic disease.
c) Crowded or malaligned teeth
d) Hormonal changes (e.g., puberty, pregnancy)
e) Diet and smoking

Gingivitis; Definition

- ✓ is a **biofilm**-induced
- ✓ **Reversible**
- ✓ **inflammatory** condition of the gingiva
- ✓ characterized by clinical signs of inflammation
- ✓ **without** loss of periodontal attachment or alveolar bone.

Plaque → gingival margin → bacterial toxins → initiating an inflammatory response.

Gram-negative anaerobic bacteria.

Gingivitis; Definition

Risk factors for gingivitis:

a) Poor oral hygiene

b) Reduced salivary flow (xerostomia), often due to medications or mouth breathing or systemic disease.

c) Crowded or malaligned teeth

d) Hormonal changes (e.g., puberty, pregnancy)

e) Diet and smoking

Gingivitis

Stages of Gingivitis:

1. Initial lesion (Subclinical stage)
2. Early lesion
3. Established lesion
4. Advanced lesion

- ✓ **Stage 1:** Initial Lesion (Subclinical Stage), bacterial toxins penetrate through the junctional epithelium, leads to activation of immune cells (mast cells and neutrophils), which cause release of inflammatory mediators like Histamine. In this stage although inflammation starts, clinically no visible signs. And this stage is reversible.
- ✓ **Stage 2: Early Lesion**; greater inflammatory cell infiltration like neutrophils. Neutrophils release cytotoxic enzymes that destroy bacteria but also damage gingival tissue. At this stage slight gingival swelling and redness and bleeding on brushing. This stage remains reversible with proper oral hygiene.
- ✓ **Stage 3: Established Lesion:** further tissue destruction and junctional epithelium transforms into a pocket epithelium, and spontaneous gingival bleeding occurs. This stage is still reversible if plaque control is restored.
- ✓ **Stage 4: Advanced Lesion;** This stage represents the transition from gingivitis to periodontitis and involves:

a) Periodontal ligament destruction
b) Alveolar bone loss

Unlike the previous stages, this phase may lead to irreversible periodontal breakdown.

Stages of Gingivitis:

Stage 1: Initial Lesion:

- ✓ (Subclinical Stage)
- ✓ bacterial **toxins penetrate** through the junctional epithelium
- ✓ leads to **activation of immune cells** (mast cells and neutrophils)
- ✓ which cause release of **inflammatory mediators** like **Histamine**.
- ✓ In this stage although inflammation starts, clinically **no visible signs**.
- ✓ And this stage is **reversible.**

Gingivitis

Stage 2: Early Lesion;

- ✓ ↑ **neutrophils**
- ✓ **cytotoxic enzymes** → destroy bacteria
  → damage gingival tissue
- ✓ slight gingival **swelling**
- ✓ **Redness**
- ✓ bleeding **on brushing.**
- ✓ **reversible** with proper oral hygiene.

Gingivitis

✓Stage 3: Established Lesion:

- ✓ **further** tissue destruction
- ✓junctional epithelium → **pocket**
- ✓**spontaneous** gingival bleeding
- ✓still **reversible**.

Gingivitis

Stage 4: Advanced Lesion;

- ✓ gingivitis → **periodontitis**

a) Periodontal ligament destruction

b) Alveolar bone loss

- ✓ **irreversible**

periodontitis, periodontal abscess and periodontal pocket

- ✓ **Periodontitis** is a chronic inflammatory oral disease. Gingivitis (red, swollen gums that bleed) if not treated will progress to periodontitis, where the inflammation begins to destroy the periodontal ligament and alveolar bone causing tooth mobility.

- ✓ **A periodontal pocket** is a pathologically deepened gingival sulcus (more than 3 mm) resulting from the apical migration of the junctional epithelium and destruction of the supporting periodontal tissues, including the periodontal ligament and alveolar bone. It is a characteristic clinical feature of periodontitis and provides a favorable environment for the accumulation of dental plaque and pathogenic bacteria

- ✓ **A periodontal abscess** is a localized accumulation of pus within the periodontal tissues caused by bacterial infection, leading to destruction of the periodontal ligament and alveolar bone and usually associated with a pre-existing periodontal pocket. Clinical Features include (1): Localized pain and swelling, (2) Red and tender gingiva, (3) Pus discharge on probing, (4) Tooth mobility, (5) Bad taste or halitosis

periodontal abscess