Do You Know



1.How many bones in human body



2.How many bones in human skull



3.How many movable bone in the skull



Skull and Cranial Bones

Dr Mayyadah Hameed Rasheed
BDS, MSc, PhD
Oral Medicine

Ashur University, Dental Technologies Department

Definition

- ✓ **Anatomy is defined as:** The scientific study of the structure of living organisms, providing a detailed understanding of the body's internal and external components, their relationships, and their functions.

Common Anatomical Terms

1. Anterior (Ventral): Towards the front of the body
2. Posterior (Dorsal): Towards the back of the body
3. Superior (Cranial): Towards the head or upper part
4. Inferior (Caudal): Towards the lower part
5. Medial: Towards the midline of the body (e.g., the nose is medial).
6. Lateral: Away from the midline of the body
7. Proximal: Nearer to the point of attachment
8. Distal: Farther from the point of attachment
9. Superficial: Closer to the body's surface (e.g., skin).
10. Deep: Further from the body's surface

Anatomic position

The anatomical position is the standard reference position of the human body:

- ✓ Standing upright
- ✓ Head and eyes facing forward
- ✓ Arms at the sides
- ✓ Palms facing forward
- ✓ Feet flat and pointing forward



Body Planes

2. Coronal or frontal

Planes: These planes are imaginary **vertical** planes at **right angle** to the sagittal plane, divides the body into **anterior (ventral)** and **posterior (dorsal)** parts

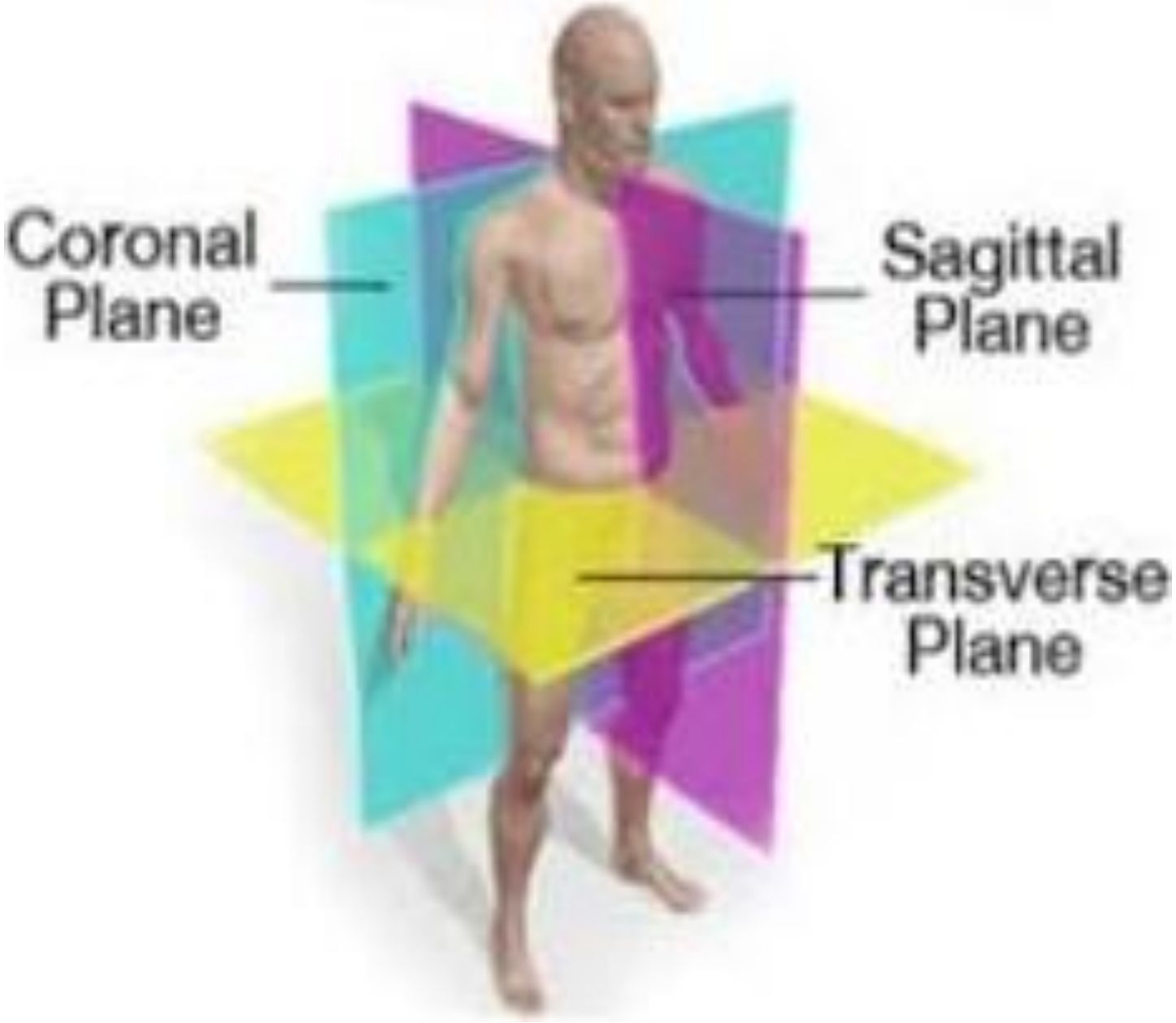

Body Planes

3. **Horizontal, or Transverse, Planes:** These planes are at **right angles** to both the sagital and the coronal planes, dividing the body into **superior** and **inferior** parts

Human Skeleton

- ✓ The human skeleton(هيكل عظمي) is a structural framework composed of **206 bones** in an adult, providing support, protection, and facilitating movement. It is divided into two main parts:

1. **axial skeleton (محوري):** forms the axis of the body, consists of:
2. skull
3. vertebral column
4. ribs
5. sternum

} thoracic cage

Human Skeleton

2. **the appendicular skeleton:** consists of 2 upper limbs (arms) and 2 lower limbs (legs) and shoulder girdle and pelvic girdle. The shoulder girdle connect upper limb to the axial skeleton, and pelvic girdles connect the lower limbs to the axial skeleton

Introduction to Head and Neck Anatomy

- ✓ **The head and neck region** contains many vital structures, including bones, muscles, nerves, blood vessels, and organs related to mastication, speech, facial expression, and respiration.
- ✓ **The skull** is a complex bony structure forming the skeleton of the head.

Function of the skull

- ✓ Housing and protection of the brain
- ✓ Support for facial structures
- ✓ Formation of the oral, orbital and nasal cavities
- ✓ Attachment for muscles of mastication and facial expression

The Skull

- ✓ The skull is a complex bony structure composed of 22 bones,

  these bones can be divided into 2 groups:

1. **cranium**: they are **8** bones forming a protective case around the brain.
2. **facial bones**: they are **14** bones, which supporting the face, support the teeth, and form cavities for the sense organs (eyes, nose, and mouth).

The Skull

(8 bones)

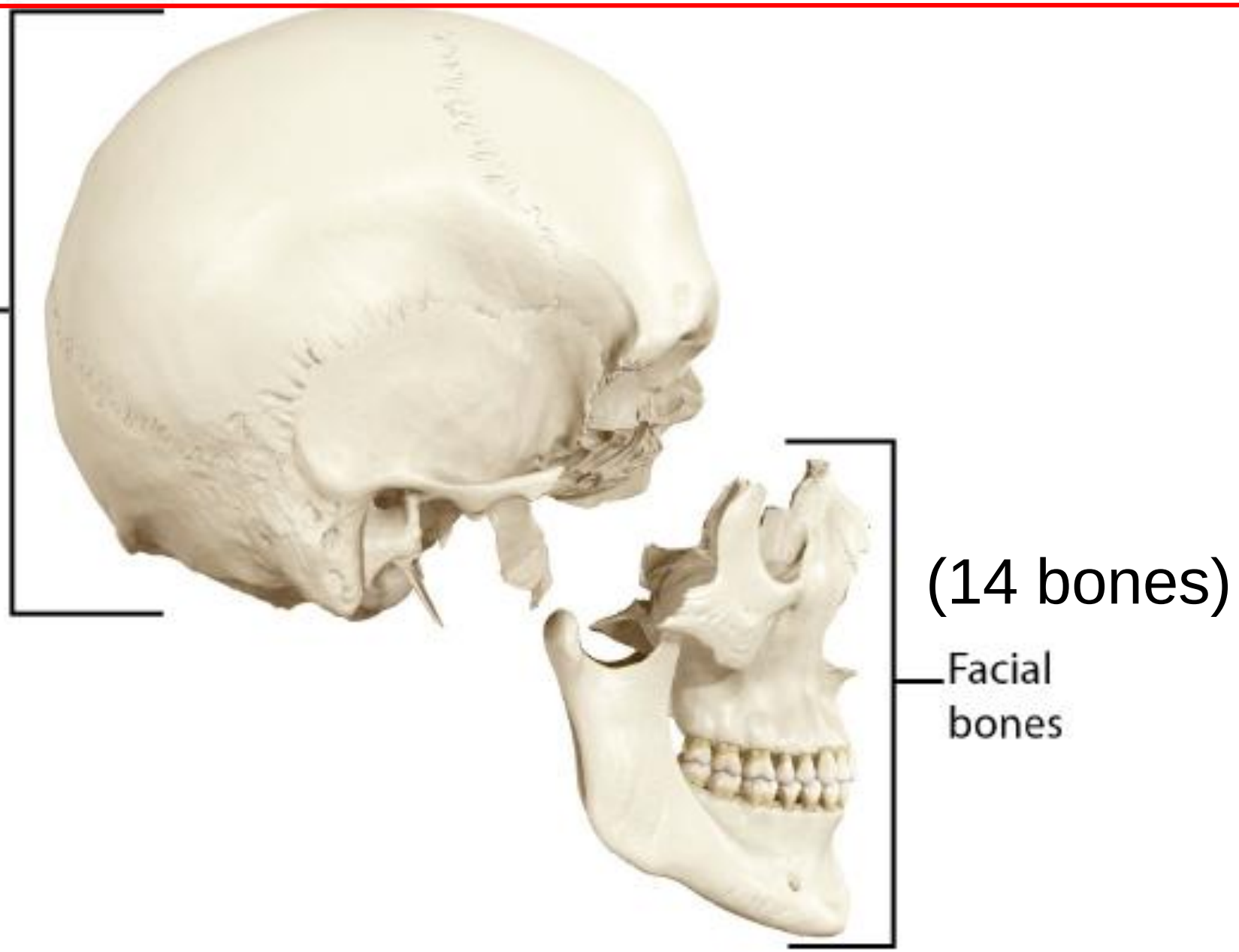

(14 bones)

Cranial Bones

The cranial bones forming a case encloses the brain. The cranium consists of 8 bones, two of which are paired:

- frontal bone: 1
- **parietal bones: 2**
- occipital bone: 1
- **temporal bones: 2**
- sphenoid bone: 1
- ethmoid bone: 1

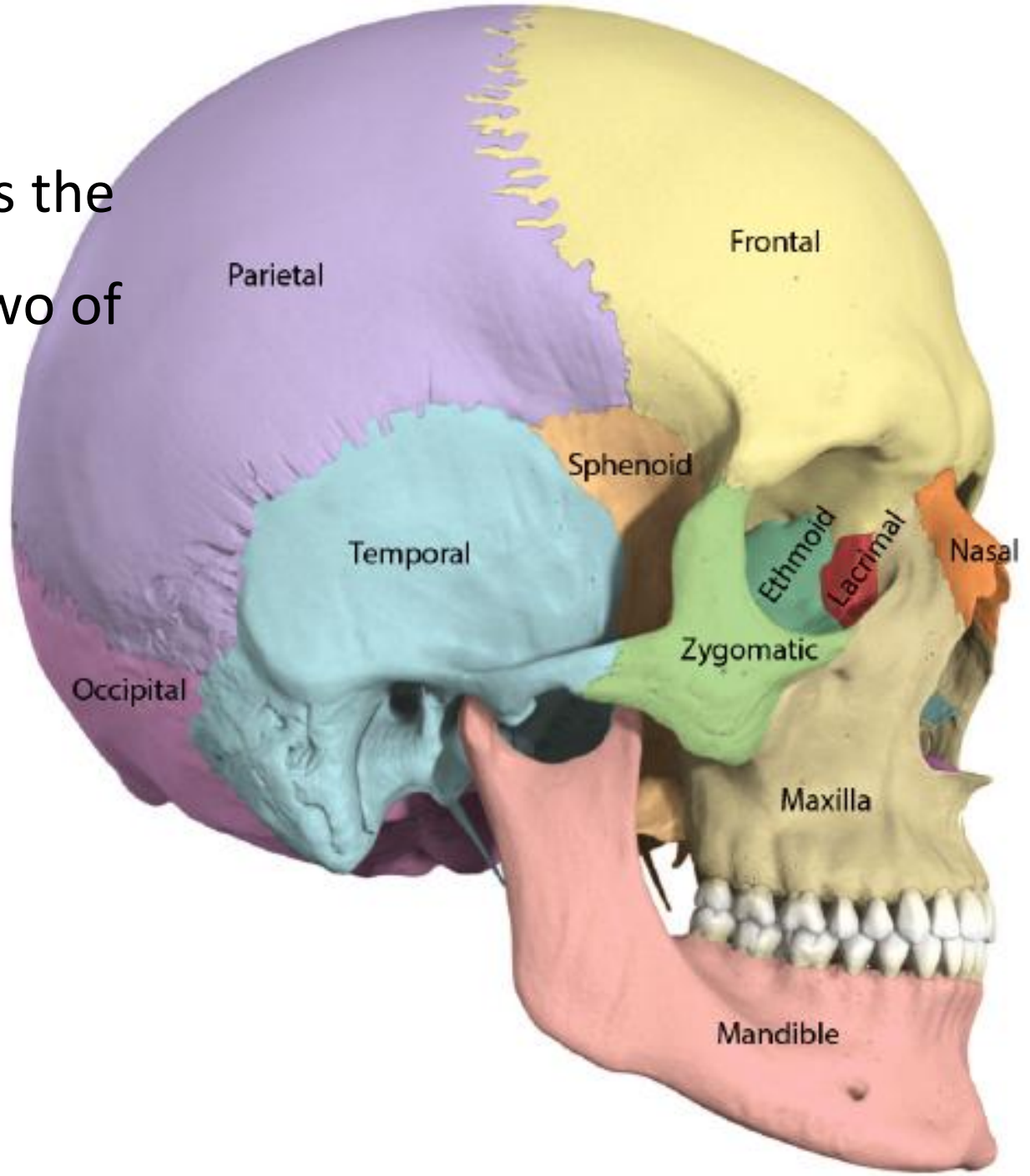

Frontal Bone

The frontal bone is shell-shaped bone, forms the main part of the forehead and the anterior portion of the cranium it consists of two parts:

1. Vertical part: it called squamous part of frontal bone, which forms the main part of forehead
2. Horizontal part: it also called orbital part which form the roof of the orbits.

Within the frontal bone, just above the orbital margins, are two hollow spaces lined with mucous membrane called the frontal air sinuses. These communicate with the nose and serve as voice resonators.

Articulation of the frontal bone:

- ✓Medially : articulates with frontal process of the maxilla and with nasal bone.
- ✓Laterally : articulates with frontal process of the zygomatic bone.
- ✓Posteriorly : articulates with two **parietal bones** by **coronal suture**.

Occipital Bone

- The occipital bone is a cranial bone located at the back and base of the skull. It plays a crucial role in protecting the brain. **Foramen Magnum** is a large opening through which the inferior part of the brain connects with the spinal cord. **Occipital condyles** are rounded projections on either side of the foramen magnum that articulate with the **first cervical vertebra (atlas),** enabling head nodding. Anteriorly, lambdoid Suture, connects the occipital bone to the 2 parietal bones.

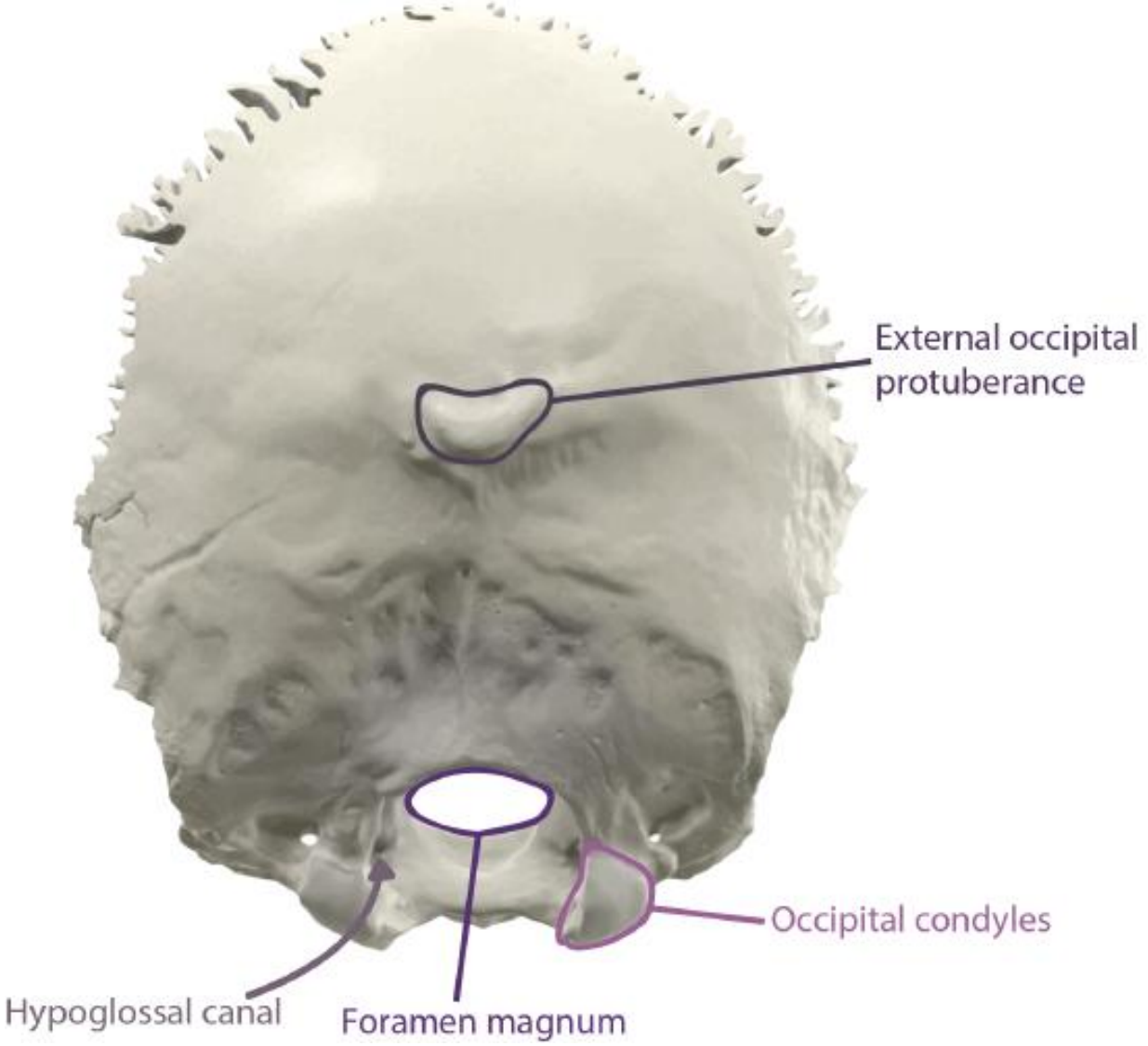

Parietal Bone

The two large parietal bones are curved, rectangular bones that form most of the superior and lateral aspects of the skull; they form the bulk of the cranial vault.

Articulation of the Parietal bones:

- ✓ medially : articulates with each other at sagittal suture.
- ✓ anteriorly : articulates with frontal bone by coronal suture.
- ✓ posteriorly : articulates with occipital bone by lambdoid suture.
- ✓ laterally: articulates with temporal bone by squamous suture

Temporal Bone

مهم

- ✓ The temporal bone is a paired cranial bone located on the sides and base of the skull, contributes to the: (1) formation of the cranial cavity, (2) housing structures of the ear, (3) and providing attachment points for muscles involved in chewing (muscles of mastication). (4) Mandibular fossa is a depression in the temporal bone that articulates with the mandible to form the temporomandibular joint (TMJ). (5) The bone contains the mastoid process, which is filled with air cells and serves as an attachment for neck muscles. (6) And a styloid process which is a slender, pointed projection that serves as an attachment for muscles and ligaments of the tongue and throat.

Sphenoid Bone

The sphenoid bone is a complex, butterfly-shaped bone located in the middle cranial fossa at the skull's base, behind the frontal bone and in front of the occipital bone. The sphenoid forms a central wedge that articulates with all other cranial bones, and acting as a keystone connecting the cranium skeleton and facial skeleton, providing structural support, and forming parts of the eye sockets and cranial floor. It houses the pituitary gland in the sella turcica. On its upper surface, presents a saddle-shaped depression houses the pituitary gland.

It consists of a central body and three pairs of processes:

greater wings

lesser wings

pterygoid processes:

(a) Medial pterygoid plate

(b)Lateral pterygoid plate

Contains sphenoidal sinuses that lighten the skull and add resonance. Forms the base, sides, and floor of the middle cranial fossa.

Contributes to the posterior and floor of the orbit (eye socket).

Ethmoidal Bone

The ethmoid bone is a small, delicate bone located at the base of the skull, between the eyes (forming the medial walls of the orbits).

The **cribriform plate** is a horizontal, perforated plate that forms the roof of the nasal cavity and part of the anterior cranial base, it contains tiny openings for the passage of olfactory nerves (cranial nerve I), enabling the sense of smell. while the vertical plate which extending downward from the cribriform plate forms the posterior third of the nasal septum, dividing the nasal cavity into left and right halves.

Skull Superior View

Viewed from above, only four skull bones are visible. These four bones make up the skull roof. :

1. Frontal
2. right parietal, left parietal
3. occipital.

Sutures

Sutures are immovable joints found between the bones of the skull. They are composed of dense fibrous connective tissue and play a critical role in connecting the skull bones during development and growth. Over time, sutures ossify (fuse), becoming more rigid in adulthood:

- ✓ **coronal suture:** between the frontal bone and the two parietal bones.
- ✓ **sagittal suture:** between the two parietal bones.
- ✓ **lambdoid suture:** between the occipital bone and the two parietal bones.
- ✓ **squamous suture:** between the parietal bone and the temporal bone.

The paranasal sinuses

Paranasal sinuses are air-filled cavities located within certain bones of the skull. They are lined with mucous membrane and communicate with the nasal cavity.

Functions of the Paranasal Sinuses:

a) Reduce the weight of the skull
b) support voice resonance
c) Warm and humidify inhaled air

These paired sinuses are named for the bones they occupy: the frontal, maxillary, ethmoid, and sphenoid.