O. Pathology

Lecture

Developmental Defects of the Oral Mucosa

Dr Mayyadah Hameed Rasheed
BDS, MSc, PhD
Oral Medicine

Ashur University, Dental Technologies Department

Developmental Defects of the Oral and Maxillofacial Region

- ✓ The formation of the **face and oral cavity** is **complex** in nature and involves the development of **multiple tissue processes** that must **merge and fuse** in a highly orchestrated fashion. Disturbances in the growth of these tissue processes or their fusion may result in the formation of different orofacial clefts.

Cleft lip and/ or Palate

- **Cleft lip** is caused by a failure of the normal orofacial development during embryonic life. It is the **most common facial deformity**. Cleft lip can occur **unilateral or bilateral**, **alone** or associated **with cleft palate**.

Cleft lip and/ or Palate

- ✓ **Majority are idiopathic**; however, a number of drugs during pregnancy have been implicated, including steroids, and diazepam.

Cleft lip and/ or Palate

- ✓ **Cleft palate** can occur as: (1) bifid uvula, (2) soft palate only, (3) soft hard and soft palate
- ✓ Cleft lip with cleft palate presents problems with feeding, speech, and hearing
- ✓ Corrective surgery is recommended

Macrostomia and Microstomia

- **Macrostomia:** Incomplete lateral merging of maxillary and mandibular processes.
- **Microstomia:** Too much fusion of mandibular and maxillary prominances may result in small mouth

Fordyce Granules

- ✓asymptomatic yellowish- white granular lesions on the buccal mucosa and lips
- ✓ectopic collection of sebaceous glands in the cheek mucosa and lips
- ✓cannot be rubbed off
- ✓no treatment is necessary

Developmental Defects of the Tongue

Dr Mayyadah Hameed Rasheed
BDS, MSc, PhD
Oral Medicine

Ashur University, Dental Technologies Department

Development of the Tongue

- ✓ the tongue is a **muscular** structure as well as a **sensory** organ that starts developing around **week 4** of intrauterine life
- ✓ a fully developed tongue consists of two parts the **anterior two-thirds** and **posterior one-third** which is called the root of the tongue they are separated from each other by a shallow v-shaped groove known as the **terminal sulcus**, the two parts develop separately which results in them having different nerve supplies.

Development of the Tongue

- ✓ the **anterior two-thirds develops from the first pharyngeal arch** and the **posterior one-third develops from the second, third and fourth pharyngeal arches**
- ✓ the anterior two-third starts developing when the mesoderm of the 1st pharyngeal arch proliferates giving rise to a midline swelling called the **tuberculum impar**, then the mesoderm of the same arch gives rise to two more bulges just lateral and above the tuberculum impar, these lateral lingual swellings enlarge overlap the tuberculum impair and merge with each other along the midline giving rise to the **mucosa over the anterior two-thirds of the tongue**

Development of the Tongue

- ✓ the area where the two lateral lingual swellings merge develops into a fibrous septum which appears as the midline groove over the surface of the tongue known as the median sulcus

Tongue Anomalies

- ✓ **Hairy tongue** is characterized by marked **elongation of the filiform papillae** of the dorsal tongue due to an **increase in keratin production** or a **decrease in normal keratin desquamation** (hyperpara keratosis), and the cause is uncertain
- ✓ The elongated papillae are usually **brown, yellow, or black** as a result of growth of **pigment-producing bacteria** or **staining from tobacco and food.**

Tongue Anomalies

- ✓ **Hairy tongue**
- ✓ The condition is typically **asymptomatic**, although occasionally patients complain of a **gagging** sensation or a **bad taste** in the mouth.
- ✓ It is a **benign** condition, but the major concern is often the **aesthetic** appearance of the tongue along with possible associated bad breath, so needs **periodic scraping** or brushing with a toothbrush or tongue scraper can **promote desquamation of the hyperkeratotic papillae** and surface debris

Tongue Anomalies

- ✓ **Hairy leukoplakia:** typically occurs on the **lateral border** of the tongue and caused by the **Epstein-Barr virus** and is usually associated with human immunodeficiency virus **(HIV)** infection or other immunosuppressive conditions.

Tongue Anomalies

- ✓ **Geographic tongue:** This common **benign** condition usually affects the tongue, producing an appearance likened to a map of the world on the dorsum, the cause is **unknown**
- ✓ Clinically, there are **irregular, smooth, red** areas on the dorsal tongue, several of these areas often **coalesce** to form a **scalloped or geographic** pattern. These areas are caused by **loss of filiform papillae**
- ✓ These areas extends for a few days before healing, only to appear again in another area. And this **migratory pattern** over a period of weeks confirms the diagnosis.
- ✓ The condition is asymptomatic and needs no treatment

Oral Pathology

Lecture

Developmental disturbances of teeth

Dr Mayyadah Hameed Rasheed
BDS, MSc, PhD
Oral Medicine

Ashur University, College of Dentistry

Developmental Disturbances of Teeth

Causes of developmental disturbances

1. **Genetic:** Inherited or gene mutation
2. **Environmental causes:**
   a) infection
   b) trauma
   c) radiation
   d) hormonal disturbances
   e) nutritional deficiencies
   f) hypoxia
   g) miscellaneous

Nutrition and tooth development

✓**Minerals**: calcium, phosphorus are needed to properly form the hydroxyapatite crystals (minerals), and their levels in the blood are maintained by **Vitamin D**. In situations where calcium, phosphorus, and vitamin D are deficient, the hard structures of a tooth may be less mineralized.

Fluoride is incorporated into the hydroxyapatite crystal of a developing tooth and makes it more resistant to demineralization and decay. Fluoride deficiency causes increased demineralization when the tooth is exposed to an acidic environment. Furthermore, an excess of fluoride while a tooth is in development can lead to a condition known as fluorosis

✓**Vitamin A:** is necessary for the tooth development

✓**Vitamin C** is necessary for the tooth development

Classifications of developmental disturbances of teeth

1. **Size:** Microdontia (small teeth), Macrodontia(large teeth)
2. **Shape**: Gemination , Dilaceration, Dens in dent
3. **Number:** Anodontia, Hypodontia, Hyperdontia
4. **Structures:** Amelogenesis imperfecta, Dentinogenesis imperfecta

Size: Microdontia

Generalized: involves all the teeth, may be caused by: **Down's syndrome**, **chemotherapeutic and radiation** treatment during tooth development

Localized microdontia: one tooth is affected, normally the upper lateral incisor **(Peg lateral)** or a **third molar.**

Shape: Gemination

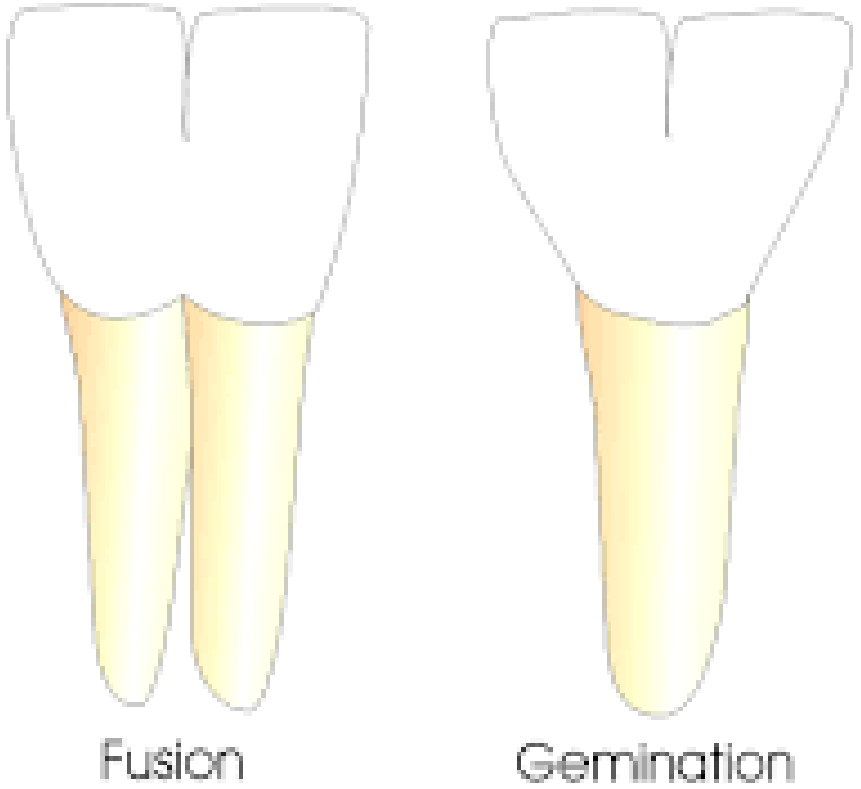





- ✓ **Tooth fusion**: Union between the enamel or both dentin and enamel of two or more separate developing tooth buds
- ✓ **Gemination:** is an attempt of a single tooth bud to divide.

3-Number: Hypodontia

(**Congenital** missing tooth or teeth): It is **one of the most common** developmental abnormalities. The absence of **third molars** is very common, followed in prevalence by the **second premolar** and **lateral incisor.**