Pre-Test

The Most Common Dye in Histology is ……..

Introduction

Dr Mayyadah Hameed Rasheed
BDS, MSc, PhD
Oral Medicine

Ashur University, Dental Technologies Department

Definition

Oral pathology: A branch of Dentistry and Pathology

- ✓ identification
- ✓ Diagnosis
- ✓ Management

} oral and maxillofacial regions

It involves the study of:

- ✓ Causes
- ✓ Processes
- ✓ effects of these diseases.

Slide Preparation

To prepare oral tissues for microscopic examination, there are several methods to choose from, depending on the **type of analysis required**. The most common methods:

- ✓ **Embedding specimens in paraffin** and sectioning them (4-10 µm in thickness) is the most common method for preparing soft tissue for histological examination.

- ✓ **Fresh frozen** soft sections: the specimen of soft tissue may be frozen and sectioned with out following the same procedures above because that will destroy the tissue. This technique allows a **stained slide to be examined within 10** minutes of taking the specimen

Slide Preparation

- ✓ **Decalcified sections** (removal of mineral structure):

  Specimens containing bone and teeth need to be **softened** by decalcifying in **acid** so they can be processed using standard paraffin embedding techniques for routine microscopy.

- ✓ **A ground** (undecalcified) sections: is prepared by sawing and grinding to make a paper thin slice. To examine the original, mineralized bone structure

Slide Preparation

Why tissue specimen should be prepared ???

Steps of Slide Preparation

1. Obtaining the specimen: specimen taken from human or animal must be removed carefully.
2. **Fixation:** To preserve the tissue and prevent autolysis by bacteria. The tissue should be placed immediately in about 400 mm of 10% neutral formalin.
3. **Dehydration:** removal of water from tissue since it is not miscible with paraffin wax. By placement of tissue in in increasing % of alcohol (40%,60%,80%,100%)
4. **Clearing:** Since alcohol is not miscible with paraffin wax, alcohol is replaced by xylene. Xylene is miscible with paraffin wax
5. **Embedding:** the specimen is completely embedded in the center of a block of paraffin wax.
6. **Section cutting** of the specimen: by microtome knife into 4-10 µm thickness. Then pick up the tissue section on a glass slide
7. **Staining the sections**: staining depend on the kind of tissue, stain used for routine microscope study is hematoxylin & eosin.
8. **Mounting the cut sections on slides**: a drop of mounting medium is added to the slide and a cover slip is placed on it.

Types of microscopy

- ✓ a microscope is an optical instrument which is used in the laboratory for examining the small objects which we can't see in the naked eye
- ✓ microscopes are mainly classified into simple microscope (consists of a single lens) and compound microscope (consists of more than one lens)

Light microscope is classified into four categories:

- Bright field microscope: (specimen appears as dark against the bright background)
- dark field microscope: (The specimen appears as bright against a dark background)
- phase contrast microscope: (to distinguish unpigmented living cells from water)
- fluorescent microscope: (specimen is stained with fluorescent dyes and then exposed to ultraviolet rays)

Electron microscope is classified into three categories:

- scanning microscope
- transmission microscope
- confocal microscope

Types of microscopy

Single Cell Organism (*Tetrahymena*) observed with:

Bright Field

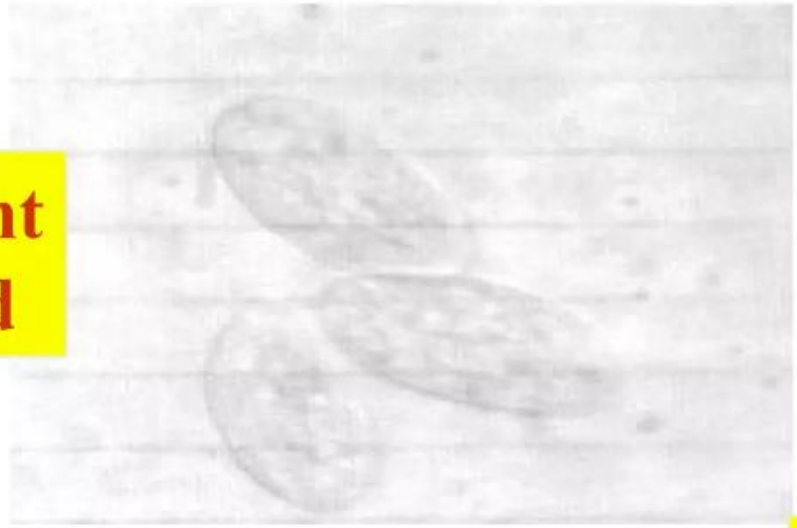

Dark Field

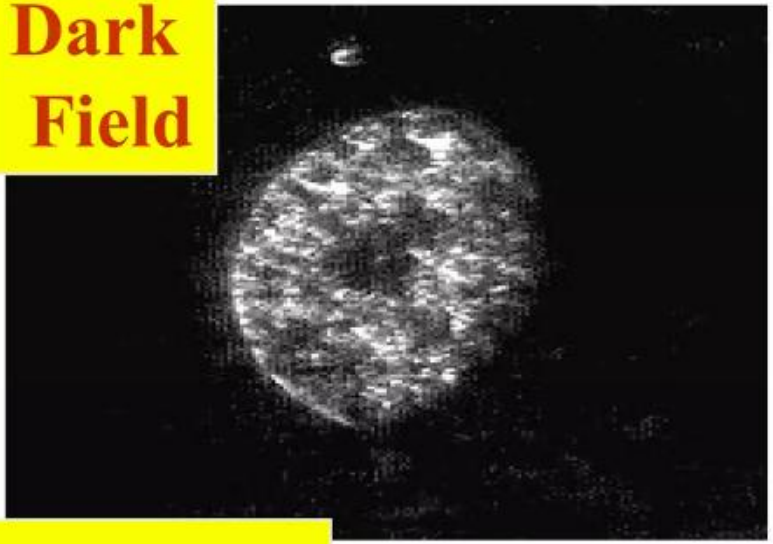

Phase Contrast

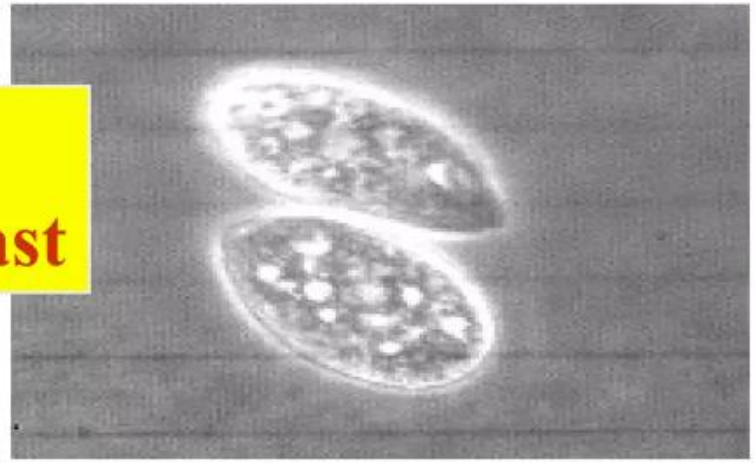

Fluorescence

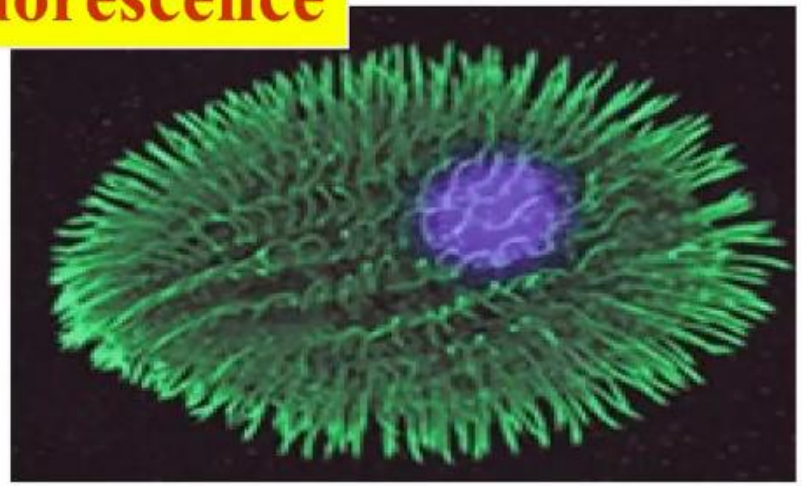

Biopsy

Biopsy: is the removal and examination of a part or the whole of a lesion.

Types of biopsy:

1. Surgical biopsy: may be incisional or excisional. Incisional biopsy is the removal of part of the lesion for diagnosis only. In excisional biopsy, the whole lesion is removed, and then usually performed to confirm the clinical diagnosis.
   Surgical biopsy has many types:
   - Fixed specimen for routine diagnosis
   - Frozen sections for rapid diagnosis
   - Fresh tissue for immunofluorescence, microbiological culture or molecular analysis
2. Fine needle aspiration biopsy: Removing very small numbers of cells or fluid by aspiration using a fine needle, the sample is processed for diagnosis
3. Wide needle/core biopsy: Needle up to 2 mm diameter is used to remove a core of tissue which is larger than in fine needle biopsy, then processed for diagnosis
4. Brush biopsy and exfoliative cytology: it is limited to the surface cells provide no information on deeper tissue

Brush biopsy and exfoliative cytology





Oral brush biopsy procedure using tooth brush. A.Using moderate pressure, the tooth brush is brushed in one direction over the entire lesion multiple times. B. The material from the brush is spread on the two thirds of a clean, dried glass slide

Biopsy

✓ **Technique:**

1. Anesthesia and incision done around the site of the lesion .
2. Biobsy provide tissue lesion and 2mm around from normal tissue .
3. Fix the tissue immediately in 10% formalin .

✓ **Indication of biopsy**:

1. Any lesion persist for more than 2 week .
2. Any inflammatory lesion that not respond to local treatment .
3. Persist hyperkeratotic changes .
4. Any lesion that has the characteristic of malignancy .