Embryology

Lab 7

Development Of Palate And Tongue And Their Anomalies

Dr Mayyadah Hameed Rasheed
BDS, MSc, PhD
Oral Medicine

Dr Fatma Adnan Abdulkareem
BDS, MSc, PhD
Oral Medicine

Ashur University, College of Dentistry

Tongue Development (Mucous Membrane)



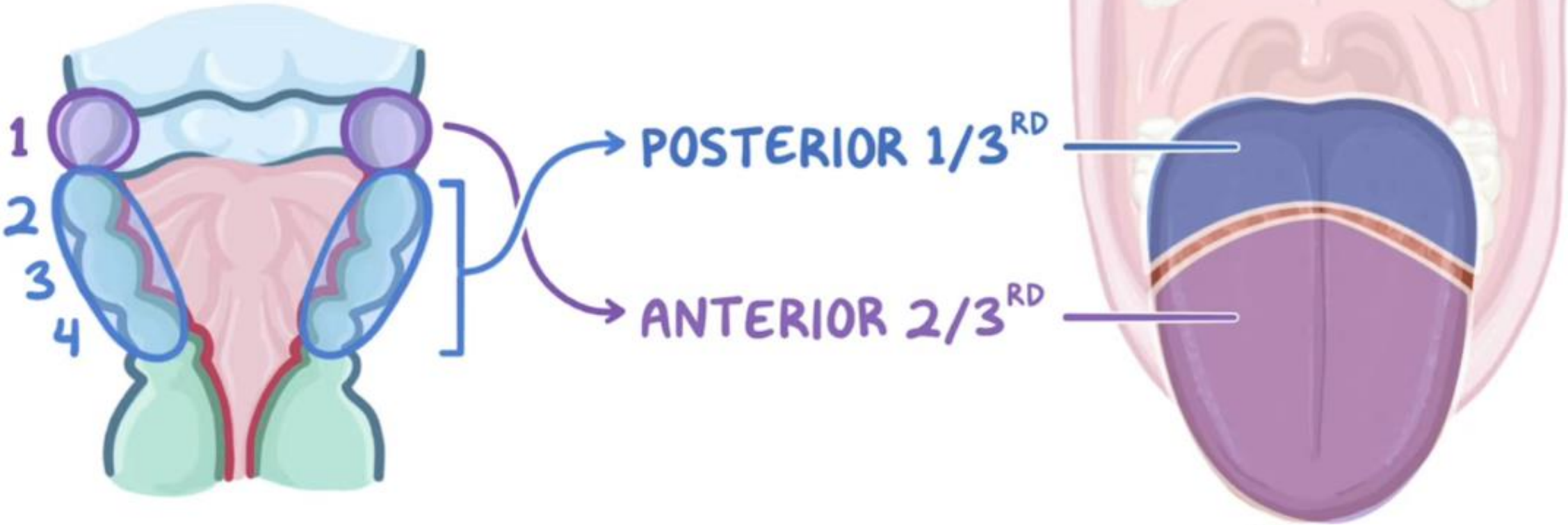

Tongue Development (Mucous Membrane)

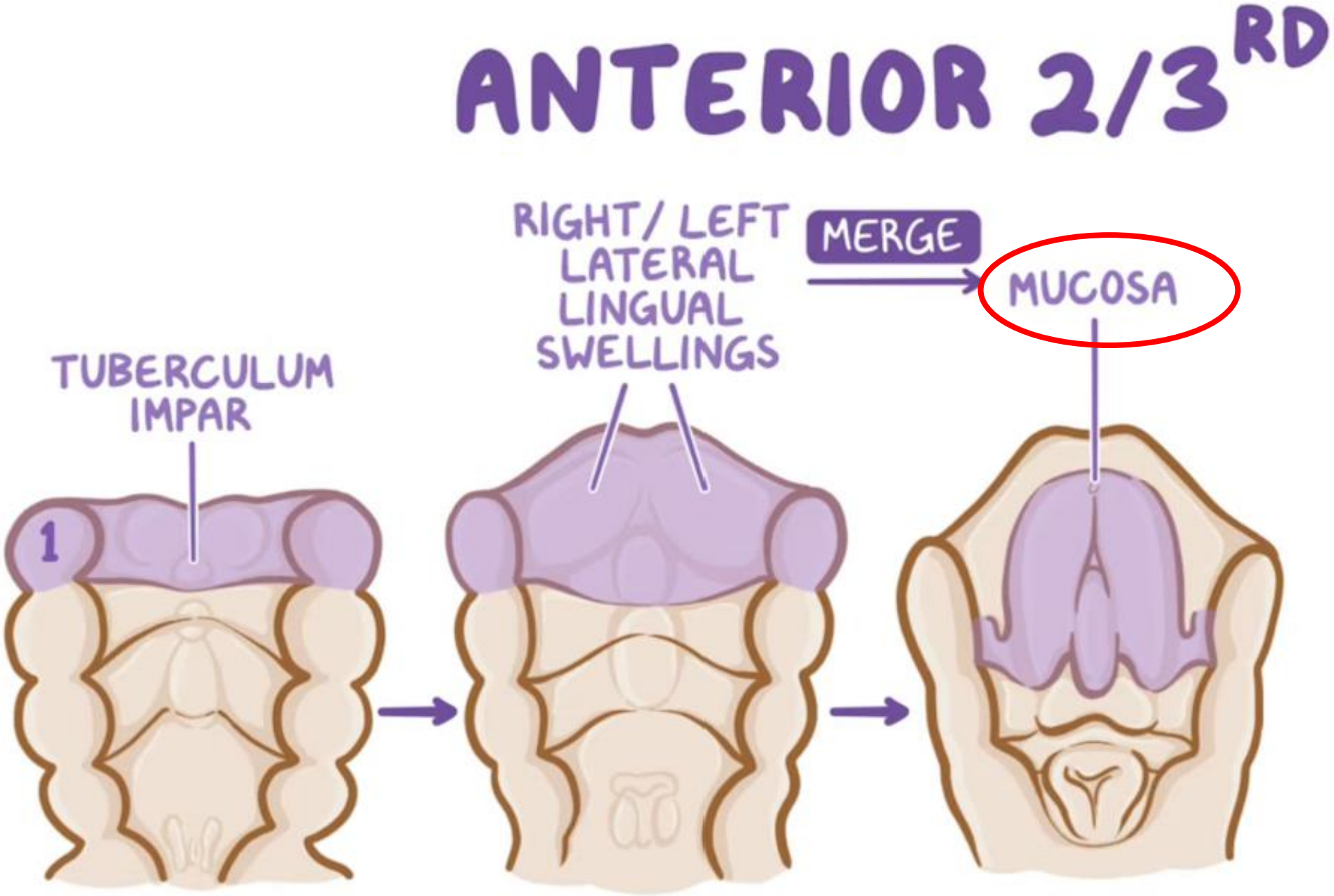

Tongue Development (Mucous Membrane)

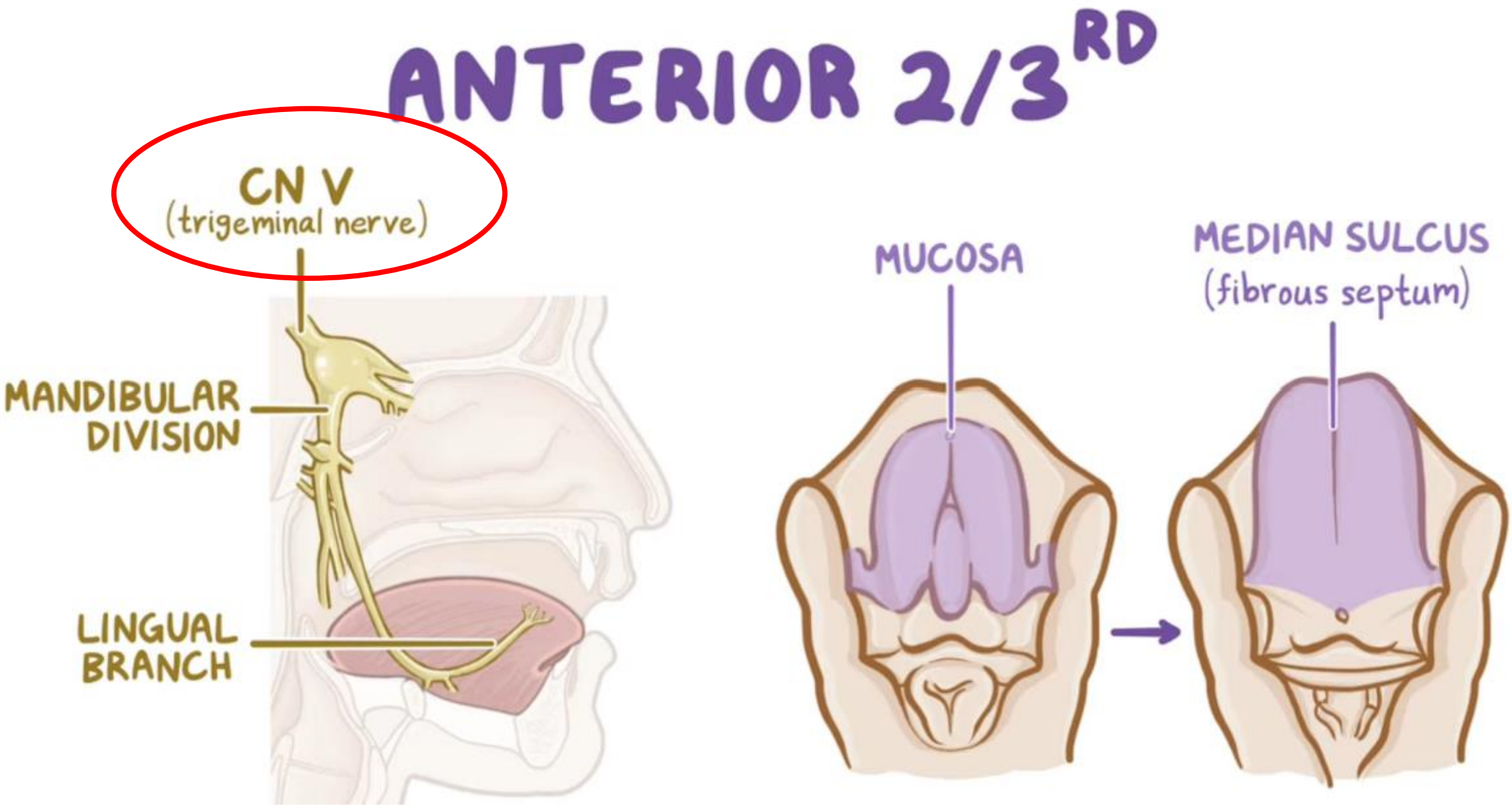

Posterior most part (epiglottis)

CN IX
(glossopharyngeal nerve)

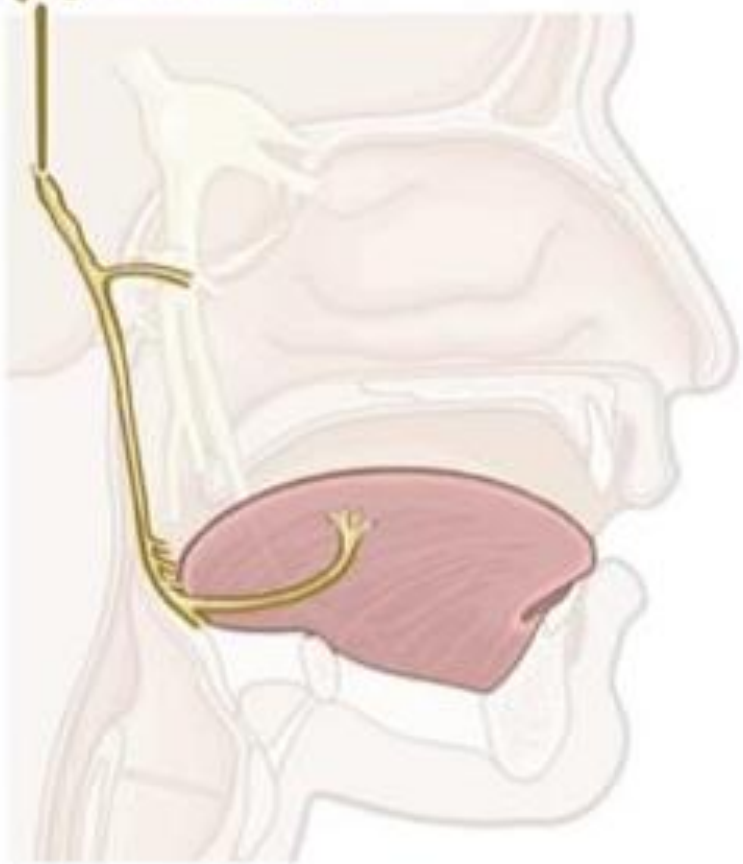

CN X - vagus nerve
(via internal laryngeal nerve)

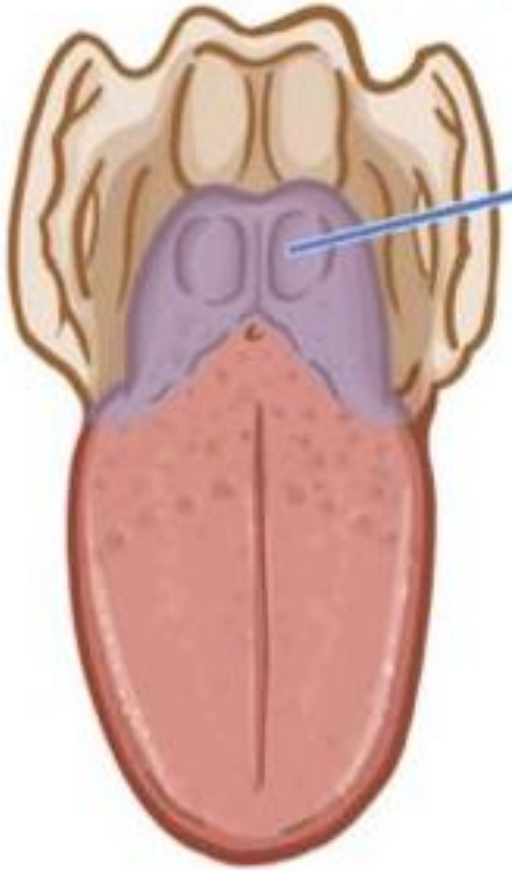

4th pharyngeal arch

Tongue Anomalies

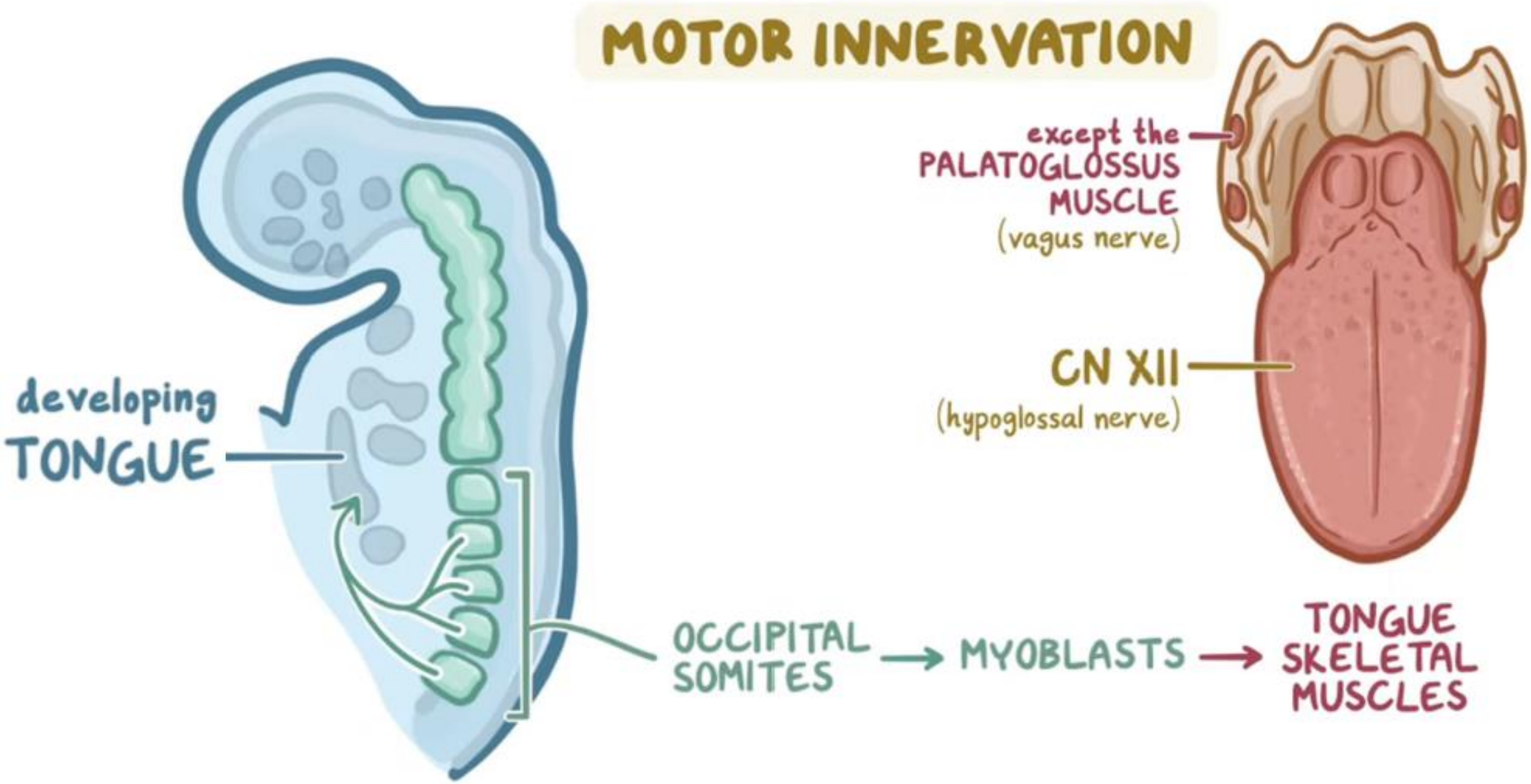

Development of the Tongue (Muscles)

Motor X CN

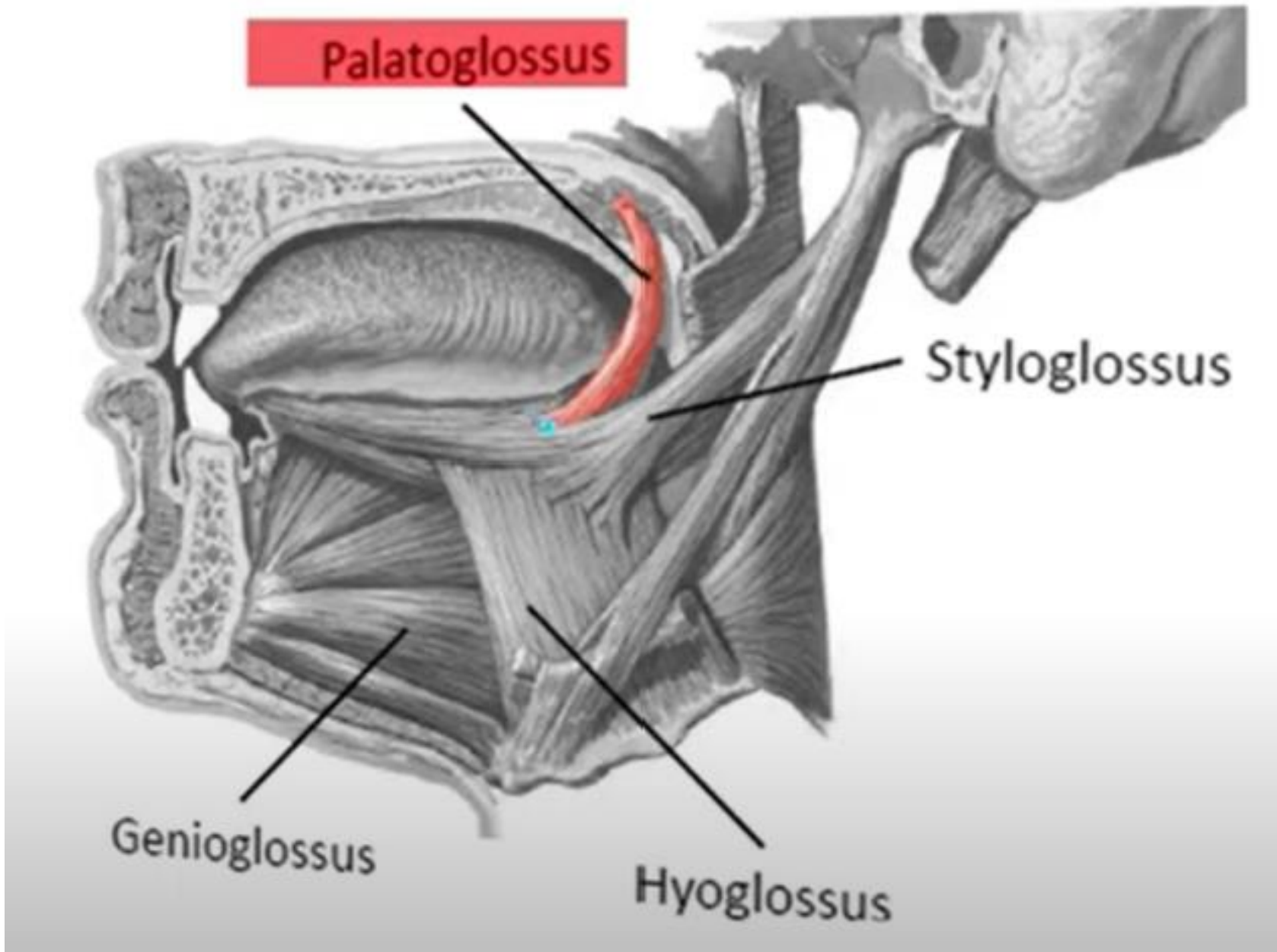

The Tongue

INNERVATION

MOTOR

Palatoglossus
VAGUS NERVE
CN 10

All other muscles
HYPOGLOSSAL NERVE
CN 12

SENSORY

Internal Laryngeal nerve
VAGUS NERVE
CN 10

Glossopharyngeal nerve
SENSORY & TASTE TO POSTERIOR 1/3RD
CN 9

Lingual nerve
SENSORY TO ANTERIOR 2/3RD
CN 5

Chorda Tympani
TASTE TO ANTERIOR 2/3RD
CN 7

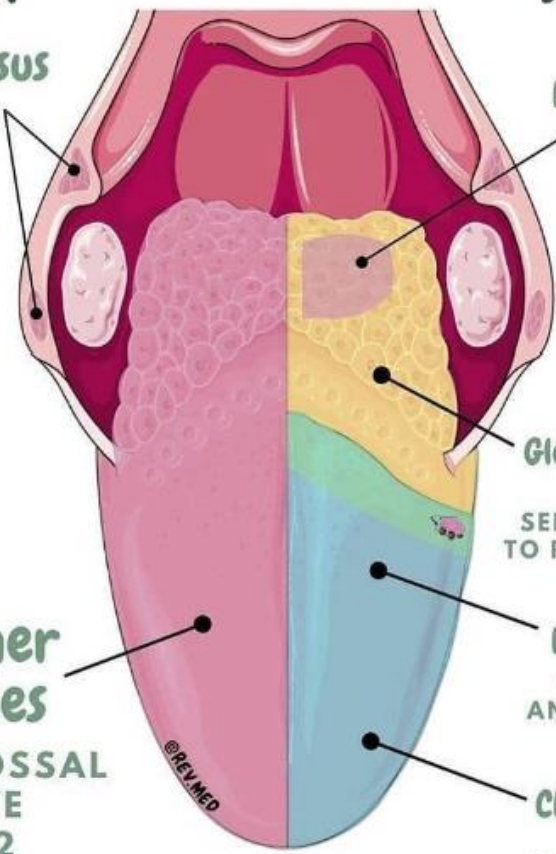

REV Med

Tongue Anomalies

Some of the various morphological variations that may occur during the development of tongue are:

- ✓ **Aglossia:** Congenital absence of the tongue is extremely rare. Usually, the tongue is absent in cases of gross underdevelopment or maldevelopment of the **1st pharyngeal arches**.



Tongue Anomalies

- ✓ **Microglossia**: It is an uncommon developmental condition and is also known as **hypoglossia**. Its defining feature is a rudimentary or an abnormally small tongue. It leads to limited muscular movement



Tongue Anomalies

- ✓ **Macroglossia:** tongues is larger than typical. Rare and can be linked to conditions such as **Down syndrome (trisomy 21).**

30 weeks gestation





2nd day of life

Tongue Anomalies

- ✓ **Ankyloglossia:** or tongue tie is a developmental abnormality characterized by a short lingual frenum or a **frenum** attachment at or near the tongue tip, resulting in restricted tongue movement. The clinical examination often reveals the presence of a heart-shaped tongue on protrusion or the inability of the tongue to touch or protrude beyond the vermillion border.





Tongue Anomalies

Cleft Tongue:

- ✓ **Complete cleft tongue** occurs due to **lack of merging** **of the lateral lingual swellings**.
- ✓ **Partial cleft tongue** is more common, occurs due to **incomplete merging** and failure of groove obliteration by underlying mesenchymal proliferation. And manifested as deep groove in the midline of dorsal surface of the tongue where food debris and microorganisms collect in the base of the cleft and causes irritation





Tongue Anomalies

Lingual Thyroid: is an abnormal mass of **ectopic thyroid** tissue seen in base of tongue caused by **failure in descendence** of thyroid tissue to its normal position during embryogenesis.

