Embryology

Lecture 7

Development Of Palate And Tongue And Their Anomalies

Dr Mayyadah Hameed Rasheed
BDS, MSc, PhD
Oral Medicine

Dr Fatma Adnan Abdulkareem
BDS, MSc, PhD
Oral Medicine

Ashur University, College of Dentistry

Development of the Tongue

- ✓ the tongue is a **muscular** structure as well as a **sensory** organ that starts developing around week **4** of intrauterine life
- ✓ a fully developed tongue consists of two parts the **anterior two-thirds** and **posterior one-third** which is called the root of the tongue they are separated from each other by a shallow v-shaped groove known as the **terminal sulcus**, the two parts develop separately which results in them having different nerve supplies.
- ✓ the **anterior two-thirds develops from the first pharyngeal arch** and the **posterior one-third develops from the second, third and fourth pharyngeal arches,** the anterior two-third starts developing when the mesoderm of the 1st pharyngeal arch proliferates giving rise to a **midline swelling** called the tuberculum impar, then the mesoderm of the same arch gives rise to two more bulges just lateral and above the tuberculum impar, these lateral lingual swellings enlarge overlap the tuberculum impair and merge with each other along the midline giving rise to the **mucosa over the anterior two-thirds of the tongue**
- ✓ since the mucosa overlying this area (anterior two third) of the tongue has its origin from the first pharyngeal arch it receives its sensory innervation from the lingual branch of the mandibular division of the fifth cranial nerve **(the trigeminal nerve)**
- ✓ the area where the two lateral lingual swellings merge develops into a fibrous septum which appears as the midline groove over the surface of the tongue known as the median sulcus

Tongue Development (Mucous Membrane)



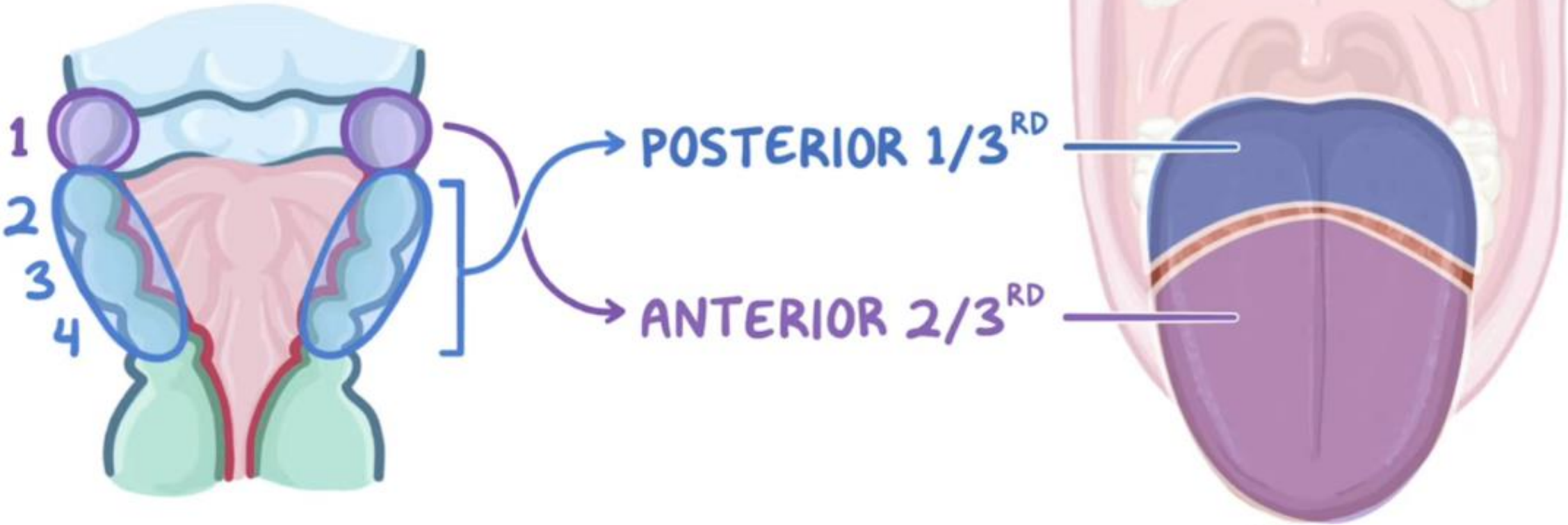

Tongue Development (Mucous Membrane)

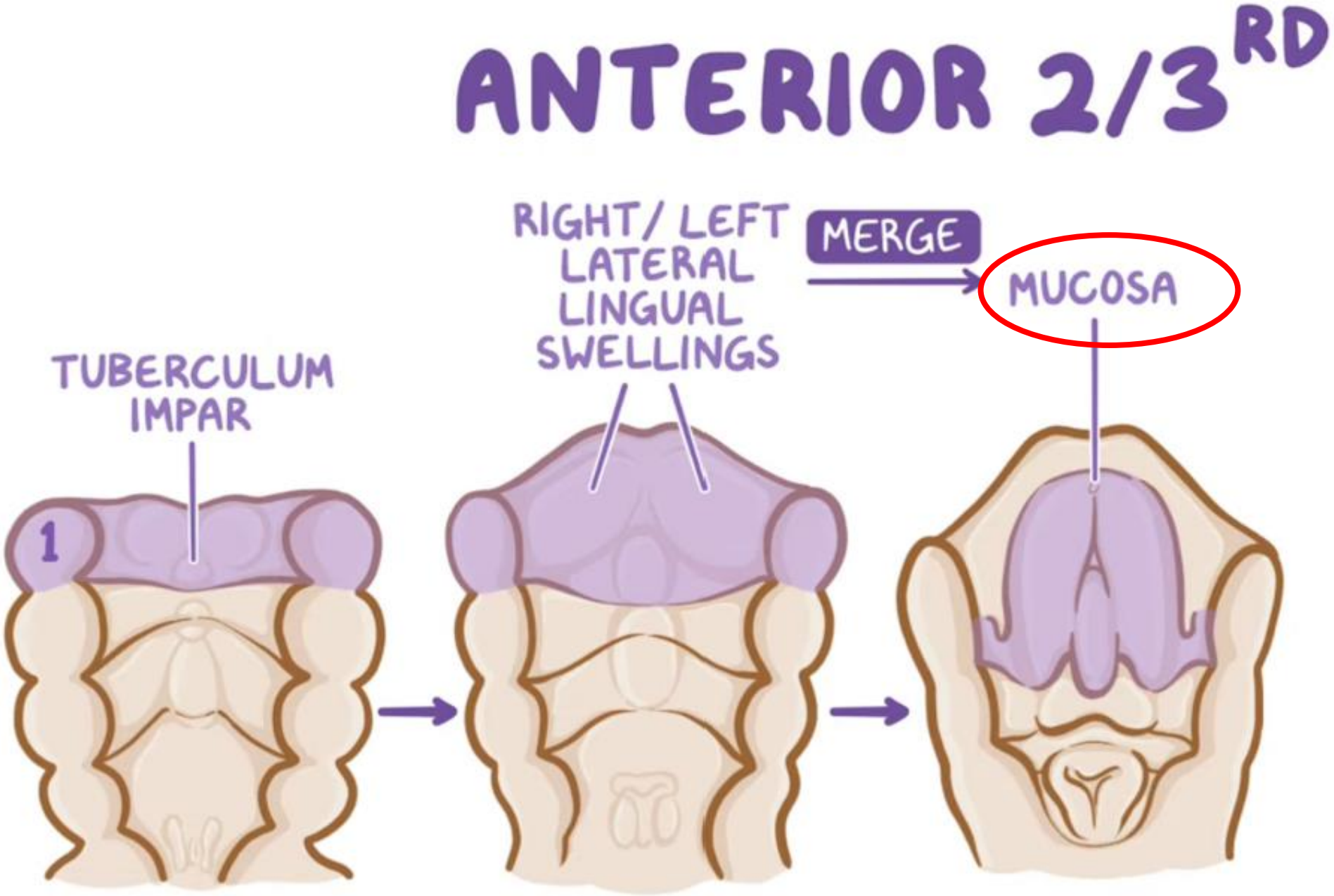

Tongue Development (Mucous Membrane)

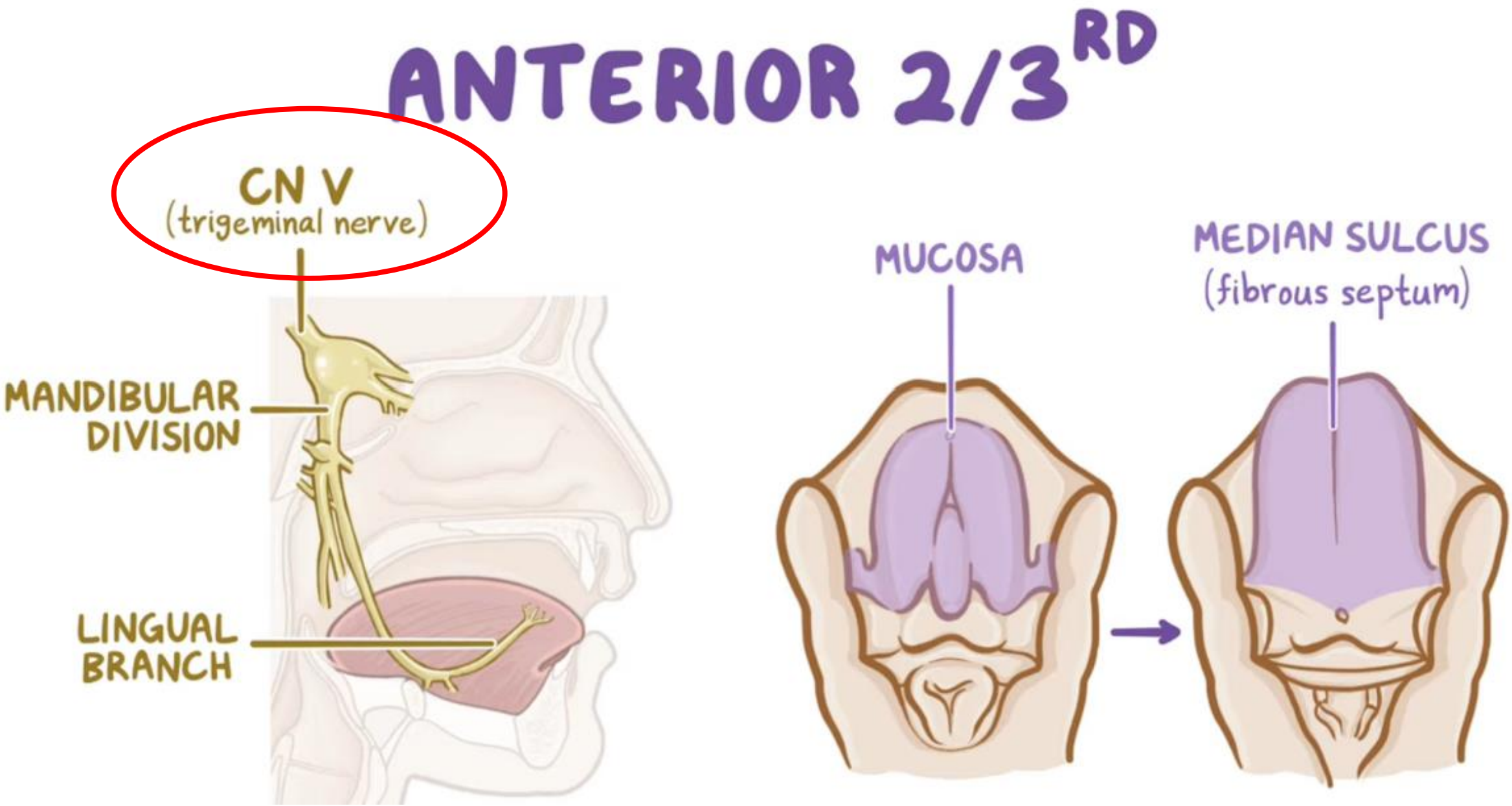

Mandibular nerve V3:

✓ Anterior:

- deep temporal
- lateral pterygoid
- Masseteric
- Buccal

✓ Posterior:

- Auriculotemporal
- Lingual
- Inferior alveolar
- Mylohyoid
- mental

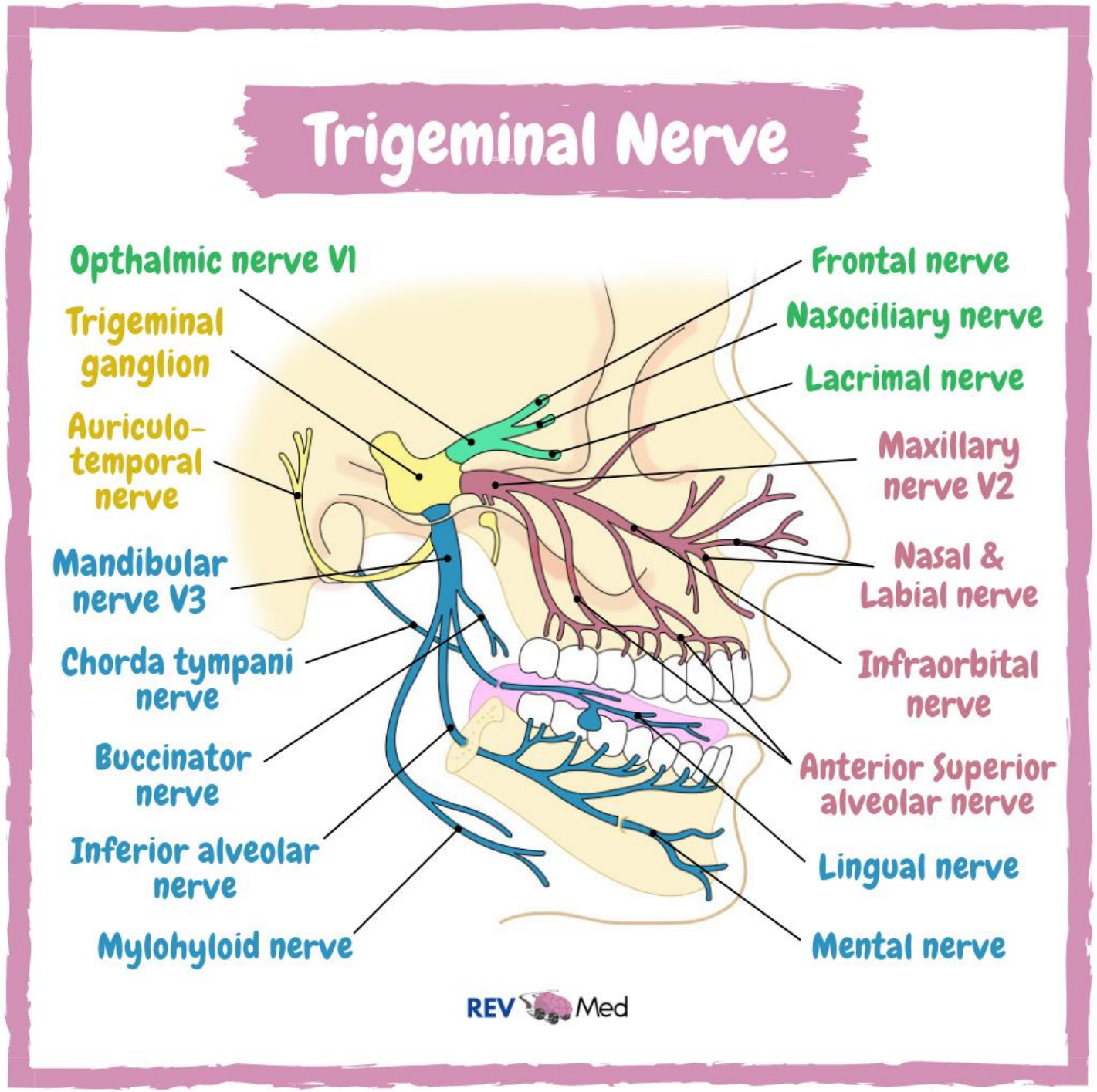

Development of the Tongue (Mucous Membrane)

- ✓ Similarly the posterior one-third of the tongue also begins to develop around week four as two mesodermal swellings.
- ✓ (Note: a swelling known as the **copula** develops in the midline of the **second and third pharyngeal arches**, which is not present in the adult tongue), the first swelling known as **hypobranchial eminence** grows from the midline of the **third and fourth** pharyngeal arches. the hypobranchial eminence begins to grow upwards and along the way it grows over the copula, the hypobranchial eminence then goes on to become the **mucosa over the posterior one-third** of the tongue which grows upwards and fuses with the anterior portion forming the complete tongue. the mucosa overlying this area of the tongue receives its sensory innervation from the **ninth cranial nerve** (the glossopharyngeal nerve)
- ✓ the posterior most part of the tongue (epiglottis) develops from a second median swelling arising from the fourth pharyngeal arch this area of the tongue receives its innervation from the tenth cranial nerve (the vagus nerve)
- ✓ The region between anterior two-third and posterior one-third contains a v-shaped depression called the terminal sulcus at the tip of the terminal sulcus the epithelium descends downwards and develops into the thyroid gland. the descent of the endoderm creates a tiny sac-like structure called foramen cecum
- ✓ (the whole tongue develops from 3 median swellings and 2 lateral swellings)

Tongue Anomalies (Mucous Membrane)

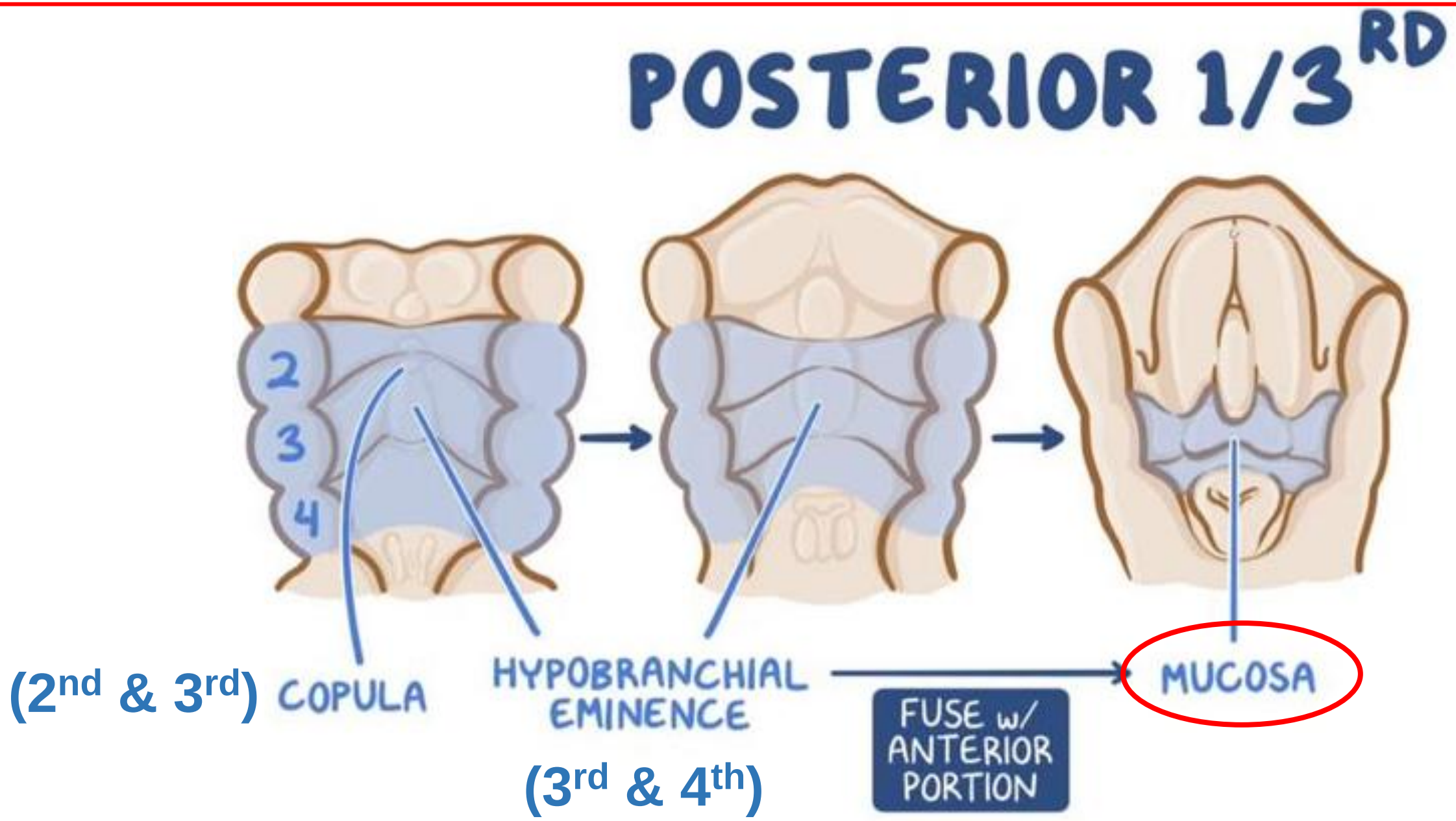

Tongue Anomalies (Mucous Membrane)

POSTERIOR 1/3RD

CN IX
(glossopharyngeal nerve)



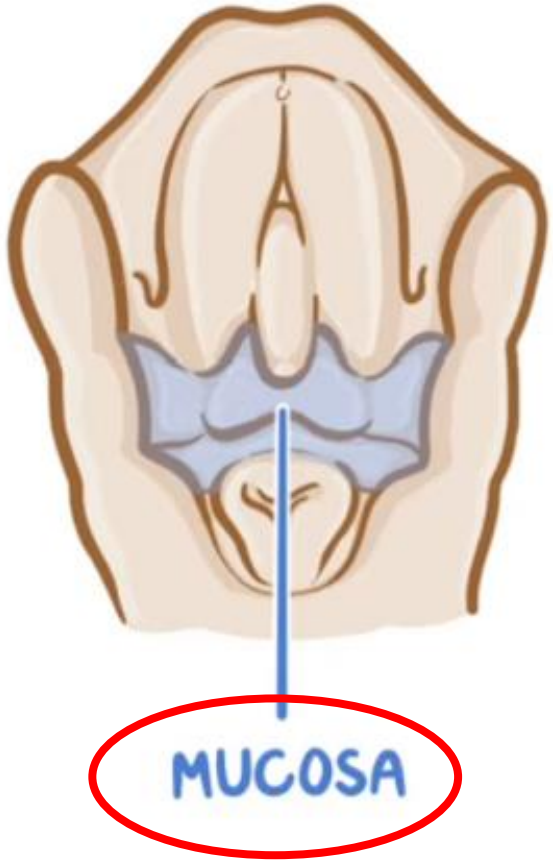

Tongue Development (Mucous Membrane)

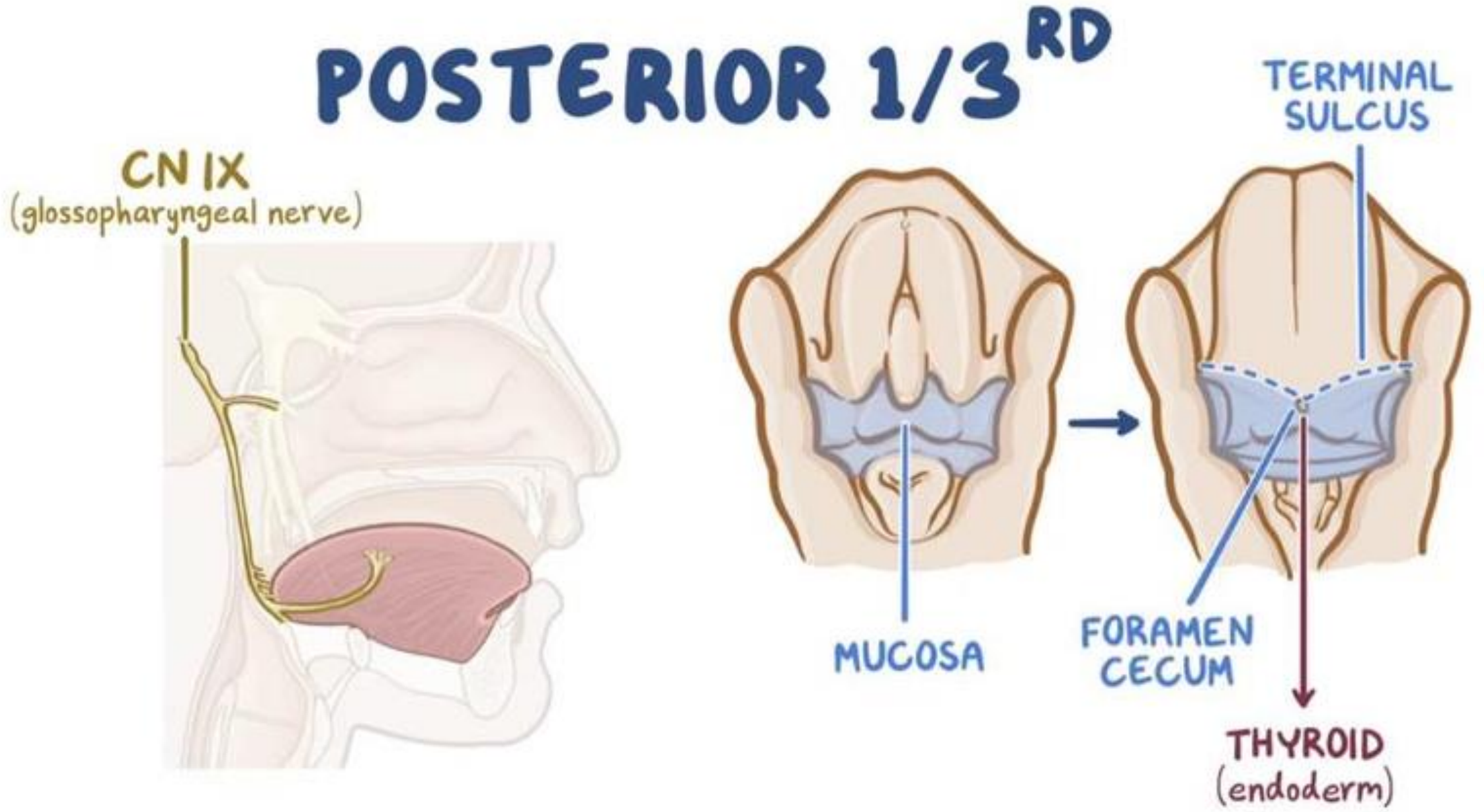

Posterior most part (epiglottis)

CN IX
(glossopharyngeal nerve)

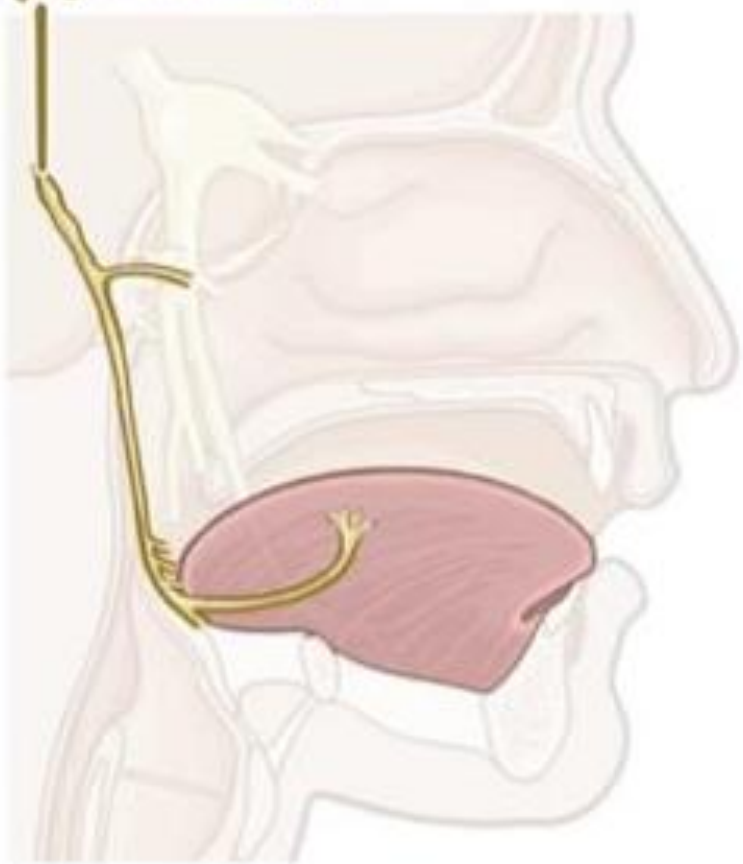

CN X - vagus nerve
(via internal laryngeal nerve)

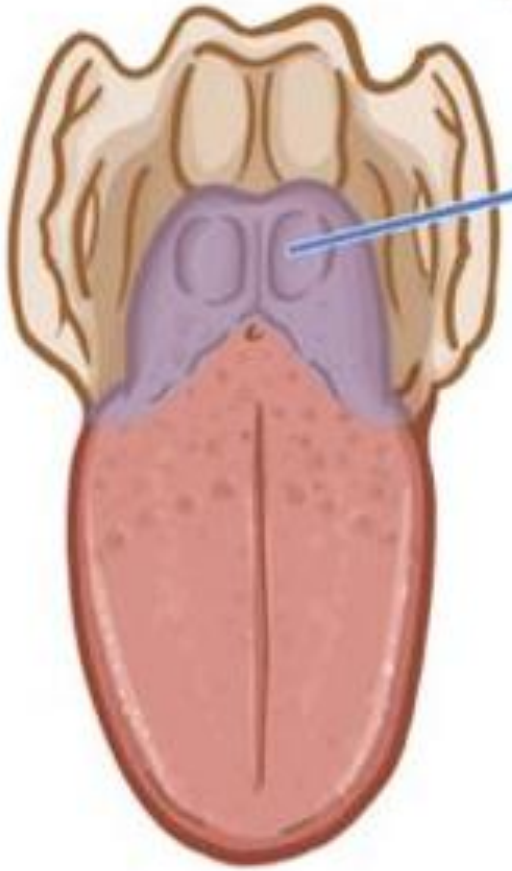

4th pharyngeal arch

Development of the Tongue (Muscles)

- ✓ As these lingual swellings are developing, the occipital somites that come from the paraxial mesoderm migrate into the developing tongue, these occipital somites give rise to myoblasts which go on to develop into the tongue **skeletal muscles.**

- ✓ The motor innervation of tongue muscles comes from the 12th cranial nerve (the hypoglossal nerve) except the palatoglossus muscle.

- ✓ **Taste buds innervation:**
- Anterior ⅔: Ⅶ CV (Chorda tympani branch) which joins the lingual branch of Ⅴ CN
- Posterior ⅓ : Ⅸ

Tongue Anomalies

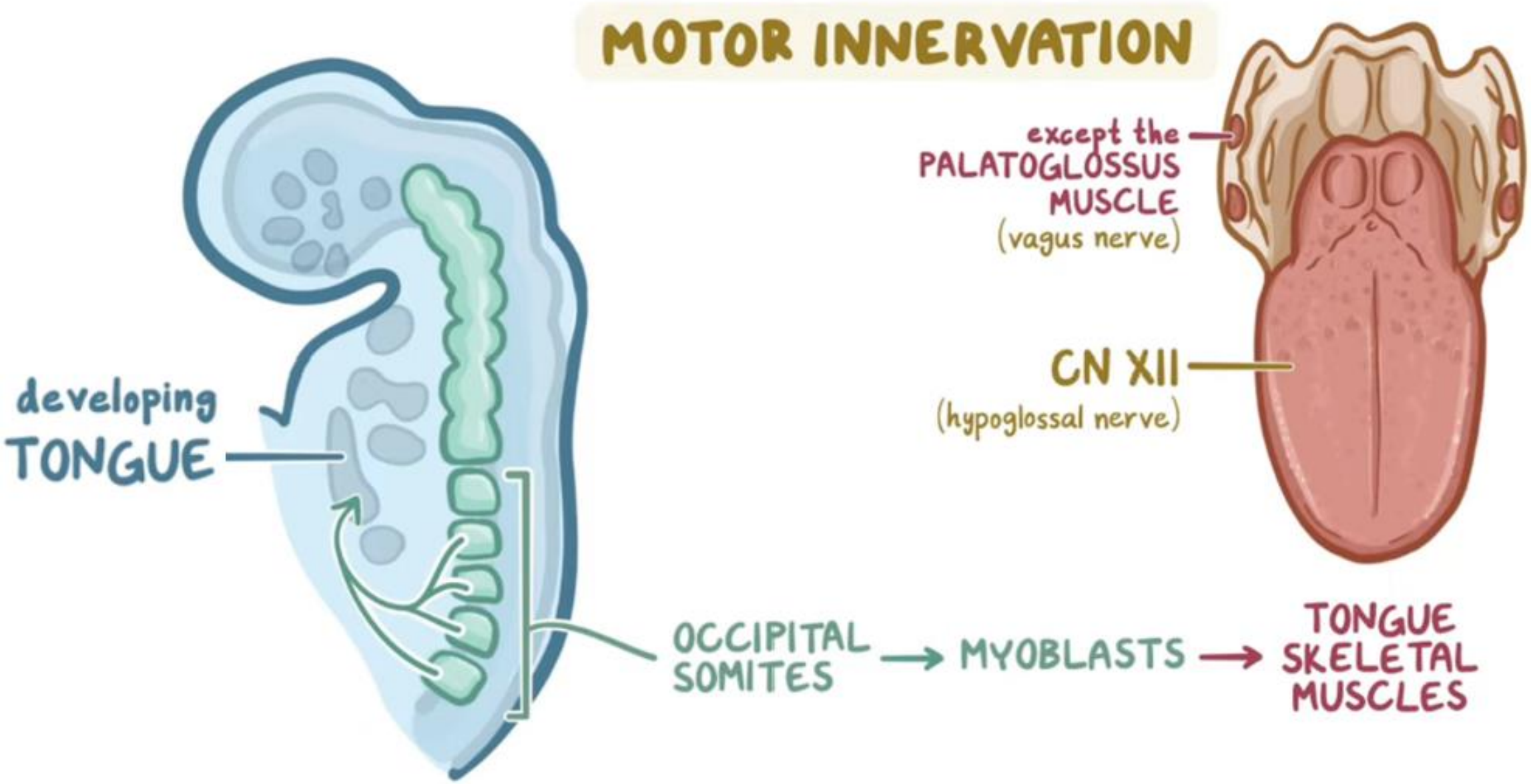

Development of the Tongue (Taste Buds)

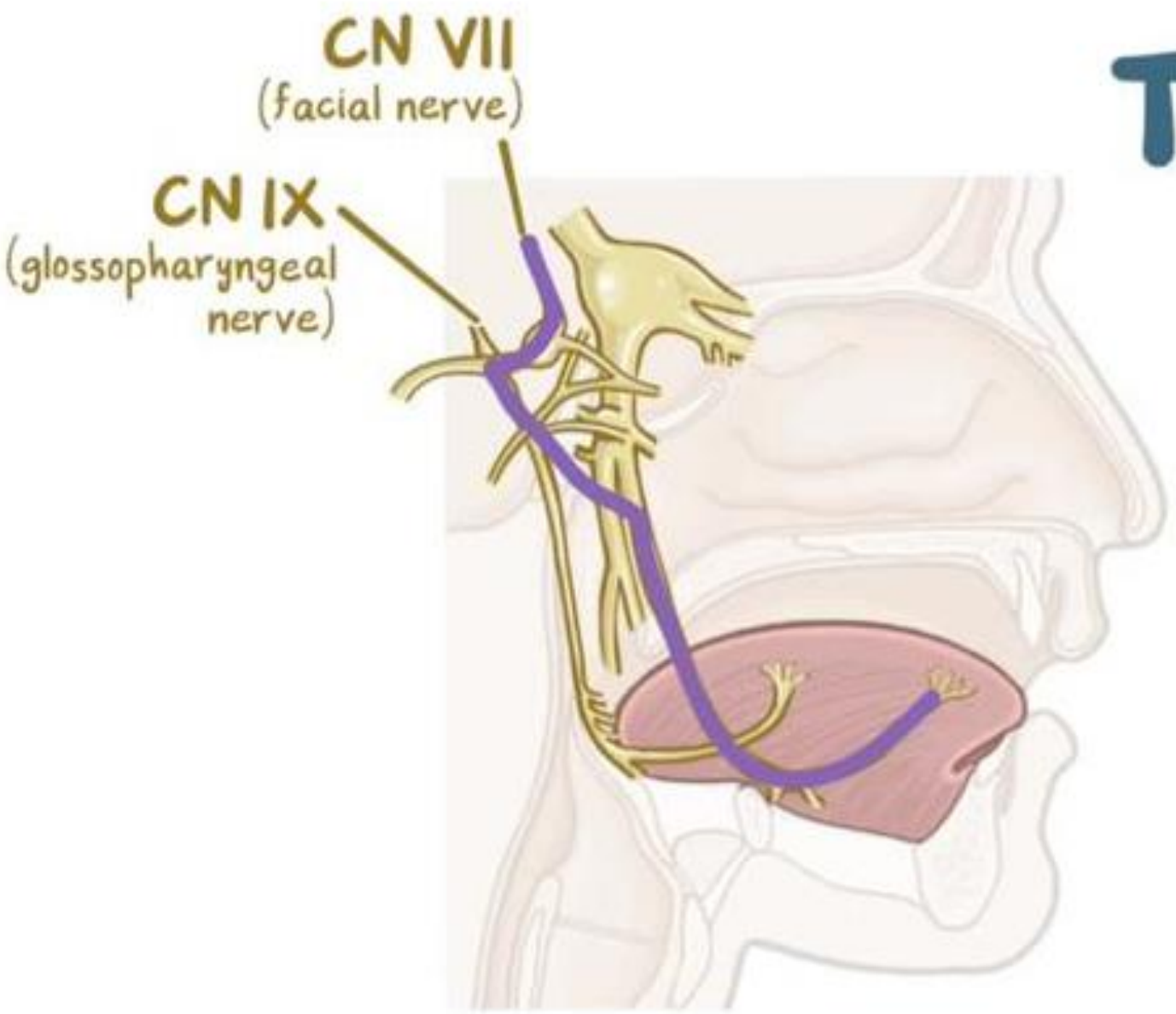

TASTE BUDS

Development of the Tongue (Muscles)

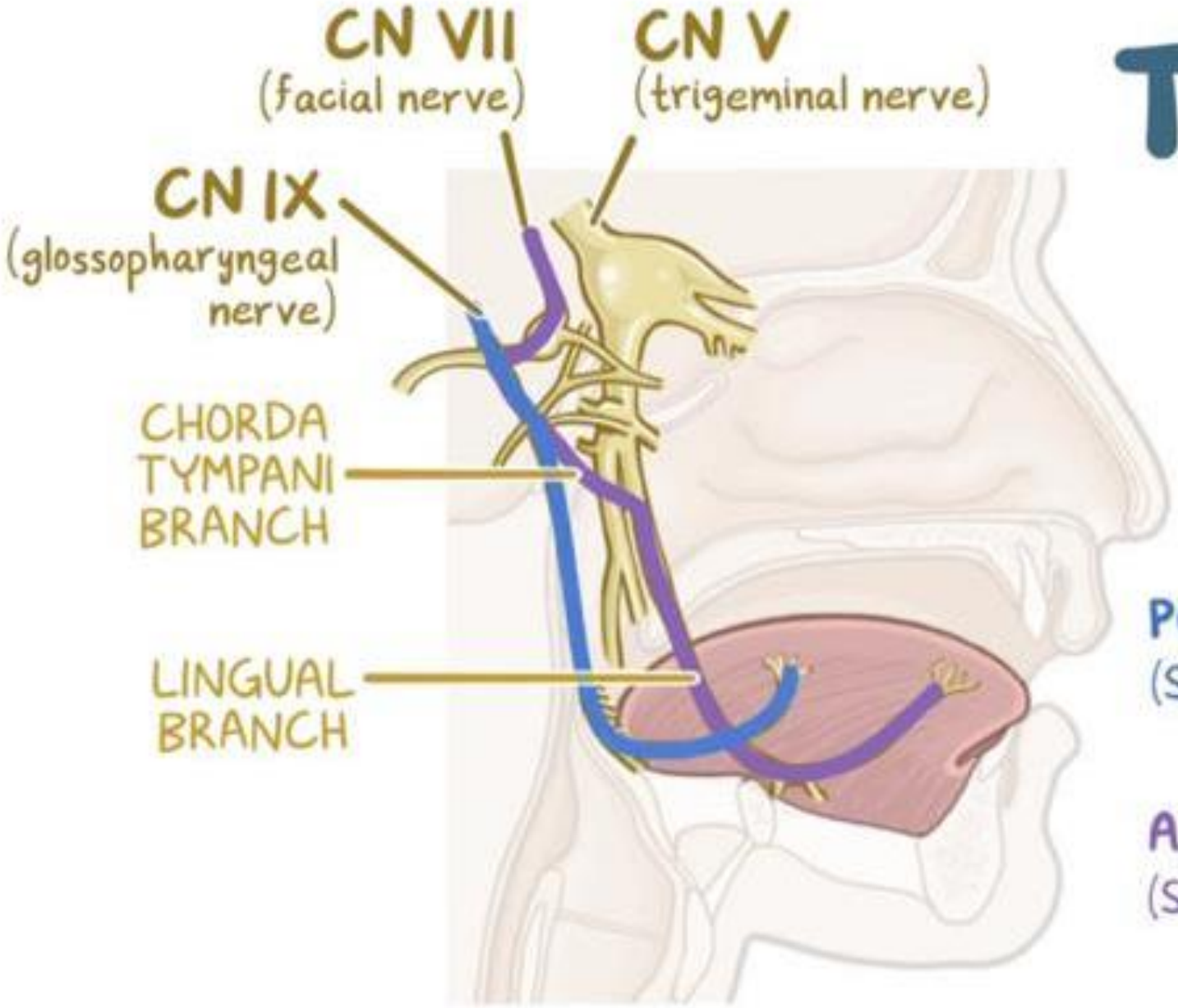

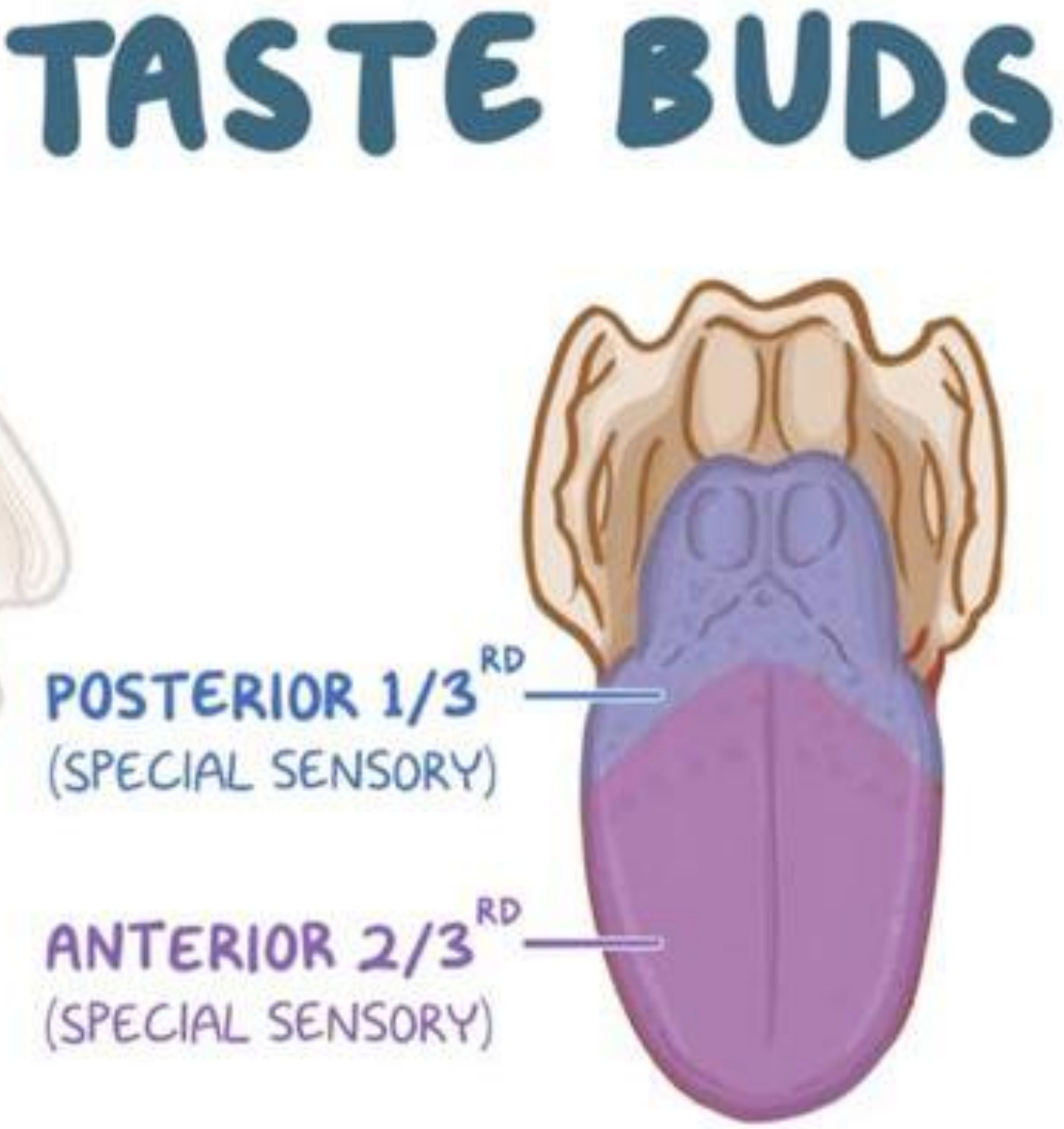

The Tongue

INNERVATION

MOTOR

Palatoglossus
VAGUS NERVE
CN 10

All other muscles
HYPOGLOSSAL NERVE
CN 12

SENSORY

Internal Laryngeal nerve
VAGUS NERVE
CN 10

Glossopharyngeal nerve
SENSORY & TASTE TO POSTERIOR 1/3RD
CN 9

Lingual nerve
SENSORY TO ANTERIOR 2/3RD
CN 5

Chorda Tympani
TASTE TO ANTERIOR 2/3RD
CN 7

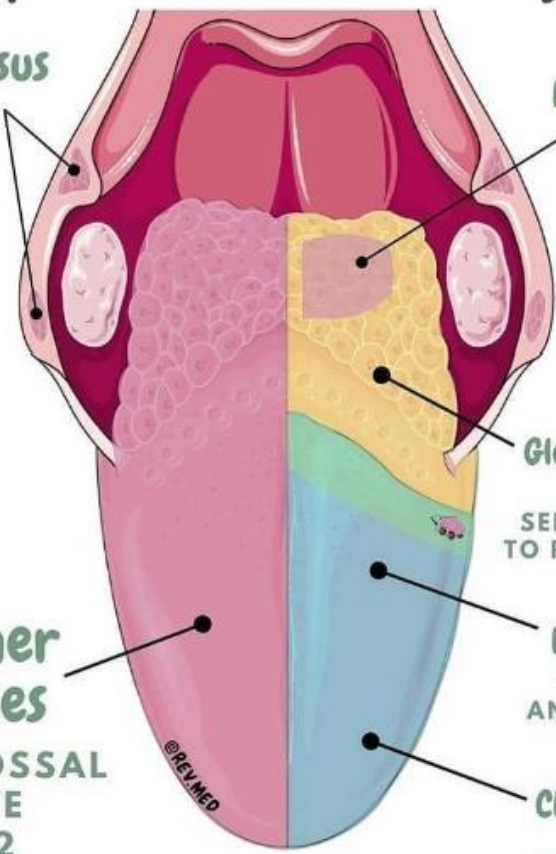

REV Med