Embryology

Lecture 6

Development Of Palate And Tongue And Their Anomalies

Dr Mayyadah Hameed Rasheed
BDS, MSc, PhD
Oral Medicine

Dr Fatma Adnan Abdulkareem
BDS, MSc, PhD
Oral Medicine

Ashur University, College of Dentistry

Development Of Palate And Anomalies

- ✓ Mammalian palatogenesis is a highly regulated process involves growth of the component tissues, epithelial to mesenchymal transformation, cell migration, and programmed cell death at fusion sites of the primary and secondary palatal shelves
- ✓ **Primary palate:** as result of medial growth of maxillary prominences, the two medial nasal prominences merge not only at the surface but also at deeper level. The structure formed by the two merged prominences is the intermaxillary segment. It composed of (1) a labial component, which forms the philtrum of the upper lip, (2) an upper jaw component, which carry the four incisor teeth, (3) a palatal component which forms the triangular primary palate, The intermaxillary segment is contiguous with the rostral (امامي) of the nasal septum
- ✓ **Secondary palate:** Although the primary palate is derived from the intermaxillary segment, the main part of the definitive palate is formed by two shelf- like outgrowths from maxillary prominences. These outgrowth (palatine shelves) are directed downward on each side of the tongue. Then reorient to a horizontal position above the dorsum of the tongue in a process known as palatal shelf elevation. With growth and expansion of the mandible the tongue moves down, allowing the palatine shelves to grow toward the midline where they meet and fuse with each other in process known as palatal shelf closer.

Development Of Palate And Anomalies

- ✓ The palatine uvula is a little piece of teardrop-shaped tissue that hangs from the back of the roof of the mouth. During swallowing, the soft palate and the uvula move together to close off the nasopharynx,so helps prevent food and liquid from entering the nasal cavity during swallowing. It also secretes saliva to keep mouth hydrated. The uvula is also part of gag reflex. When something touches this area of soft palate, it could induce gagging or vomiting as a safety feature. If uvula senses that something is going down the “wrong way,” it course corrects in an effort to avoid choking.

Malformations

- ✓ Facial and palatal clefts usually occur because of a combination of environmental and genetic factors. Cleft lip is the most common facial malformation.

Facial Clefts :are classified according to position and extent. A cleft may affect one or both sides of the upper lip (unilateral or bilateral) and can be either incomplete or complete. An incomplete cleft lip ranges in size from a notch to a deep groove in the upper lip but does not involve an opening of the nostril into the oral cavity. A cleft may occur in the midline of the maxilla, which is rare in humans, involves a notch in the medial nasal tissue that may be minute or may extend as a cleft into the nose.

A cleft of the mandible may appear in the midline, and this also is rare

Palatal Clefts: All the preceding facial clefts involve the lip, but some may extend into the palate as unilateral and bilateral cleft lip and palate defects. Because the palatine shelves meet in the midline, both unilateral and bilateral clefts of the palate are in the midline.

Cleft lip & palate result in abnormal facial appearance and difficulties with speech and feeding. Because the lip and the palate develop separately, it is possible to have a cleft lip without a cleft palate, a cleft palate without a cleft lip, or both a cleft lip and cleft palate together The incisive foramen is considered the dividing landmark between anterior and posterior cleft deformities. anterior to the incisive foramen include lateral cleft lip, cleft upper jaw, and cleft between the primary and secondary palates. Such defects are due to a partial or complete lack of fusion of the maxillary prominence with the medial nasal prominence on one or both sides. Posterior to the incisive foramen include cleft (secondary) palate and cleft uvula. Cleft palate results from a lack of fusion of the palatine shelfs which may be due to smallness of the shelfs, frailer of the shelfs to elevate, or faller of the tongue to drop from between the shelves because of micrognathia. Third type is formed by combination of the clefts lying anterior as well as posterior to the incisive foramen

Malformations

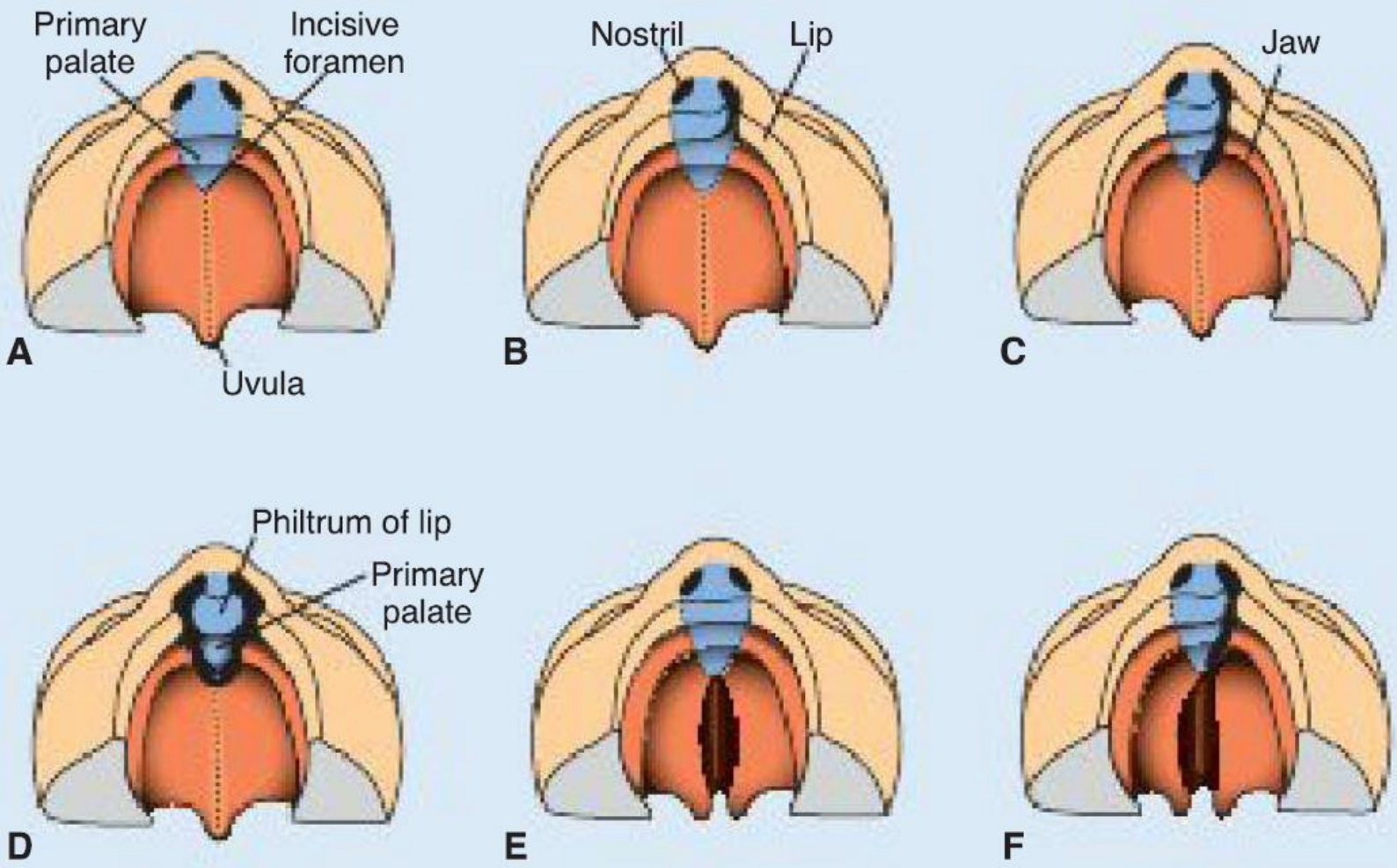

FIGURE 17.28 Ventral view of the palate, gum, lip, and nose. **A.** Normal. **B.** Unilateral cleft lip extending into the nose. **C.** Unilateral cleft involving the lip and jaw and extending to the incisive foramen. **D.** Bilateral cleft involving the lip and jaw. **E.** Isolated cleft palate. **F.** Cleft palate combined with unilateral anterior cleft lip.

Facial Anomalies

2. **Oblique facial cleft:** A rare defect that results when the **lateral nasal process fails to fuse with the maxillary process**, usually resulting from hypoplasia of one of the tissue masses
3. **Macrostomia:** Incomplete lateral merging of maxillary and mandibular processes.
4. **Microstomia:** Too much fusion of mandibular and maxillary prominances may result in small mouth
5. **Hemifacial macrosomia:** is a condition in which one side of the face is smaller or underdeveloped or has parts that are missing. While the hallmark is asymmetry of the face, one or both sides may be affected. It is the second most common facial birth defect after cleft lip and palate
6. **Frontonasal dysplasia:** Frontonasal dysplasia: is a rare malformation resulting from abnormal morphogenesis of the frontonasal process, associated with a spectrum of midline facial bone and soft-tissue malformations, Major characteristics may include widely spaced eyes; a flat broad nose; and/or a vertical groove down the middle of the face; and abnormal skin-covered gap in the front of the head

Facial Anomalies

- **Oblique facial cleft:** A rare defect that results when the **nasolateral process** fails to fuse with the **maxillary process**, usually resulting from hypoplasia of one of the tissue masses





Facial Anomalies

- ✓ **Macrostomia:** Incomplete lateral merging of maxillary and mandibular processes.





Facial Anomalies

- ✓ **Microstomia:** Too much fusion of mandibular and maxillary prominances may result in small mouth



Facial Anomalies

- **Hemifacial macrosomia:** is a condition in which one side of the face is smaller or underdeveloped or has parts that are missing. While the hallmark is asymmetry of the face, one or both sides may be affected. It is the second most common facial birth defect after cleft lip and palate



Facial Anomalies

- **Frontonasal dysplasia:** is a rare malformation resulting from abnormal morphogenesis of the **frontonasal process**, associated with a spectrum of **midline facial bone and soft-tissue** malformations, Major characteristics may include widely spaced eyes; a flat broad nose; and/or a vertical groove down the middle of the face; and abnormal skin-covered gap in the front of the head

Facial Anomalies

✓ Frontonasal dysplasia:





