Embryology

Lab 6

Development Of Palate And Tongue And Their Anomalies

Dr Mayyadah Hameed Rasheed
BDS, MSc, PhD
Oral Medicine

Dr Fatma Adnan Abdulkareem
BDS, MSc, PhD
Oral Medicine

Ashur University, College of Dentistry

Development Of Palate And Anomalies

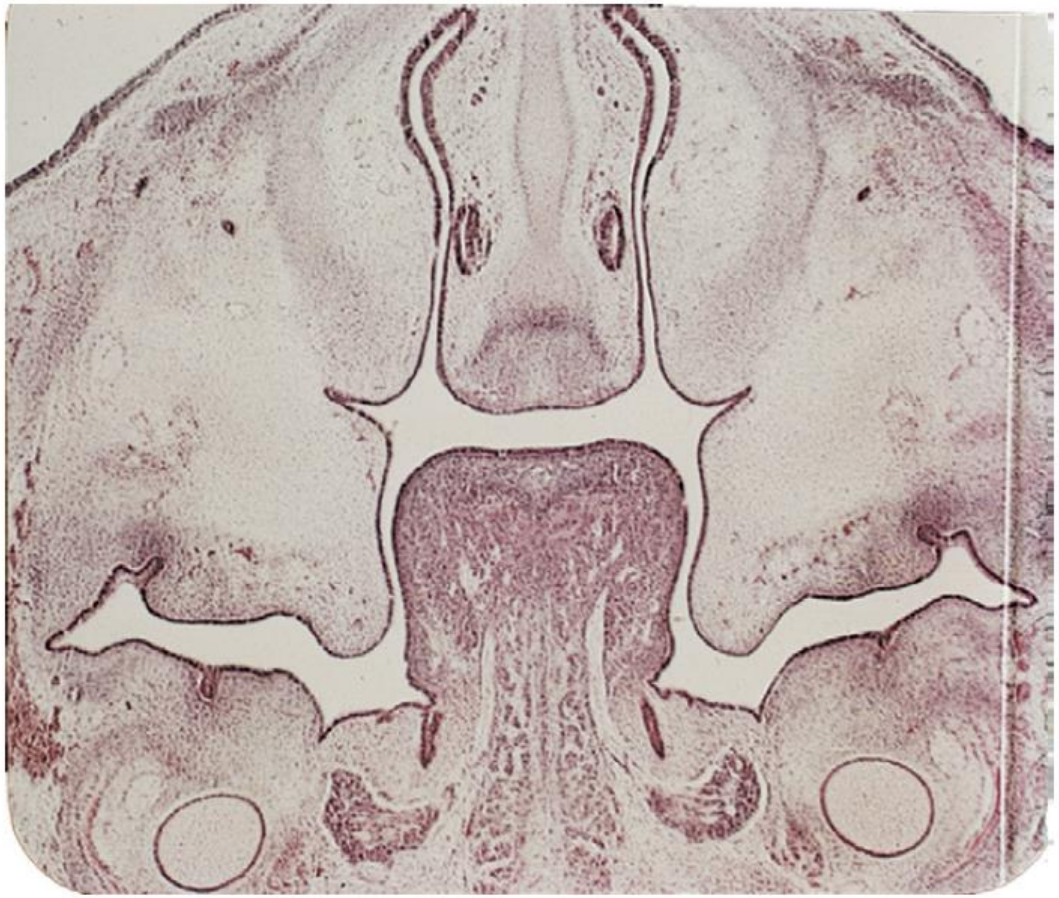

Fig. 4.8 Coronal section of facial tissue showing tongue's growth upward into the nasal cavity during the seventh prenatal week. Palatine shelves (maxillary processes) contact the tongue during their medial growth. The tongue then grows down beside the palatal shelves. The tongue muscle begins to differentiate at this time.

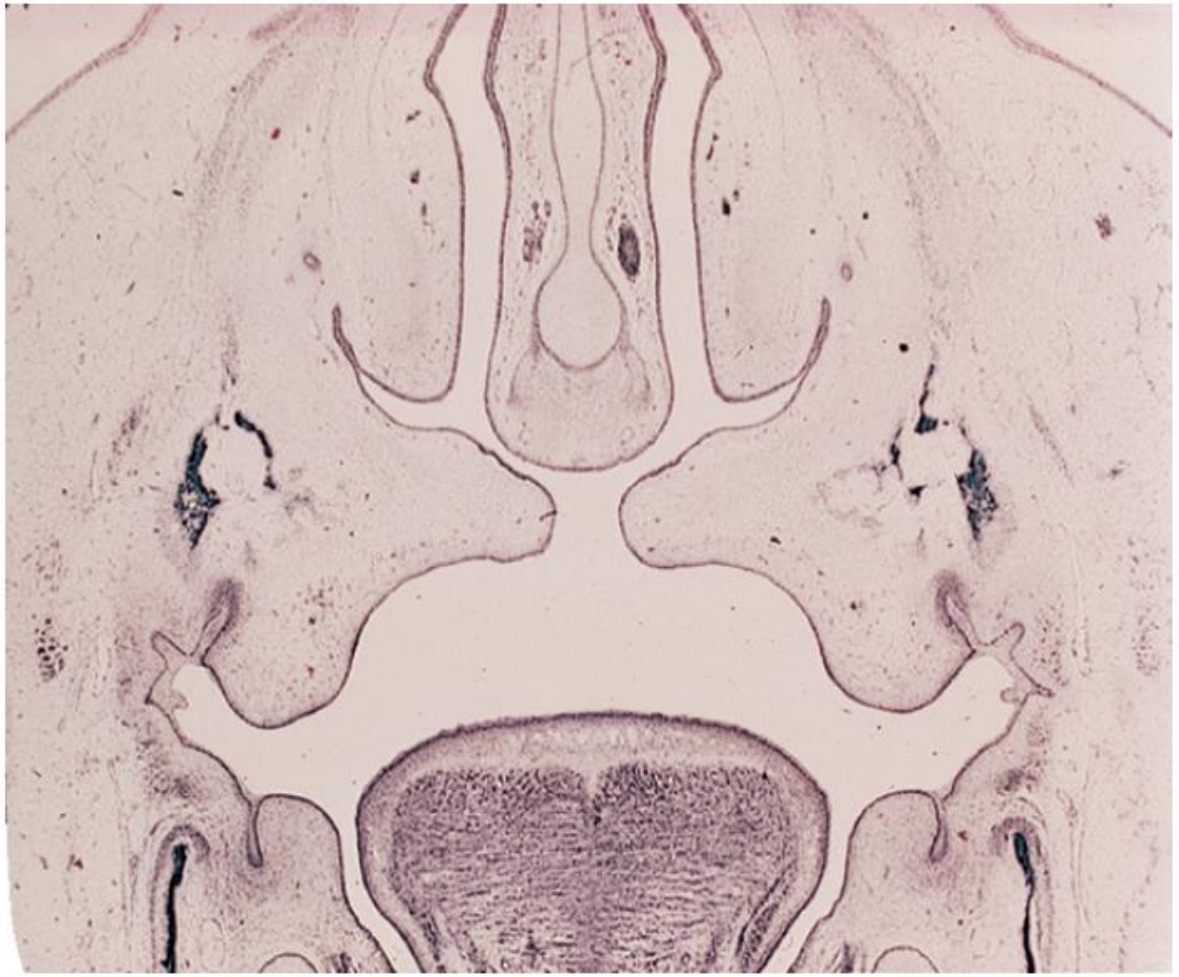

Fig. 4.11 Tongue with overlying palatal shelves at eighth week. The palatal shelves are in a near-midline position underlying the nasal septum.

Development Of Palate And Anomalies

- ✓ The palatine uvula is a little piece of teardrop-shaped tissue that hangs from the back of the roof of the mouth. During swallowing, the soft palate and the uvula move together to close off the nasopharynx,so helps prevent food and liquid from entering the nasal cavity during swallowing. It also secretes saliva to keep mouth hydrated. The uvula is also part of gag reflex. When something touches this area of soft palate, it could induce gagging or vomiting as a safety feature. If uvula senses that something is going down the "wrong way," it course corrects in an effort to avoid choking.

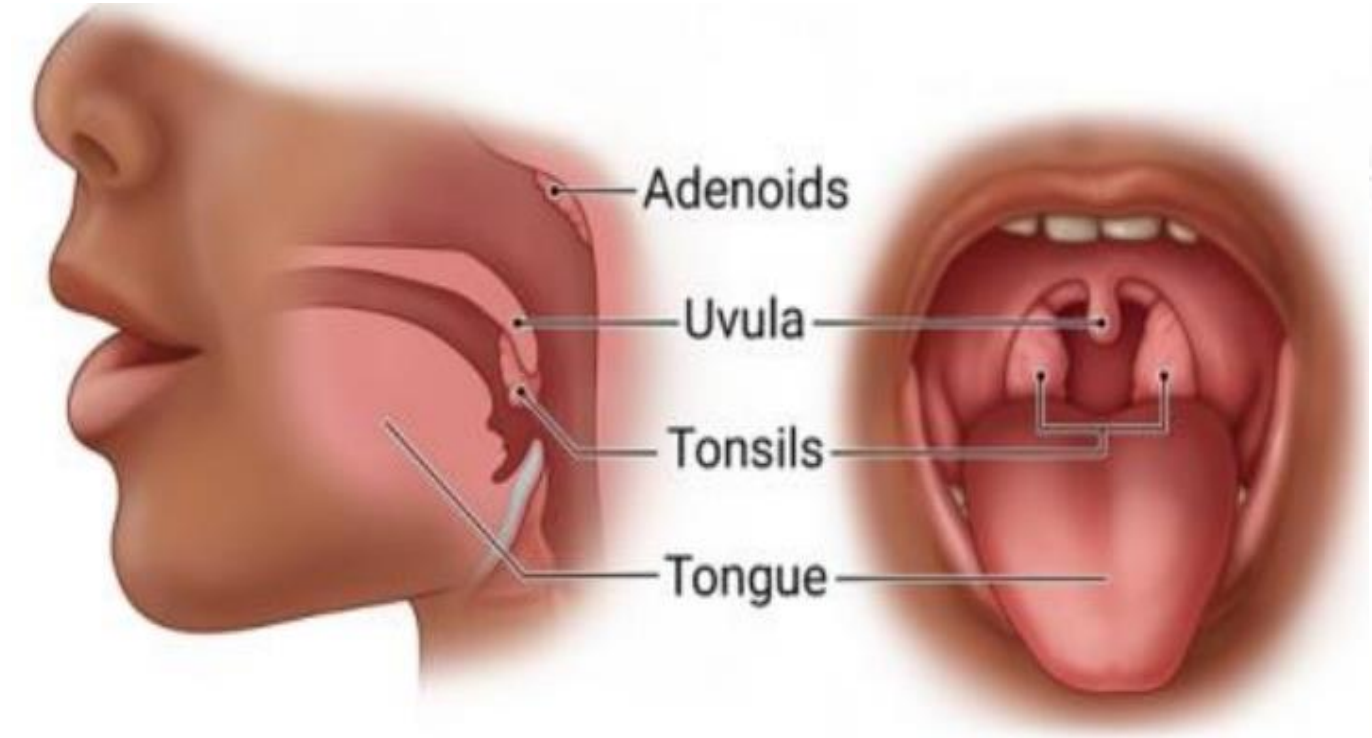



Malformations

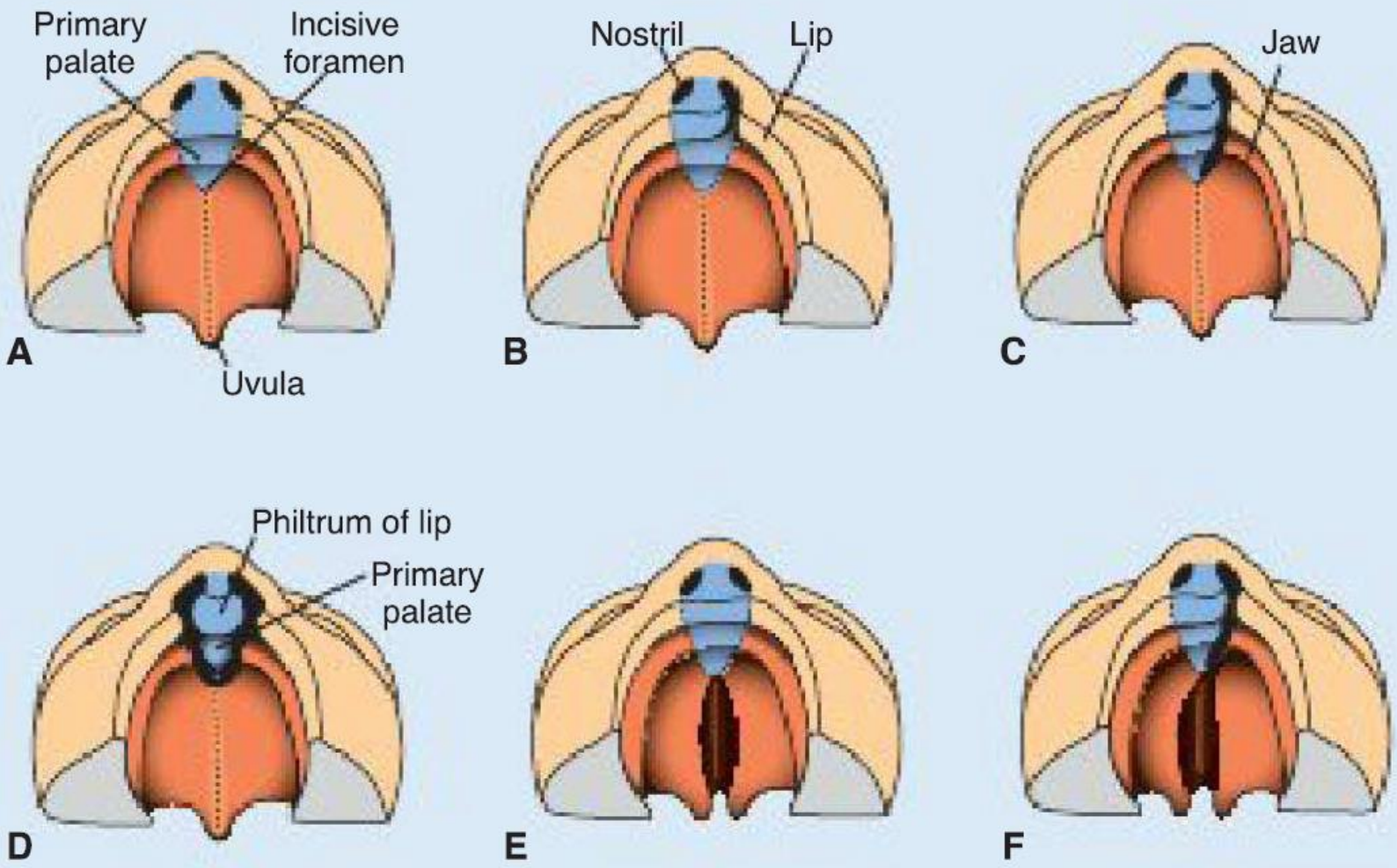

FIGURE 17.28 Ventral view of the palate, gum, lip, and nose. **A.** Normal. **B.** Unilateral cleft lip extending into the nose. **C.** Unilateral cleft involving the lip and jaw and extending to the incisive foramen. **D.** Bilateral cleft involving the lip and jaw. **E.** Isolated cleft palate. **F.** Cleft palate combined with unilateral anterior cleft lip.

Facial Anomalies (عملي)

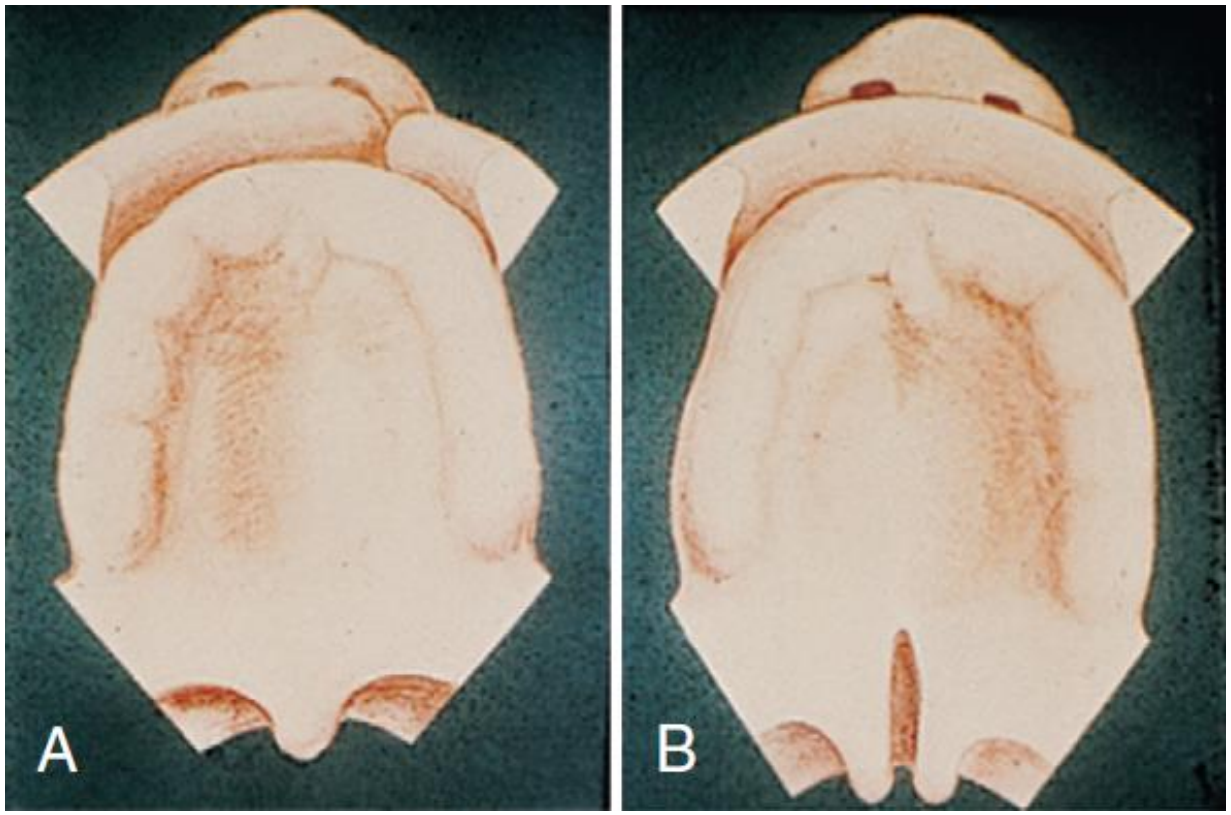

Cleft lip only

Cleft palate only



Unilateral complete cleft lip and palate

Bilateral complete cleft lip and palate

Facial Anomalies (عملي)

Example of Unilateral cleft of the lip

- ✓ this partial cleft
- ✓ Located in the line of fusion of the **medial nasal** and **maxillary processes.**

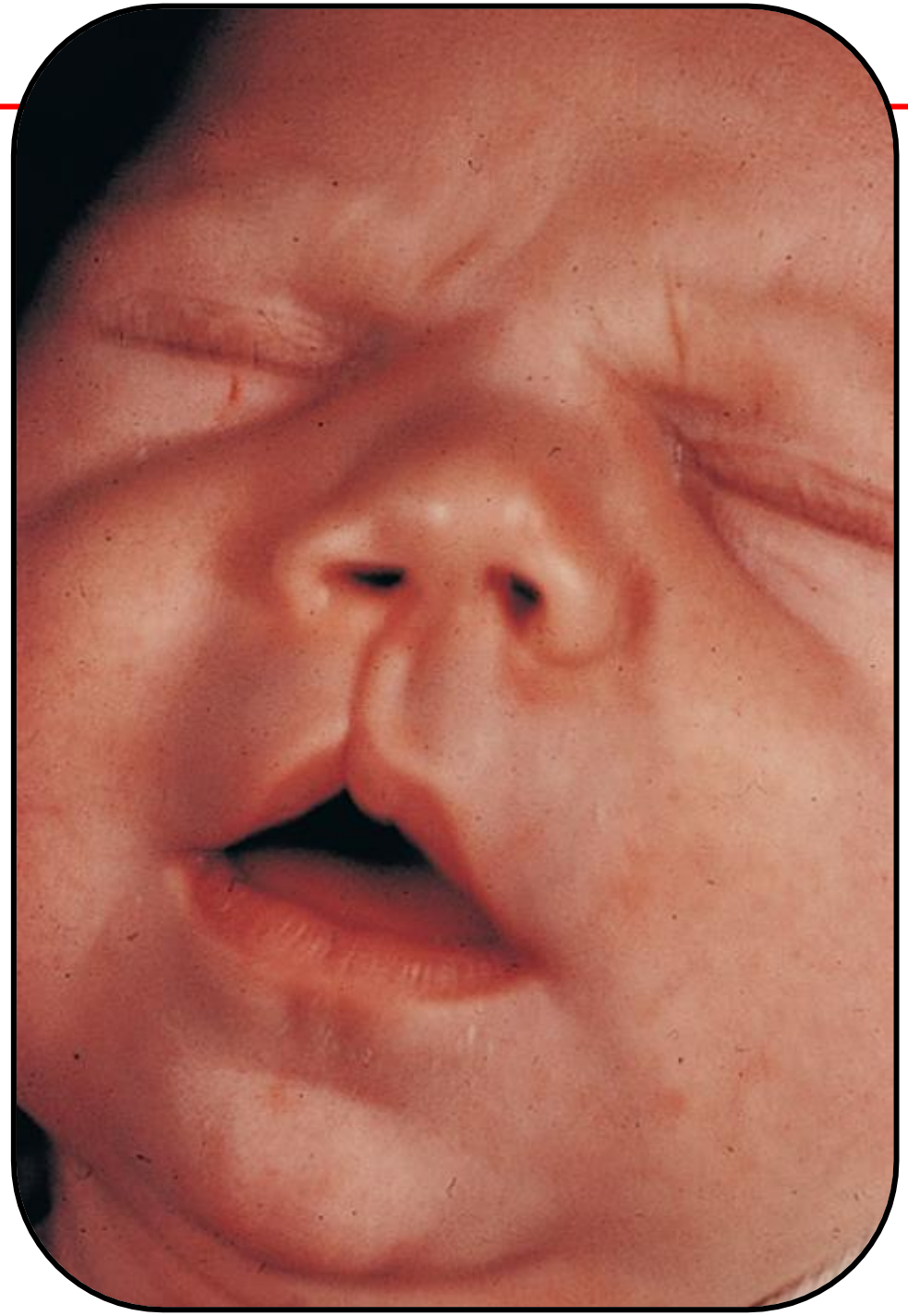

Facial Anomalies (عملي)

Example of Unilateral complete cleft lip

- ✓ The **maxillary process** and **medial nasal process** did not fuse
- ✓ And then pulled apart during facial growth.



Facial Anomalies (عملي)

Example of Midline cleft of the lip

- ✓ This rare cleft
- ✓ Occurs when the **two medial nasal process** fail to merge

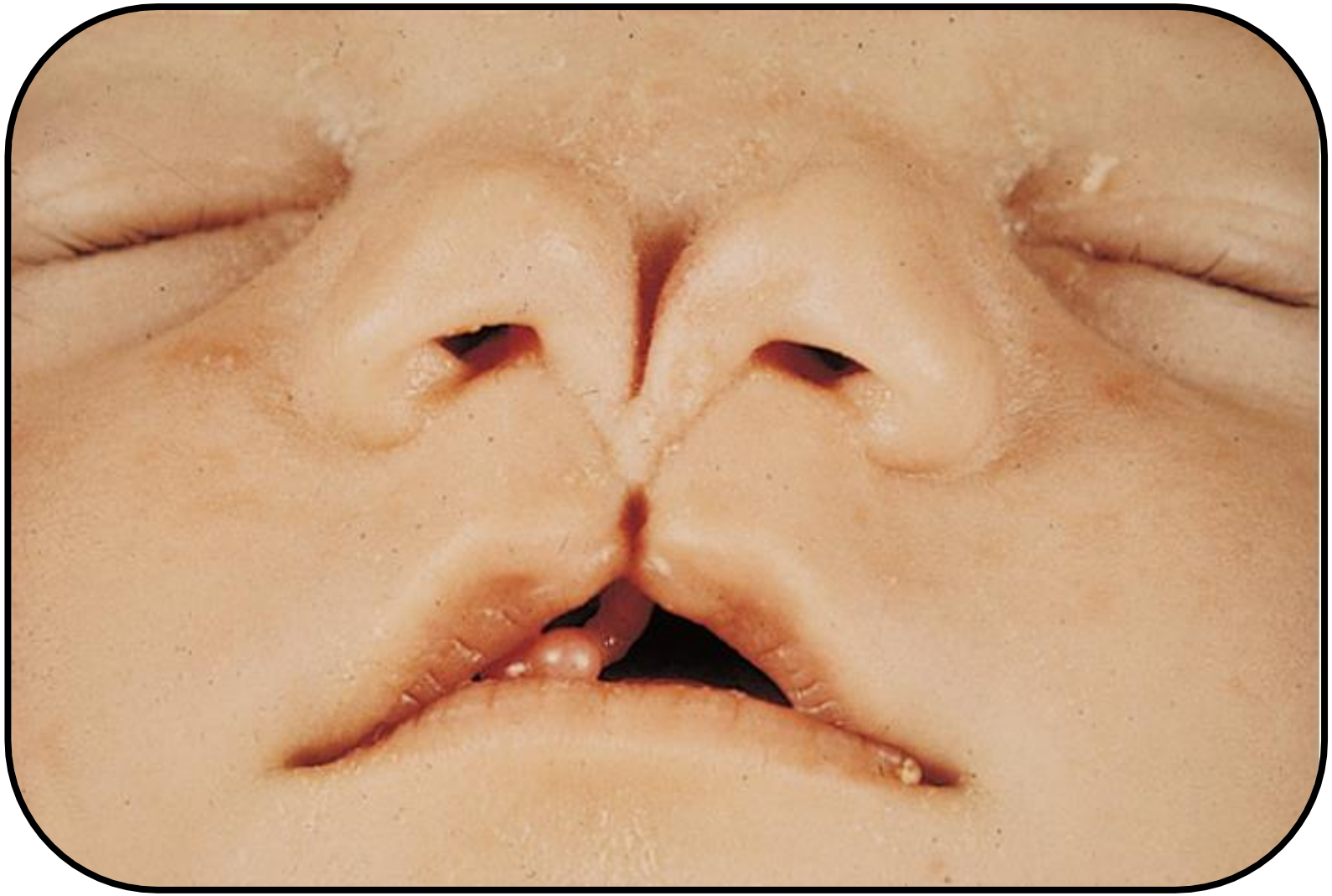

Facial Anomalies (عملي)

Example of Midline cleft of the mandible

- ✓ The two parts of the **first pharyngeal arch**, including the bony mandible, are separated at birth



Example of Bilateral complete cleft of the lip

- ✓ The **medial nasal process** did not fuse on either side of the developing **maxillary processes**.
- ✓ This results in **anterior extrusion** of the medial labial process.



Example of Bilateral complete cleft lip and Palate

- ✓ **Bilateral cleft** extends lateral to the medial palatal process and then posteriorly in the midline.

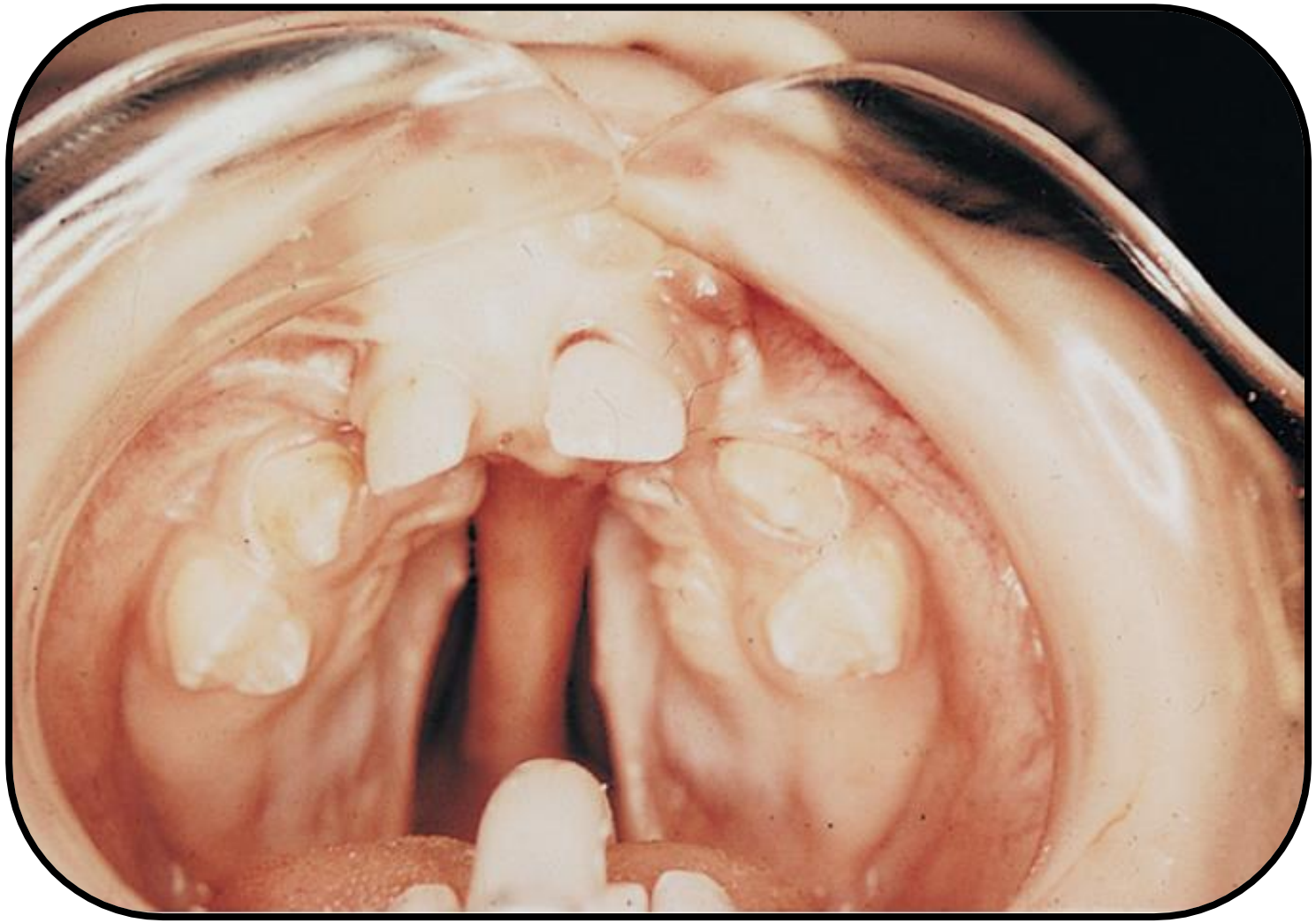

Facial Anomalies (عملي)

Example of a unilateral complete cleft lip and palate

a cleft of the palate developed lateral to the medial palatal segment then posteriorly in the midline between the two palatal processes. This cleft occurs along the fusion lines of the palatal processes.

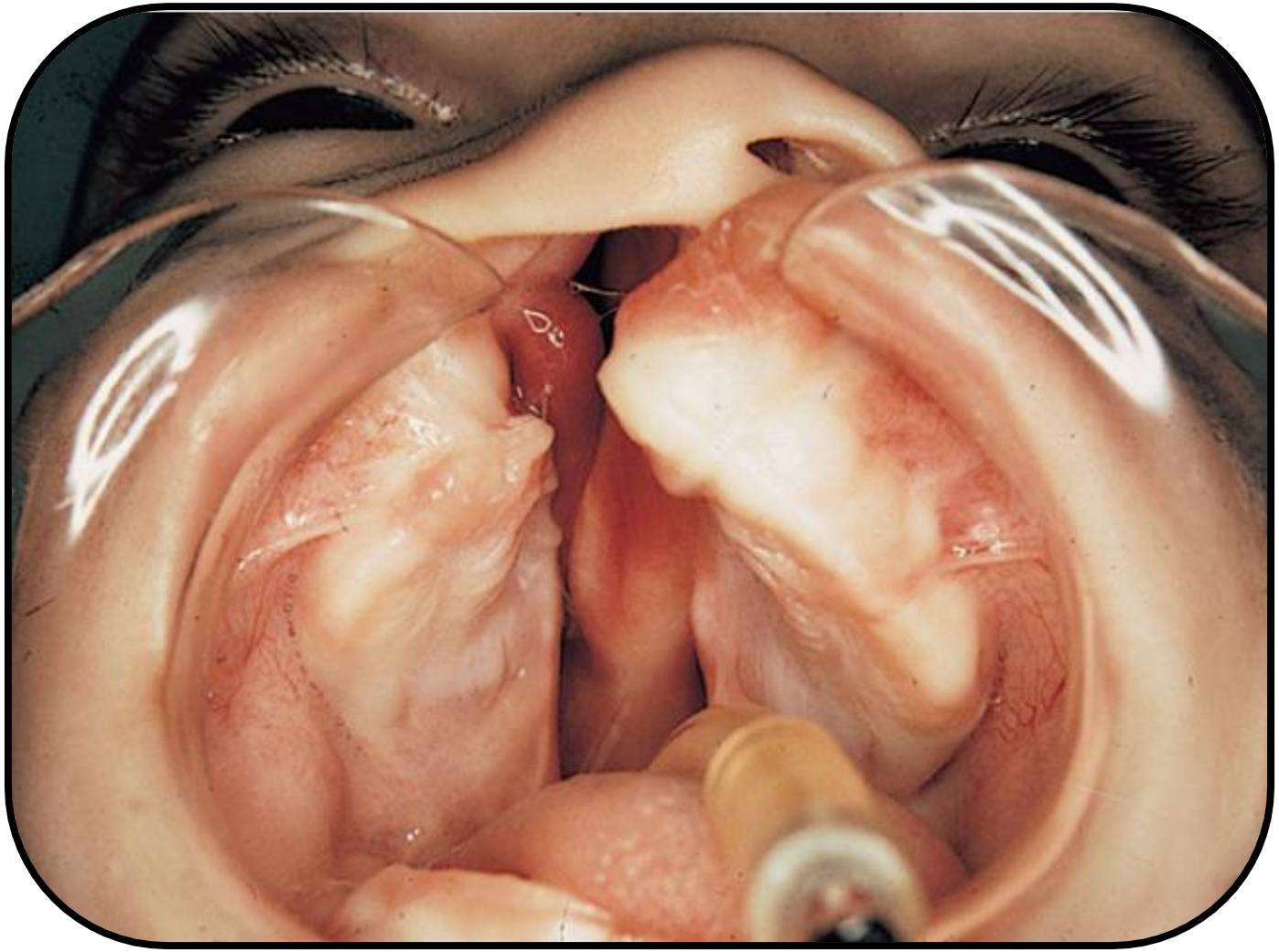

Facial Anomalies

- **Oblique facial cleft:** A rare defect that results when the **nasolateral process** fails to fuse with the **maxillary process**, usually resulting from hypoplasia of one of the tissue masses





Facial Anomalies

- ✓ **Macrostomia:** Incomplete lateral merging of maxillary and mandibular processes.





Facial Anomalies

- ✓ **Microstomia:** Too much fusion of mandibular and maxillary prominances may result in small mouth



Facial Anomalies

- **Hemifacial macrosomia:** is a condition in which one side of the face is smaller or underdeveloped or has parts that are missing. While the hallmark is asymmetry of the face, one or both sides may be affected. It is the second most common facial birth defect after cleft lip and palate



Facial Anomalies

✓ Frontonasal dysplasia:





