Embryology

Lecture 5

Development of The Face

Dr Mayyadah Hameed Rasheed
BDS, MSc, PhD
Oral Medicine

Dr Fatma Adnan Abdulkareem
BDS, MSc, PhD
Oral Medicine

Ashur University, College of Dentistry

Development of The Face

- ✓ **During 3rd week** of embryonic development, an **oropharyngeal membrane** initially appears at the site of the future face. It is comprised of an external ectoderm and internal endoderm. This membrane during the **4th week** begins to **break down** in order to become the future oral cavity, and sits at the beginning of the digestive tract.
- ✓ The external human **face develops between the 4th and 6th week** of embryonic development. There are two important **tissue structures** involved in development of the nose and face **{the pharyngeal arches and neural crest cells}**

3rd Week

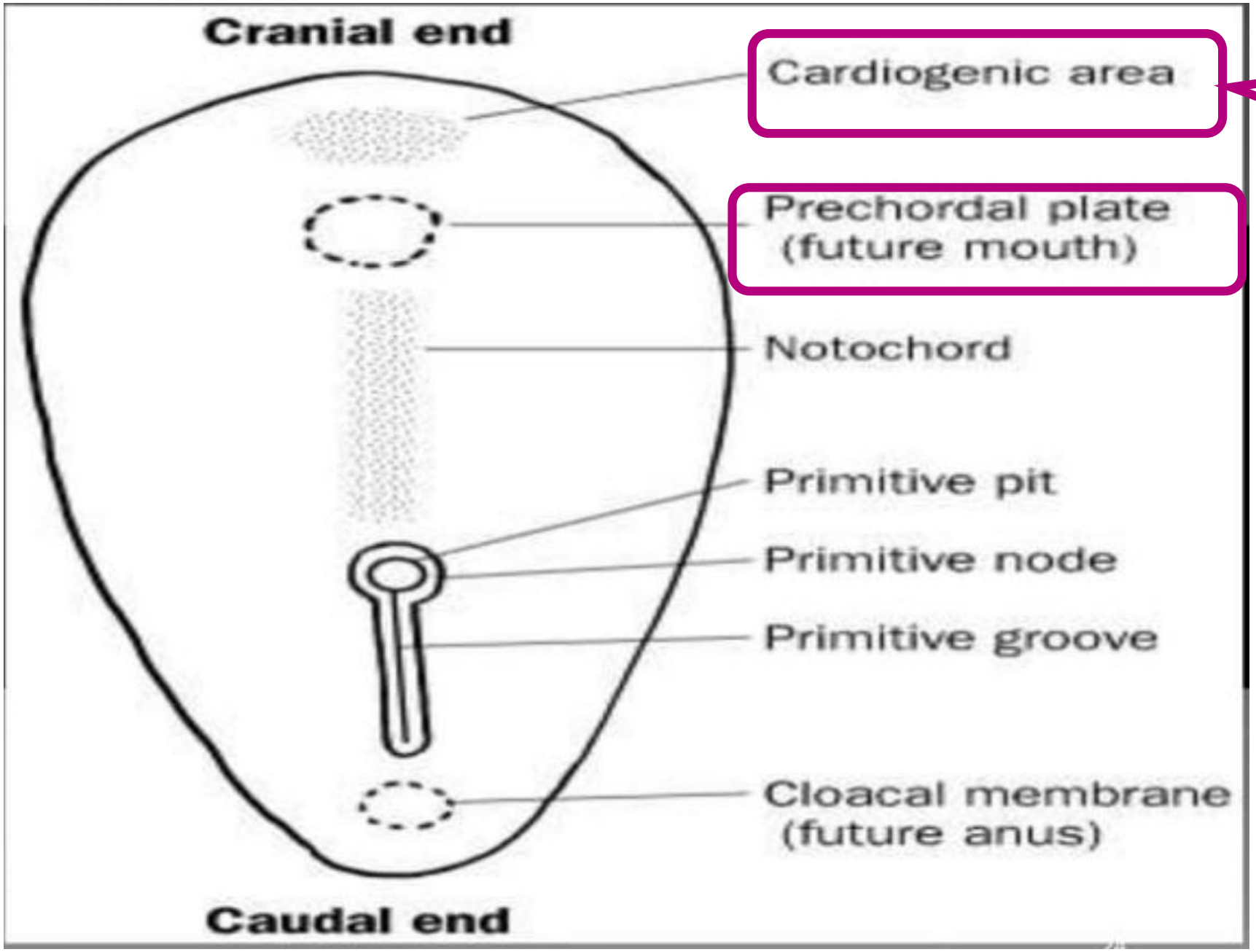
Cranial end
Cardiogenic area
Prechordal plate
(future mouth)
Notochord
Primitive pit
Primitive node
Primitive groove
Cloacal membrane
(future anus)
Caudal end

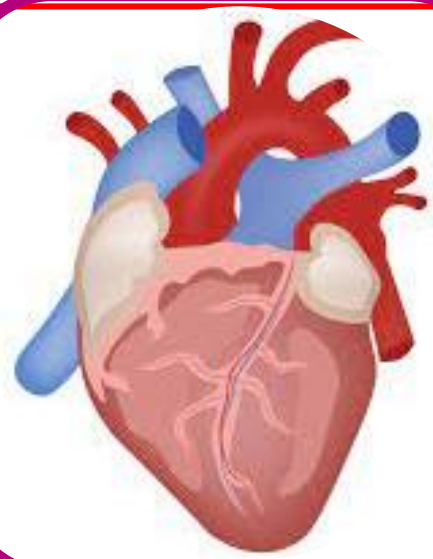



3rd Week

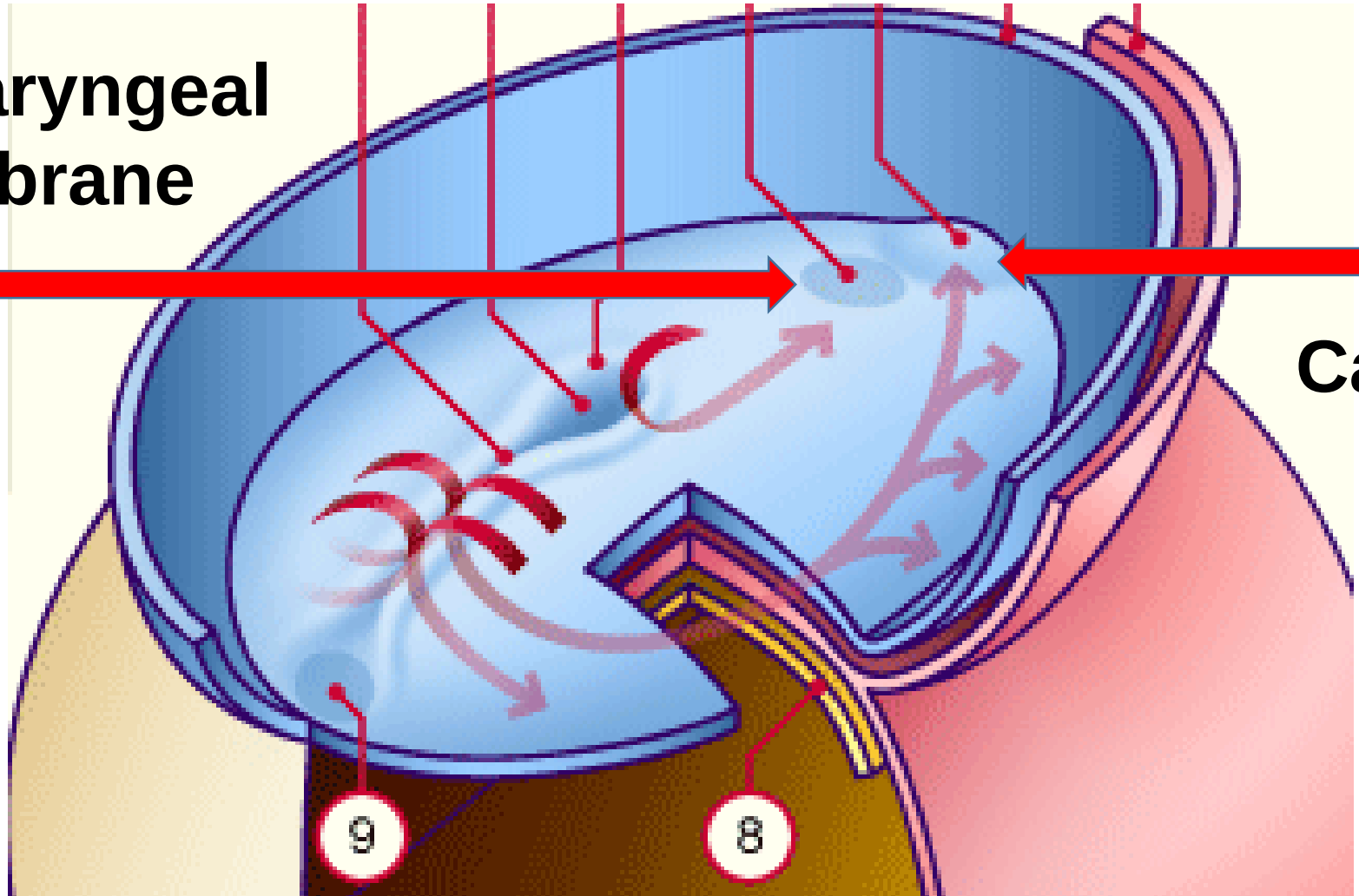

Development The Oral Cavity

- ✓ The oral pit first appears in the 4th week of development, when the **cephalocaudal bending** occurs and pushes the heart ventrally, and the **yolk sac becomes enclosed** to form an elongating tube known as the **foregut**

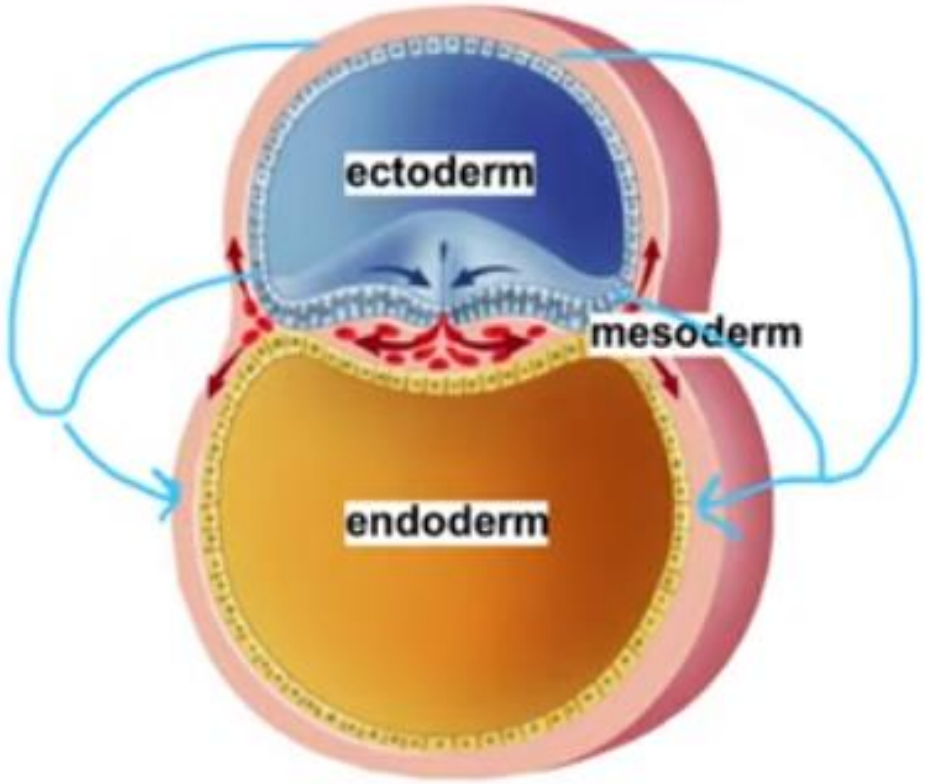

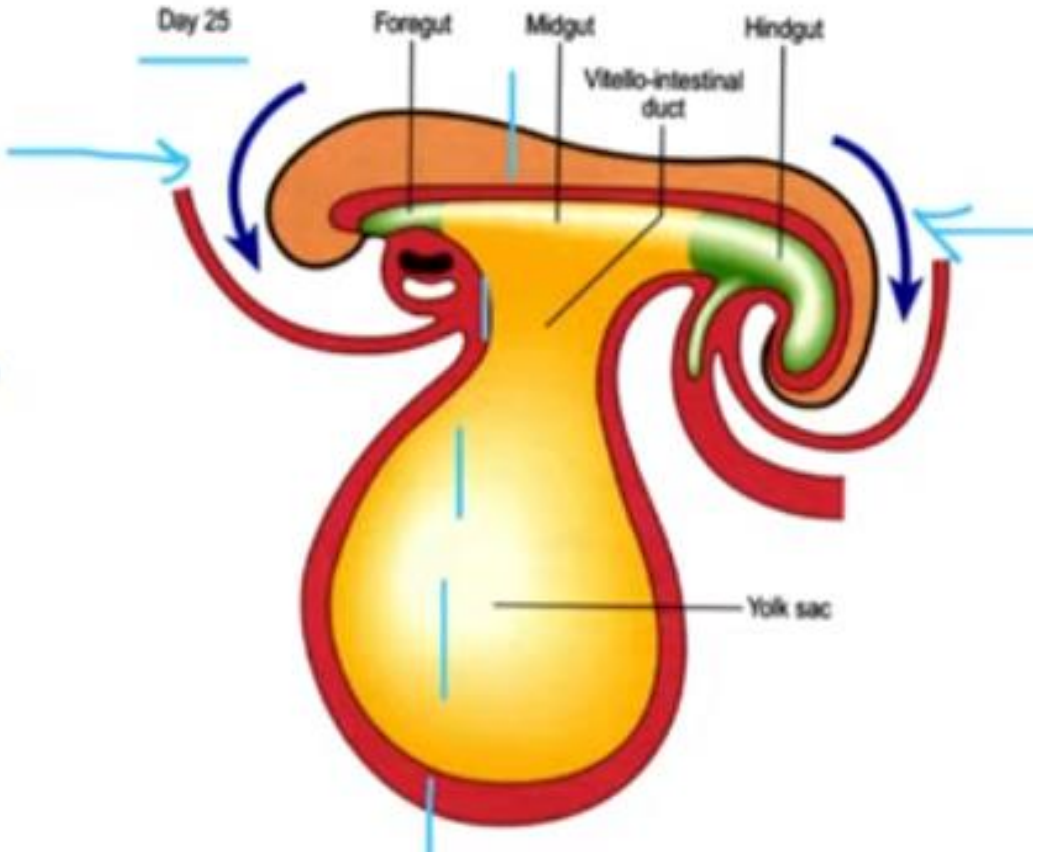

Development The Oral Cavity

- ✓ This **pit (stomatodeum)** which lies between the forebrain (from above) and the heart (bellow) will deepen and eventually becomes the oral cavity.
- ✓ At its **deepest extent** is the **oropharyngeal membrane**, which ruptures in the 5th week, opens the oral cavity to the tubular foregut, and soon becomes the oropharynx.

Development of The Face

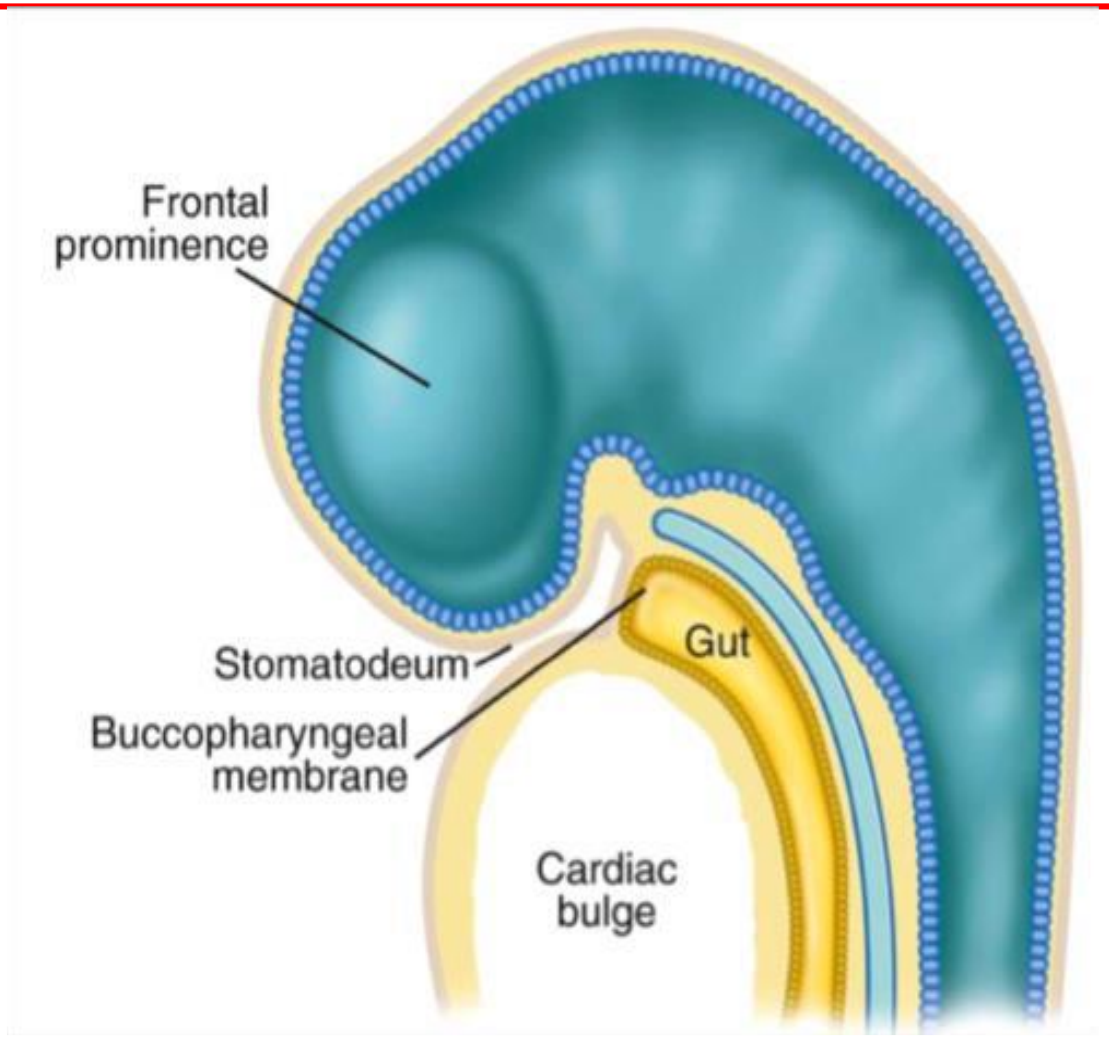

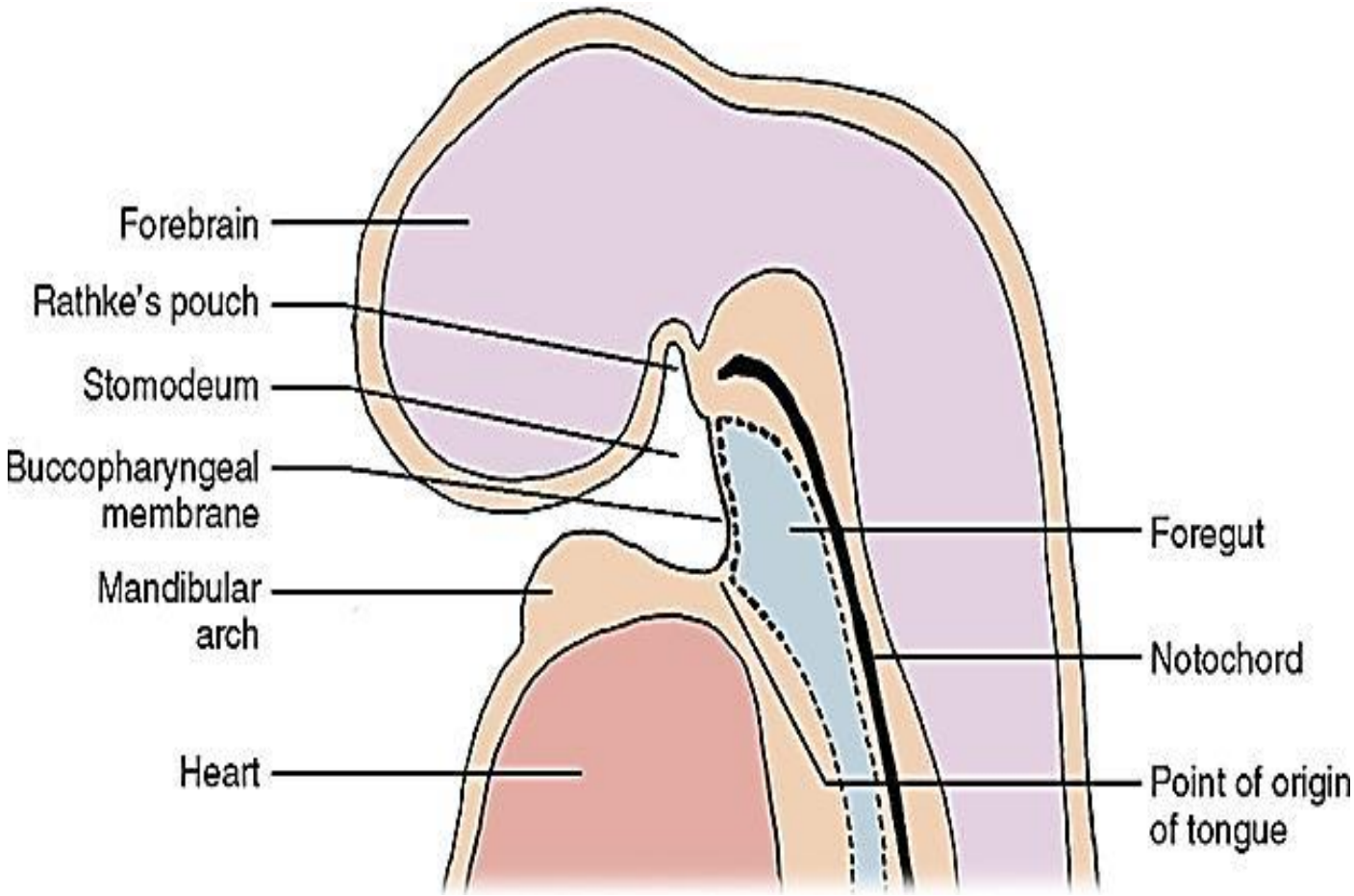

Development of The Face

- ✓ The enlarging heart now becomes positioned below the mandibular arch and begins beating at the end of the 4th week
- ✓ The forming face now grows away from the forebrain and presses against the chest and heart.



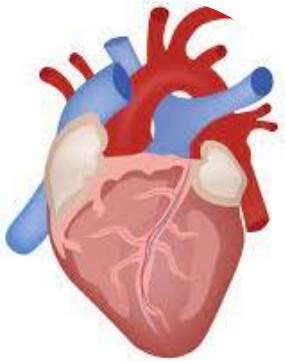

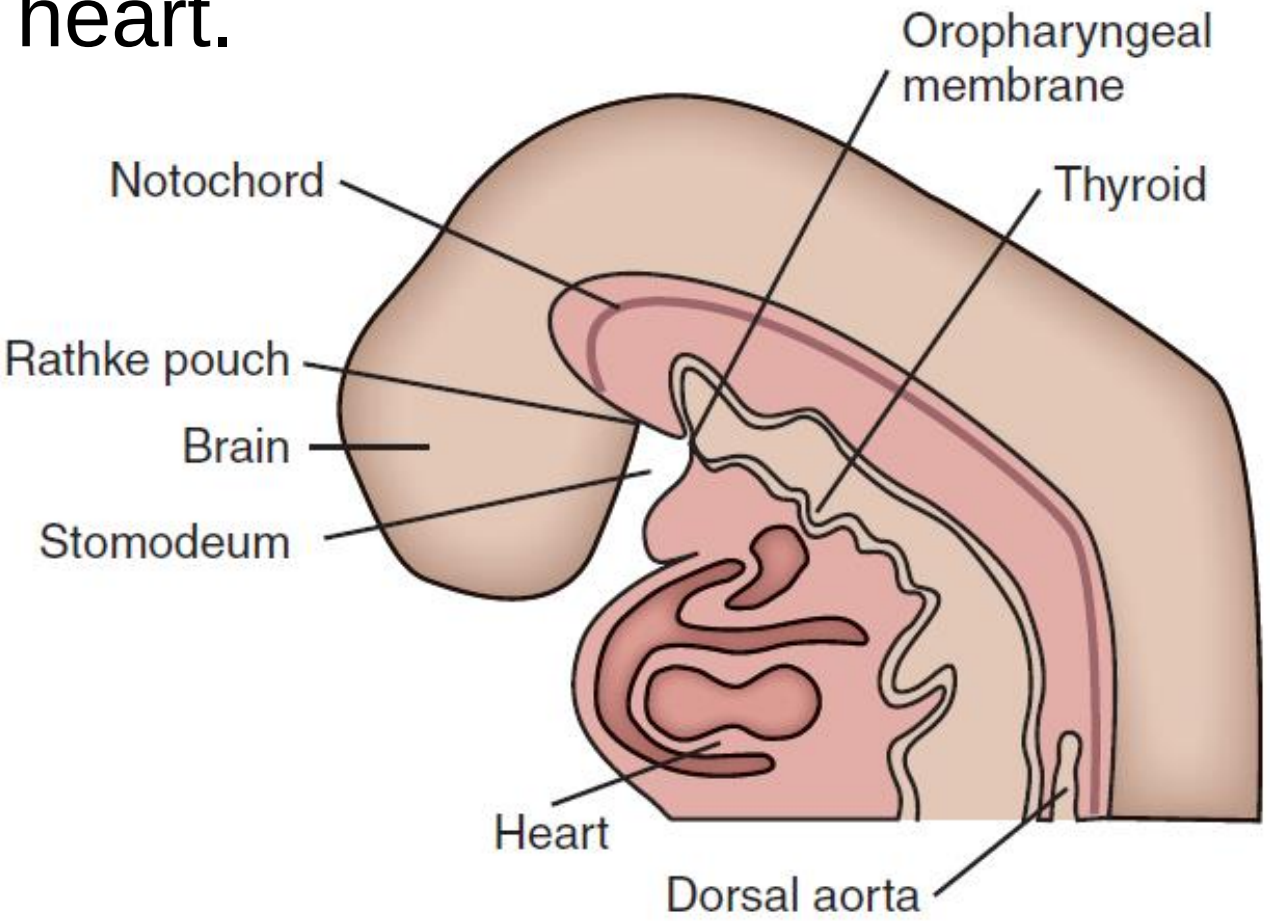

Development of The Face

- ✓ The external face forms from 5 prominences that surround the oropharyngeal membrane:
- A **frontonasal prominence**
- **2 Mandibular prominences**
- **2 maxillary prominences**

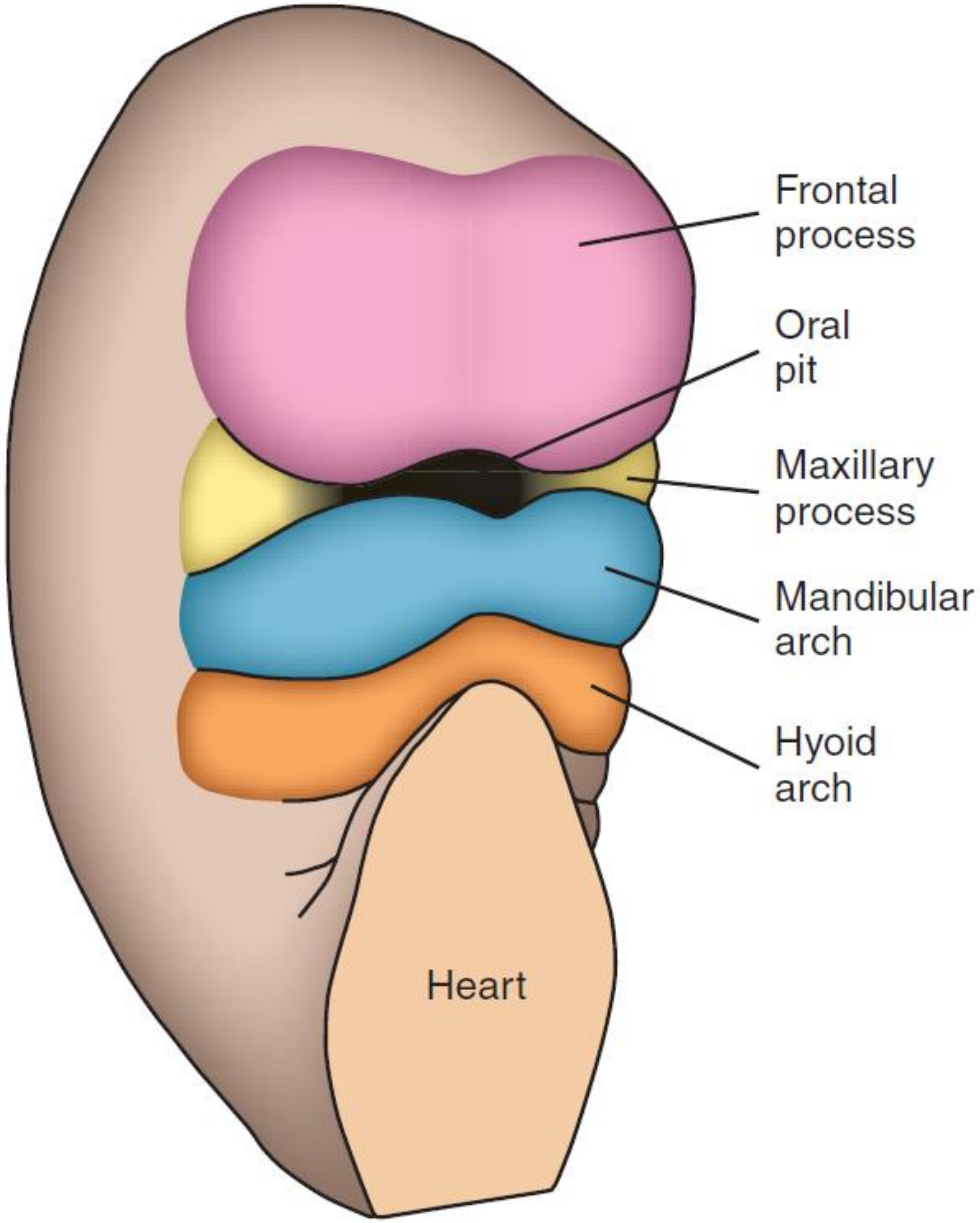

Development Of The Nasal Cavity

- ✓ Nasal development is instigated by the appearance of two ectodermal thickenings called **nasal placodes** on both sides of the frontonasal prominence.

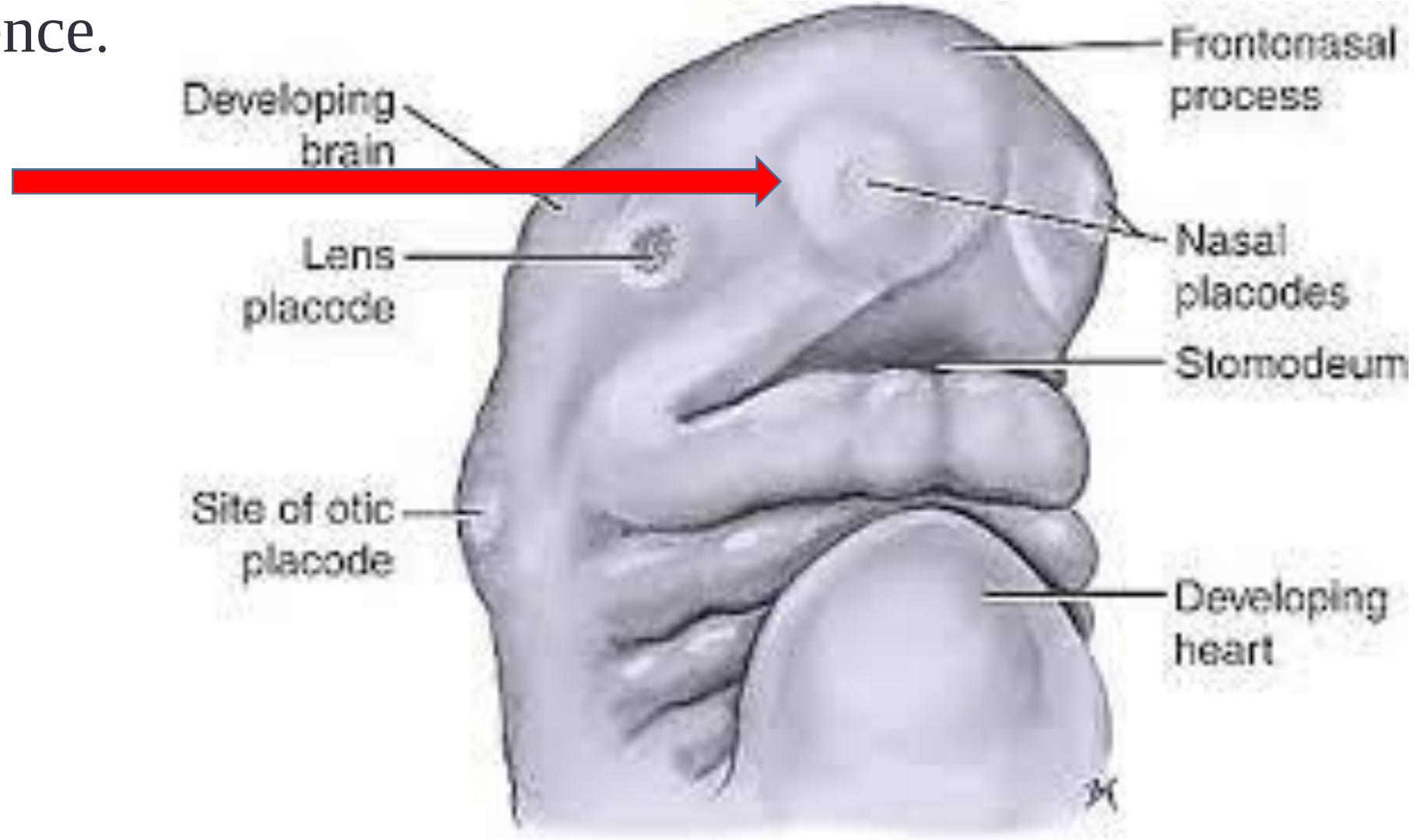

Development Of The Nasal Cavity

- ✓ These **nasal placodes** then invaginate to form **nasal pits**
- ✓ At the same time, mesodermal cells around the placodes will proliferate, and form a medial and lateral nasal prominences for each placode.

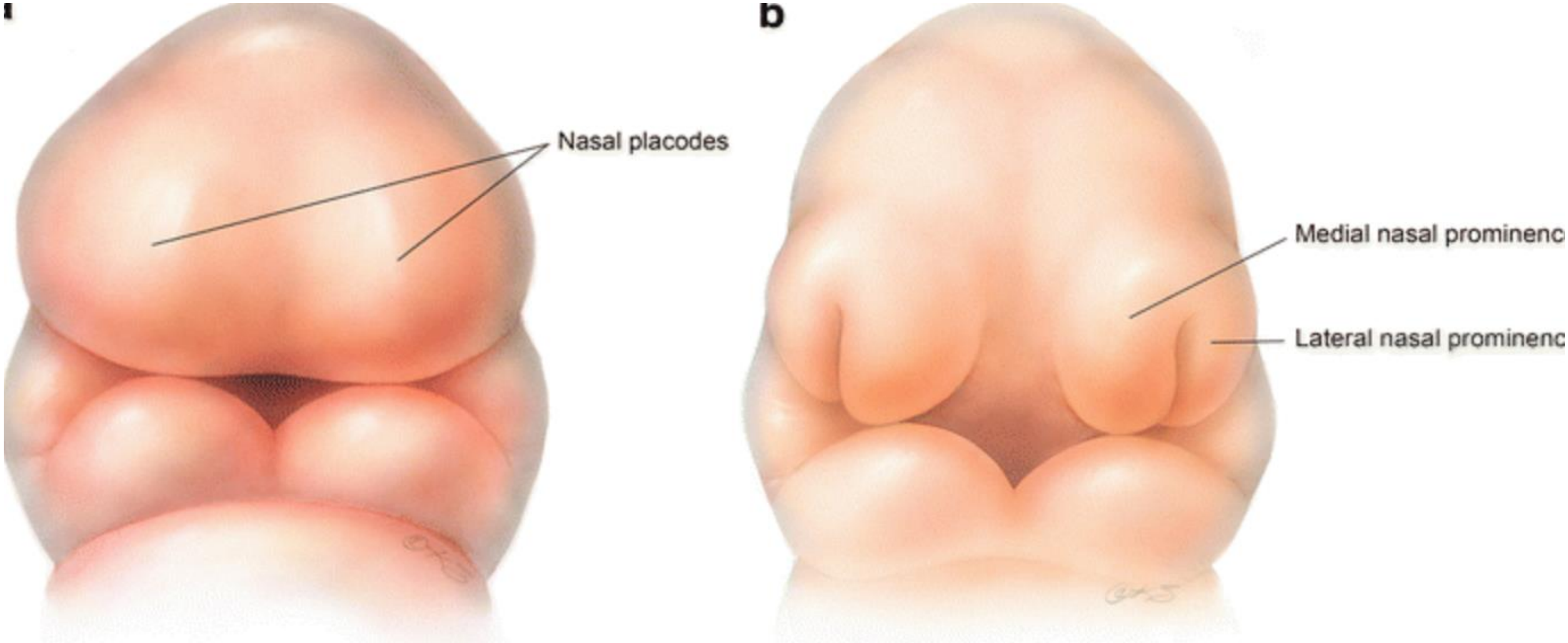

Development Of The Nasal Cavity

- ✓ The 2 medial nasal prominences will fuse to form the **median nasal process**, which fuses with the 2 maxillary prominence, giving rise to a **smooth upper lip**.
- ✓ The lateral nasal prominence gives rise to the **alae of the nose**, and fuses with the maxillary prominence, forming the **nasolacrimal duct**. This duct is formed when the ectoderm thickens into a cord and sinks into the underlying mesenchyme.

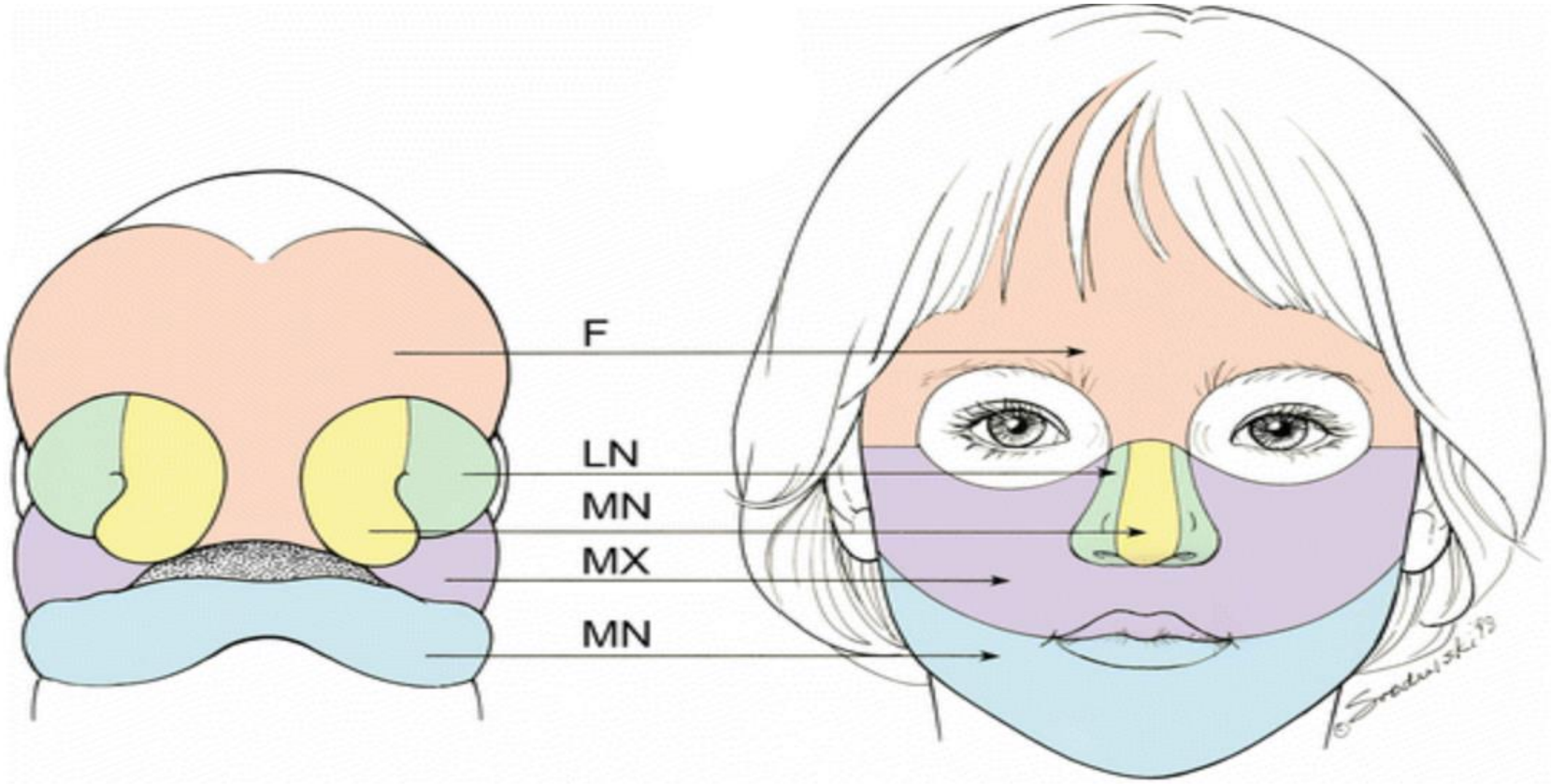

Development Of The Nasal Cavity

- ✓ The mandibular prominence on each side will grow and fuse to form the lower lip and jaw

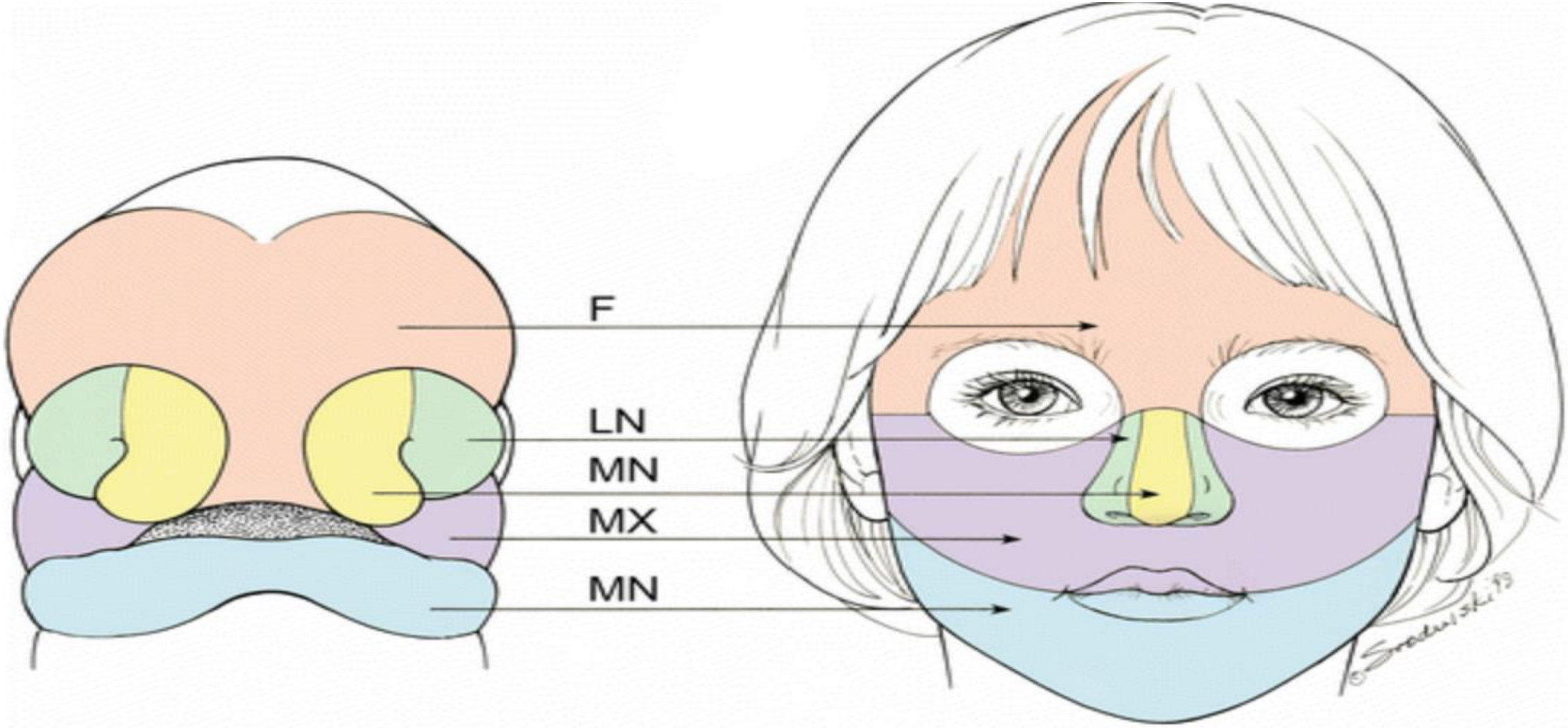

Development Of The Nasal Cavity

- ✓ The **nasal pits** deepen and develop the **nasal sacs** which grow dorsocaudally in front of the forming brain.
- ✓ In the beginning, the nasal sacs are separated from the oral cavity by the **oronasal membrane**.
- ✓ This membrane disappears in the 7th week leaving a connection between the nasal cavities and the oral cavity, called the **primitive choanae**.
- ✓ Later, when the development of the secondary palate occurs, the choanae changes its position and locates at the **junction of the nasal cavity and the pharynx**.
- ✓ The **nasal septum** grows as a down growth from the **merged nasal prominences** and fuses with the palatine process.

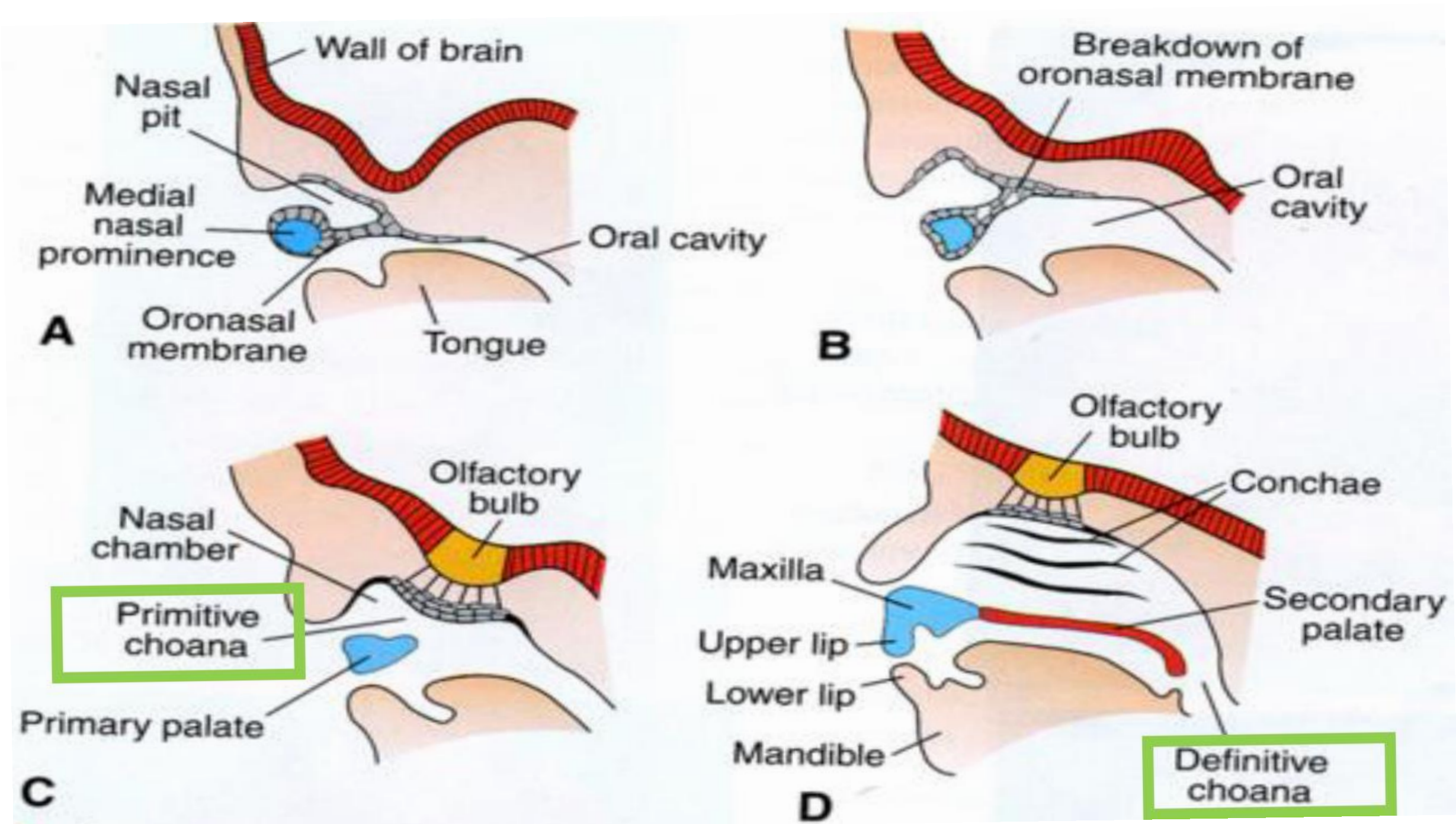
Wall of brain
Nasal pit
Medial nasal prominence
Oral cavity
Oronasal membrane
Tongue
A
Breakdown of oronasal membrane
Oral cavity
B
Olfactory bulb
Nasal chamber
Primitive choana
Primary palate
C
Olfactory bulb
Conchae
Maxilla
Secondary palate
Upper lip
Lower lip
Mandible
Definitive choana
D

The Inter-maxillary Segment

- ✓ Is formed from the fusion of the paired medial nasal prominences and the maxillary prominences, as the maxillary prominences expand medially, the nasal prominences are ‘pushed’ closer to the midline which fuse establishing the intermaxillary segment that gives:

a- The portion of the upper lip containing the philtrum

b- The upper jaw with 4 incisors

c- The primary palate.

The Inter-maxillary Segment

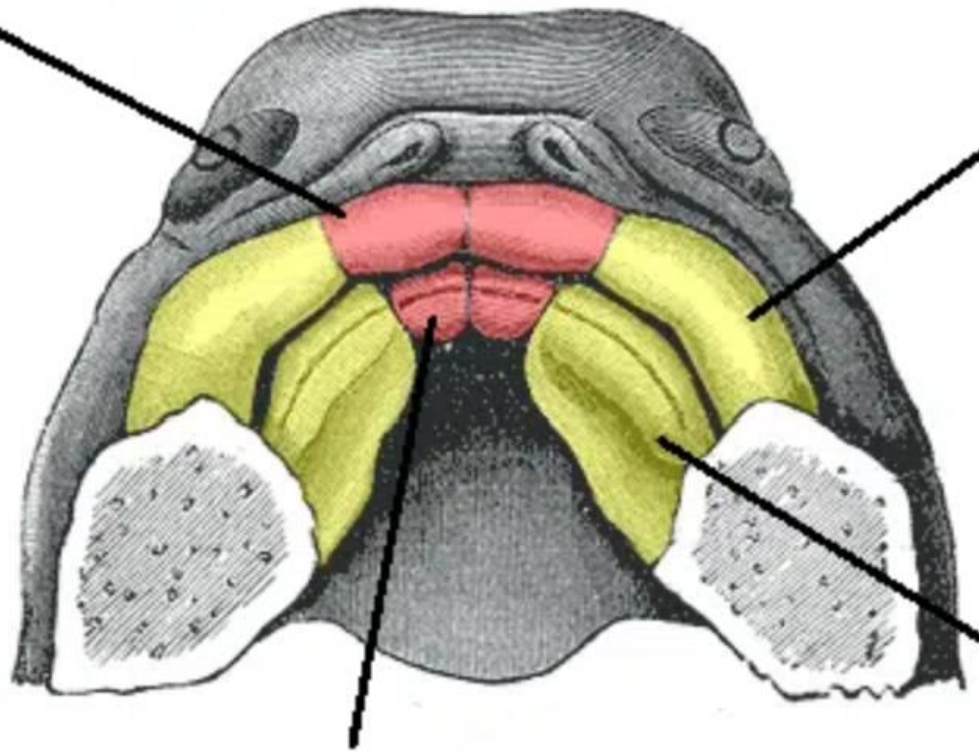

The Inter-maxillary Segment

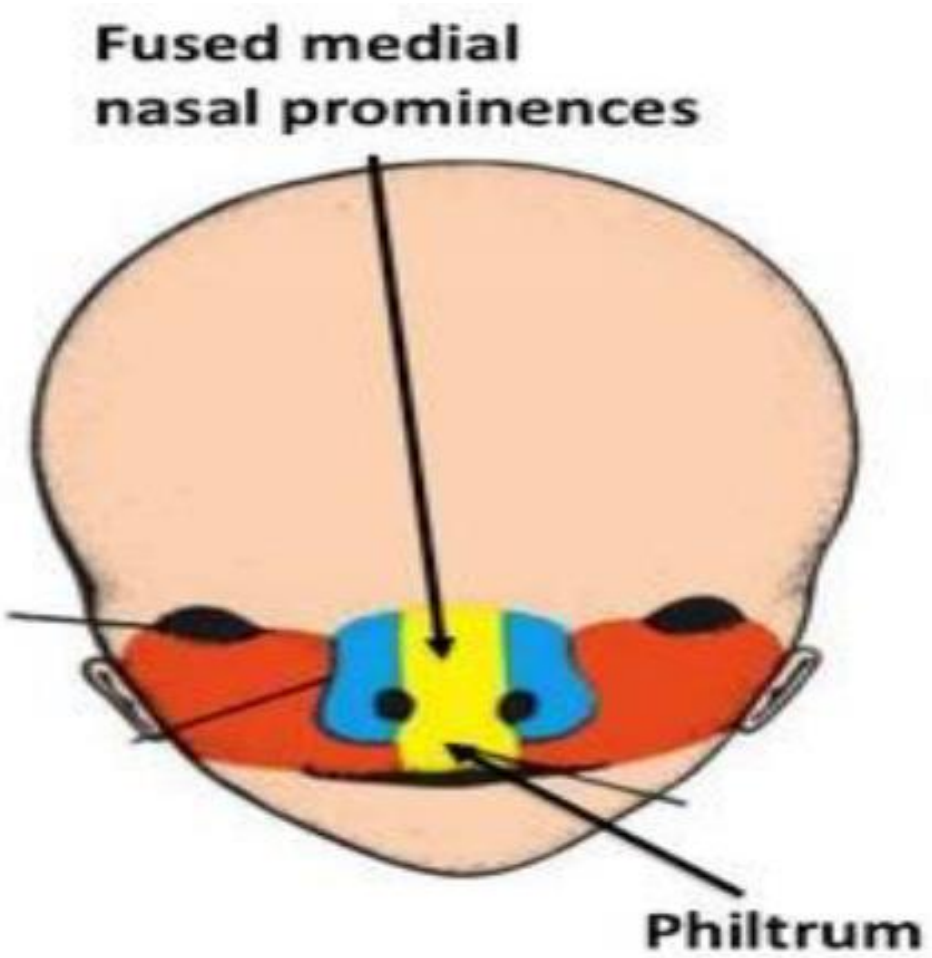

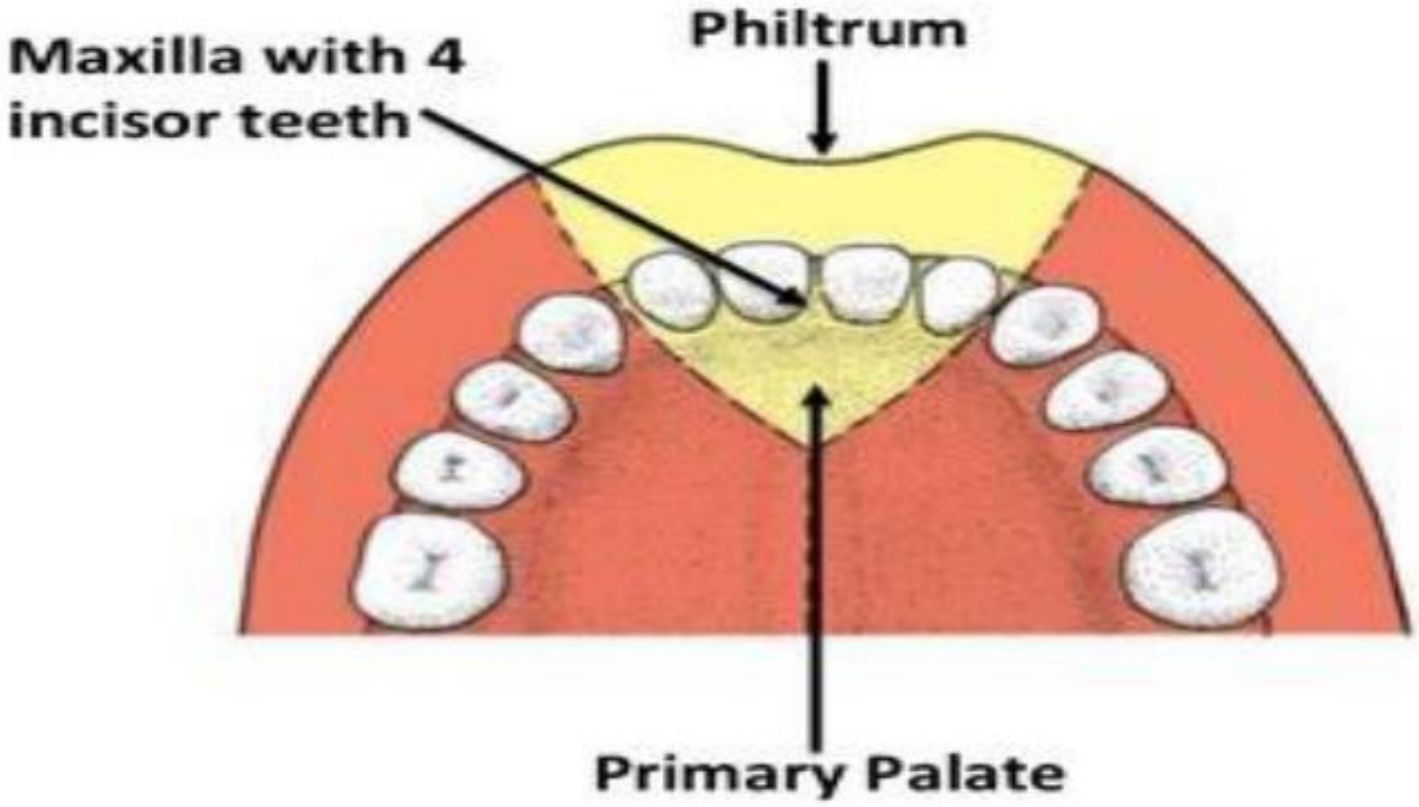

The Cheeks

- ✓ After formation of the upper and lower lips, the stomodium is very broad.
- ✓ In it’s lateral parts, it is bounded above by the maxillary process & below by the mandibular process which undergo progressive fusion with each other to form the cheeks.

The Nasal Fin

- ✓ The epithelial coverings of the **medial nasal** and **maxillary** processes normally contact and create a zone of fusion termed the **nasal fin**.
- ✓ This epithelial fin is soon **penetrated by connective tissue** growth, which binds together the two maxillary and medial nasal parts of the lip.
- ✓ If this penetration were not to occur, the lip could **pull apart**.
- ✓ Soon the **orbicularis oris muscle** grows around the oral pit to provide support to the upper lip.
- ✓ As mentioned, the nasal pits continue behind the nasal fin to open into the roof of the mouth.

The Nasal Fin

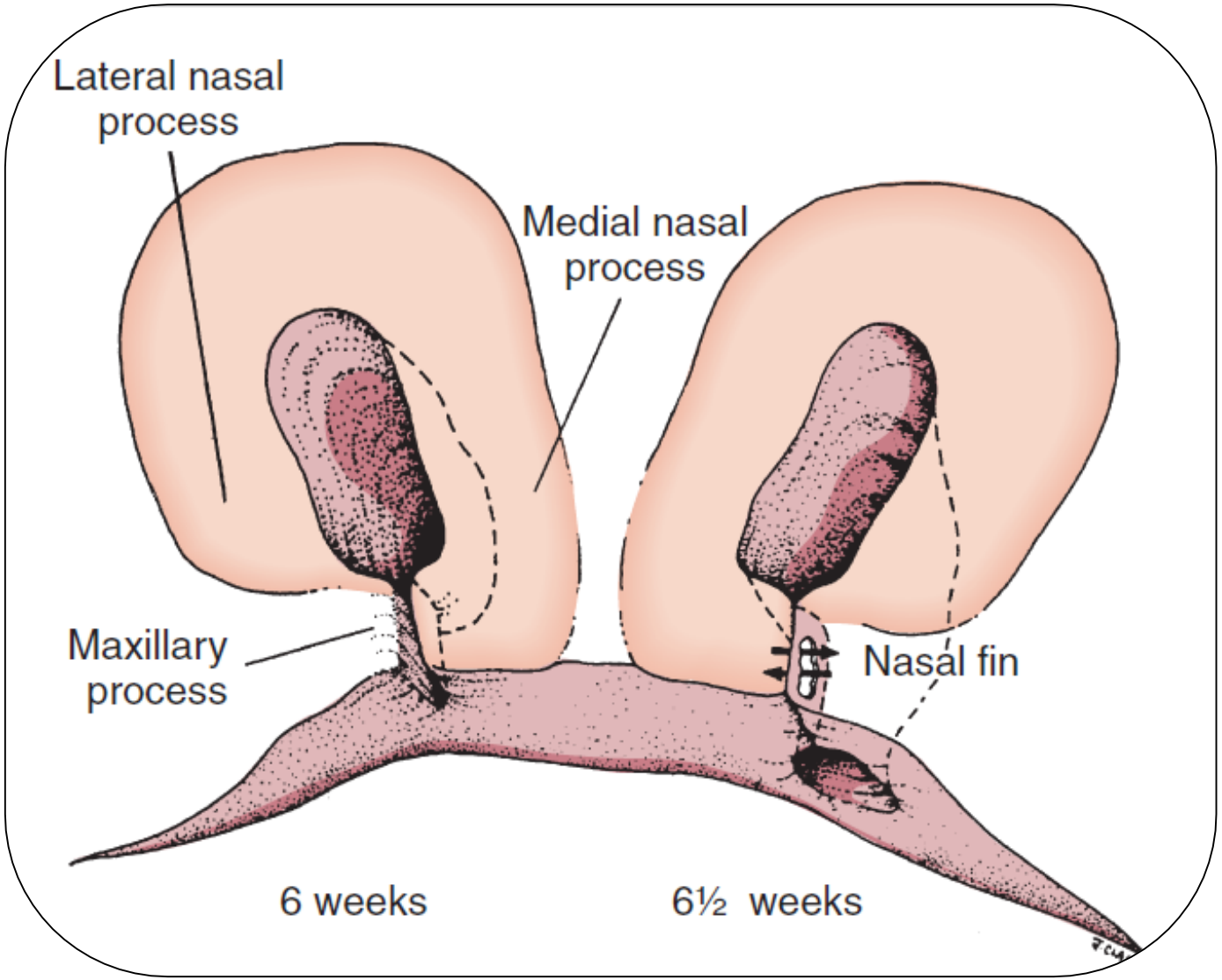



Derivatives Of Facial Components

The Prominence	Structures they will form
Frontonasal prominence	Forehead, bridge of the nose, Frontal and nasal bones
Maxillary prominences	Upper cheek, most of the upper lip, Maxilla, zygomatic bone, secondary palate
Mandibular prominences	Fuse to form Chin, lower lip lower cheek, and mandible
lateral nasal prominences	Alae of the nose
medial nasal prominences	Intermaxillary segment
lateral nasal processes with the maxillary prominences	Nasolacrimal canal

Derivatives Of Facial Components

