Embryology

Dr Mayyadah Hameed Rasheed

BDS, MSc, PhD

Oral Medicine

Ashur University, College of Dentistry

✓ Embryology:

Gametes, fertilization, embryos, fetuses, congenital disorders

Male gamete

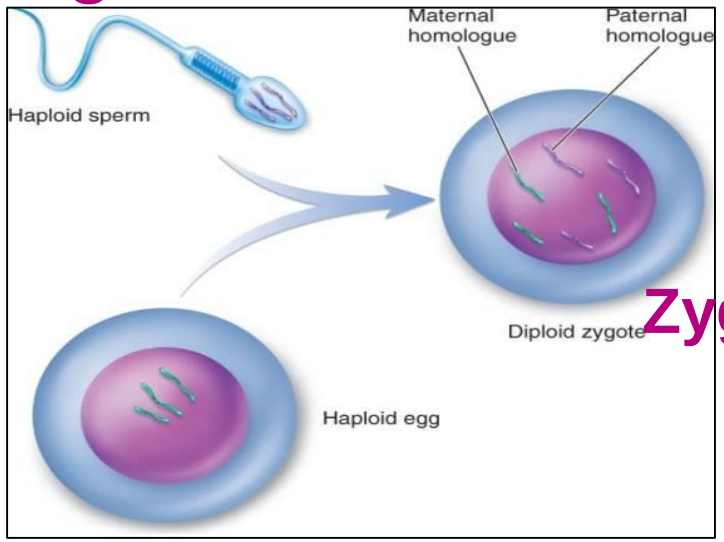

Zygote

Female gamete

Egg (mature)

Oogenesis

Oocyte

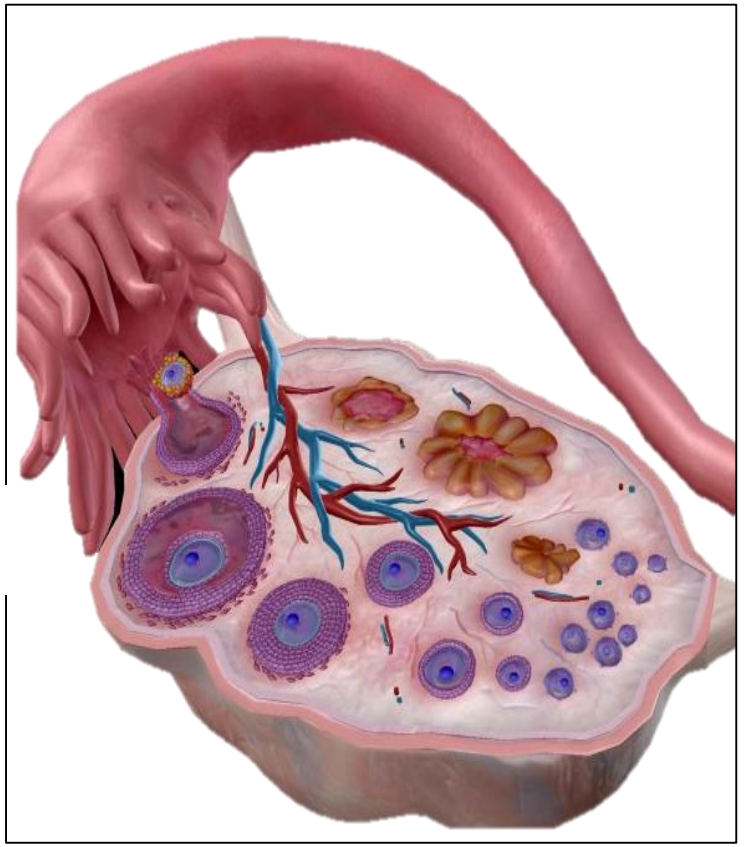

- ✓ **Before birth**
- ✓ **400,000**
- ✓ **Folliculogenesis 𝒱𝓈 spermatogenesis**

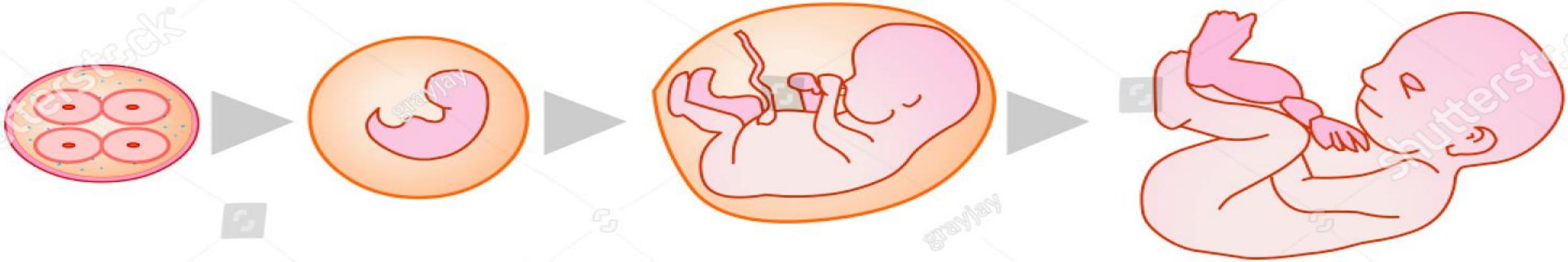

Zygote Embryo Fetus Baby

8 weeks **9 weeks** **Birth**

9 months = 38 weeks

Menstrual cycle = 28 days

Degenerates
2 weeks after
ovulation

Not fertilized

Ovulation
only 1
14th – 16th

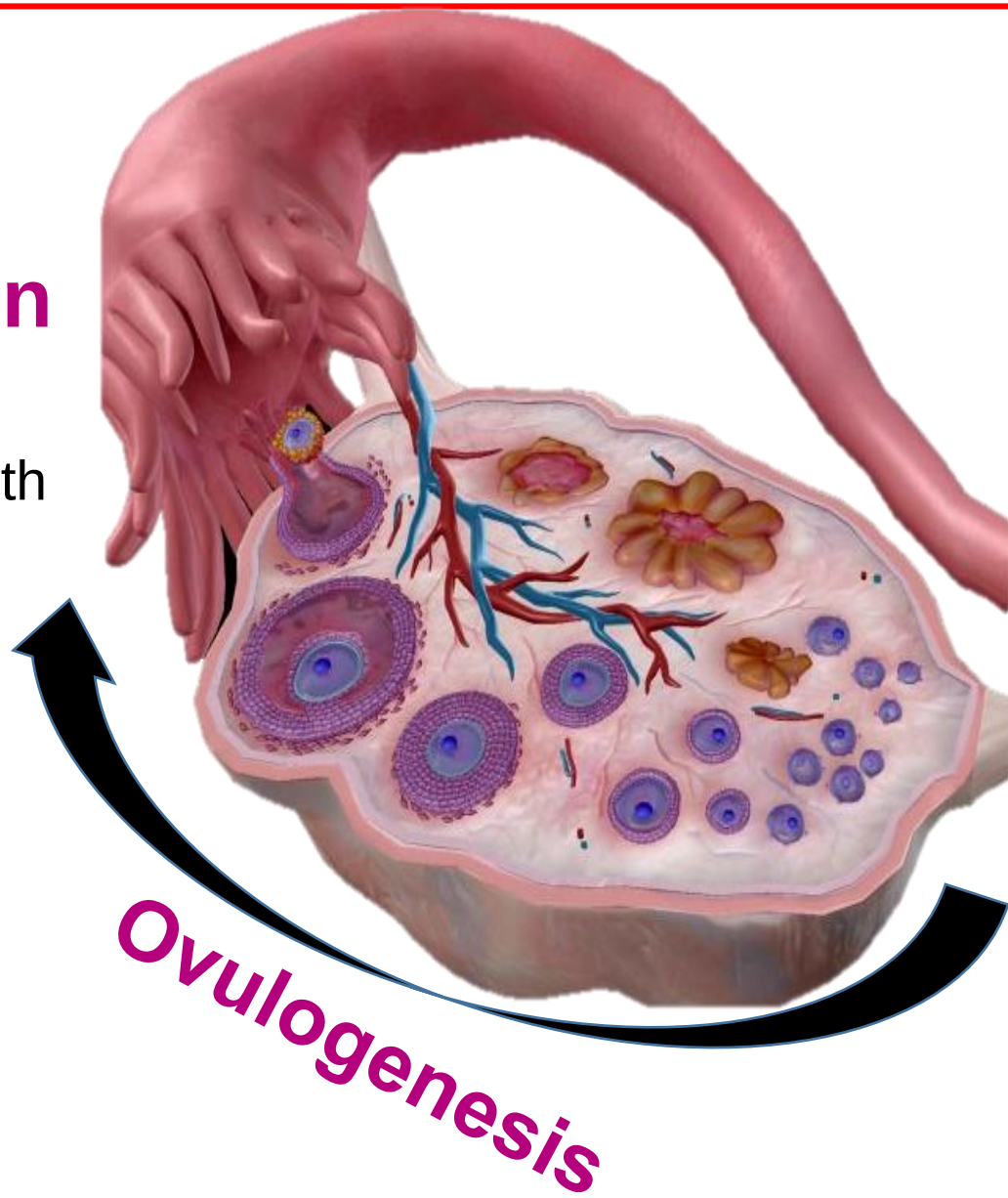

Capsule of cells = follicle

Folliculogenesis

- ✓ Wall thickens
- ✓ Fluid
- ✓ Graafian follicle
- ✓ Migrates
- ✓ Bulging locally
- ✓ Rupture

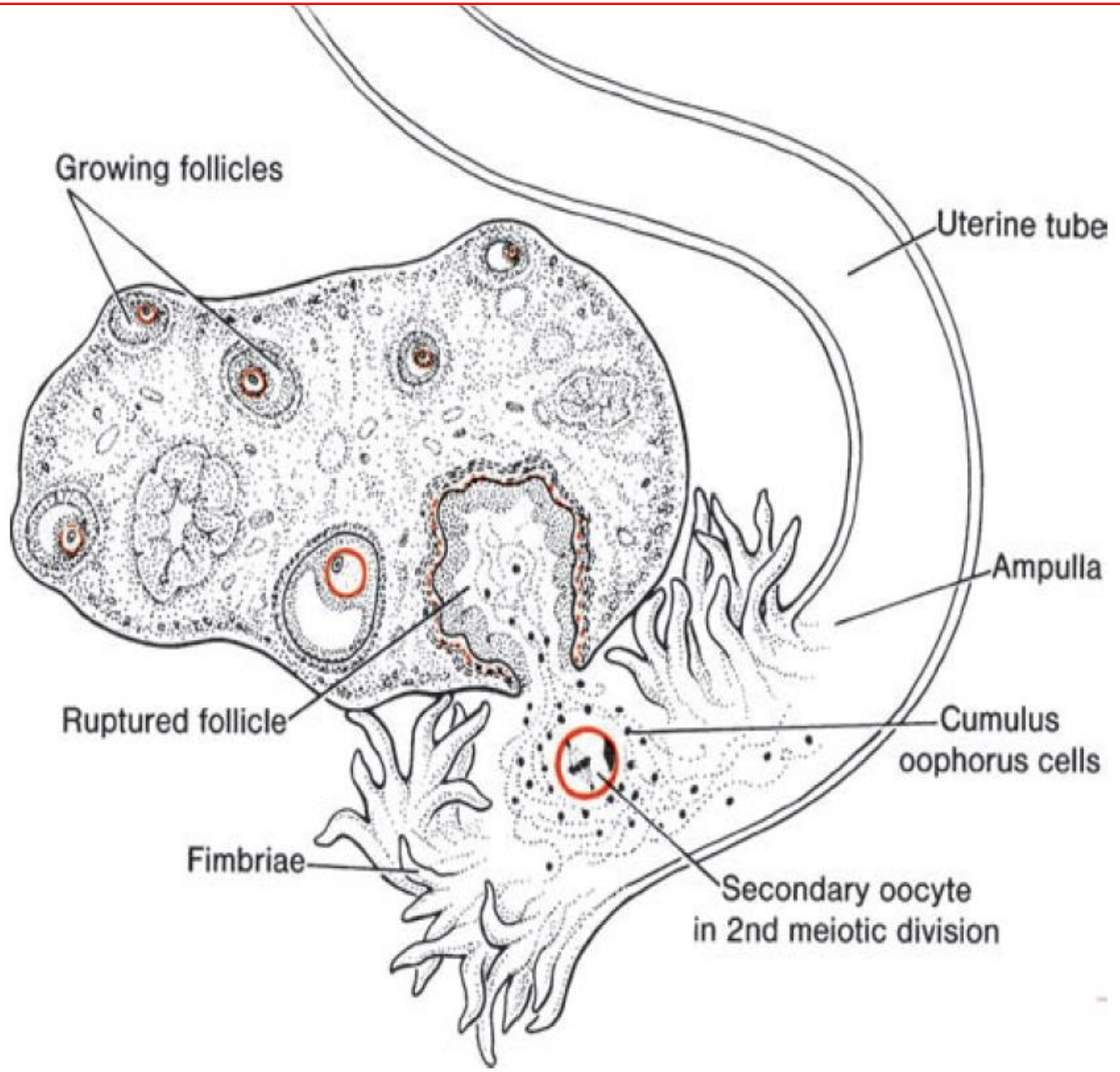

Menstrual cycle = 28 days

1
Mature

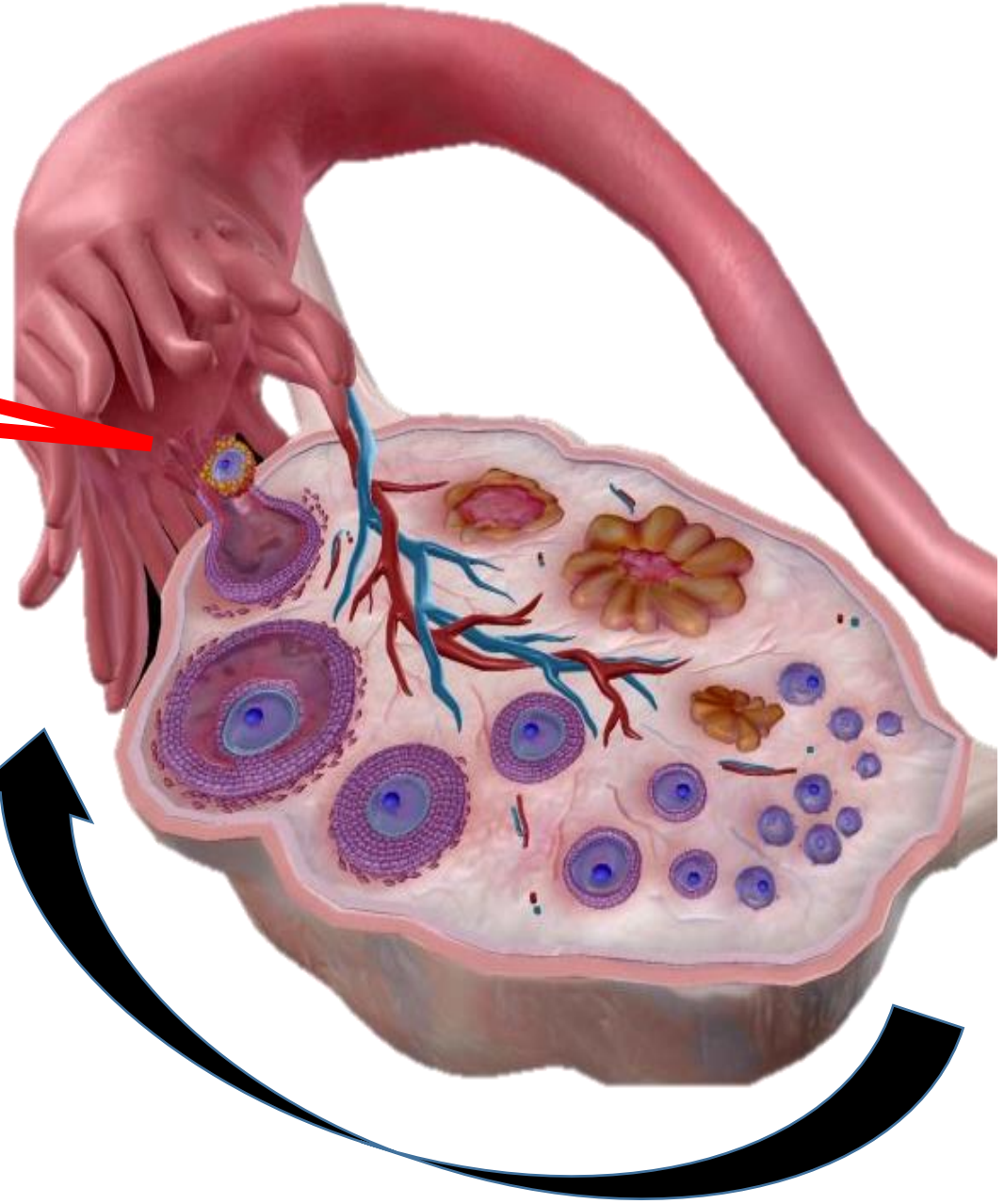

Others
follicular atresia

15 - 20
follicles are
stimulated
to grow

Egg
Fluid
Cells

Fallopian tube fimbriae

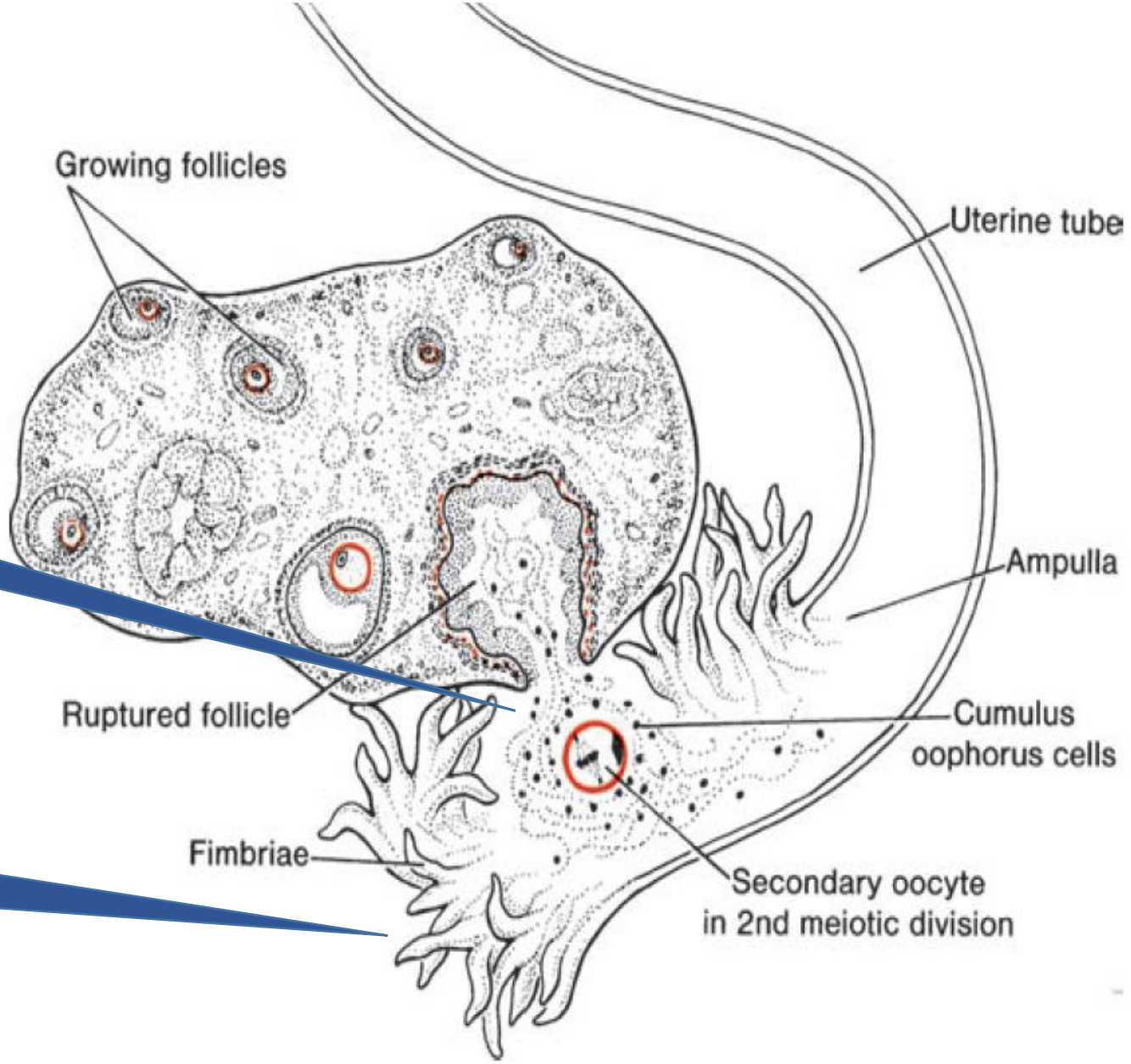

The oocyte is covered by the **zona pellucida** (transparent, porous, glycoprotein coat) and one or more layers of follicular cells which radially arrange themselves as the **corona radiate.**

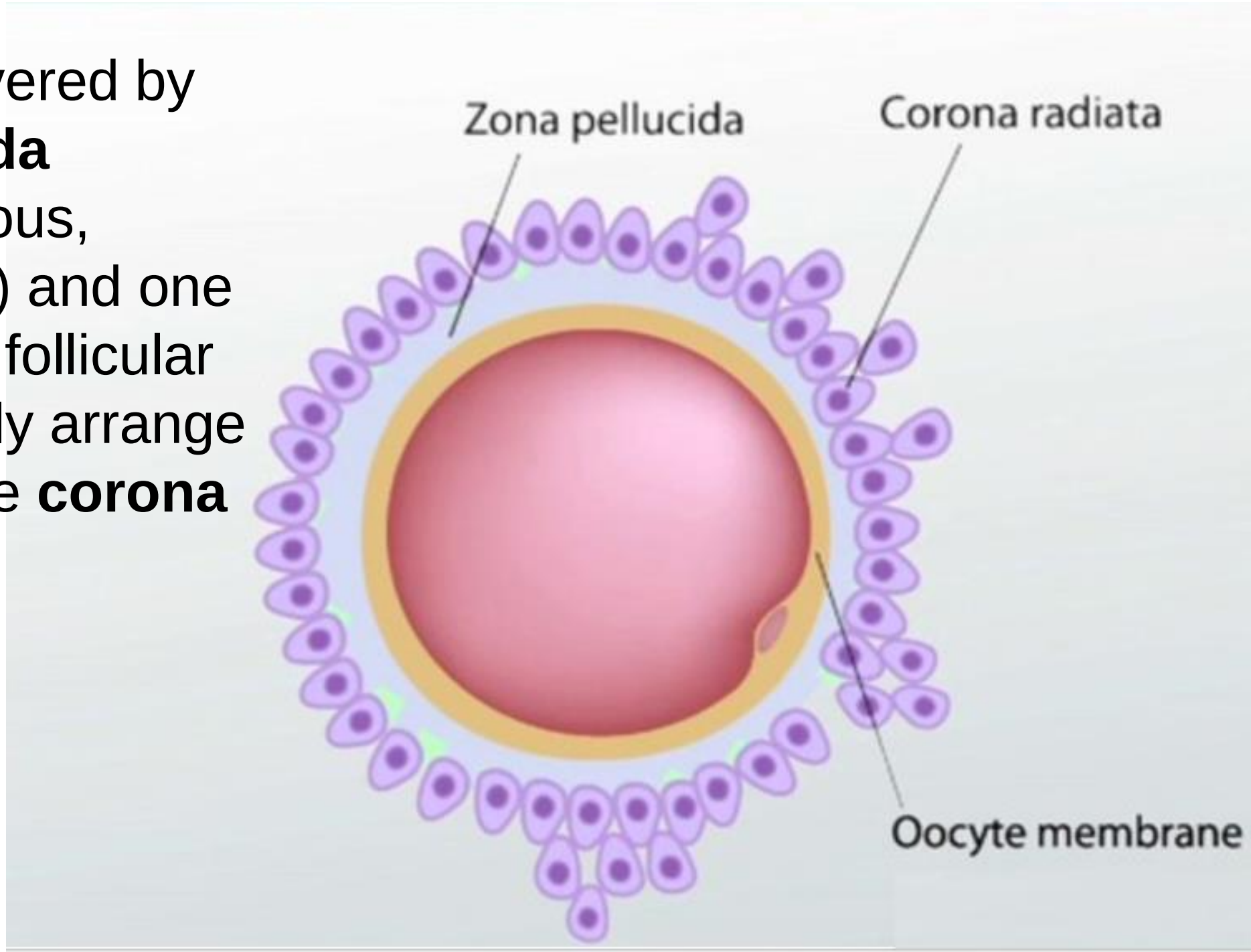

Corpus albicans
fibrotic scar

Fully mature
yellowish projection

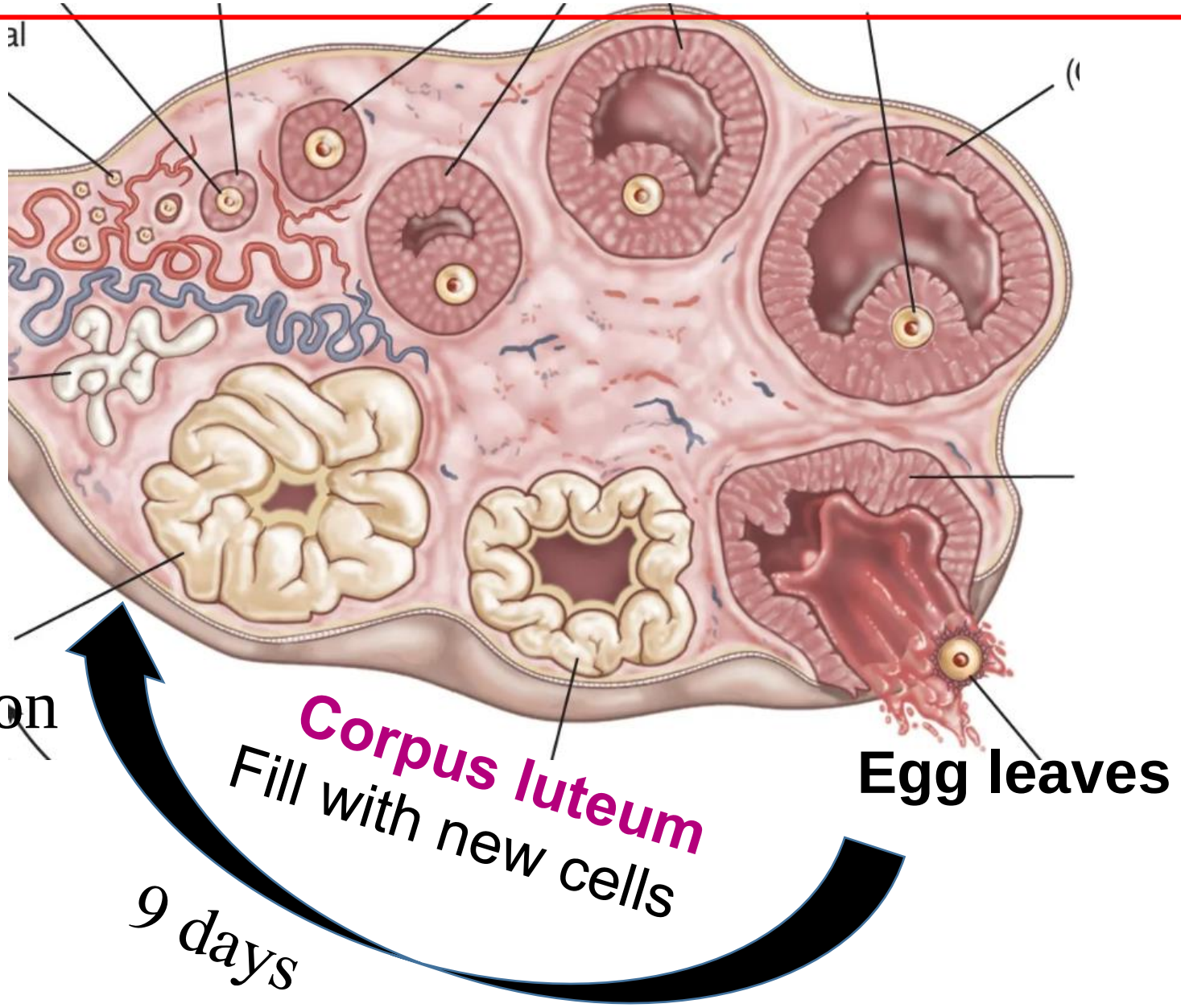

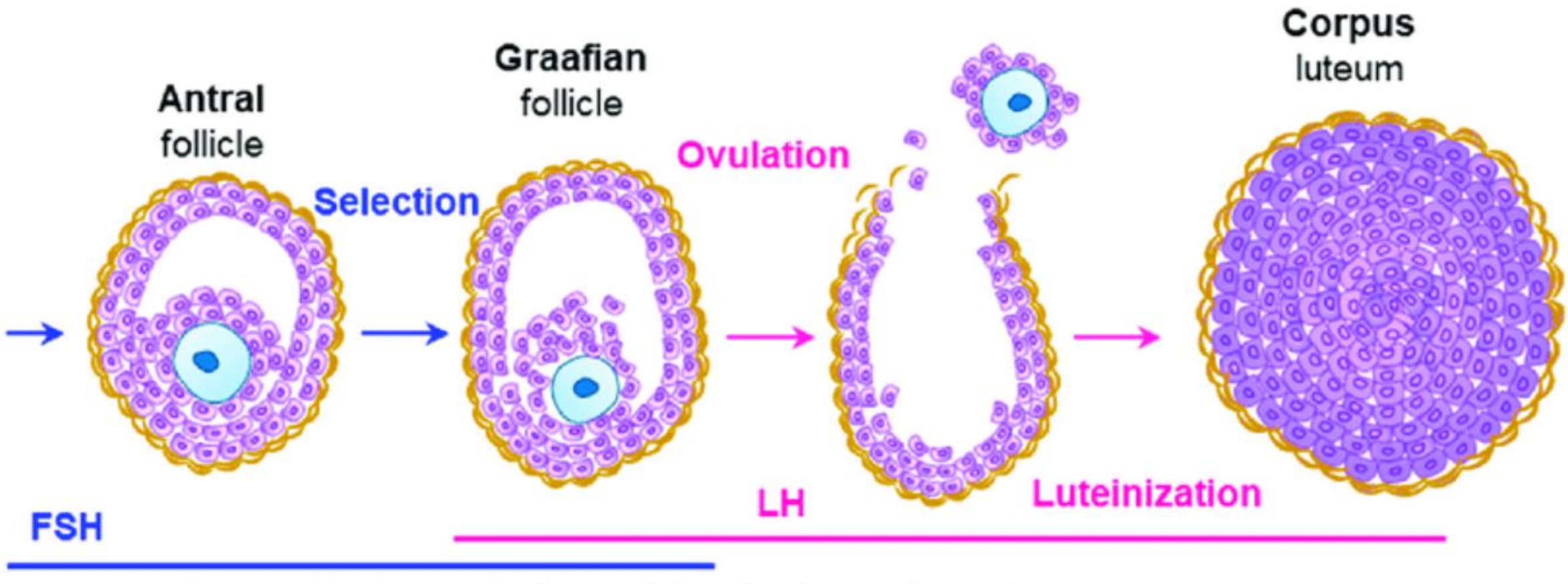
Antral
follicle
Selection
Graafian
follicle
Ovulation
Corpus
luteum
FSH
LH
Luteinization

Hypothalamus

pituitary gland

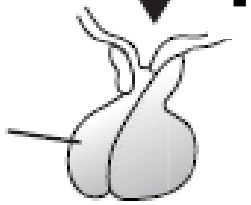

gonadotropins

follicle-stimulating FSH

LH luteinizing hormone

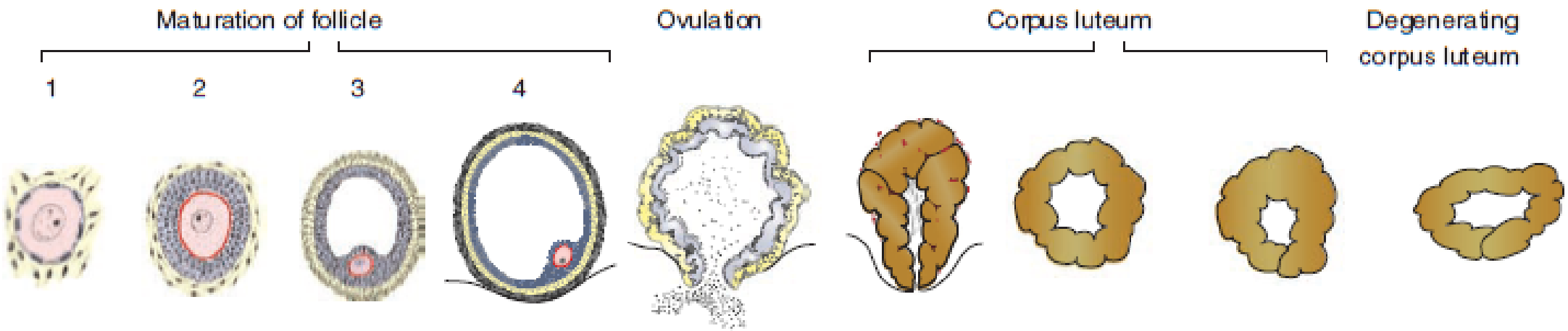

If egg fertilized:

1st : Corpus luteum **As** (Temporary endocrine gland)

↓

Progesterone **to** (keep the uterine wall receptive)

↓

endometrium gets thicker and
is well supplied with blood vessels

Then: Placenta → Until the child birth.

Progesterone blocks hormones from the pituitary gland →
No further ovulation during pregnancy.

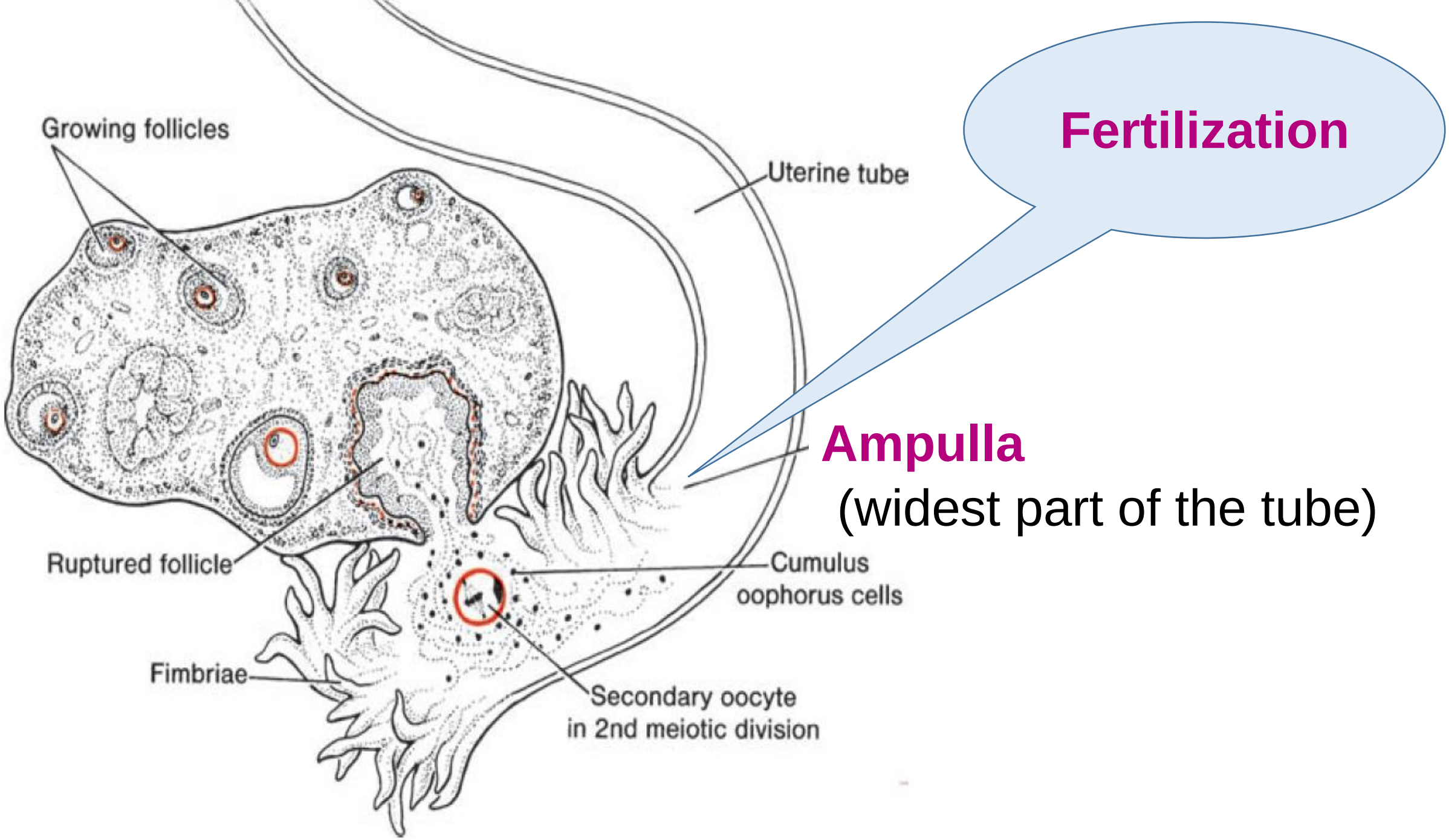

Fertilization

Ampulla

(widest part of the tube)

1. Capacitation
2. Acrosome reaction

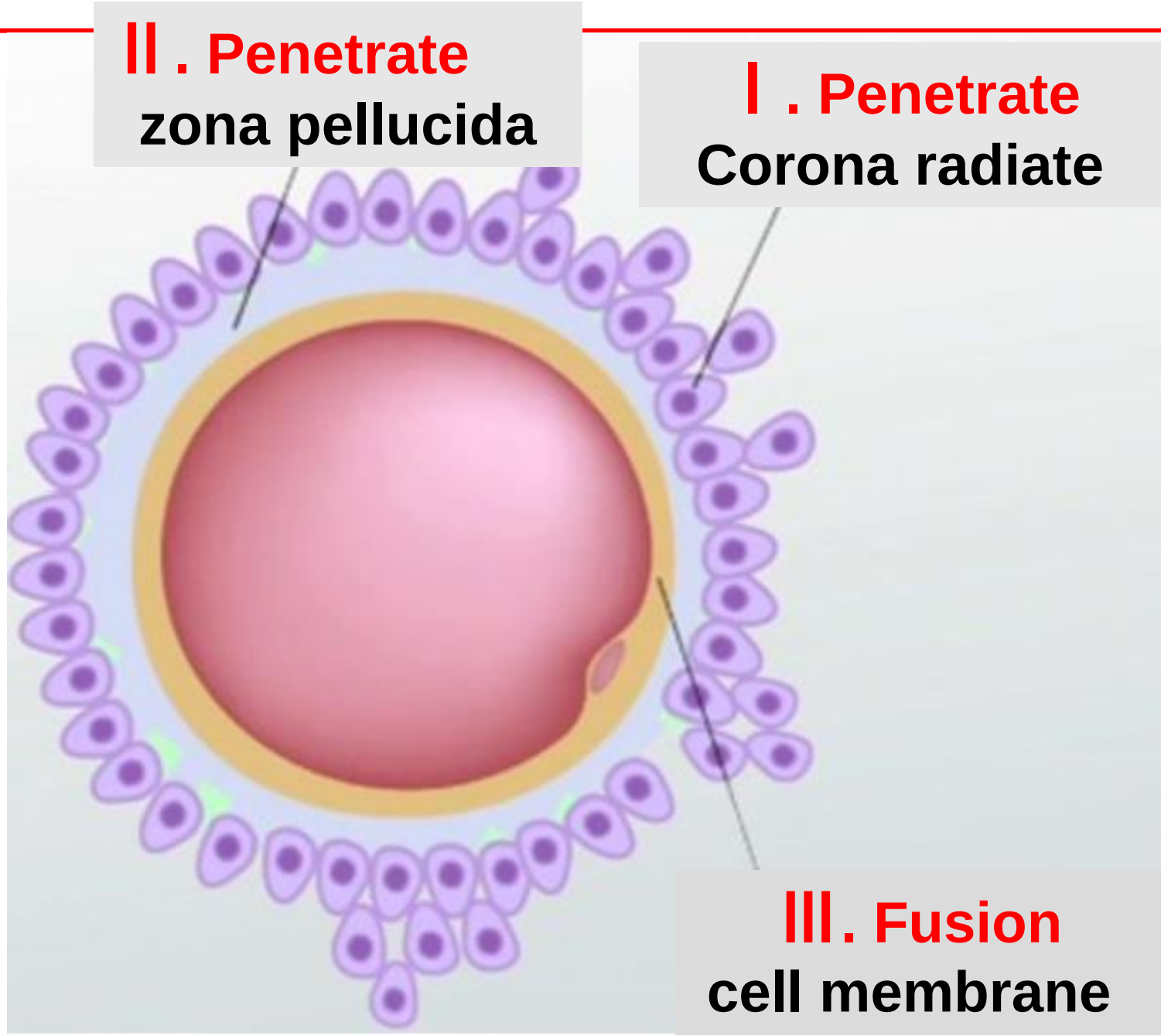

Results of fertilization

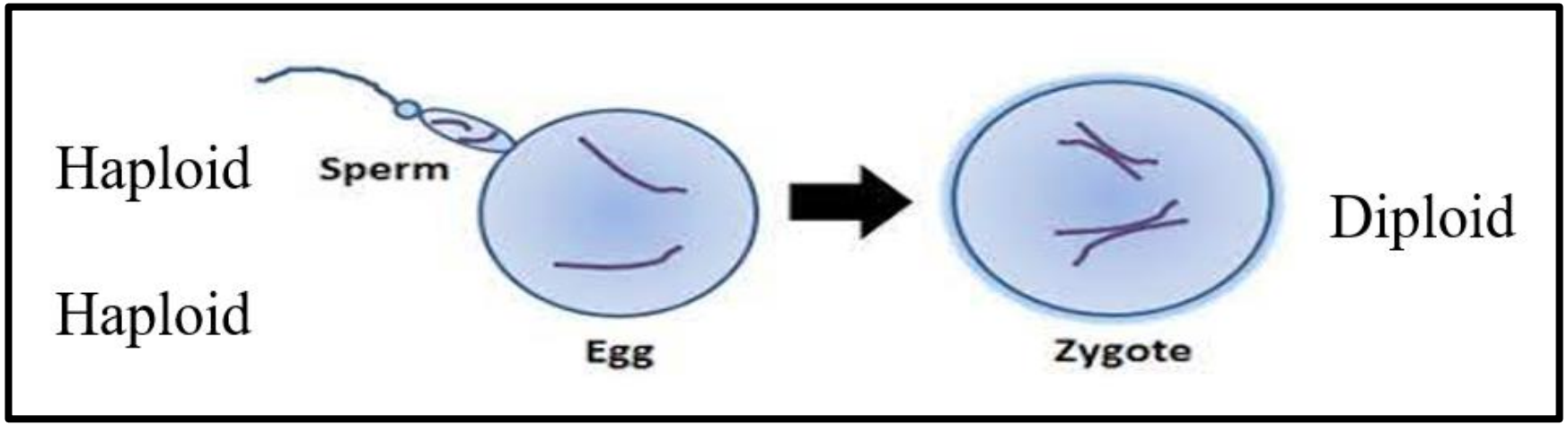

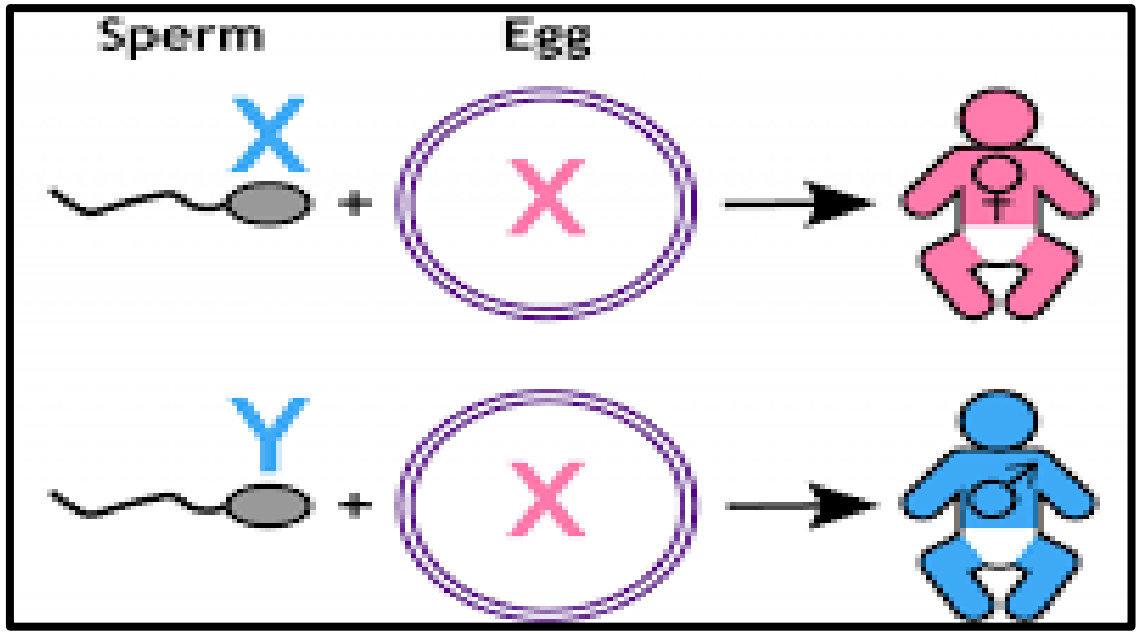

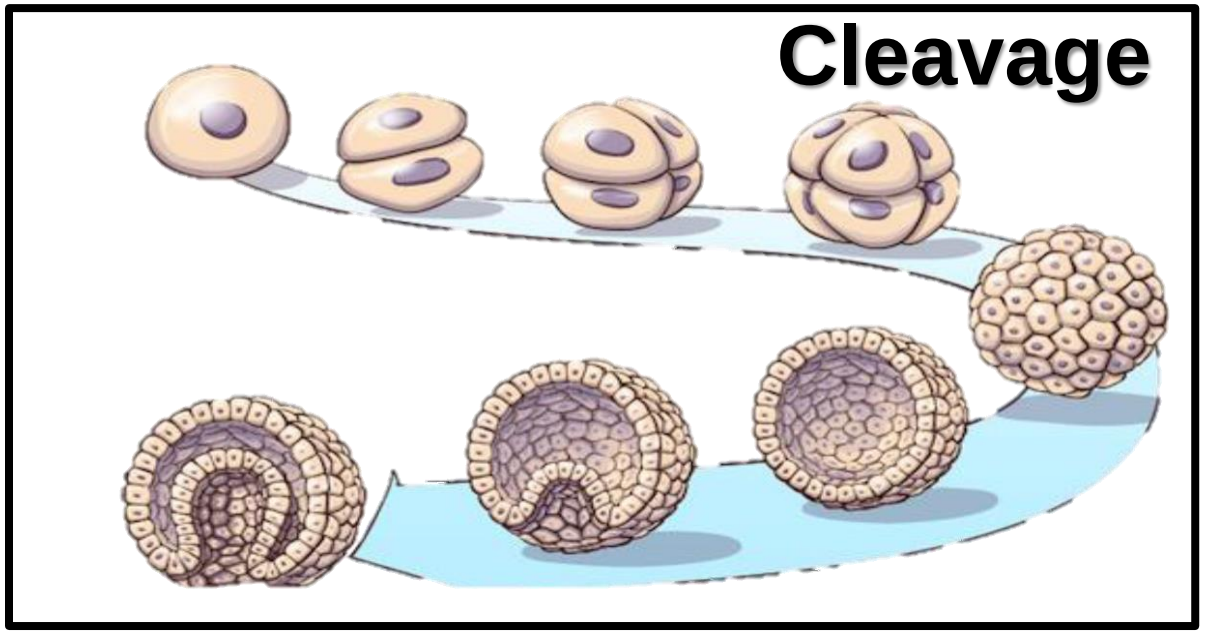

Cleavage ↑No. ↓Size

Zygote | **Blastomeres (loose)**

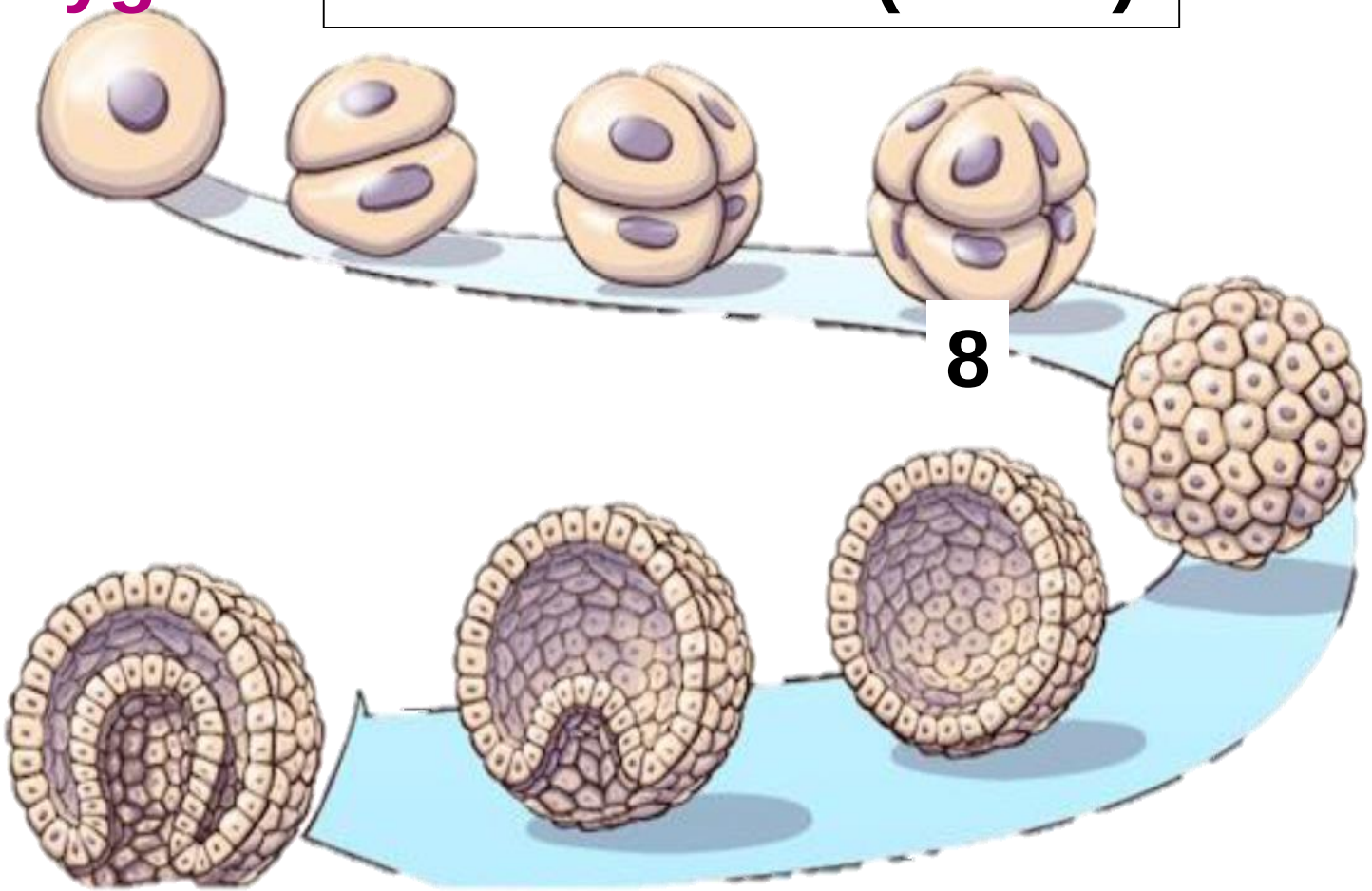

After 3rd = Compact ball
= 16 cell =**Morula.**

Cavitation = Blastocyst: inner + outer cell mass

Blastocyst

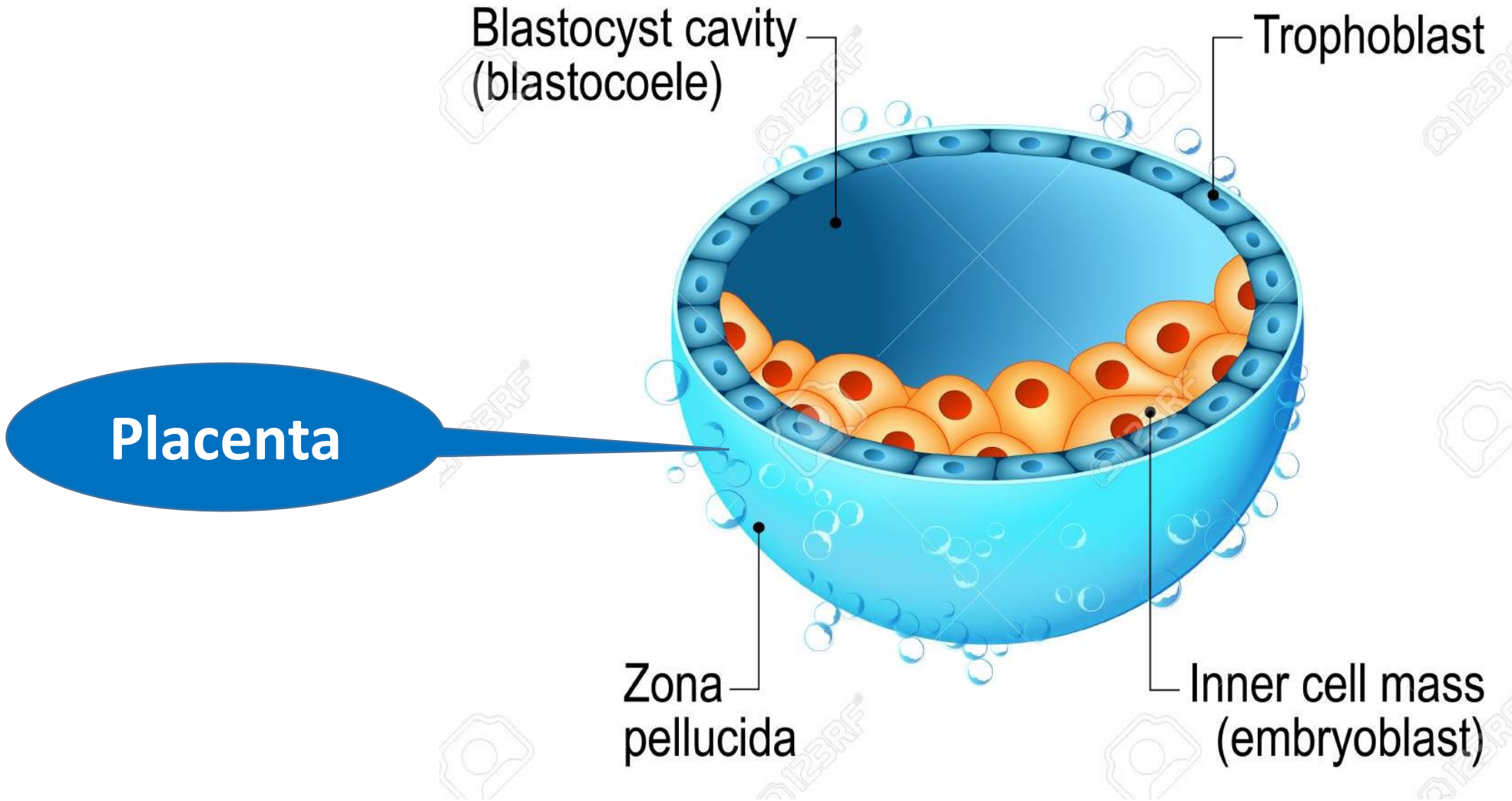
Blastocyst cavity
(blastocoele)
Trophoblast
Placenta
Zona
pellucida
Inner cell mass
(embryoblast)

blastocyst

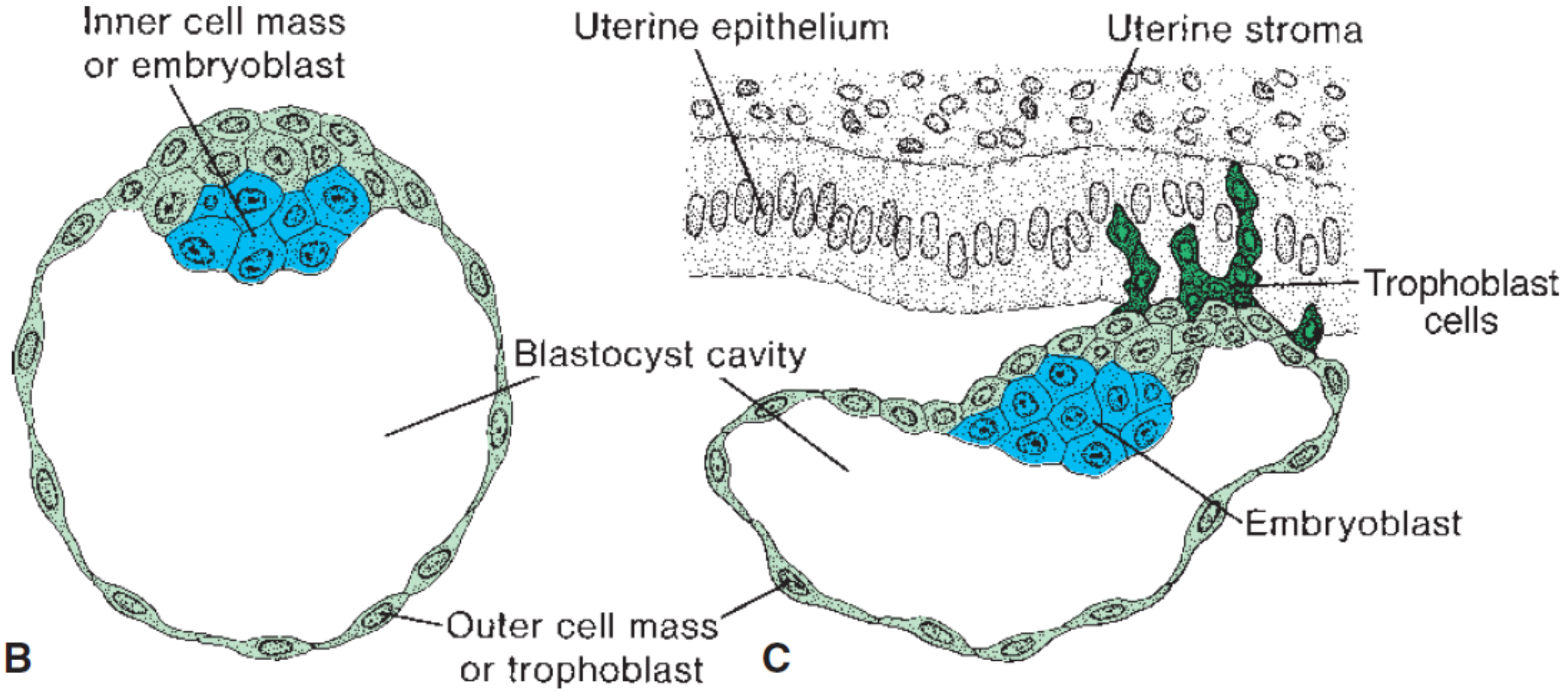
Inner cell mass
or embryoblast
Uterine epithelium
Uterine stroma
Trophoblast
cells
Blastocyst cavity
Embryoblast
Outer cell mass
or trophoblast
B
C