Embryology

Lecture 4

Pharyngeal Apparatus

Dr Mayyadah Hameed Rasheed
BDS, MSc, PhD
Oral Medicine

Dr Fatma Adnan Abdulkareem
BDS, MSc, PhD
Oral Medicine

Ashur University, College of Dentistry

Folding

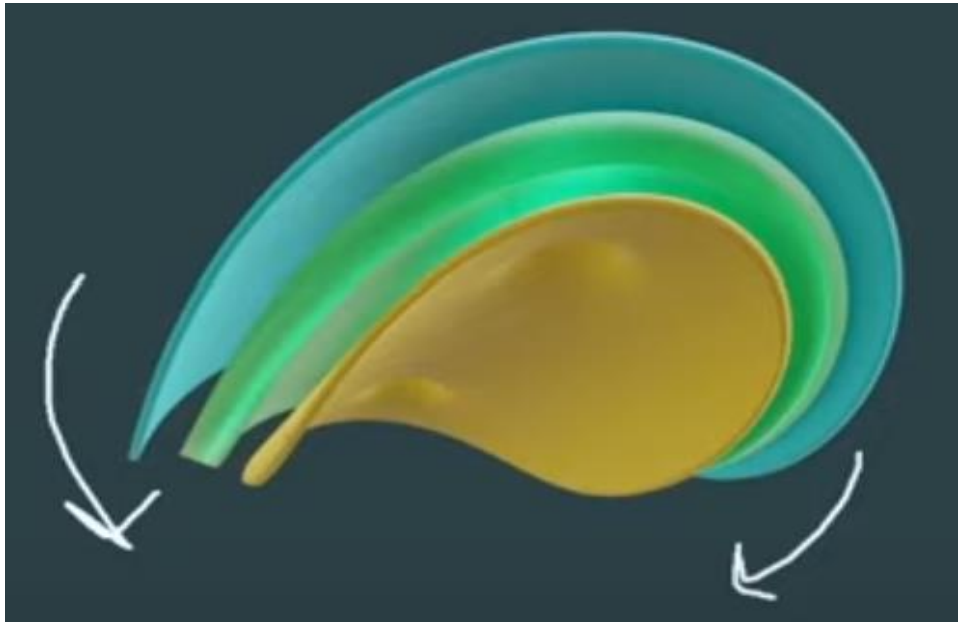



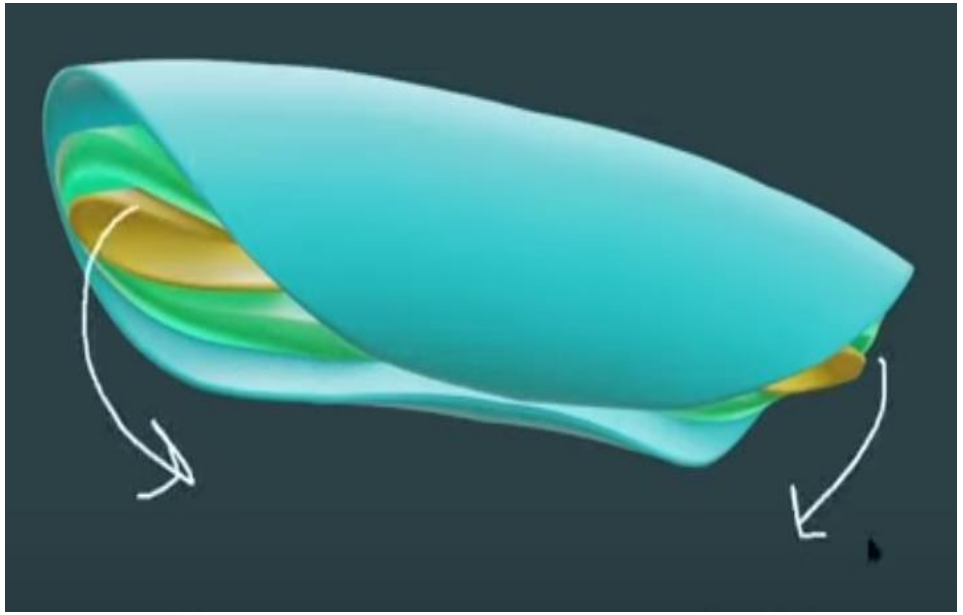

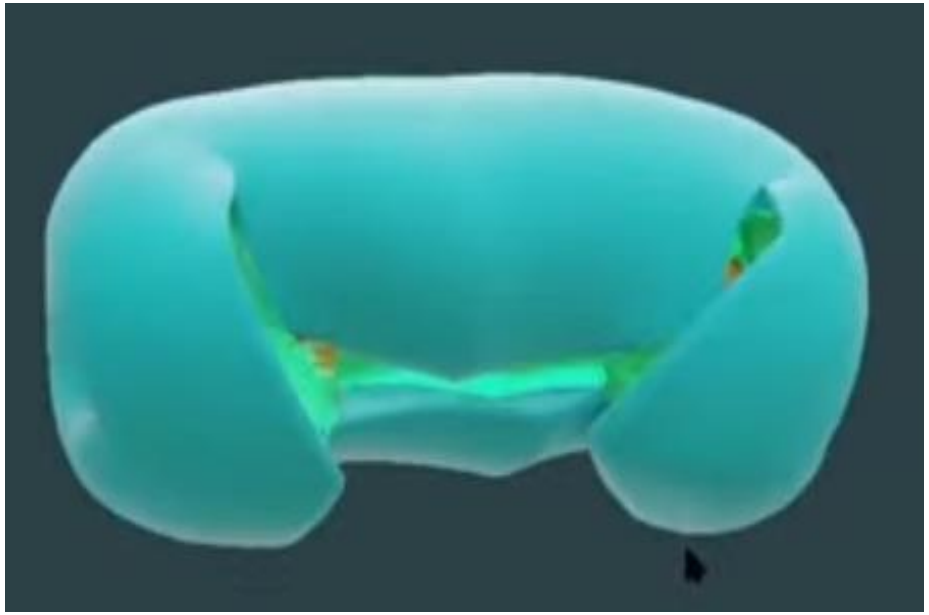

Embryonic Folding

The flat trilaminar embryonic disk becomes a more cylindrical embryo due to the longitudinal and transverse folding that occurs simultaneously.

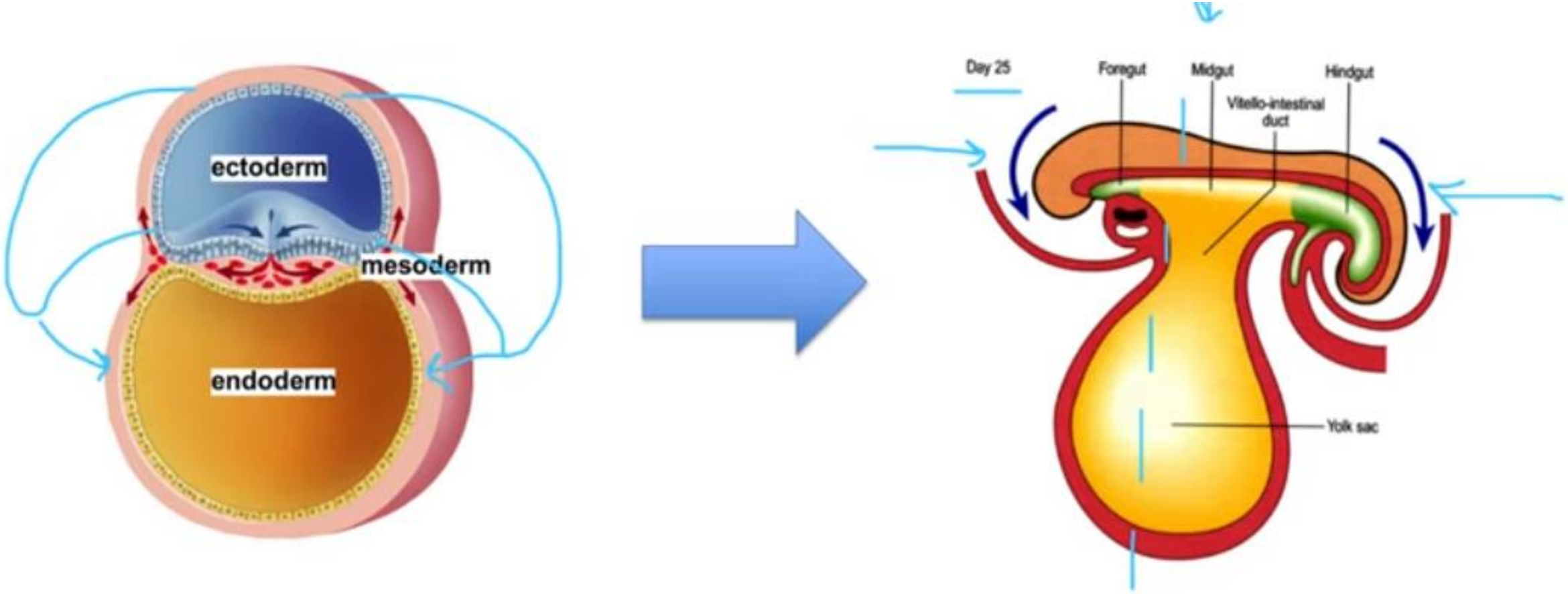

Mesoderm

Intraembryonic mesoderm

Extraembryonic mesoderm

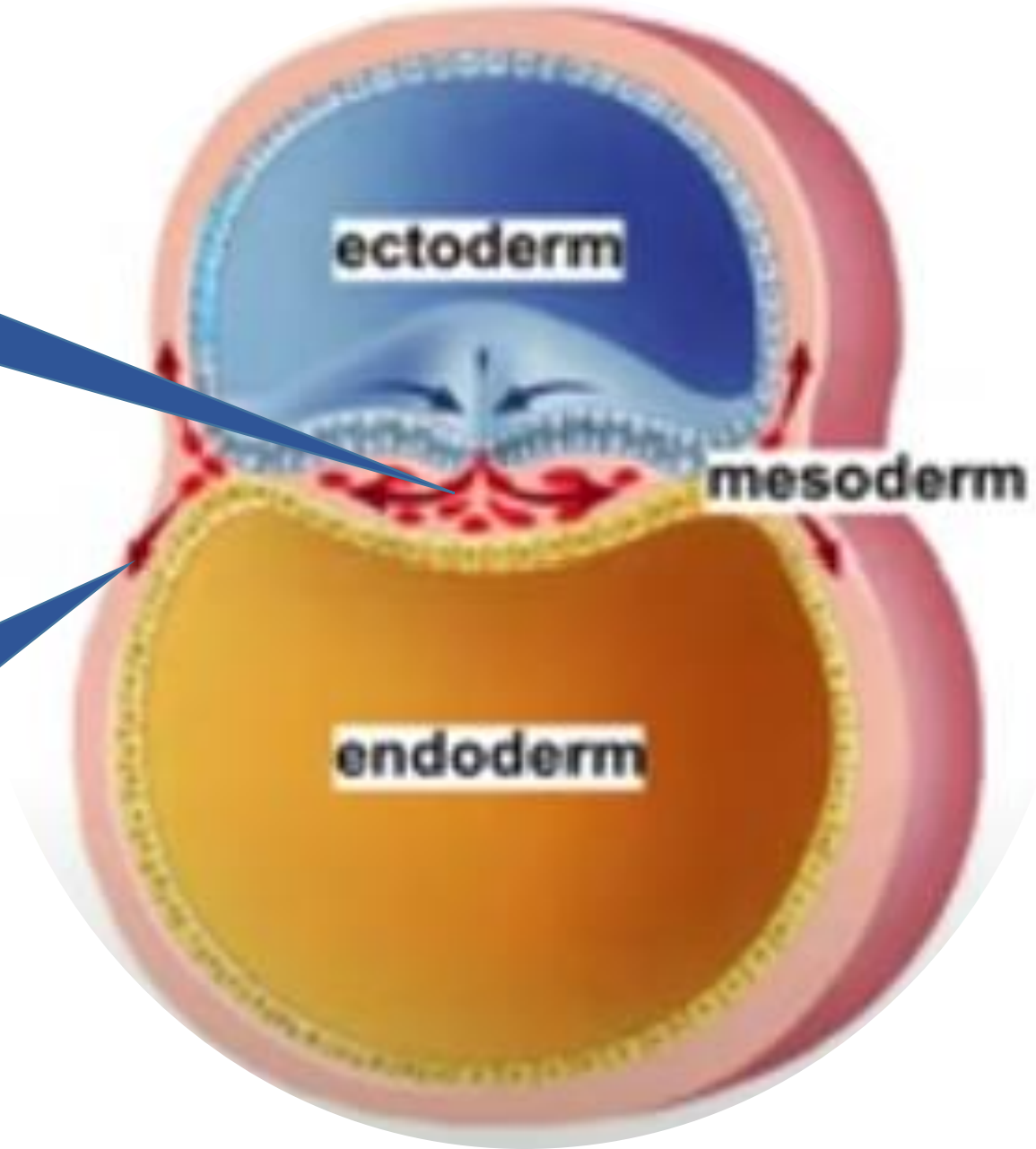

The Intraembryonic Mesoderm

The intraembryonic mesoderm is formed by proliferation of cells in the primitive streak and it separates the ectoderm and the endoderm.

As the notochord and neural tube developed, the intraembryonic mesoderm on each side of notochord forms three longitudinal columns which are:

1. Paraxial mesoderm: gives 42-44 pairs of somites. These somites further differentiate into 3 components:

a- Sclerotome (cartilage and bone)

b- Myotome (muscles)

c- Dermatome (dermis of skin)

2. Intermediate mesoderm: (gives kidneys & genital system)

3. Lateral mesoderm: differentiates into 2 layers which give many structures. The cavity between these two layers is the intraembryonic coelom (coelom is the body cavity that contains the internal organs).

The Intraembryonic Mesoderm

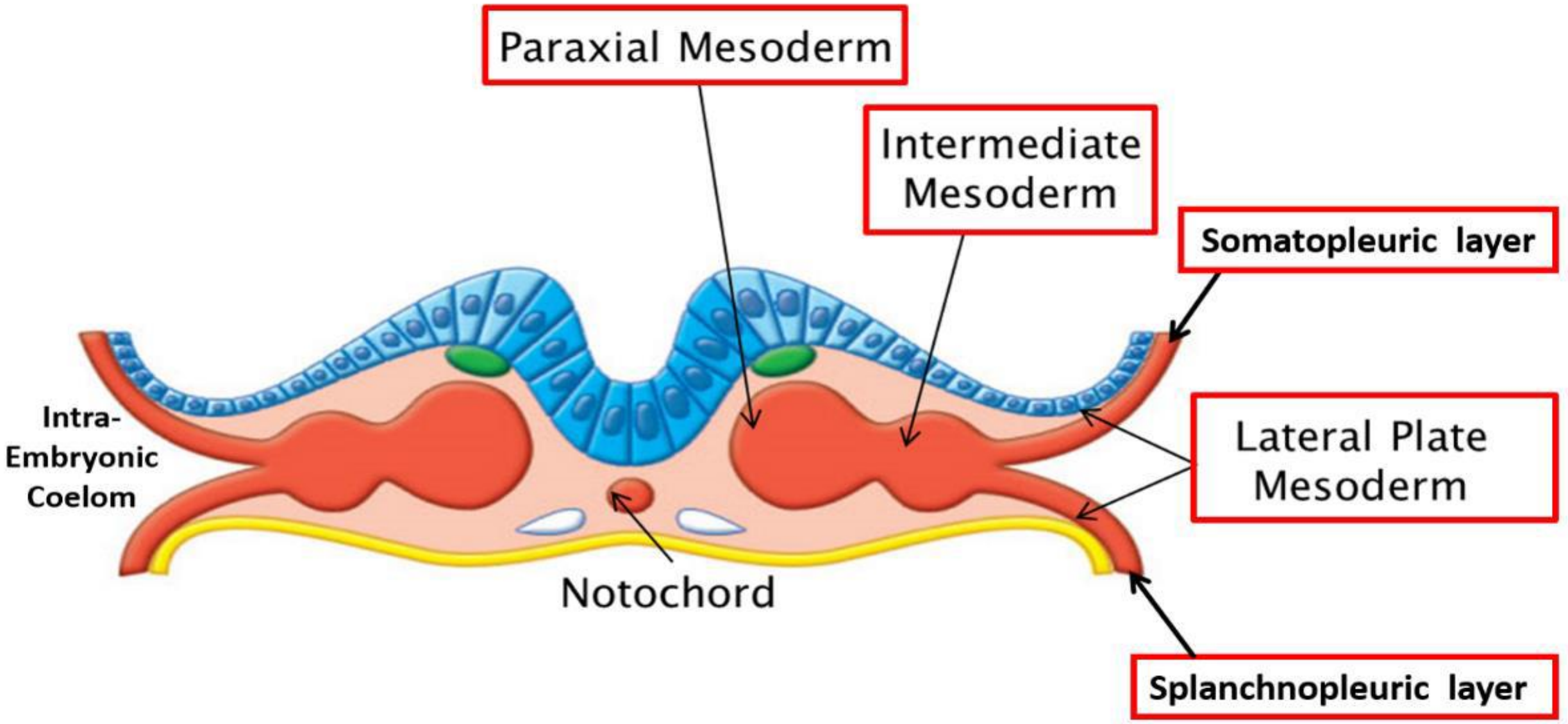

The Intraembryonic Mesoderm

a- Sclerotome (cartilage and bone)
b- Myotome (muscles)
c- Dermatome (dermis of skin)

Kidneys & genital system

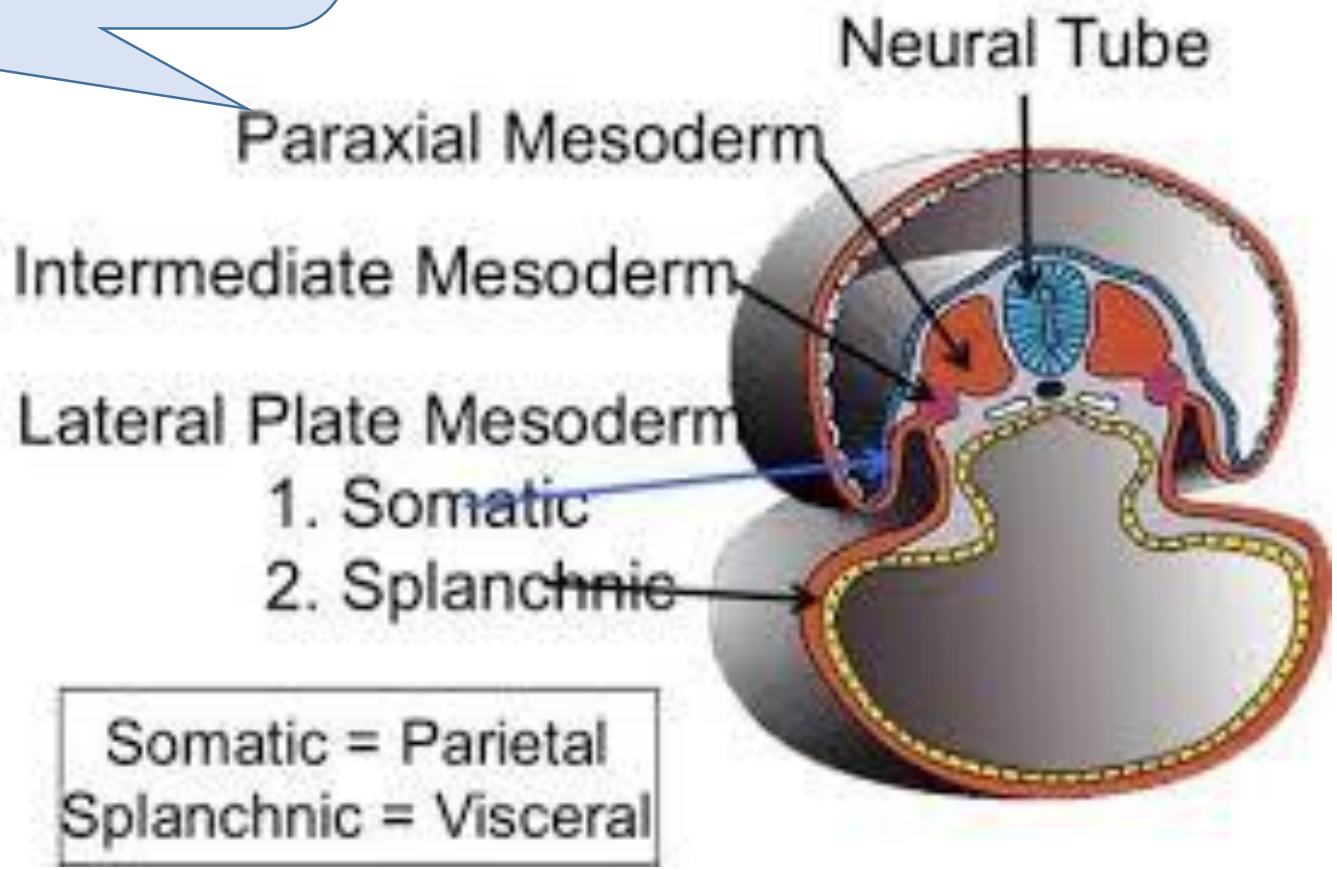

The Intraembryonic Mesoderm

a- Sclerotome (cartilage and bone)
b- Myotome (muscles)
c- Dermatome (dermis of skin)

Kidneys & genital system

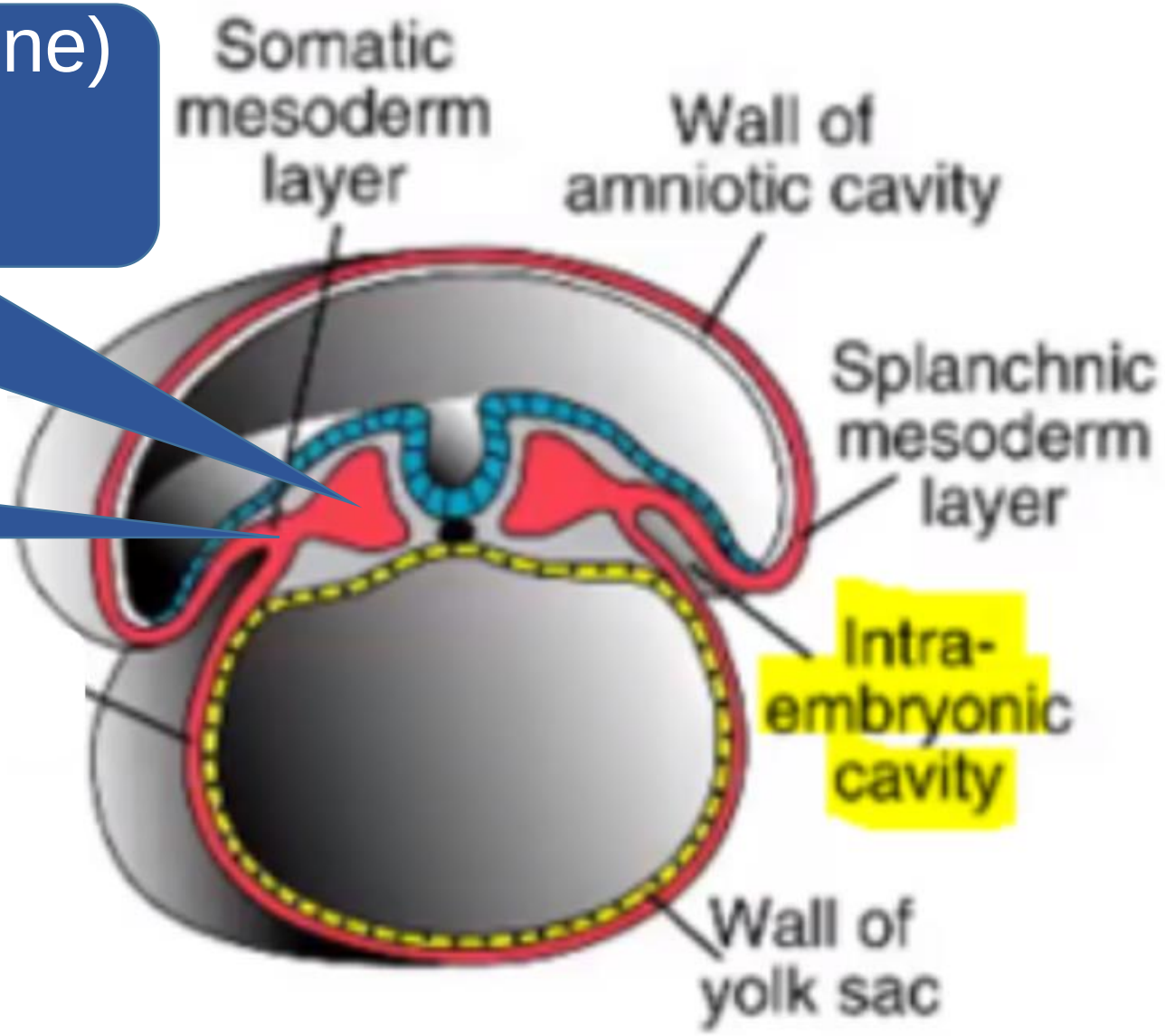

Head and Neck (pharyngeal Arch, pouch & Cleft)

- ✓ The development of the head and neck begins in the 4th and 5th week.
- ✓ Growth of mesoderm in the cranial region (lateral to the stomodeum and just above the cardiac bulge) of the embryo results in the formation of pharyngeal apparatus
- ✓ The entire pharyngeal apparatus consists of arches, pouches, grooves, and membranes, all of which are early embryonic structures with roles in the formation of the face and neck structures.
- ✓ These pharyngeal arches results from a proliferation of mesoderm germ layer and infiltrated by the neural crest cells from the neural tube. (The outer wall of the pharyngeal arches is made up of ectoderm and endoderm will make up the inner wall of these arches and their central core is made up of mesoderm)
- ✓ pharyngeal arches are seen as pairs on lateral sides of the embryo.
- ✓ These pharyngeal arches are named as arch number one, arch number two, three, four, and six. The fifth pharyngeal arch disappears once it's formed.
- ✓ First arch is comprised of two parts: maxillary prominence ,mandibular prominence associated with Meckel's cartilage
- ✓ On the outer aspect, the pharyngeal arches are separated from each other by the pharyngeal cleft also called the pharyngeal grooves.

Head and Neck (pharyngeal Arch, pouch & Cleft)

✓The development of the **head and neck** begins in the

4th week and 5th week.

Pharyngeal Apparatus

- ✓Lateral to the stomodeum and just above the cardiac bulge
- ✓6 pairs of pharyngeal arches develops by week 4.
- ✓Mesoderm infiltrated by the neural crest cells.
- ✓Named: 1,2,3,4,6. The 5th disappears once it's formed

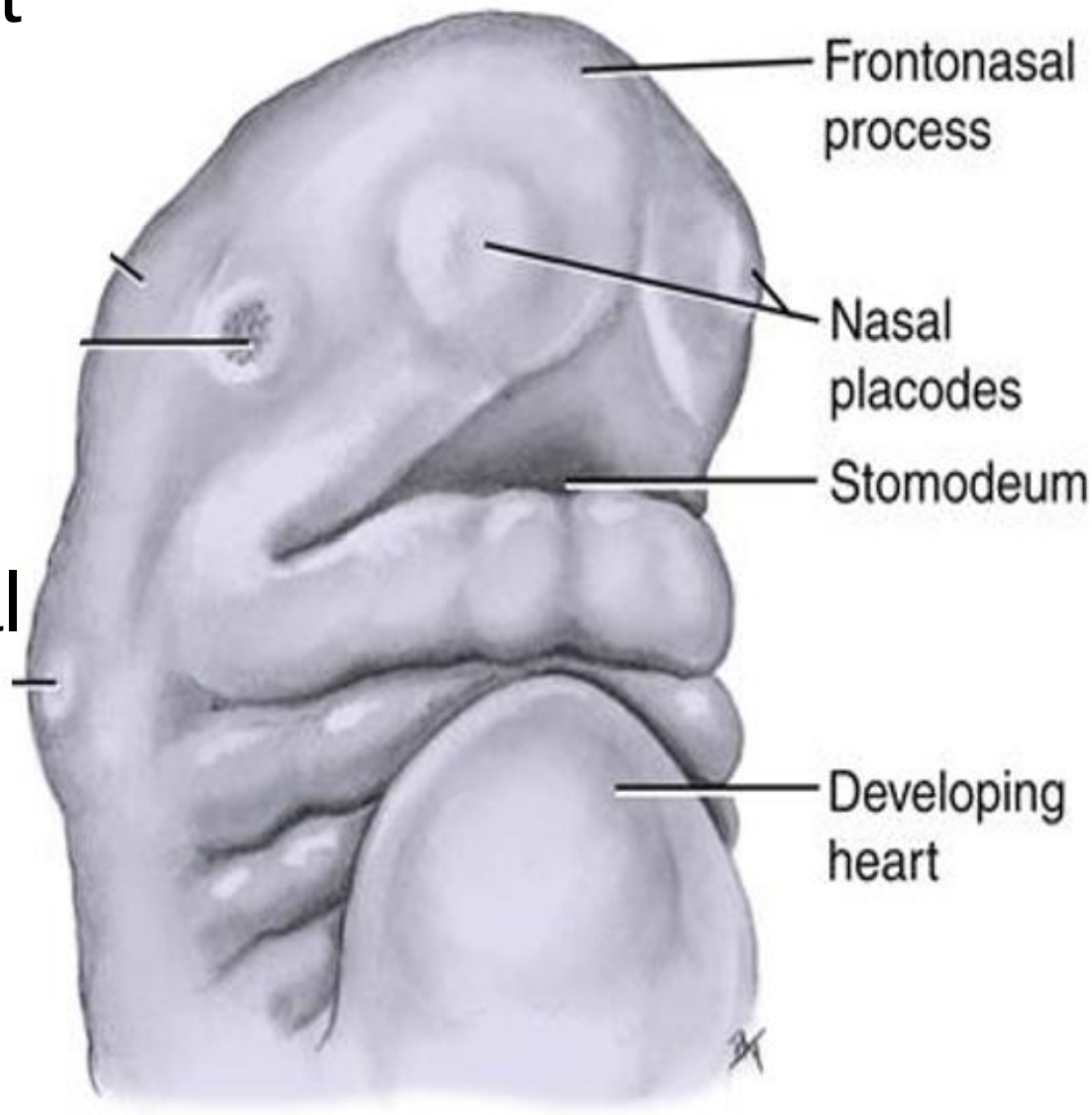

Head and Neck (pharyngeal Arch, pouch & Cleft)

- ✓1st arch is comprised of two parts: maxillary prominence ,mandibular prominence associated with Meckel's cartilage

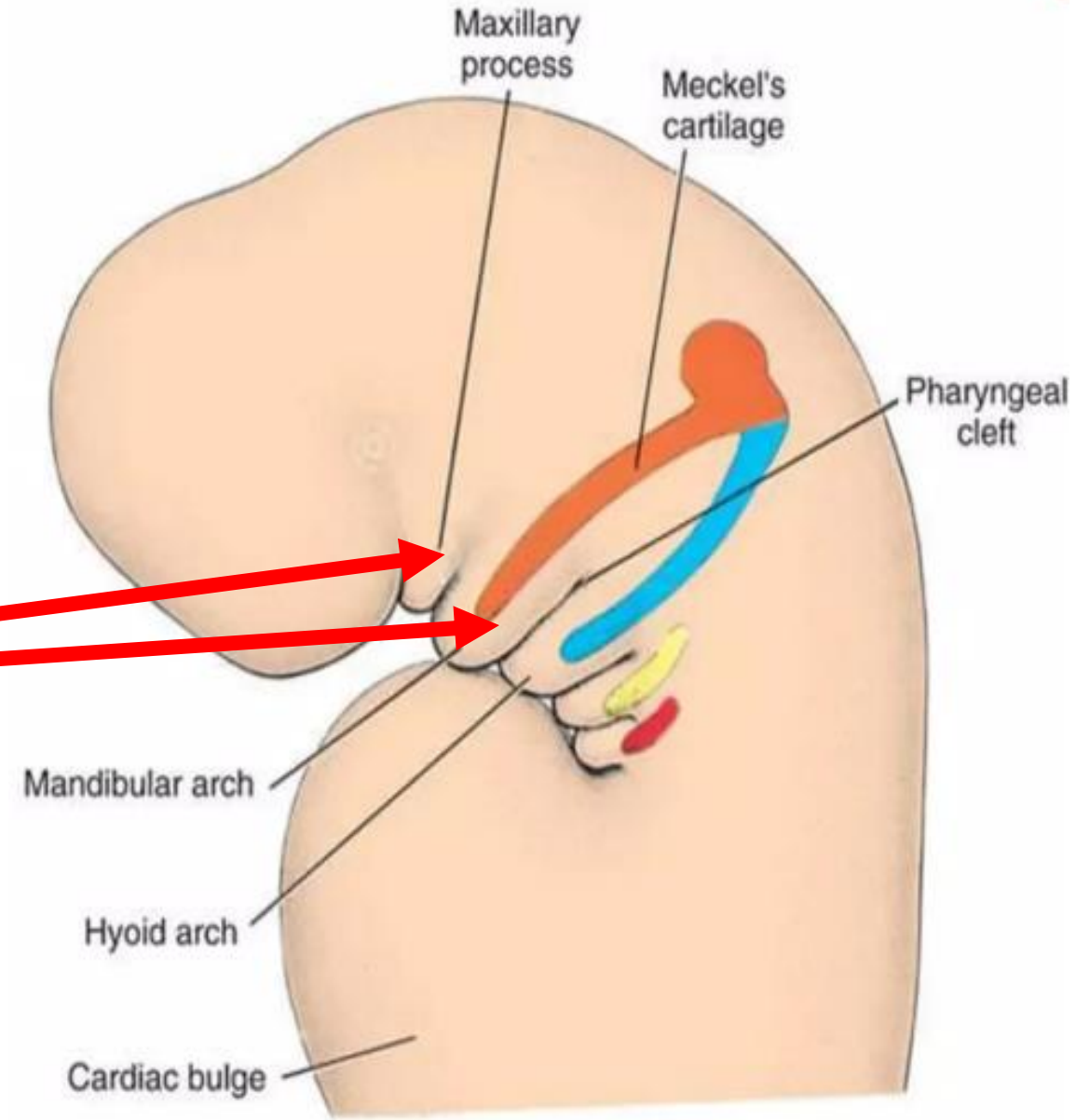

Head and Neck (pharyngeal Arch, pouch & Cleft)

- ✓ The pharyngeal grooves are four in number, the first pharyngeal cleft lies in between the first and second pharyngeal arch.
- ✓ From the inner aspect the pharyngeal arches are separated by small concavities or depressions called the pharyngeal pouches. The pharyngeal pouches are also four in number.
- ✓ Together the pharyngeal arches, the pharyngeal clefts and the pharyngeal pouches makes up the pharyngeal apparatus.
- ✓ As the embryo develops, each pharyngeal arch includes cartilaginous, arterial, muscular and nervous components. These will subsequently give rise to structures of the developing fetus

Pharyngeal Apparatus

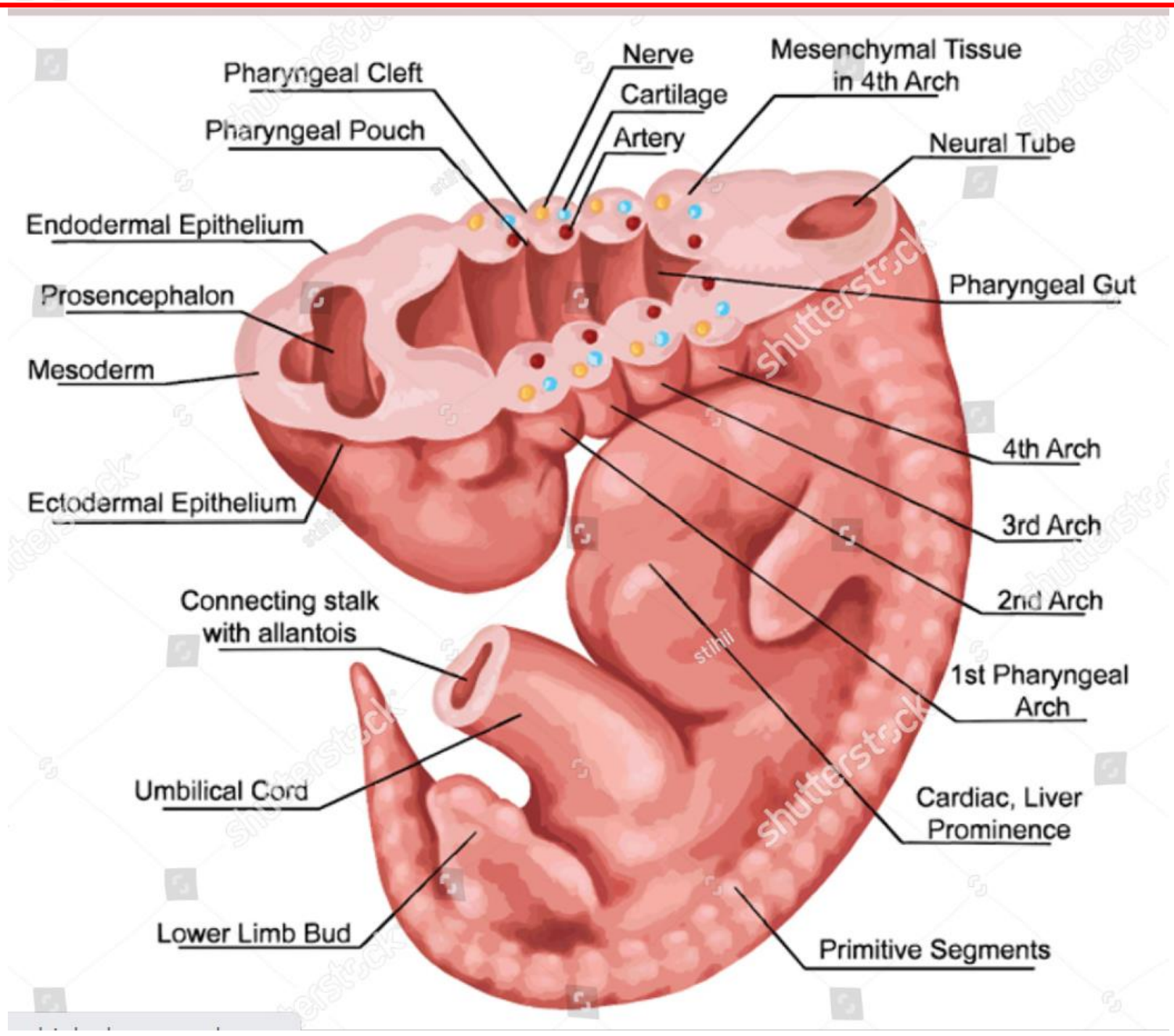

Pharyngeal Apparatus

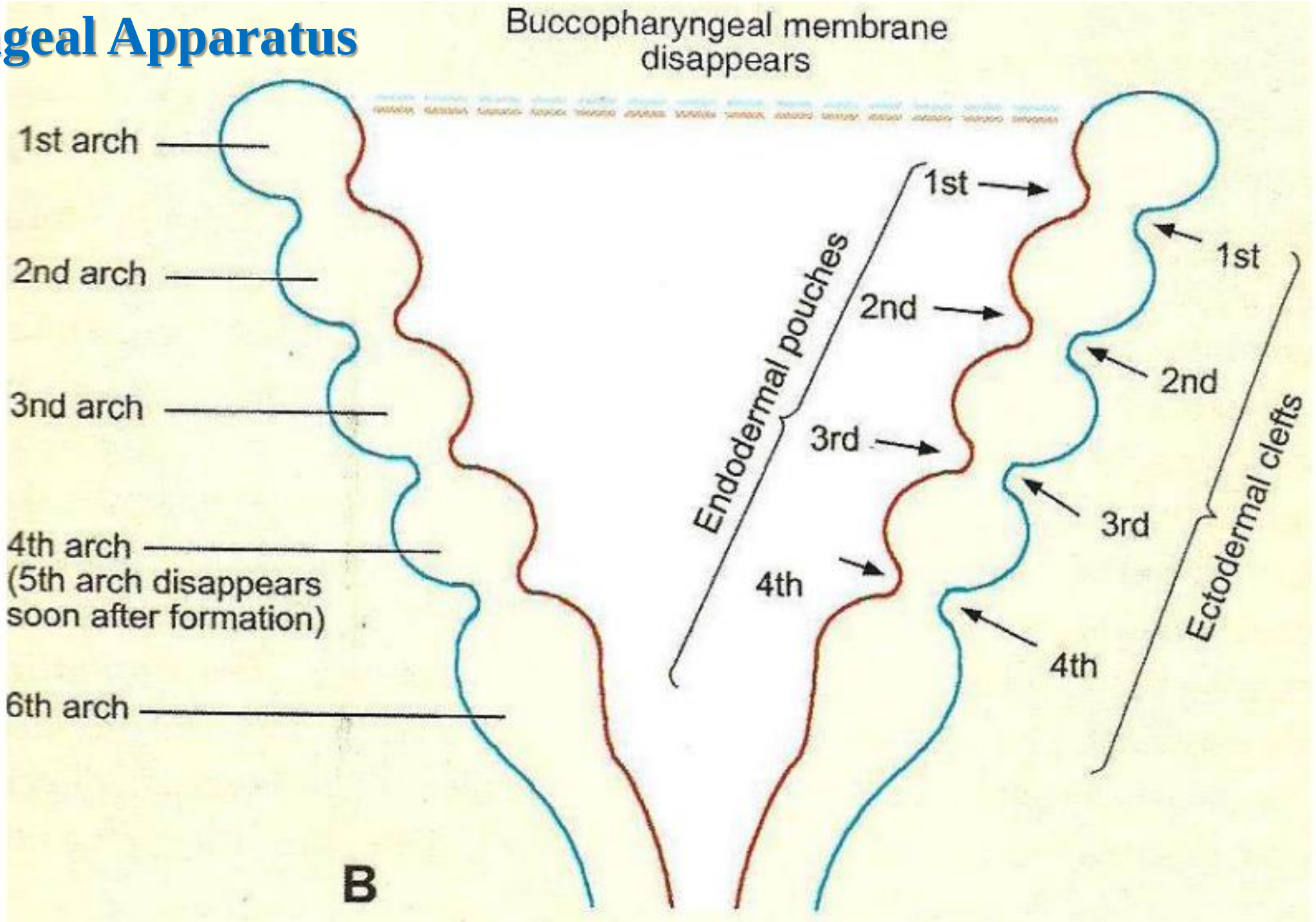

Pharyngeal Apparatus

- ✓ The nerve supply of the first pharyngeal arch is the fifth cranial nerve or the trigeminal nerve.
- ✓ Facial nerve innervates the second arch.
- ✓ Third arch innervated by glossopharyngeal nerve.
- ✓ Fourth and sixth arch innervated by vagus nerve
- ✓ The cartilage of the first arch is called the Meckle's cartilage and that of the second arch is the richert's cartilage

Pharyngeal Apparatus

5th (V): Trigeminal N

7th (VII): Facial N

9th (IX): Glossopharyngeal N

10th (X): Vagus N

10th (X): Vagus N

Pharyngeal Arch	Cranial Nerve	Skeleton/Cartilage	Muscles
1 (mandibular)	V	Meckel's cartilage, Maxilla, mandible, zygomatic, temporal, malleus, incus	MOM, anterior digastric, mylohyoid, tensor veli palatini, tensor tympani
2 (hyoid)	VII	Reichert's cartilage, stapes, styloid process, upper half of hyoid body and lesser horns	MFE, posterior digastric, stylohyoid, stapedius
3	IX	Lower half of hyoid body and greater horns	Stylopharyngeus
4	X	Thyroid cartilage	Cricothyroid, levator veli palatini, palatoglossus, pharyngeal constrictors
6 (not visible)	X	Cricoid cartilage	Laryngeal muscles

- ✓ Meckle's
- ✓ Maxilla and mandible
- ✓ Muscles of mastication

- ✓ Richert's cartilage
- ✓ Muscles of facial expression

Pharyngeal Arch	Cranial Nerve	Skeleton/Cartilage	Muscles
1 (mandibular)	V	Meckel's cartilage, Maxilla, mandible, zygomatic, temporal, malleus, incus	MOM, anterior digastric, mylohyoid, tensor veli palatini, tensor tympani
2 (hyoid)	VII	Reichert's cartilage, stapes, styloid process, upper half of hyoid body and lesser horns	MFE, posterior digastric, stylohyoid, stapedius
3	IX	Lower half of hyoid body and greater horns	Stylopharyngeus
4	X	Thyroid cartilage	Cricothyroid, levator veli palatini, palatoglossus, pharyngeal constrictors
6 (not visible)	X	Cricoid cartilage	Laryngeal muscles

Fate of Pharyngeal Arches

- ✓ The **1st groove** and **pouch** are involved in the formation of **ear structures**, (such as the external auditory meatus, the primordial tympanic cavity and the eustachian tube).

- ✓ The **2nd ,3rd , 4th** are obliterated by the overgrowth of the **2nd** arch. This area will eventually become the future **cervical sinus**.

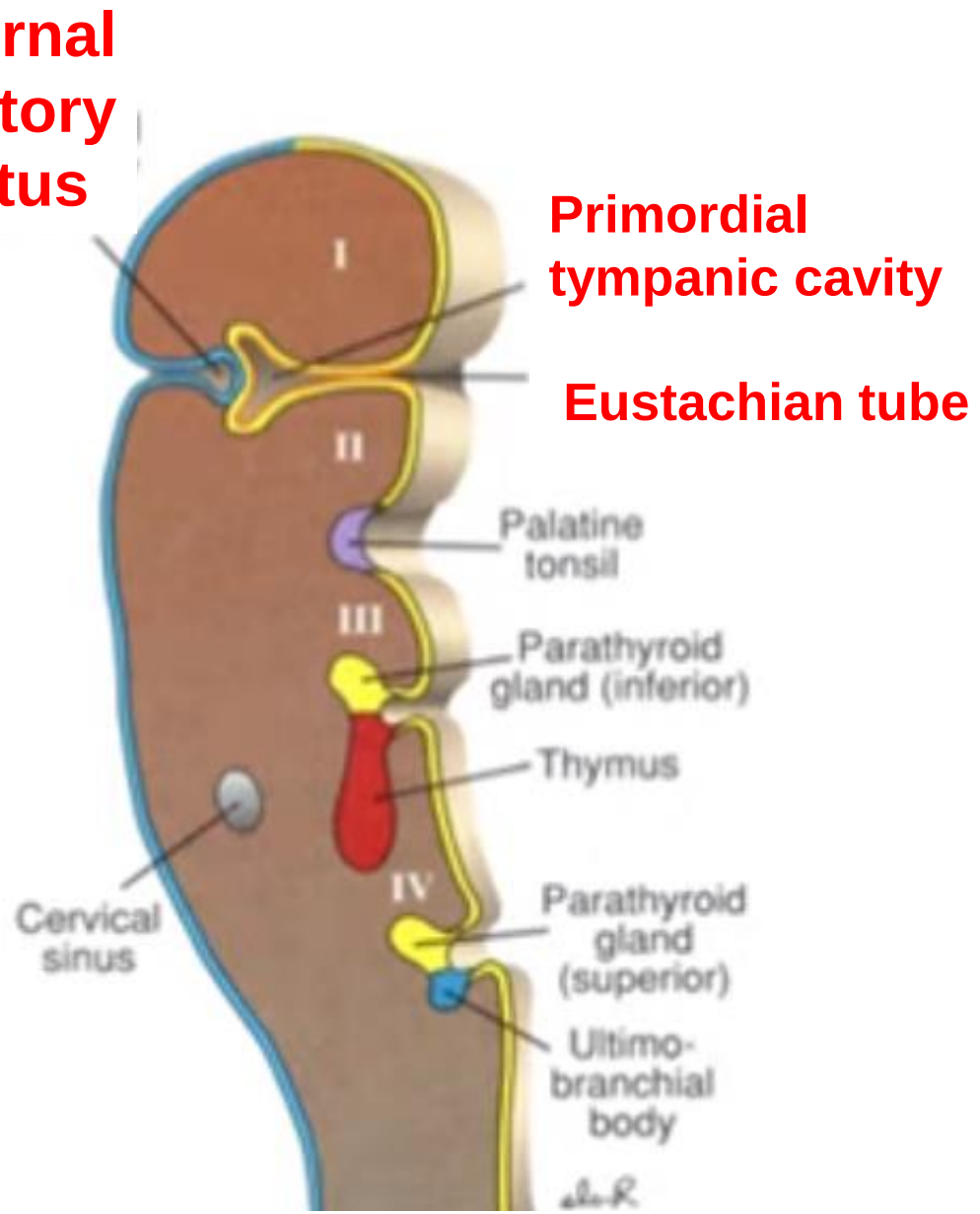

Clefts and Pouches

WEEK 4

Pharyngeal Clefts, Pouches, & Placodes

Arch	Cleft	Pouch	Placode
1	EAM	Eustachian tube and tympanic cavity	Trigeminal ganglion
2	Cervical sinus	Palatine tonsil	Geniculate ganglion
3	Cervical sinus	Thymus and inferior parathyroids	Inferior sensory ganglion of 9th cranial nerve
4	Cervical sinus	Superior paraythyroids and ultimobranchial body (parafollicular cells of thyroid)	Inferior sensory ganglion of 10th cranial nerve

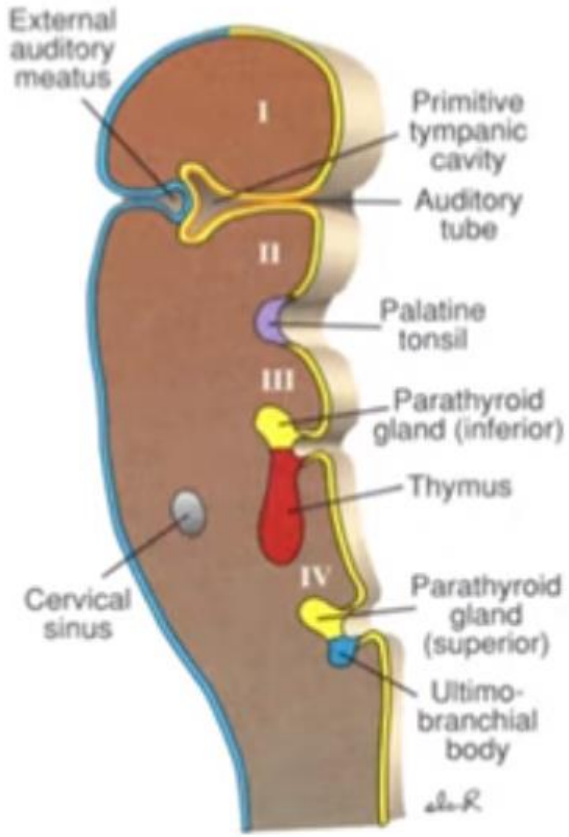

Fate of Pharyngeal Arches

- ✓ During the **5th week**, the **2nd** pharyngeal arch enlarges and overgrows the **3rd and 4th** arches, forming the ectodermal depression called **cervical sinus**.

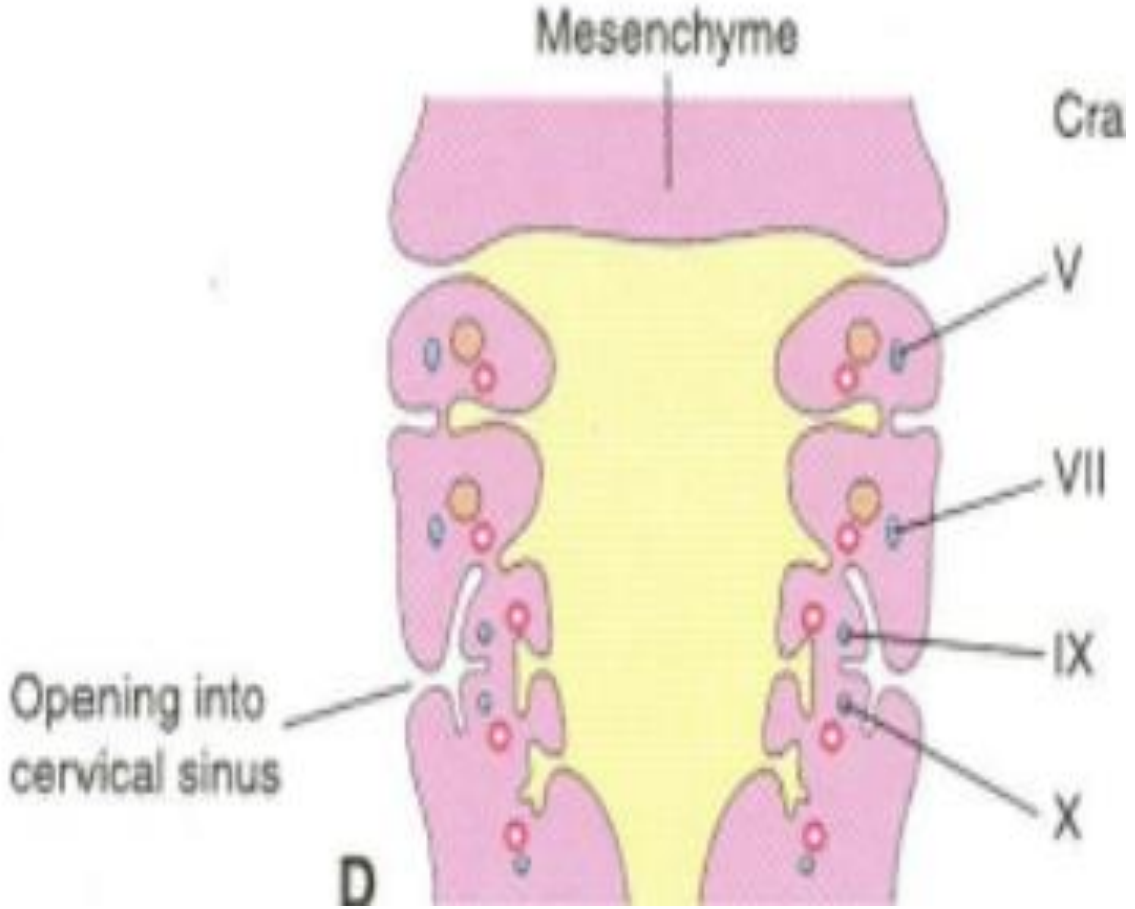

Fate of Pharyngeal Arches

- ✓ **2nd ,3rd , 4th grooves** are obliterated by the overgrowth of the **2nd arch**, giving the neck a smooth contour. This area will eventually become the future **cervical sinus**.

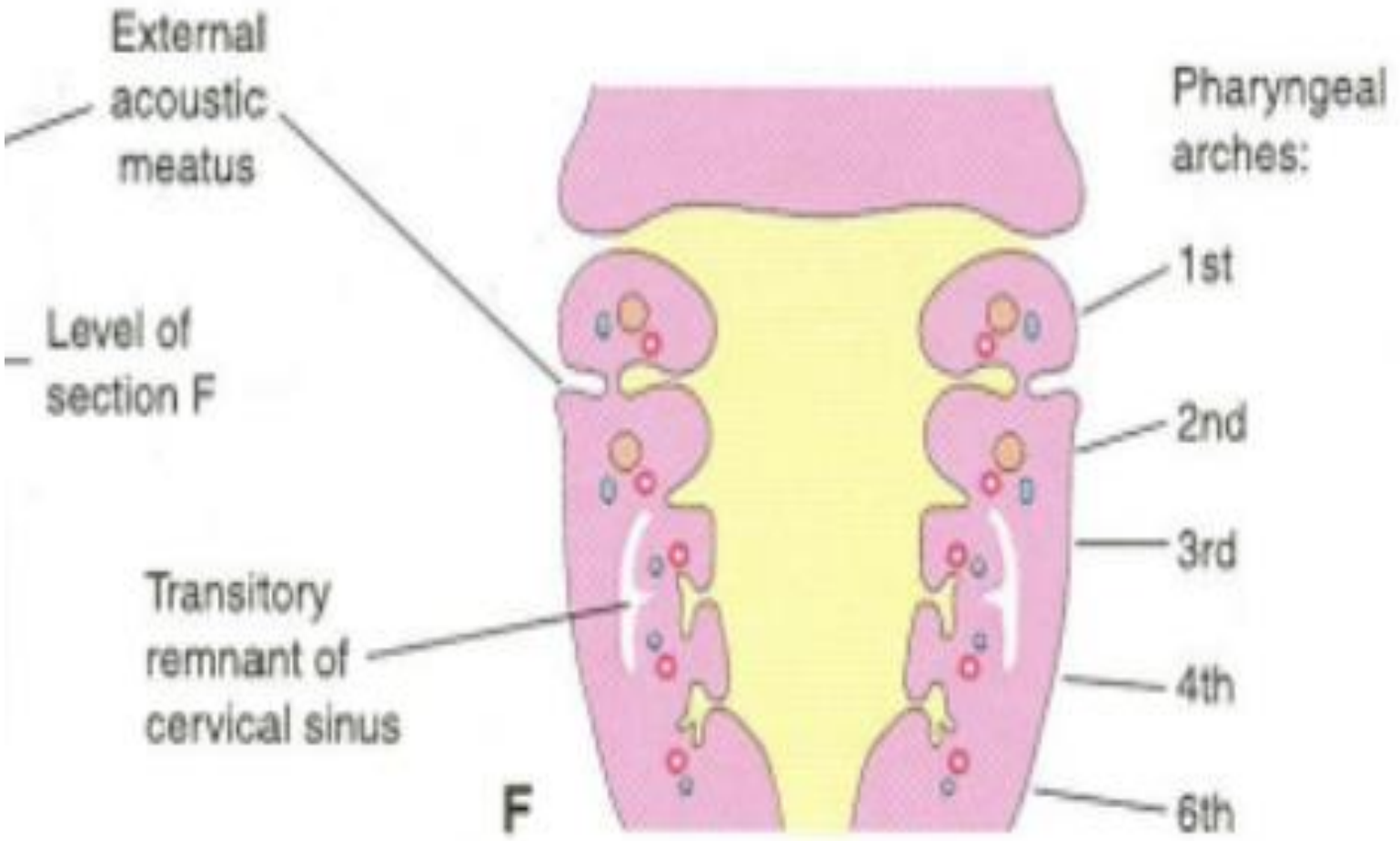

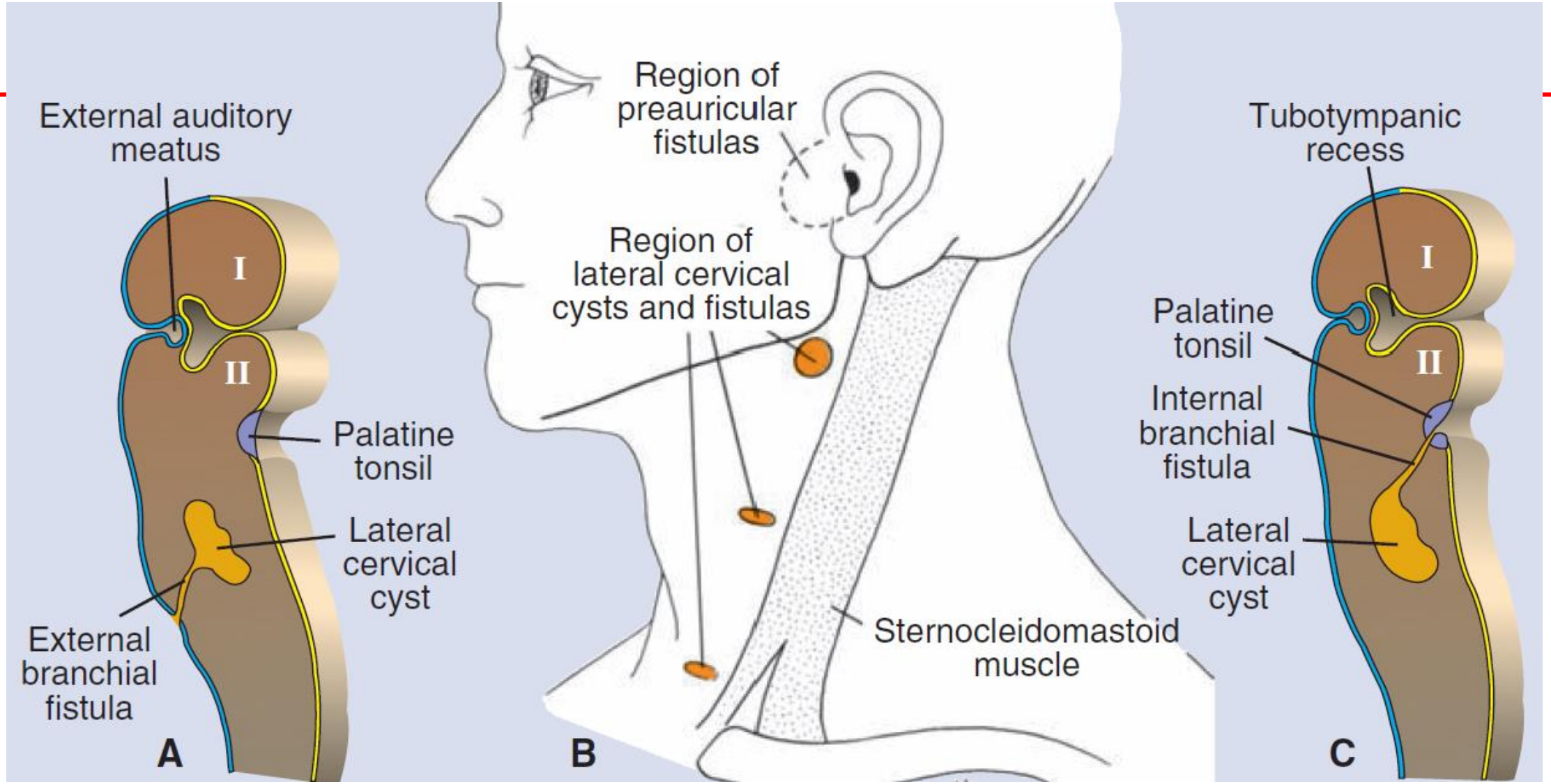

Figure 17.14 **A.** Lateral cervical cyst opening at the side of the neck by way of a fistula. **B.** Lateral cervical cysts and fistulas in front of the sternocleidomastoid muscle. Note also the region of preauricular fistulas. **C.** A lateral cervical cyst opening into the pharynx at the level of the palatine tonsil.

Fate of Pharyngeal Arches



- ✓Remnants of pharyngeal **clefts** **2nd, 3rd , 4th** can appear in the form of **cervical cysts** or **fistulas** found along the anterior border of the sternocleidomastoid muscle.

Pharyngeal Clefts and Pouches

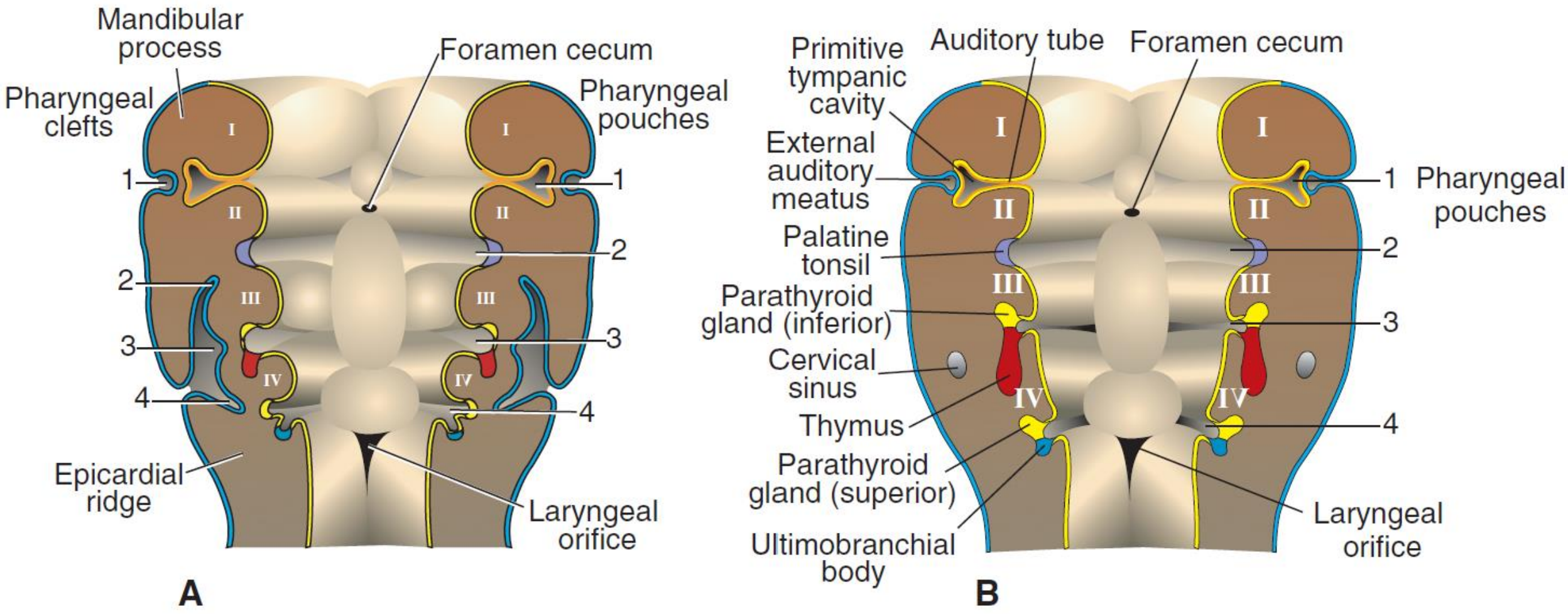

A. Development of the pharyngeal clefts and pouches. The second arch grows over the third and fourth arches, burying the second, third, and fourth pharyngeal clefts. **B.** Remnants of the second, third, and fourth pharyngeal clefts form the cervical sinus, which is normally obliterated. Note the structures formed by the various pharyngeal pouches.

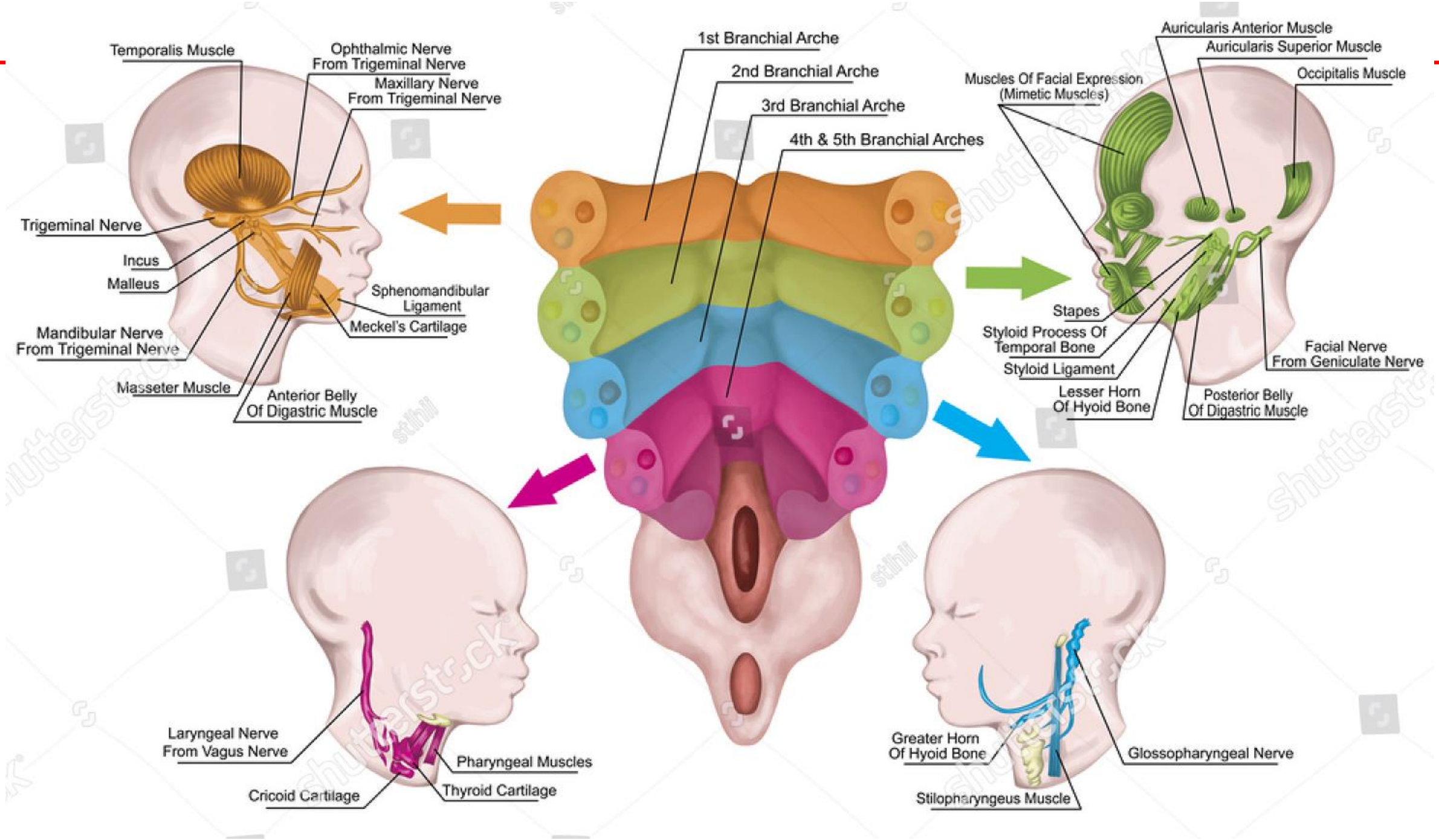
Temporalis Muscle
Ophthalmic Nerve From Trigeminal Nerve
Maxillary Nerve From Trigeminal Nerve
Trigeminal Nerve
Incus
Malleus
Sphenomandibular Ligament
Meckel's Cartilage
Mandibular Nerve From Trigeminal Nerve
Masseter Muscle
Anterior Belly Of Digastric Muscle
1st Branchial Arche
2nd Branchial Arche
3rd Branchial Arche
4th & 5th Branchial Arches
Auricularis Anterior Muscle
Auricularis Superior Muscle
Occipitalis Muscle
Muscles Of Facial Expression (Mimetic Muscles)
Stapes
Styloid Process Of Temporal Bone
Styloid Ligament
Lesser Horn Of Hyoid Bone
Facial Nerve From Geniculate Nerve
Posterior Belly Of Digastric Muscle
Laryngeal Nerve From Vagus Nerve
Pharyngeal Muscles
Cricoid Cartilage
Thyroid Cartilage
Greater Horn Of Hyoid Bone
Glossopharyngeal Nerve
Stilopharyngeus Muscle