EMBRYOLOGICAL DEVELOPMENT & ORAL CAVITY

Senior lecturer
Dr sura talal kadhim
Department of prosthodontics technology
Lec 2

Oral Histology

- Is the science that deal with the study of normal oral tissue by the mean of Microscope

Embryology

- Is the study of prenatal development in stages before birth.

Growth and development

- **Growth** is defined as a normal process in which increase in size or increase in weight .

- **Development** : is defined as the process of growth and differentiation, or an increase towards maturity or full size (increase complex , function).

Major phases of intra-Uterine life

- The intra-Uterine development of human is divided into three major phase as follows:

Phase I: Formation of three germ layers

- Fertilization.....end of 2nd week

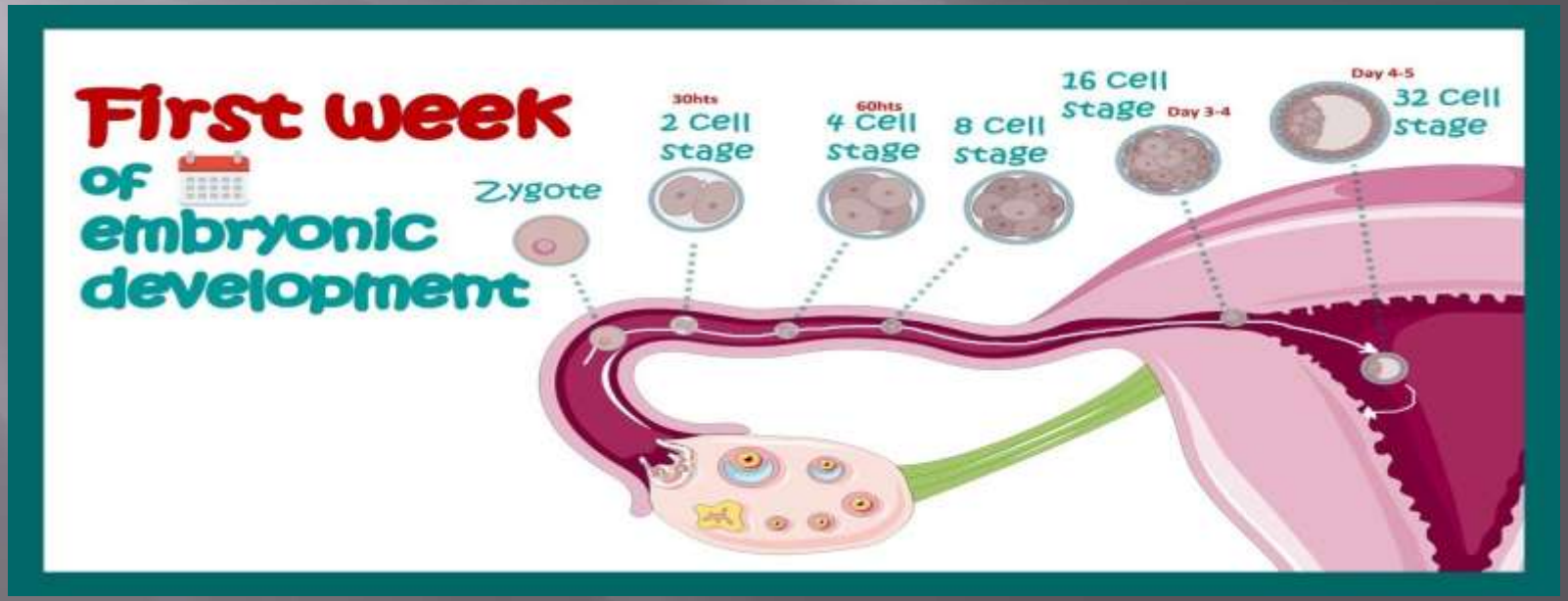

Phase II: The embryonic period. During this time all organ systems are developed

- 3rdweek .....8th week

Phase III : The fetal period. During this period there is a rapid increase in the overall size and maturation of the fetus.

- 8th week .....birth .

First week of fertilization

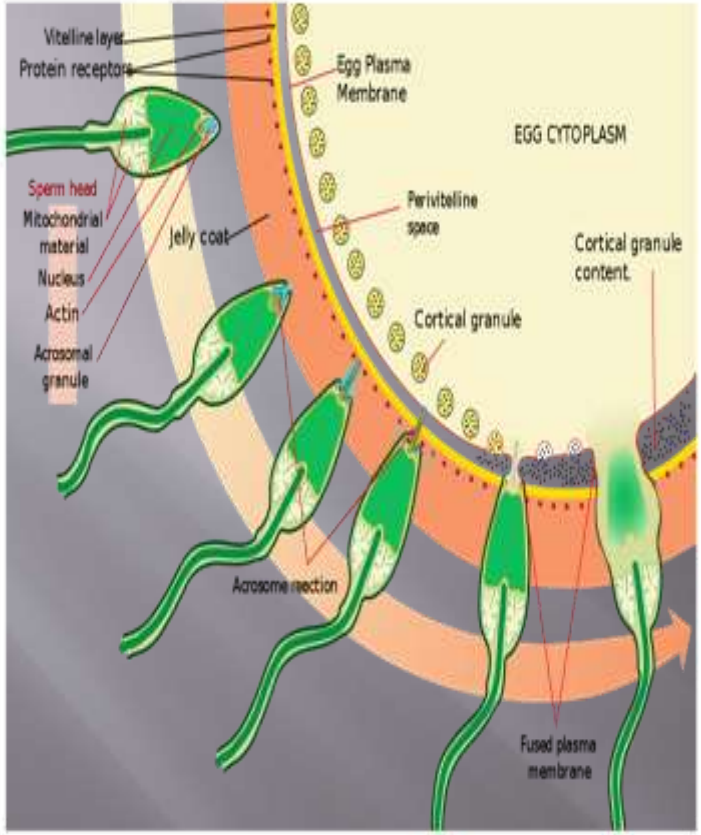

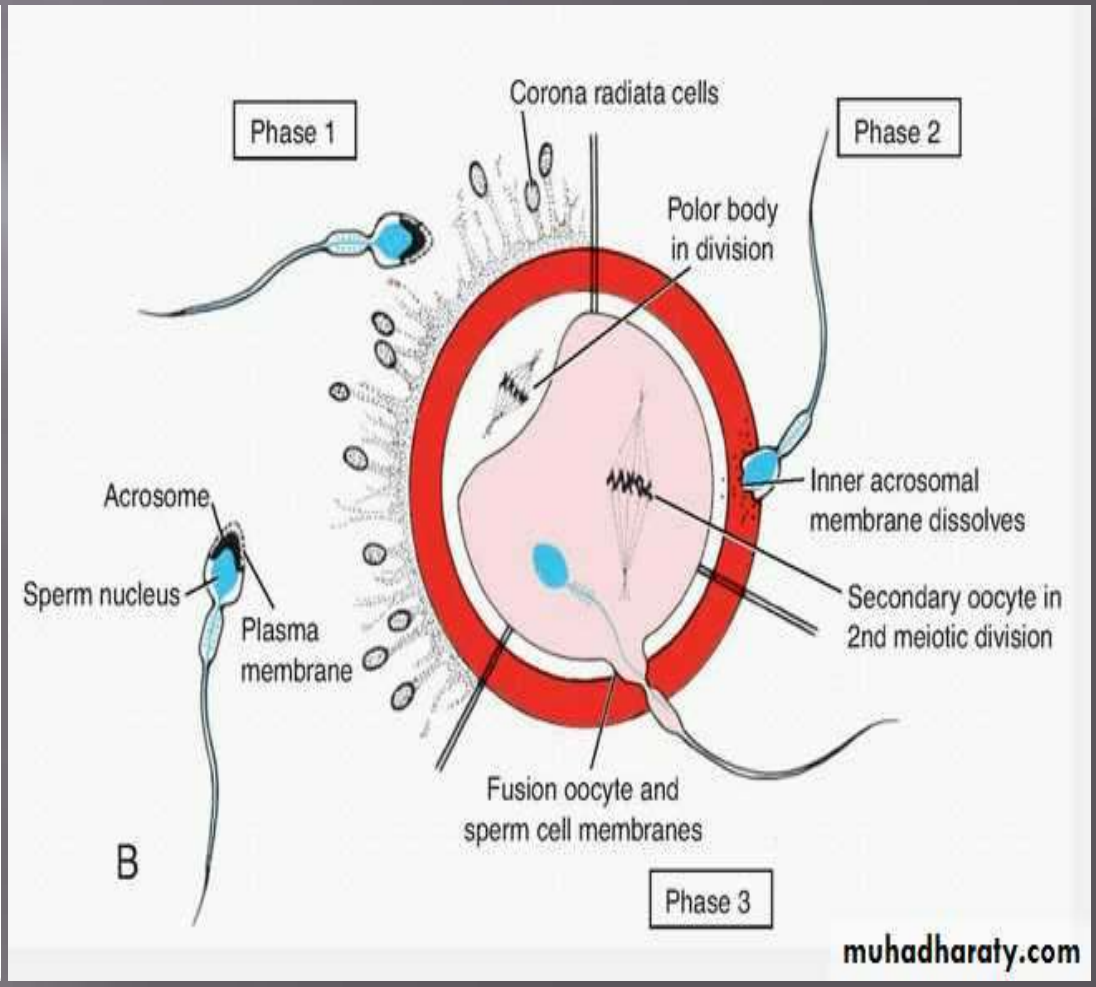

After fertilization of the ovum, a series of cell divisions gives rise to an egg cell mass known as the ***morula*** .





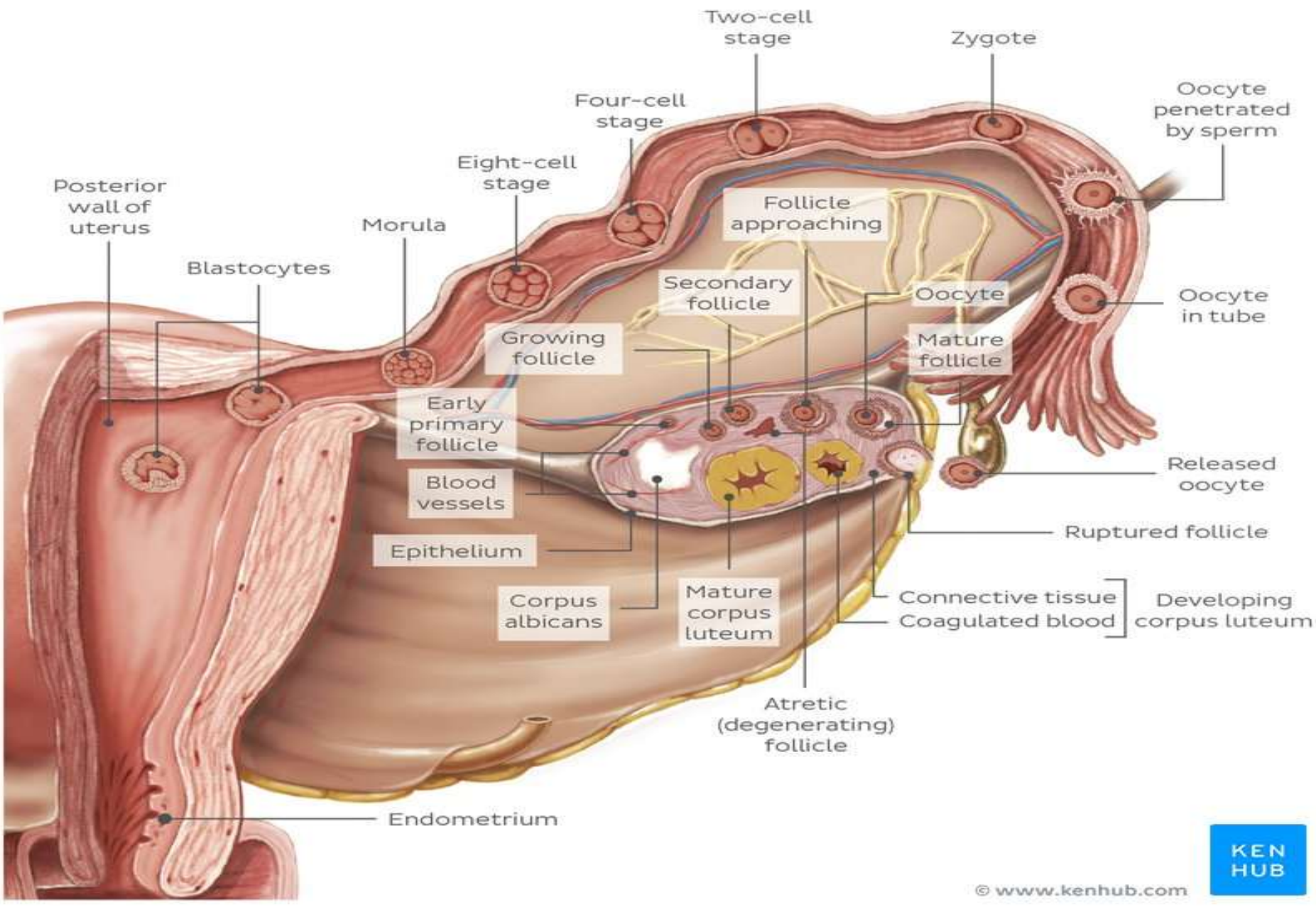
Two-cell stage
Zygote
Four-cell stage
Oocyte penetrated by sperm
Eight-cell stage
Posterior wall of uterus
Follicle approaching
Morula
Blastocytes
Secondary follicle
Oocyte
Oocyte in tube
Growing follicle
Mature follicle
Early primary follicle
Released oocyte
Blood vessels
Ruptured follicle
Epithelium
Corpus albicans
Mature corpus luteum
Connective tissue
Coagulated blood
Developing corpus luteum
Atretic (degenerating) follicle
Endometrium
© www.kenhub.com
KEN HUB

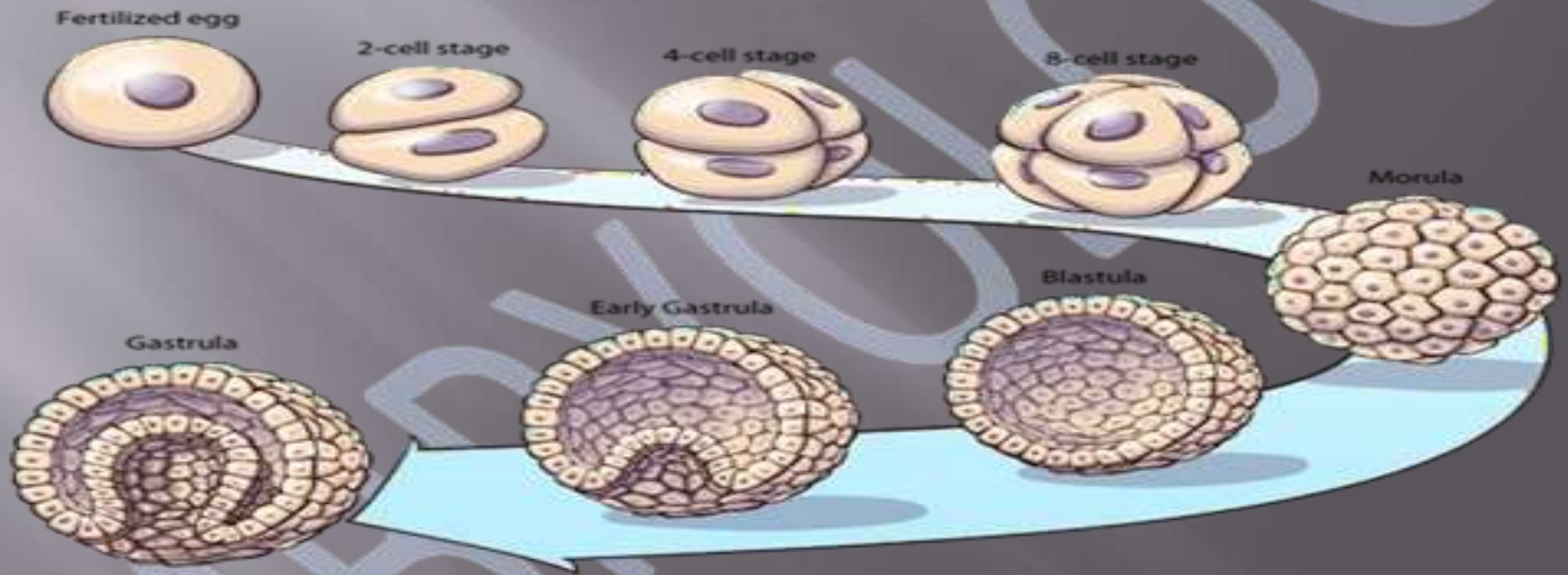

Cell Cleavage
Process by which the number of cells in a developing embryo is multiplied through cell division.

EMBRYOLOGY

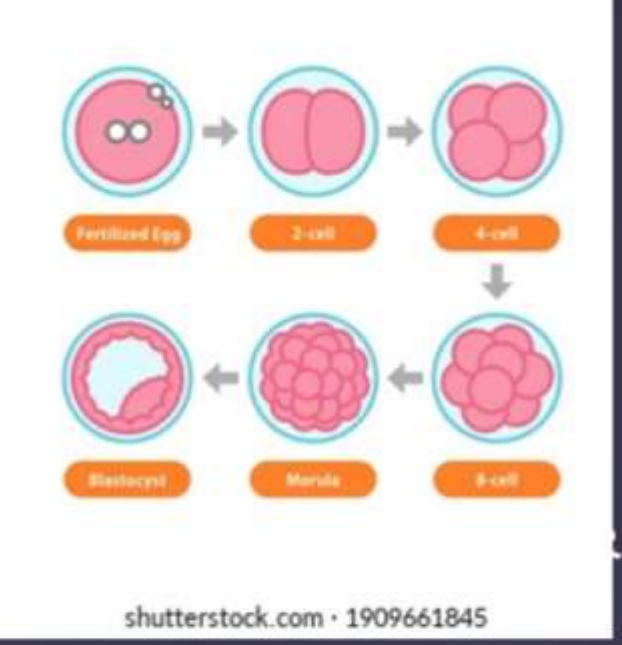

the zygote undergoes cleavage divisions Without increase in the size (blastomeres).

During the first week

- First division occurs about a day after fertilization ,and subsequent divisions occur every 12-24hrs.
- solid sphere of cells within the zona pellucida the morula (sixteen cells)

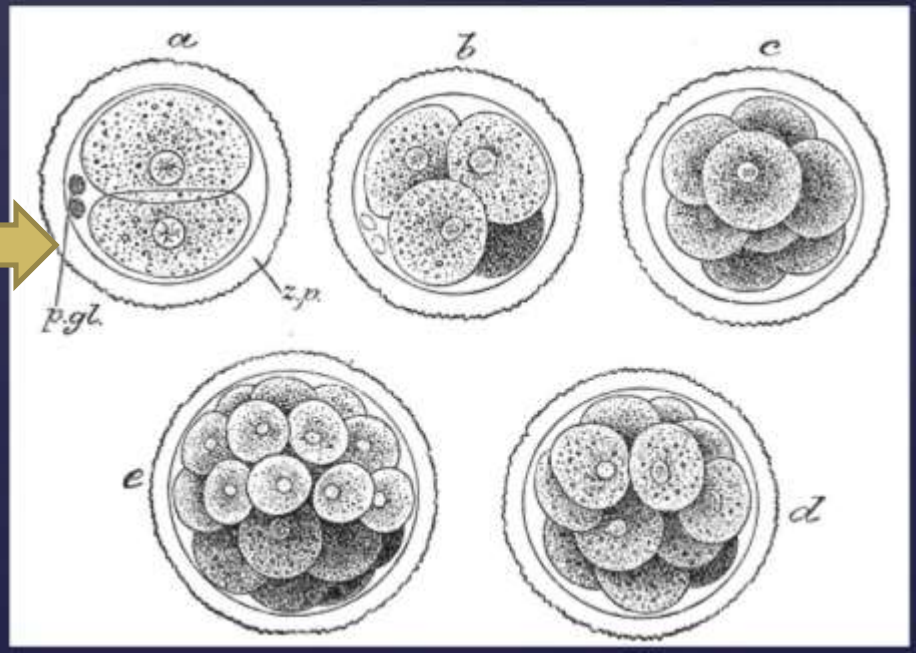

- About the time the morula enters the uterine cavity, fluids begin to penetrate through the zona pellucida into the intercellular spaces of the inner cell mass.

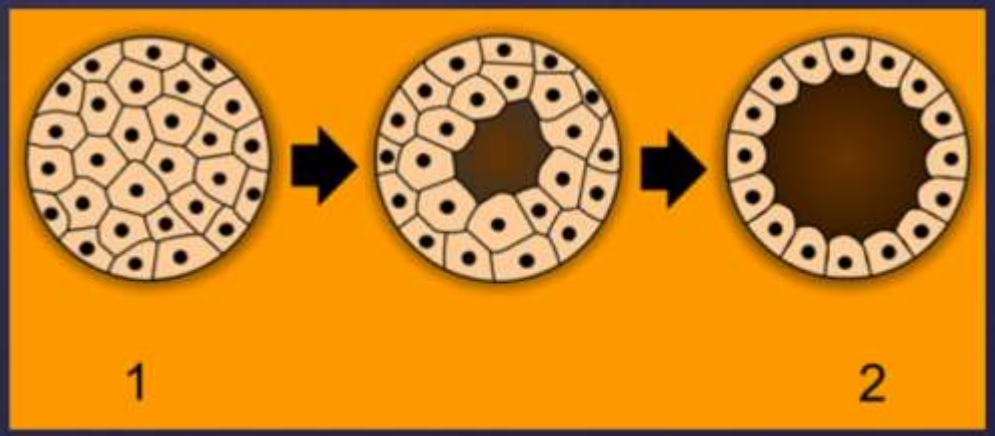

- Gradually, the intercellular spaces become confluent, and finally, a single cavity, the blastocole forms.

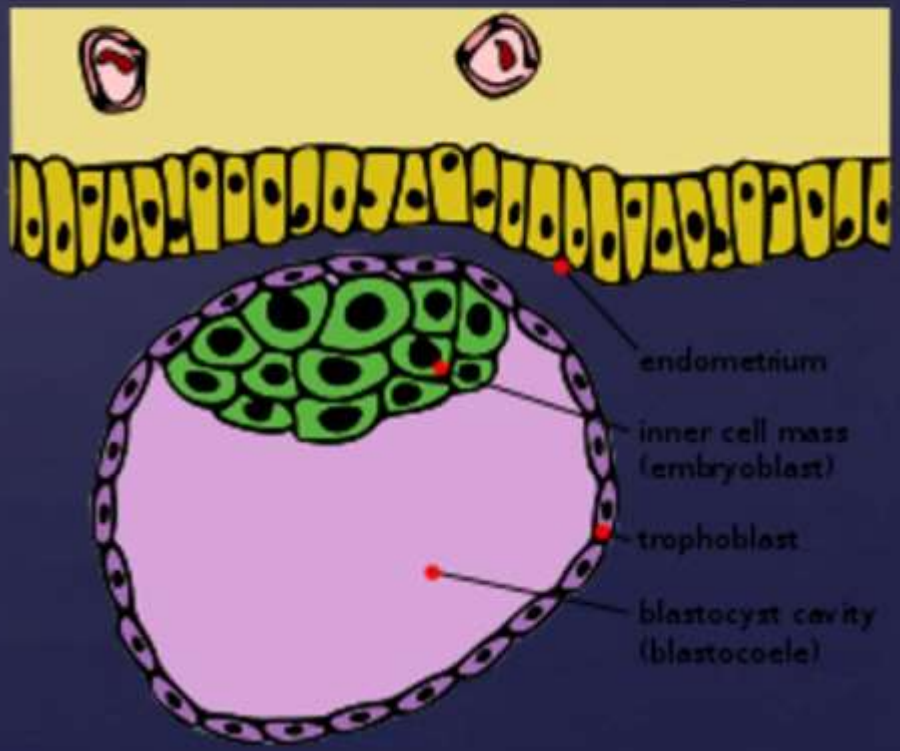

- Cleavage continues and cellular differentiation.
- then a blastocyst, consisting of embryoblast and trophoblast.

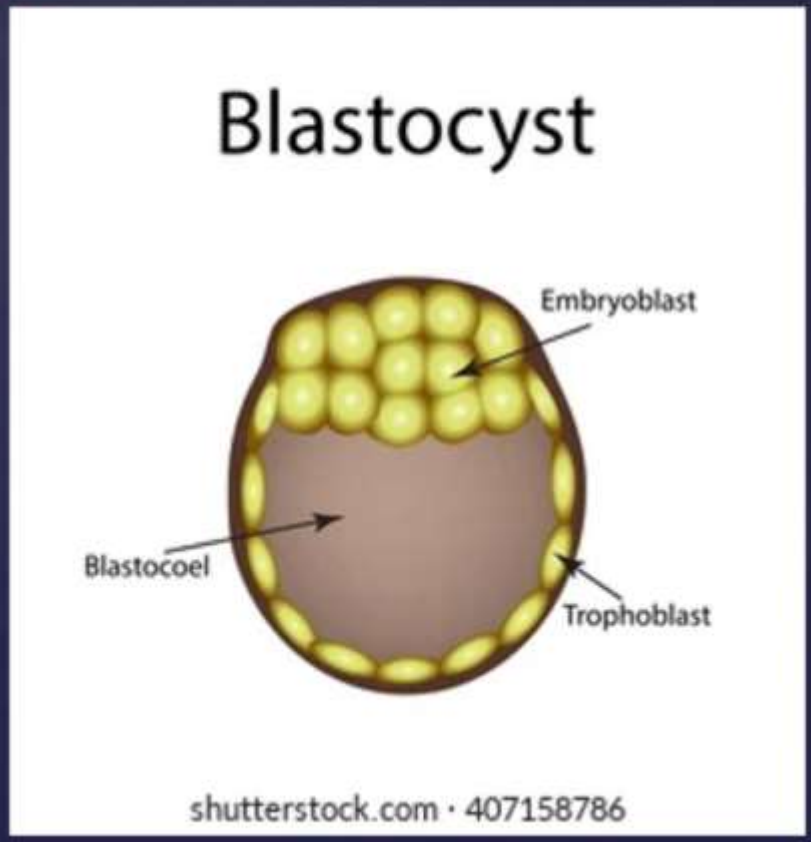

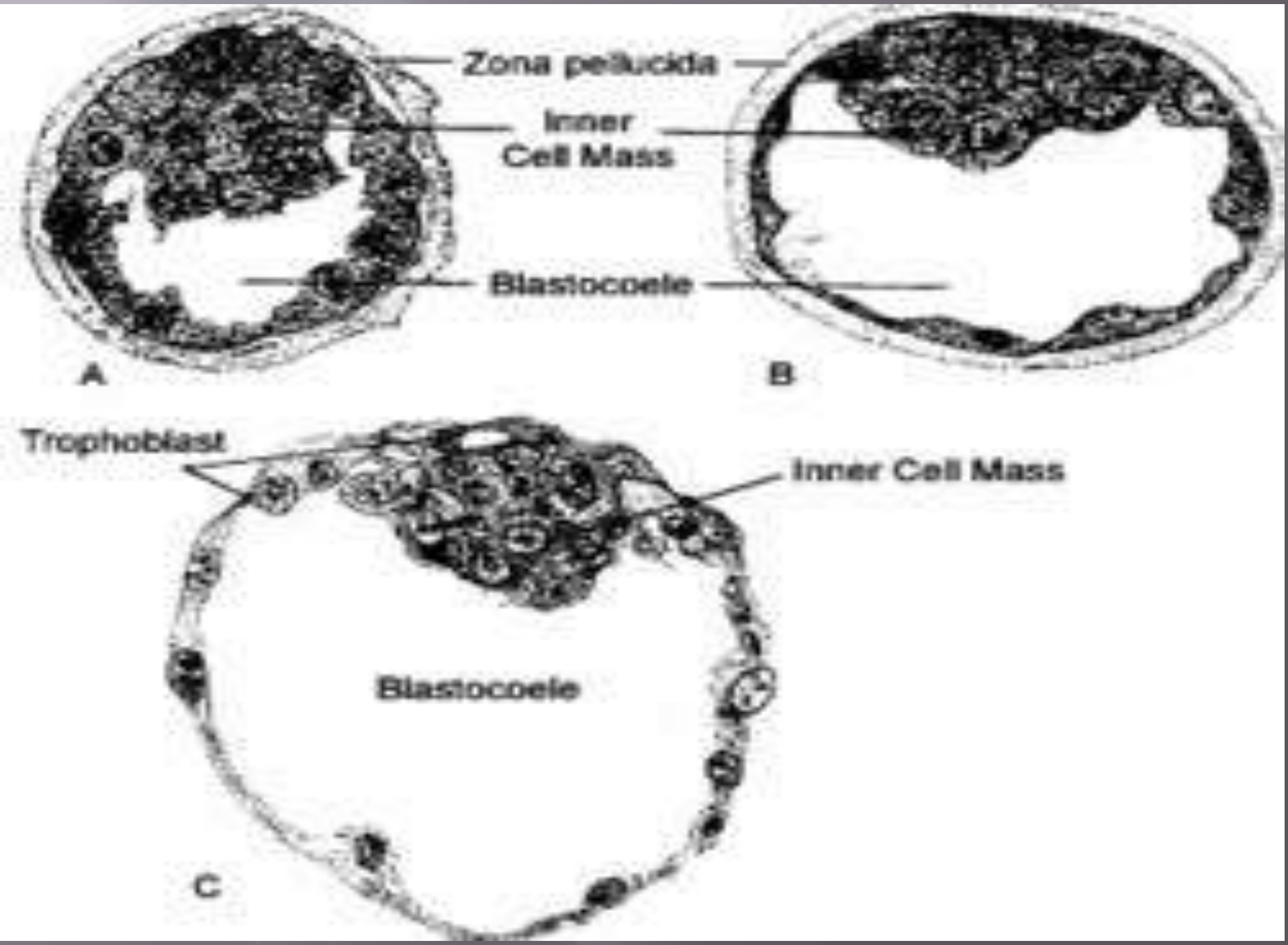
Zona pellucida
Inner
Cell Mass
Blastocoele
A
B
Trophoblast
Inner Cell Mass
Blastocoele
C

- During this week development is predominately associated with implantation of the blastocyst into the uterine wall to establish a source of nutrition

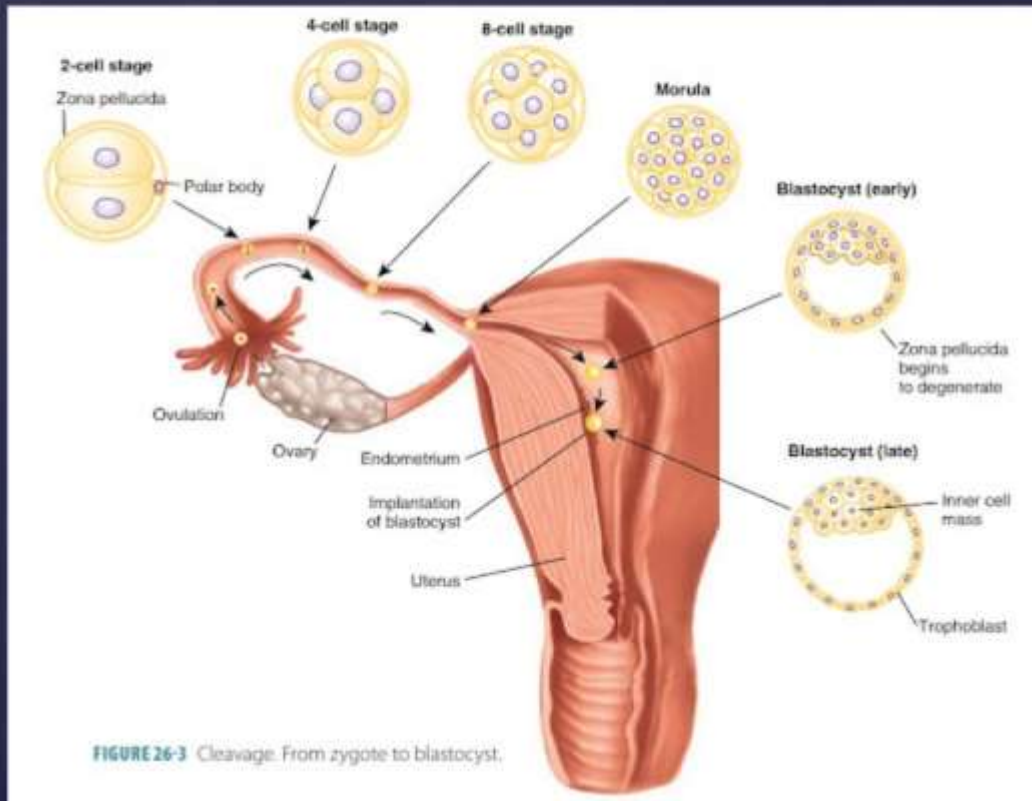

FIGURE 26-3 Cleavage: From zygote to blastocyst.

As it migrates towards the uterus, the zona pellucida surrounding the blastocyst prevents direct contact with the epithelial lining of the fallopian tubes, ensuring implantation in approximately 99% will occur within the uterus.

Once the blastocyst enters the uterus, the zona pellucida degenerates to expose theunderlying trophoblast layer, thus enabling it to attach to the endometrium.

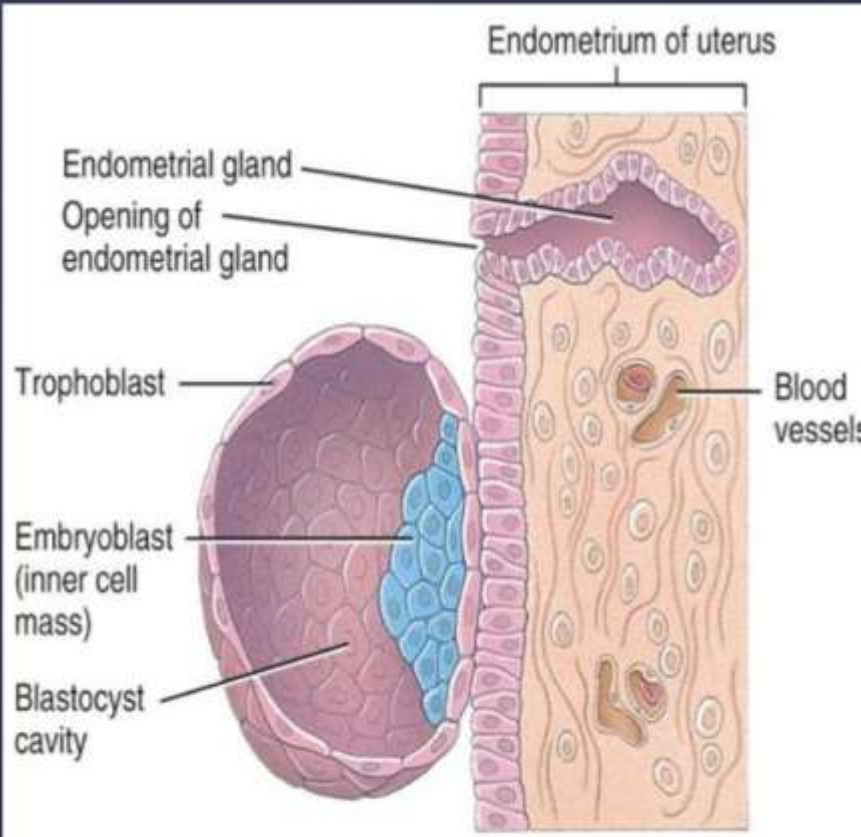

(b) Frontal section through endometrium of uterus and blastocyst, about 6 days after fertilization

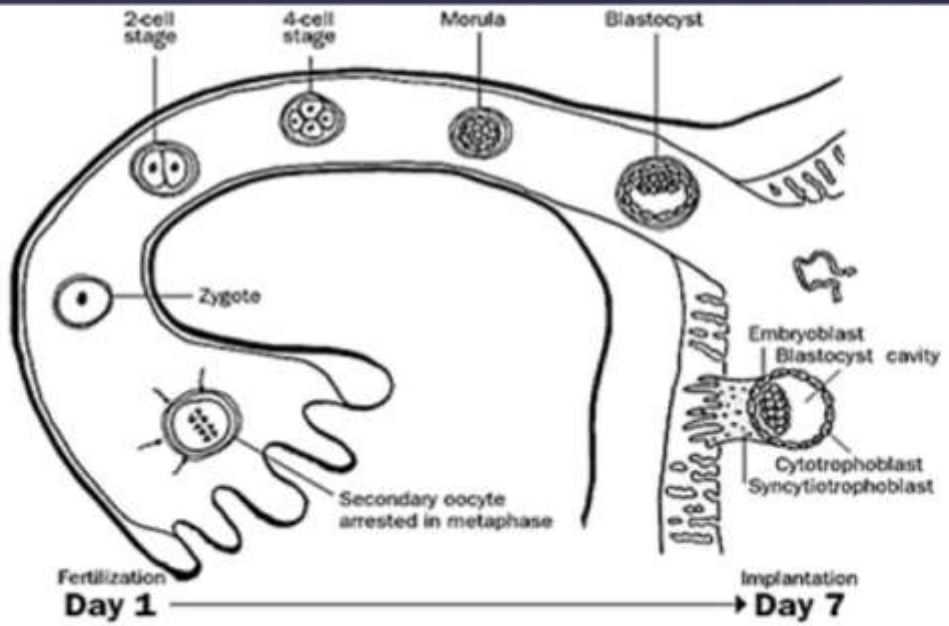
2-cell stage
4-cell stage
Morula
Blastocyst
Zygote
Embryoblast
Blastocyst cavity
Cytotrophoblast
Syncytiotrophoblast
Secondary oocyte arrested in metaphase
Fertilization
Day 1
Implantation
Day 7

- The inner mass of cells differentiate to become embryoblasts and polarise at one end.

This polarisation leaves a cavity, the blastocoele, creating a structure that is now termed the blastocyst.

- The resulting increase in size of the blastocyst causes it to hatch through the zone pellucida , which then disintegrates.

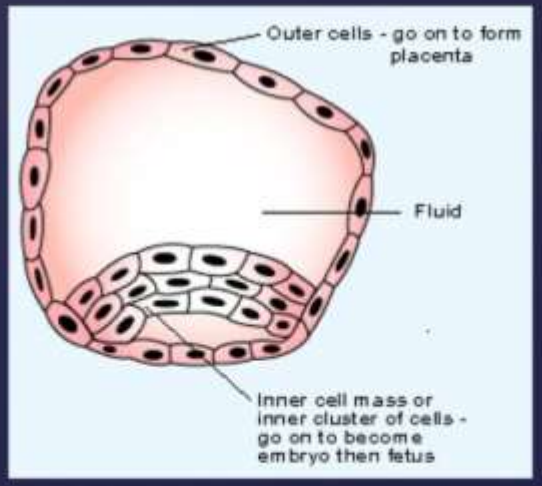

Second week of development

- The second week is concerned with

1-implantation

2- the differentiation the blastocyst into early embryonic and placental forming structures.



EMBRYOLOGY

- The embryoblast forms embryonic disc, which is a bilaminar disc of two layers, an upper layer called the epiblast (primitive ectoderm) and a lower layer called the hypoblast(primitive endoderm).

Day 8

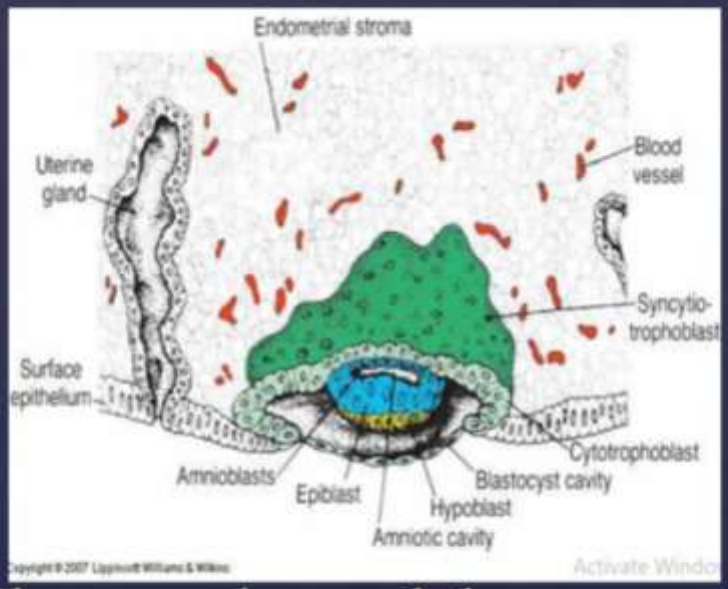

Day 9

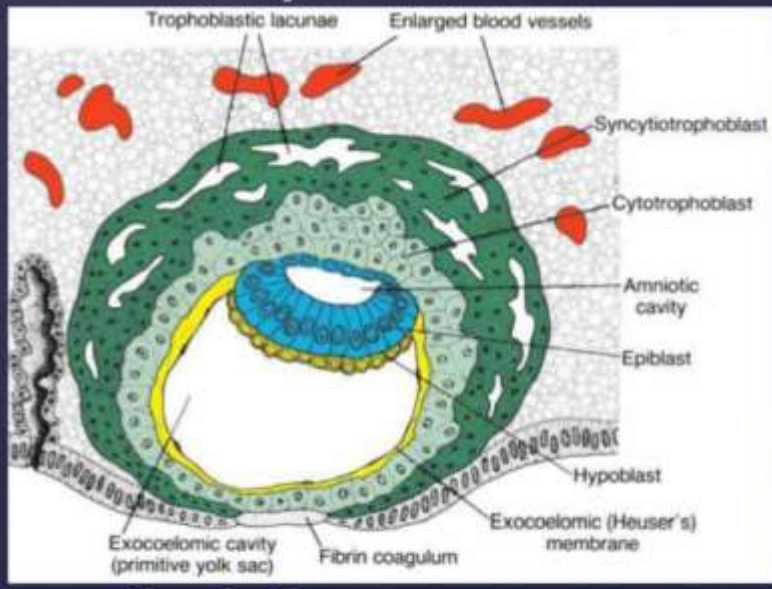

The embryoblast and the trophoblast will turn into two sub-layers

At about 9 days after fertilisation ,the inner cell mass separates into two layers, the epiblast and hypoblast .

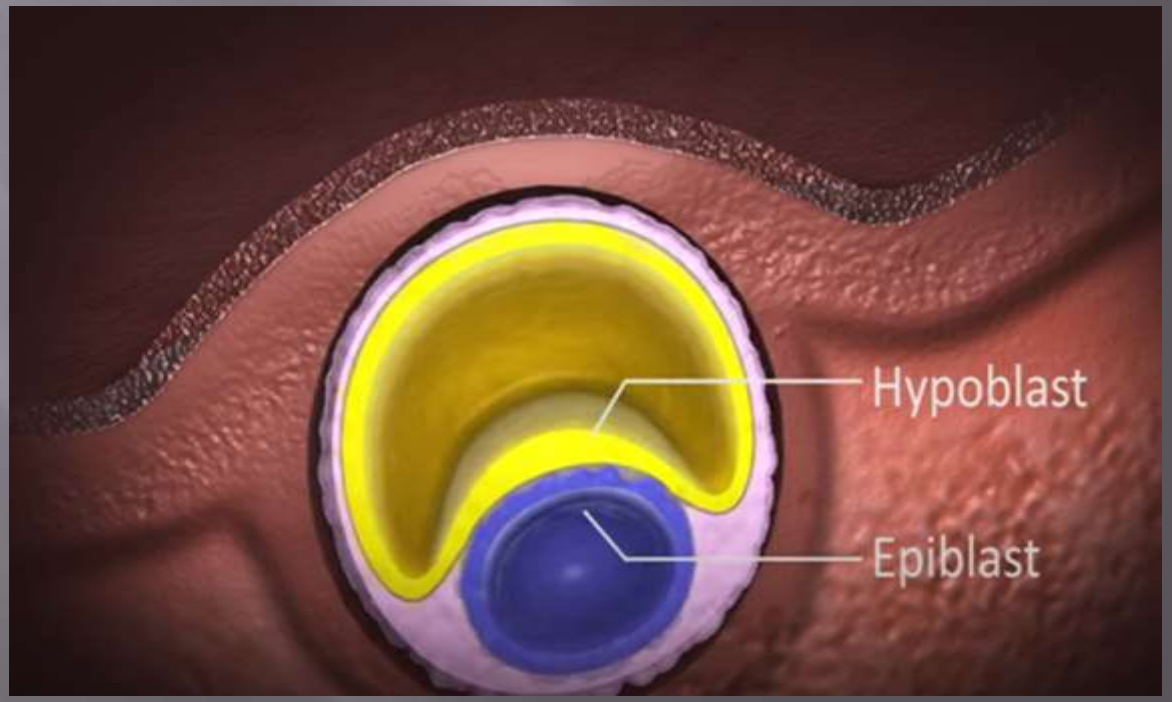

Second week:

it is the week of two, why?

The epiblast cells then organise themselves into a flat disc (bilaminar disc or embryo) two-layered, flattened, essentially circular plate of cells with superior epiblast layer (high columnar cells) and inferior hypoblast layer (small cuboidal cells).



- The disc is stretched between what will become the amniotic cavity and the yolk sac .The trophoblast will develop two sub-layers:
- Cytotrophoblast
  Syncytiotrophoblast

Day 12

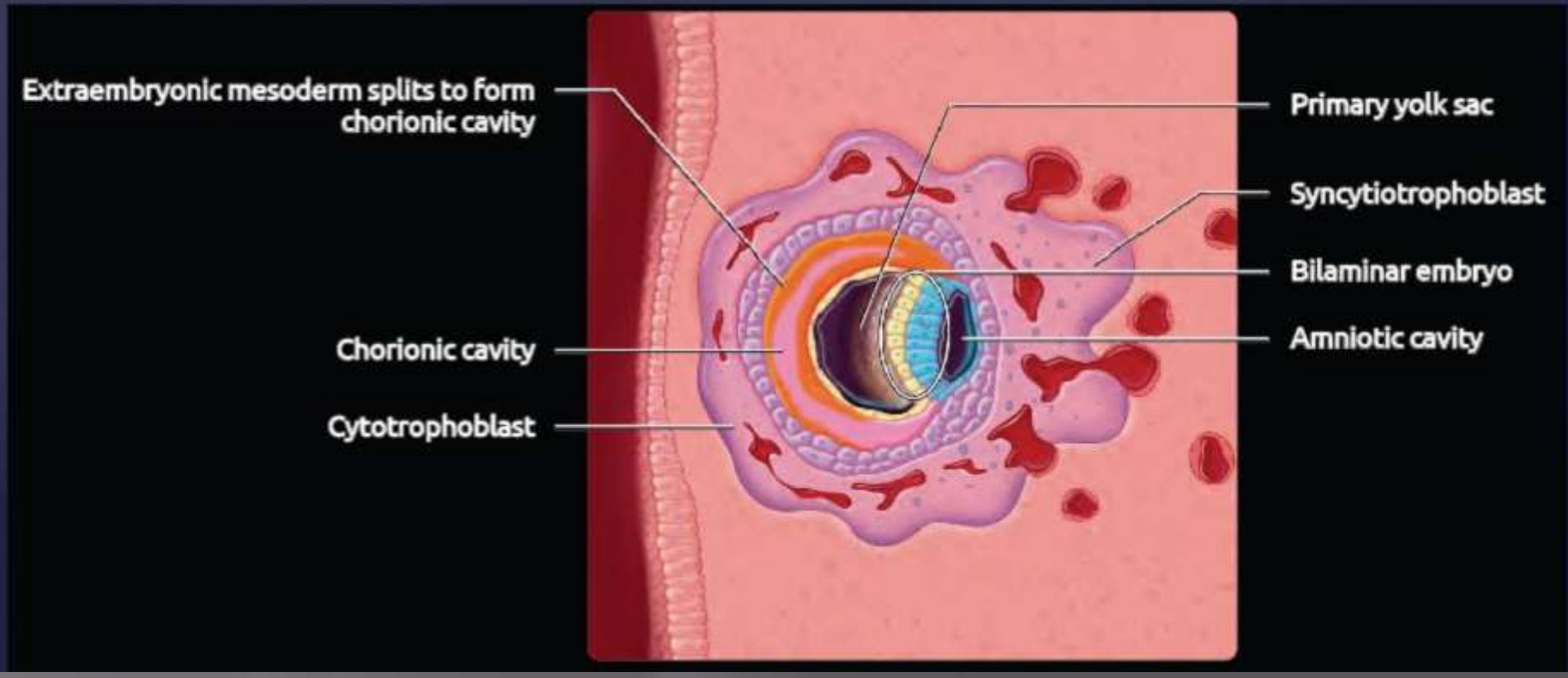

Implantation:

after ovulation, the endometrial lining becomes

1- thickened

2-ts secretory glands becoming elongated

3-is increasingly vascular

The placenta develops once the blastocyst is implanted, connecting the embryo to the uterine wall.

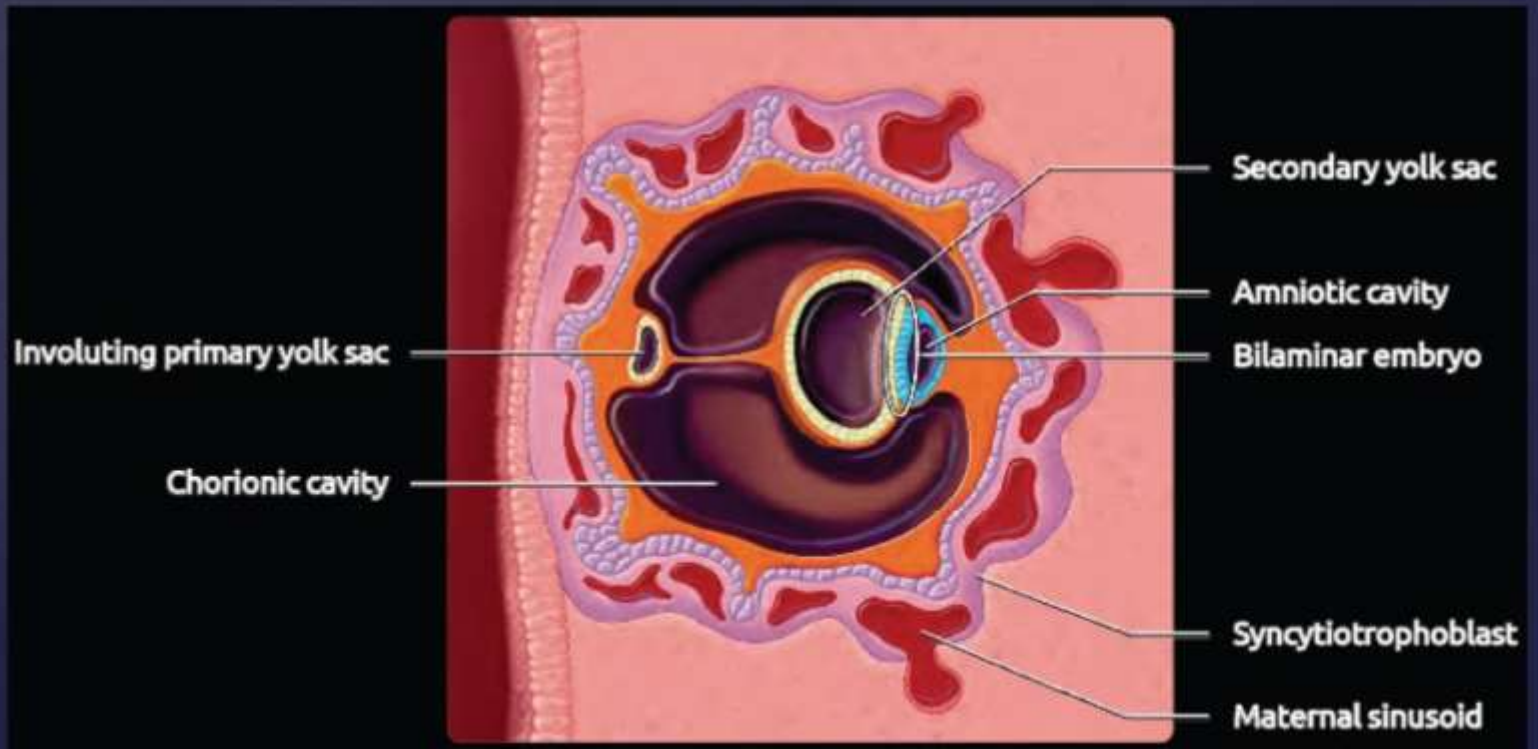

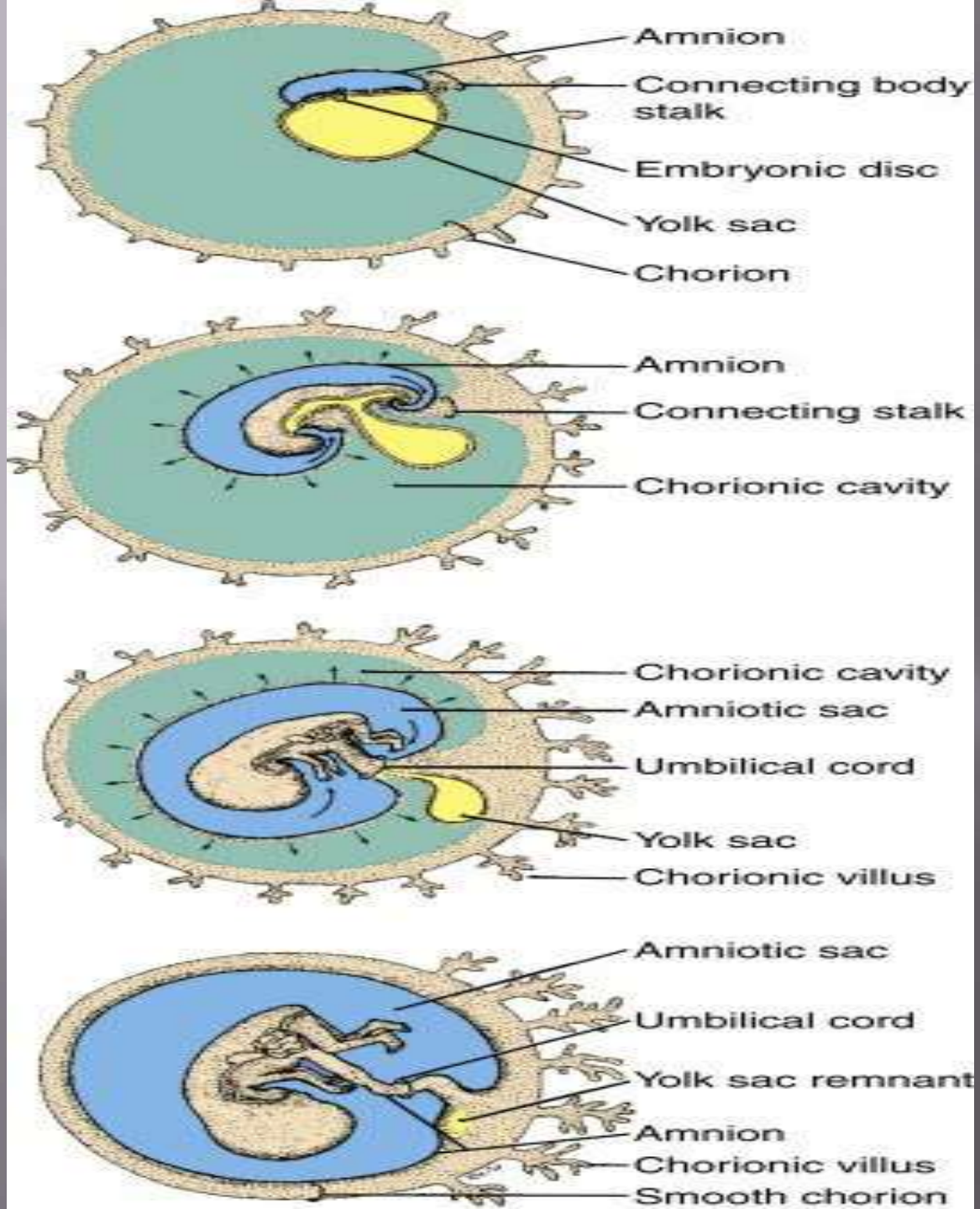
Amnion
Connecting body stalk
Embryonic disc
Yolk sac
Chorion
Amnion
Connecting stalk
Chorionic cavity
Chorionic cavity
Amniotic sac
Umbilical cord
Yolk sac
Chorionic villus
Amniotic sac
Umbilical cord
Yolk sac remnant
Amnion
Chorionic villus
Smooth chorion

- An erosion of the endothelial lining of the maternal capillaries by the syncytiotrophoblastic cells of the sinusoids will form where the blood will begin to penetrate and flow through the trophoblast to give rise to the uteroplacental circulation.

Day 13

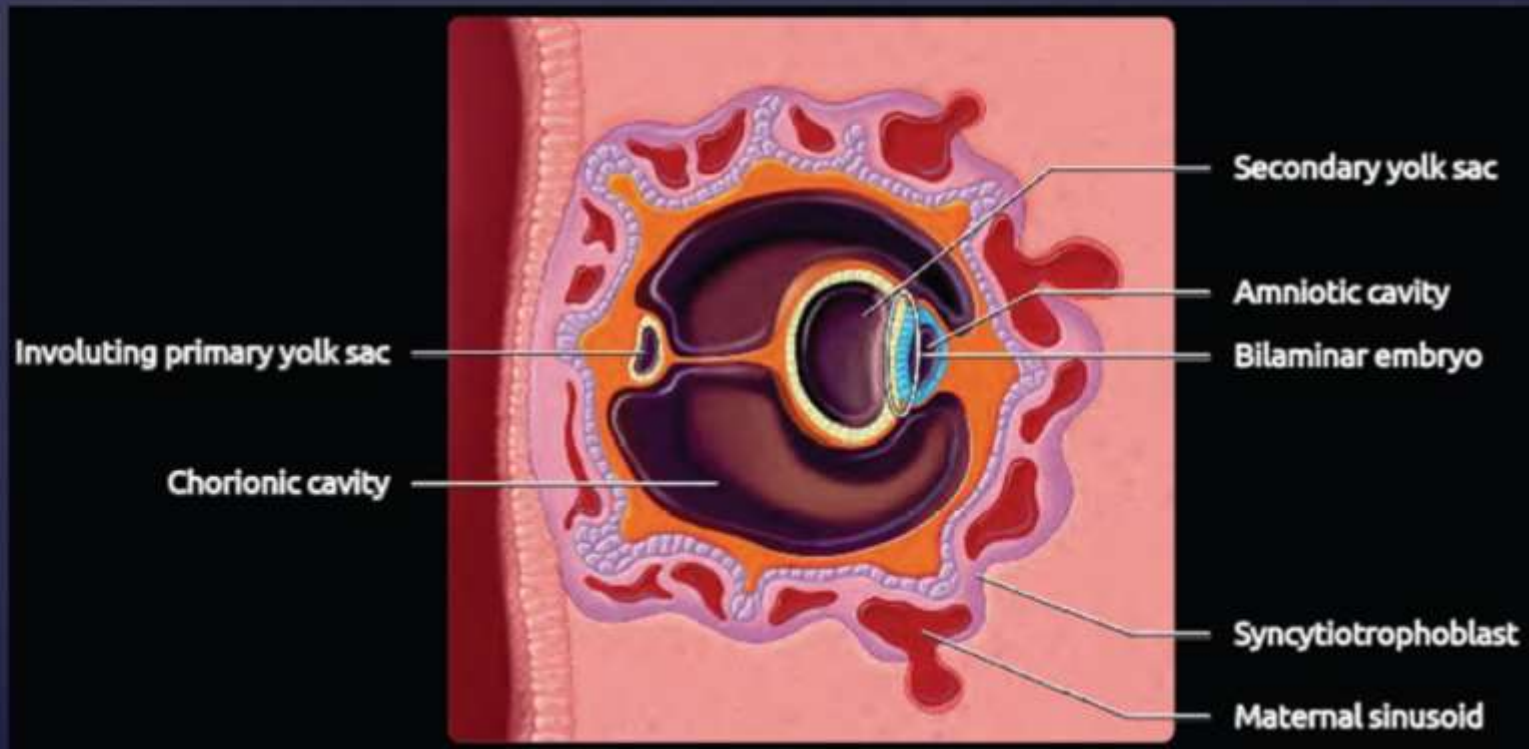

- The embryo is joined to the trophoblastic shell by a narrow connecting stalk that develops into the umbilical cord to attach the placenta to the embryo.

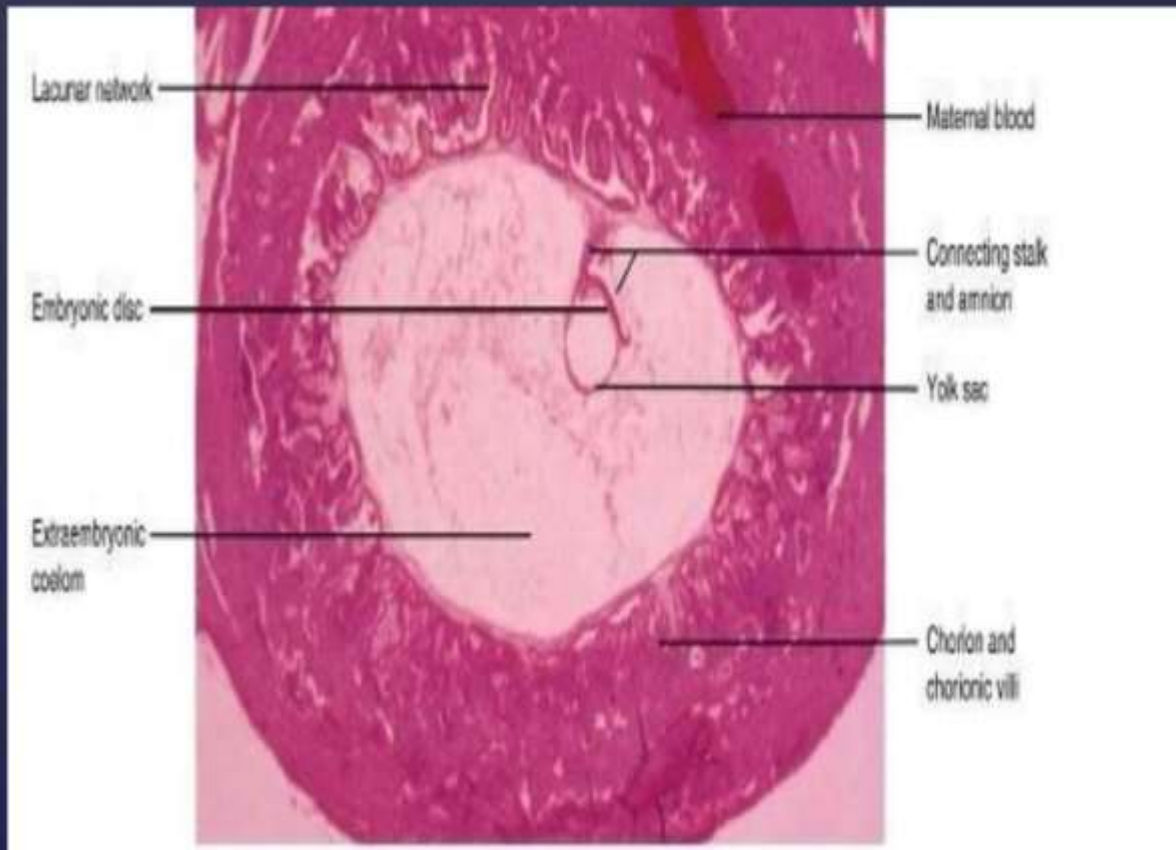

Third week

Cells from epiblast layer migrate between the two layers, becoming mesenchyme, embryonic connective tissue leading to differentiation of new embryonic layer within disc from mesenchyme, called mesoderm.

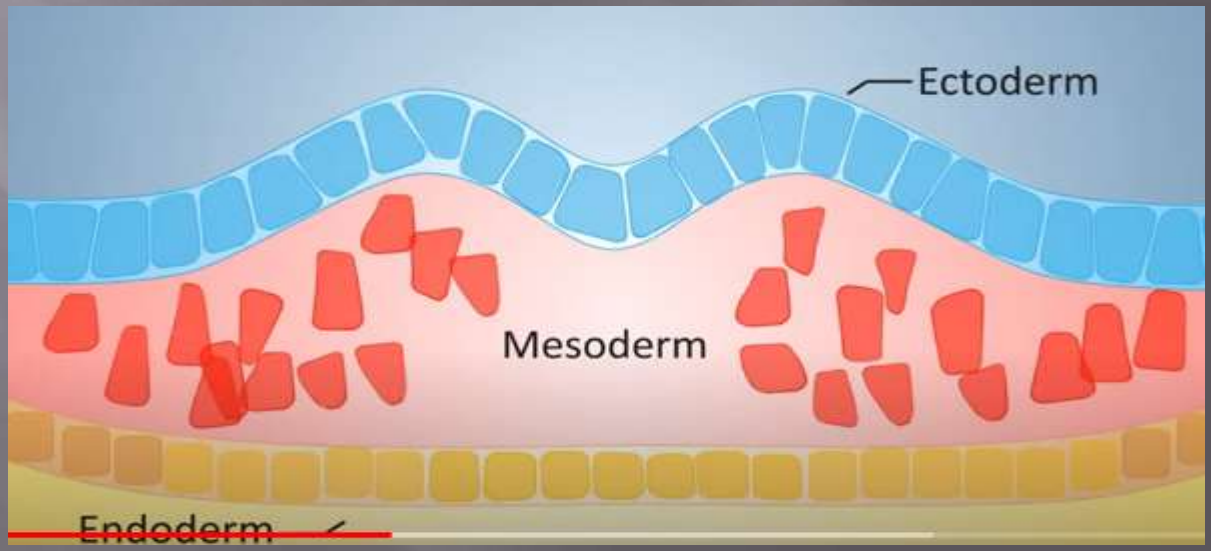

The embryo take the shape of trilaminar disc, three-layered disc with epiblast layer now ectoderm and hypoblast layer now endoderm.

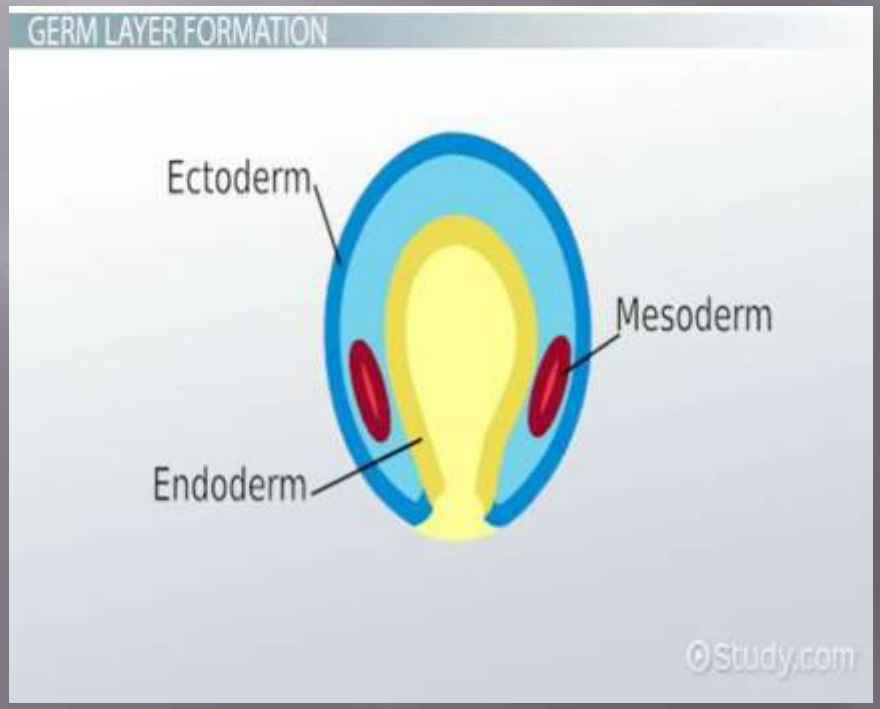



The embryonic disk soon acquires three layers:

- There are 3 layers formed as follows :
- 1- Ectoderm (outer layer) (epiplast) : ectodermal cells, form the outer body covering (epithelium), neural plate which form the brain, spinal cord.
- **(the outer skin layer, the sensory cells of the eyes, ears and nose, some of the nervous system and external skin glands**

- 2- mesoderm (middle layer) : mesodermal cells, develop the muscle, skeleton, & blood cells which is the (**middle layer of cells, which form the deep skin layer, muscle, bone marrow and blood cells, lymphatic system, reproductive organs and excretory organs including the salivary glands).**

- 3-Endoderm (inner layer) (hypoplast) : endodermal cells, become the gastrointestinal tube. Which is the (**inner layer of cells, which form the linings of the respiratory and digestive systems, liver and pancreas**).

Medical terms

- 1-Fertilization: Egg+ sperm = fertilization (occur in distal part of the uterine tube) fertilized egg then grow and converted to Zygote

- 2-Zygote: is a eukaryotic cell formed by a fertilization event between two gametes ,and contains all of the genetic information necessary to form a new individual.
- 3- Morula : is a solid mass of cells, zygote undergo further growth to form a ball of cells.

- 4- Blastocyst : is a Morula when increased size.
- 5- Embryoblast : Blastocyst later on becomes hollow and develops a small inner cell mass called the embryoblast (forms the embryo).The outer layer of cell lining is called the trophoblast (forms the placenta).
- 6- Basic germ layers: In the second week of prenatal life

Thank you